



Fibular Strut Graft with Cannulated Hip Screw of Neglected Femoral Neck Fracture in a Young Adult: A Case Report

Adiet Wahyu Kristian^{1*}, I. G. N. Bagus Andhika Pramana¹, A. A. Ngurah Krisna Dwipayana¹, I Ketut Suyasa², I. G. N. Wien Aryana²

¹Department of Orthopaedic and Traumatology, Udayana University, Sanglah General Hospital, Bali, Indonesia; ²Department of Orthopaedics and Traumatology, Faculty of Medicine, Udayana University, Sanglah General Hospital, Denpasar, Indonesia

Abstract

Edited by: Ksenija Bogoeva-Kostovska
Citation: Kristian AW, Pramana IGNBA, Dwipayana AANK, Suyasa IK, Aryana IGW. Fibular Strut Graft with Cannulated Hip Screw of Neglected Femoral Neck Fracture in a Young Adult: A Case Report. Open Access Maced J Med Sci. 2023 Apr 02; 11(C):109-114. <https://doi.org/10.3889/oamjms.2023.10916>
Keywords: Femoral neck fracture; Neglected; Cannulated hip screw
***Correspondence:** Adiet Wahyu Kristian, Department of Orthopaedic and Traumatology, Sanglah General Hospital, Udayana University, Bali, Indonesia.
E-mail: adietkristian@yahoo.co.id
Received: 05-Sep-2022
Revised: 19-Mar-2023
Accepted: 23-Mar-2023
Copyright: © 2023 Adiet Wahyu Kristian, I. G. N. Bagus Andhika Pramana, A. A. Ngurah Krisna Dwipayana, I Ketut Suyasa, I. G. N. Wien Aryana
Funding: This research did not receive any financial support
Competing Interests: The authors have declared that no competing interests exist
Open Access: This is an open-access article distributed under the terms of the Creative Commons Attribution-NonCommercial 4.0 International License (CC BY-NC 4.0)

BACKGROUND: Neglected femoral neck fractures in young adults (age <60) pose a major challenge in terms of appropriate treatments for each specific condition.

AIM: The objective of this case report is to explain the presentation of neglected femoral neck fractures and its clinical consequences and to discuss the management of the disease.

CASE PRESENTATION: This case presents a 14-year-old male with neglected displaced fracture of femoral neck, which was successfully managed by closed reduction and internal fixation with two cannulated screws and non-vascularized fibular strut graft.

CONCLUSION: Femoral neck fractures in young adults are considered as a rare fracture case, eventually it was associated with serious complications. The management of this type of fractures in children is challenging, particularly that of a neglected fracture. Fibular strut graft with two cannulated hip screws for neglected femoral neck fractures in children considered to be cost-effective and technically less demanding as well as associated with good outcomes.

Introduction

Neglected femoral neck fractures in young adults (age <60) pose a major challenge in terms of appropriate treatments for each specific condition. While there is still no defined period for a fracture to be called “neglected,” several studies have introduced the term. Manjunath has defined “neglected fracture” as a delay of 30 days or more from the injury to seek medical help [1], whereas Sandhu *et al.* assigned the term when it is 21 days of duration or longer [2]. The choice of treatment depends on the patient age, duration of injury, activity level, and extent of displacement, while the goals to be achieved include anatomic reduction, stable fixation, blood supply preservation to the bone fragments, and early mobilization for stiffness prevention [3].

Based on the previously stated considerations, attempts to preserve the viable femoral head in a young active patient are preferable than the sacrificing procedure options. Multiple methods have been used with varying success for treating neglected fractures of femoral neck. While the guidelines for ideal management are still evolving, surgeons should be

considerate decision-makers in terms of acclimatization to methods to appropriately recognize, manage, and prevent further complications for improved quality of life of the patient.

This case report features a case of a 14-year-old male with neglected displaced fracture of femoral neck, which was successfully managed by closed reduction and internal fixation with two cannulated screws and non-vascularized fibular strut graft. The method used in this case is relatively easy to perform, not requiring microvascular anastomosis, contributes to the repair of any incidental avascular necrosis (AVN), and is not burdened by the complications of intertrochanteric osteotomy such as limping.

Objective of case report

The objective of this case report is to explain the presentation of neglected femoral neck fractures and its clinical consequences and to discuss the management of the disease.

Ethical research approval

This case report has been approved by Udayana University ethical board and Prof. I.G.N.G Ngoerah central general hospital ethical board.

Case Report

A 14-year-old male presented to the Orthopedic Polyclinic with chief complaint of the right hip pain after falling down 3 weeks before the polyclinic consultation. The patient had a history of walking on the bathroom before suddenly slipped and fell down with the right hip bumped into the bathroom floor. Any history of unconsciousness, nausea, or vomiting was denied. The patient had been brought to a hospital immediately after falling down, and had been told that there was no abnormality found in his right hip. After the injury, the patient was still able to stand though in a painful limping gait that aggravated by the increasing frequencies of weight-bearing over the period of 3 weeks, before being brought to hospital. The patient was then referred by an orthopedic surgeon with a diagnosis of neglected close fracture of the right femoral neck for further management.

The physical examination in Figure 1 showed that the affected limb was externally rotated and deformed into hip flexion, while no swelling nor bruise was found. There was no tenderness felt, sensory function was normal and artery dorsalis pedis was palpable. The active range of movement of the hip was restricted and painful. The limb length discrepancy was calculated to be 2 cm. Telescopy test was positive, while Trendelenburg test could not be elicited. The pelvic X-ray in Figure 2 and 3 of both hip anteroposterior (AP) view 20° internal rotation showed a displaced femoral neck with sclerosis of margins, patchy sclerosis of head. Sentons line was broken. The pre-operative Harris hip score (HHS) was 55. He was admitted and immobilized on skin traction for 7 days before surgery to reduce the possibility of worsen the fracture.

Lateral approach and a straight skin incision over the greater trochanter and proximal femur was made like in Figure 4. On exposure of the hip, a fracture of femoral neck was found. A guidewire (K-wire) was inserted in the center of the femoral neck in both AP and lateral views and was used to guide the insertion of fibular graft. After it was positioned satisfactorily, the femoral neck was reamed over the third guidewire using the distal part of the 8 mm triple reamer. Nine centimeters of the mid ipsilateral fibular graft was harvested subperiosteally through a posterolateral approach. The fixation of the fracture is then done using two cannulated screws with the size of 8 mm and 85 mm, before the fibular strut graft was finally planted between those two cannulated screws with the length of approximately 80 mm. Durante c-arm could be seen

in Figure 5. The wound result can be seen in Figure 6 which sutured by layers and bleeding was calculated approximately 350 cc.

The patient was allowed to sit up in bed on the 1st post-operative day. The patient was discharged on the third day after the dressing was changed. Post-operative plain radiographs such as in Figure 7, 8, and 9 were done after discharge and on monthly intervals until union. Mobilization was started on the third post-operative day depending on the pain tolerance with non-weight-bearing method using crutches for the first 6 weeks. The weight bearing was then increased gradually as tolerated by the patient, allowing full weight-bearing after 3 months of surgery. Serial radiographs showed progressive healing (which showed fracture consolidation with incorporation of the fibular strut graft). The patient was seen in the outpatient department 3 months postoperatively and the HHS was 94.

Discussion

Fractures of femoral neck in young patients tend to be uncommon injuries, compared to their counterparts in older people. It accounts only for <1% of all fractures in children [5]. Most of the cases are caused by a relatively high-energy injury such as motor vehicle accidents and fall from height, and may be associated with additional extremity, visceral, or head injuries in 30% of patients [6]. This case presents a 14-year-old male with right hip pain after falling. Pathologic fractures can also occur due to low-energy injury and more rarely, stress fractures due to repetitive activity such as running and jumping. Femoral neck fracture is one of the most common hip fractures in children, along with the intertrochanteric region type. A delayed presentation of femoral neck fracture is defined as a delay of 48 h–20 days between injury to diagnosis, while in neglected fractures, the delay is more than 21 days based on Manjunath, or more than 30 days based on Sandhu *et al.* [1], [2], [7].

The higher risk of AVN in growing and developing child can be explained by the tenuous blood supply during the period of regression of the ligamentum teres artery and LCA branches after the age of 4–10 years, thus making the posterosuperior branch of MCA to be the major supplying vessel to the femoral head. The difference between the femoral neck fractures in children and in adults is due to the tenuous blood supply in children and the proximal femur with the thick periosteum being resilient, which necessitates significant force to cause a breakage [5], [8].

The classification of pediatric hip fractures can be generally divided by the method of Delbet into four types. This classification helps determine the treatment options and predicts the prognostic significance, such as

the risk of femoral head AVN. Type I is transepiphyseal separation, which is through the proximal femoral physis (<10%). Type II is transcervical fracture, which is considered as the most common type of pediatric hip fracture (40–50%) that extends through the mid-portion of the femoral neck. Type III is cervicotrochanteric fracture, which occur through the base of femoral neck (25–35%). Type IV is intertrochanteric fracture (between greater and lesser trochanter), which accounts for 6–15% of all pediatric hip fractures and has the best outcome [4], [5]. Moon and Mehlman showed that type I and type II were 15 and 4 times as likely, respectively, to develop AVN and growth arrest as type III and type IV. On the contrary, the latter groups tend to have more significant rates of varus malunion if not appropriately treated. Goldstein and Kim in Rockwood and Wilkins 9th edition also stated that subtrochanteric fractures have been included by some experts in the proximal femoral fractures discussion but is not yet included in the Delbet classification [6].

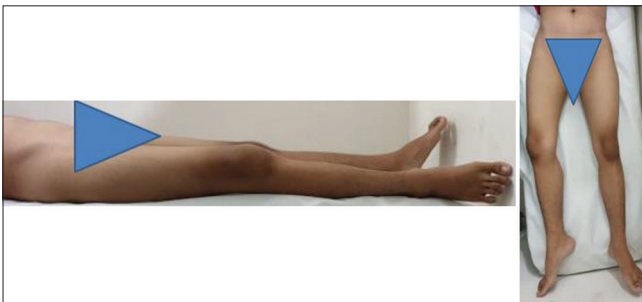


Figure 1: Clinical presentation of the patient (hip region)

The diagnosis of femoral neck fracture in young adults is based on the history of high-energy injury and typical signs and symptoms of the shortened, externally rotated, and painful lower extremity. A pelvic X-ray was done in the patient with both hip AP view 20° internal rotation was taken, showing a displaced femoral neck with sclerosis of margins, patchy sclerosis of head. Sentons line was broken. Clinical features are usually apparent, and a patient with a complete fracture is unable to move due to severe pain in hip and has a shortened, externally rotated extremity. The diagnosis is confirmed by plain radiographs in two views. The AP view of pelvis with hip extended and 15° internally rotated will show any displacement compared to the opposite side. Cross-table lateral view should also be taken to avoid any displacement and pain while mobilization, as well as a full-length radiograph AP and lateral views of the femur to complete the assessment. Furthermore, non-displaced fracture or stress fractures might be difficult to detect on radiographs. Special studies may be required to reveal an occult fracture, which may include computed tomography scan, magnetic resonance imaging, or a technetium bone scan that can demonstrate increased uptake at the fracture site [5], [6].

The treatment options for neglected displaced femoral neck fracture in young adults are focused on

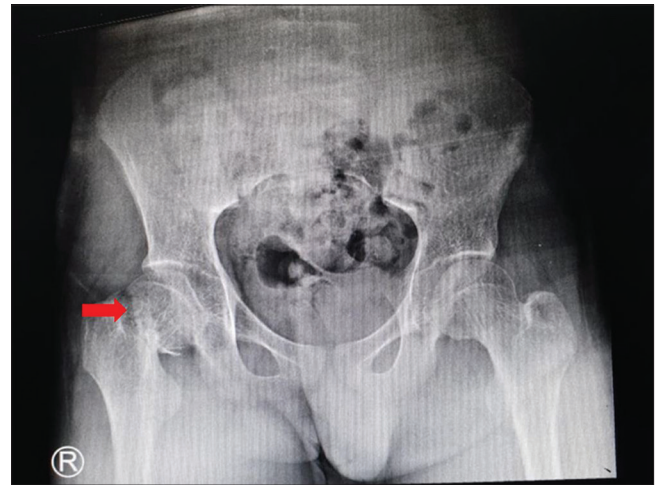


Figure 2: Pelvic X-ray AP view at the time of presentation (09/04/2020)

salvaging the femoral head, preventing osteonecrosis, and non-union. The preserving procedures can be done if femoral head is viable, which include fixation alone, osteotomy with/without fixation, non-vascularized/free bone grafting (muscle pedicle bone/cortical bone) with/without fixation, vascularized fibular grafting, combination of osteotomy and bone grafting, and combination of fixation with platelet rich plasma. Whereas salvaging procedures include the following techniques of arthroplasty; unipolar, bipolar, total hip, girdle stone, and arthrodesis [6], [8].

Although there are still no definitive guidelines to surgically treat young particularly pediatric patients with neglected femoral neck fracture, multiple methods have been used with varying success. Cui *et al.* stated in their meta-analysis that the treatment options have

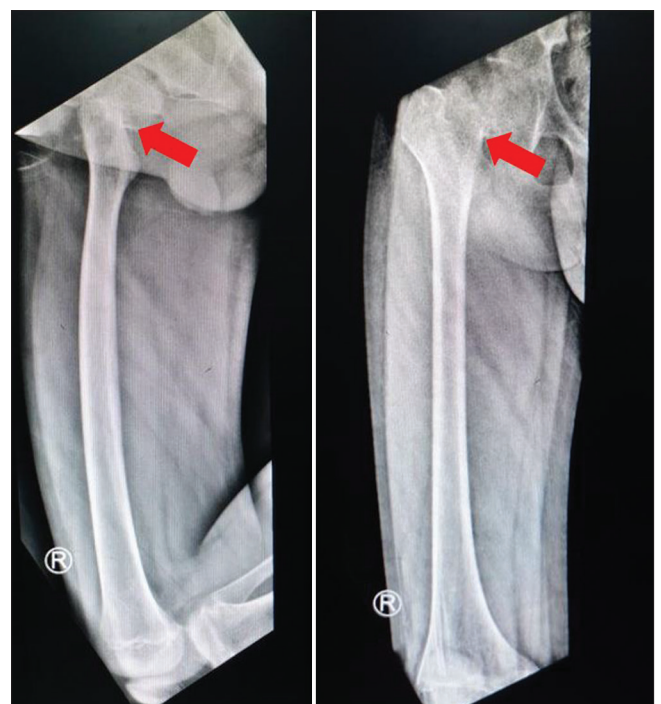

Figure 3: Right thigh X-ray AP/lateral view at the time of presentation (09/04/2020)

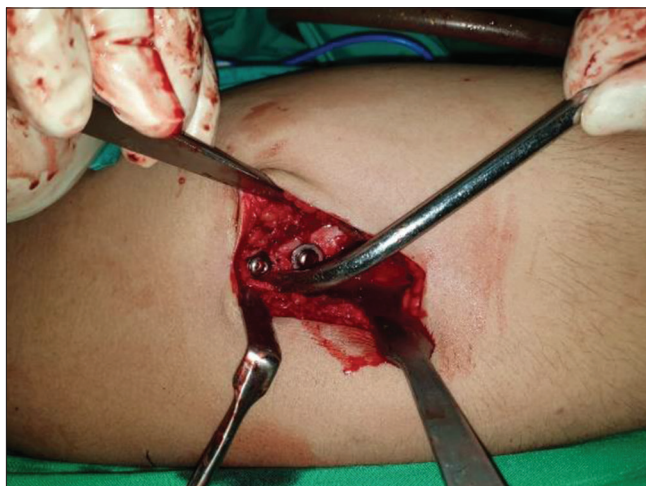

Figure 4: Right thigh operation (15/04/2020)

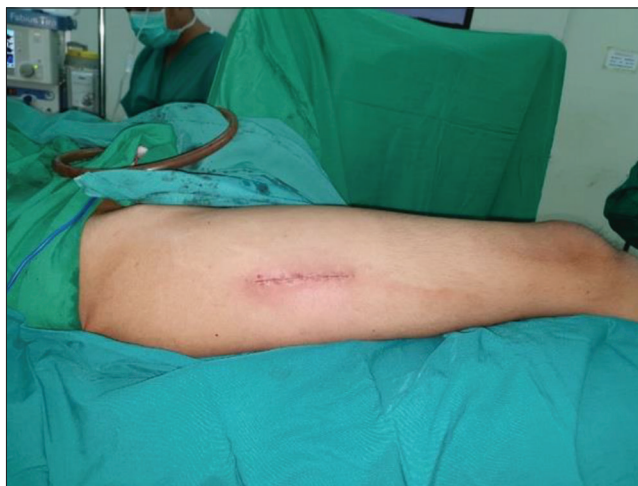

Figure 6: Clinical picture post-operative (15/04/2020)

predominantly used internal fixation in combination with either osteotomy or bone grafting (vascularized or non-vascularized), with hip arthroplasty being a salvage procedure [9]. Internal fixation is seldom performed alone in the neglected femoral neck fractures. It is probably due to higher AVN rate of 22.30% found in a meta-analysis done by Elzohairy and Eid, which was successful in 76.5% (95% CI 65.58–83.81%) of cases [7], whereas osteotomy has been used to alter the biomechanical features at the fracture site, both with or without internal fixation, and in some cases with the addition of bone grafting to help promote bone healing. Osteotomy with internal fixation had a union rate of 91.33% (95% CI 84.91–92.87), whereas fractures fixed by internal fixation with pedicled muscle graft proceeded to union in 86.25% (95% CI 78.92%–88.54%) of cases and those managed with free fibular graft in 88% (95% CI 78.35%–90.84%), respectively. The internal fixation and osteotomy group also had the lowest rate of AVN at 6.29%, followed by the internal fixation with free fibular graft group (10.20%) and then internal fixation with pedicled muscle graft (12.08%). However, osteotomy poses two significant problems, including shortening, limp, a decreased range of movement, and several potential risks of non-union at the osteotomy site. The rates of AVN as the results of osteotomy done in several studies of Roshan and Ram’s meta-analysis ranged between 6% and 42% and a non-union rate between 0% and 45%. When measured by differing criteria, a “good” functional outcome of

postosteotomy has been recorded in 35% to 80% of the subject population. Meanwhile, bone grafting has been the most widely used method to treat neglected femoral neck fractures, with often excellent results in use of both vascularized (muscle pedicle/iliac crest) and non-vascularized (Phemister-type cortical tibial grafts and free fibular strut grafts) bone grafts [7], [9].

Free fibular graft procedure has been widely considered as a method to assure both structural support and a graft framework in a neglected femoral neck fracture. This procedure results in non-union rates between 0% and 17% and AVN rates of 0–33% [9]. The advantages of free fibular graft are stated to be technically simple with minimal donor site morbidity, which providing additional rotational stability due to the trephine shape of the graft itself, and the medullary canal of the graft allowing a guide pin insertion for ease of introduction. Based on a meta-analysis of Elzohairy and Eid, fixation with three cancellous screws provides firm fixation, whereas parallel lag screws permit collapse while maintaining position. The fibula shape stabilizes the fracture by preventing rotation, and subchondral

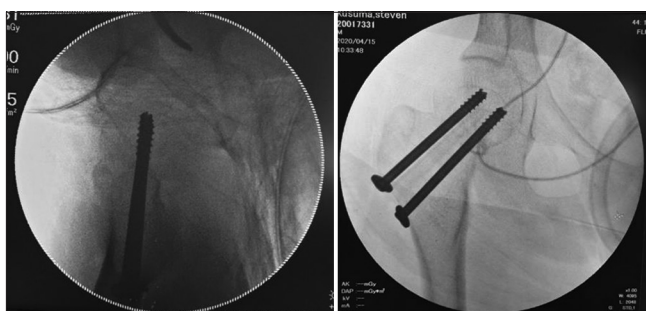

Figure 5: Right thigh C-arm view (15/04/2020)

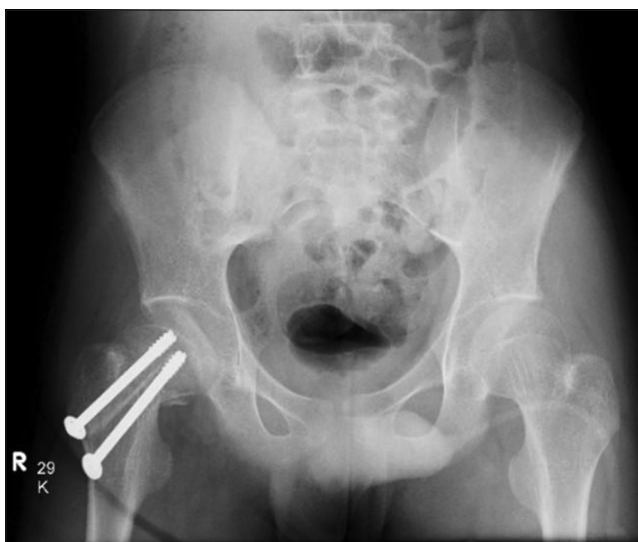

Figure 7: Post-operative pelvic X-ray AP view (15/04/2020)

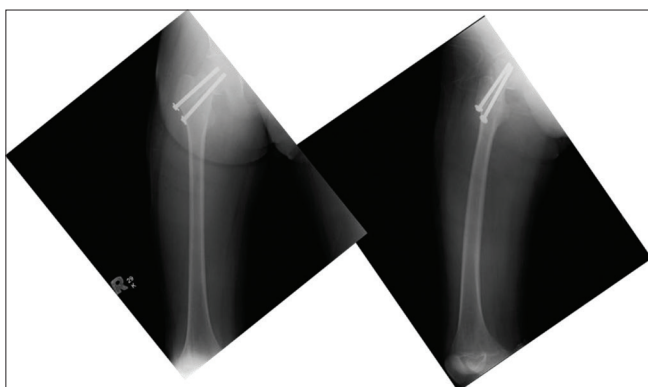


Figure 8: Post-operative right thigh X-ray AP/lateral view (15/04/2020)

placement of bone in avascular femoral heads might minimize structural collapse until revascularization occurs. The meta-analysis by Roshan and Ram also stated the preferred method for treating neglected femoral neck fracture in young adults to be a free fibular graft with two cannulated screws, and early mobilization (AVN 0–6.5%, non-union 9–12%) [7], [8], [9].

In this case report, the neglected femoral neck fracture, treated with closed reduction by traction, fibular strut graft, and two cannulated hip screw fixations with lateral approach achieved a good outcome. However, there are controversies in the literature whether to perform open or closed reduction. Many experts in their reports advocated open reduction to ensure proper excision of the pseudoarthrosis, freshening the fracture, anatomic reduction, and to avoid intracapsular vessels damage [11], [12]. Yet Damany *et al.*, in their meta-analysis of 18 studies on femoral neck fracture of 564 patients, found that with open reduction, the non-union rate increased to 11.2% (from overall 8.9%) compared with 4.7% for fractures treated with closed reduction. It has been stated based on authors' experience that gentle gradual accurate-closed reduction might be possibly useful without too much nor too many manipulations affecting vascularity [13].

Fibular grafting has a role as a combination of fixation device and bone graft augmenting union during the reconstruction of the neck and head of femur, which is the reason that it has been recommended for the treatment of

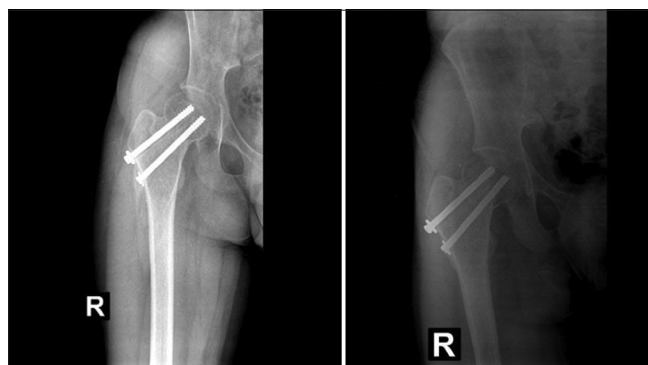

Figure 9: X-ray examination 6 month and 1 year follow-up after surgery

neglected or non-union femoral neck fractures [14]. It also provides sufficient osteoconductive and osteoinductive potential, which as previously stated, is a reliable biological implant in revascularization and rotational stabilization due to its trephine shape, thus attributed to the good result of the patient reported in this case, along with the gentle manipulation of closed reduction avoiding the disruption of the already compromised femoral head blood supply [14], [15], [16]. Moreover, cannulated screws have been universally used for femoral neck fracture fixation, providing better fixation compared to pins, and are recognized to have a significantly lower risks of non-union and infection than the sliding screw-plate [14].

Fractures of the femoral neck are associated with a high level of complications, including AVN, non-union, premature physical closure, and coxa vara, as well as arthrofibrosis in conditions of neglected cases. AVN is the most serious and most common complications. A considerable number of literatures revealed a variable incidence, depending on the patients' age, the initial displacement degree, the type of fracture, the surgery time, and the fixation method [17]. A study by Gupta *et al.* demonstrating a technique using muscle pedicle bone grafting with internal fixation has been proposed in the prevention of non-union and AVN of the femoral head [18]. Femoral head drilling could decompress the necrotic bone and promotes the vascular granulation tissue growth, whereas the muscle graft acts as a vascular graft, promoting bone growth, as well as the femoral head revascularization [9]. The result of this case report is similar to the results achieved with the recent treatment methods for the femoral neck fracture in young adults, in which the treatment goals are as follows: early diagnosis, early surgery, anatomical reduction, capsular decompression, and the fracture stability [11]. In the presented case, efforts were done to achieve a stable internal fixation using fibular strut graft with two cannulated hip screws for satisfactory functional outcome as well as reduced complications of a neglected femoral neck fractures.

The HHS was developed to measure the outcome of hip surgery including pain, function, absence of deformity, and range of motion [19]. The HHS score usually used for total hip replacement, femoral neck fractures, and osteoarthritis [20]. The presented case showed significant improvement of HHS score before (55) and after surgery (94). In younger children <7–8 years and in Delbet types I, II, and III with the risk of displacement after fixation, a single hip spica should be applied. Early mobilization for older patients with type III and IV fractures and stable plate fixation can be carried out as mentioned above. Hip spica immobilization may be needed in children with inadequate fixation, unreliable patients, and in patients with poor bone biology [22]. In this case report, mobilization was started on the 3rd post-operative day depending on the pain tolerance with non-weight-bearing method using crutches for the initial 6 weeks. The weight-bearing was then increased gradually as tolerated by the patient, allowing full weight-bearing after 3 months of surgery.

Conclusion

Femoral neck fractures in young adults in Bali are considered as a rare fracture case; eventually, it was associated with serious complications. The management of this type of fractures in children is challenging, particularly that of a neglected fracture. Fibular strut graft with two cannulated hip screws for neglected femoral neck fractures in children considered to be cost-effective and technically less demanding as well as associated with good outcomes. Further, follow-ups are awaited in a greater number of such cases to help further strengthening this method as a definitive treatment strategy in femoral neck fracture, and hence, becoming a new lead to further enhancement of the outcome which is the patient's quality of life.

Authors' Contributions

1. Emma Novauli Hutabarat: conception, literature review, analysis, data collection, writing-review, and editing
2. Faridha Ilyas: conception, literature review, and editing
3. Safruddin Amin: conception, methodology, supervision, and editing.

References

1. Manjunath D. Advances in fractures in the neck of the femur in adults. In: *Hip Joint in Adults: Advances and Developments*. United Arab Emirates: Jenny Stanford Publishing; 2018. p. 123-39.
2. Sandhu HS, Sandhu PS, Kapoor A. Neglected fractured neck of the femur: A predictive classification and treatment by osteosynthesis. *Clin Orthop Relat Res*. 2005;431:14-20. PMID:15685050
3. Chand DK, Mohapatra BN. Fibular osteosynthesis with cannulated hip screw fixation of neglected femoral neck fracture in a young adult: Case report. *Int J Adv Res*. 2016;5(1):536-9.
4. Warwick D, Blom A, Whitehouse M. Femoral neck fractures. In: *Apley & Solomon's Concise System of Orthopaedics and Trauma*. Boca Raton: CRC Press; 2021. p. 687-9.
5. Palocaren T. Femoral neck fractures in children: A review. *Indian J Orthop*. 2018;52(5):501-6. https://doi.org/10.4103/ortho.IJOrtho_404_17 PMID:30237607
6. Waters PM, Skaggs DL, Flynn JM. *Rockwood and Wilknie's Fractures in Children: Orthopaedics Trauma Association*. 9th ed. Wolters Kluwer; 2019. p. 1405-20.
7. ELzohairy MM, Eid AS. Meta-analysis of different methods used for joint preserving procedures in the management of delayed, neglected, and non-united femoral neck fractures in young adults. *Trauma*. 2016;18(4):245-9. <https://doi.org/10.1177/1460408616645612>
8. Elzohairy MM. Recent concept for management of femoral neck fracture non-union in young adults. *Ortho & Rheum Open Access J*. 2017;6(4):66-72.
9. Cui L, Zhuang Q, Lin J, Jin J, Zhang K, Cao L, *et al*. Multicentric epidemiologic study on six thousand three hundred and ninety five cases of femoral head osteonecrosis in China. *Int Orthop*. 2016;40(2):267-76. <https://doi.org/10.1007/s00264-015-3061-7> PMID:26660727
10. Patterson JT, Tangtiphaibontana J, Pandya NK. Management of pediatric femoral neck fracture. *J Am Acad Orthop Surg*. 2018;26(12):411-9. <https://doi.org/10.5435/JAAOS-D-16-00362> PMID:29781820
11. Song KS. Displaced fracture of the femoral neck in children: Open versus closed reduction. *J Bone Joint Surg Br*. 2010;92(8):1148-51. <https://doi.org/10.1302/0301-620X.92B8.24482> PMID:20675763
12. Damany DS, Parker MJ, Chojnowski A. Complications after intracapsular hip fractures in young adults. A meta-analysis of 18 published studies involving 564 fractures. *Injury*. 2005;36(1):131-41. <https://doi.org/10.1016/j.injury.2004.05.023> PMID:15589931
13. Elgeidi A, El-Negery A. Fibular strut graft for nonunited femoral neck fractures in children. *J Child Orthop*. 2017;11(1):28-35. <https://doi.org/10.1302/1863-2548-11-160221> PMID:28439306
14. Mittal R, Banerjee S. Proximal femoral fractures: Principles of management and review of literature. *J Clin Orthop Trauma*. 2012;3(1):15-23. <https://doi.org/10.1016/j.jcot.2012.04.001> PMID:25983451
15. Jaiswal A, Pruthi KK, Goyal RK, Pathak V, Habib M, Tanwar YS, *et al*. Evaluation of osteosynthesis with dual fibular bone grafting for neglected femoral neck fractures. *J Clin Orthop Trauma*. 2013;4(2):58-69. <https://doi.org/10.1016/j.jcot.2013.04.003> PMID:26403626
16. Moon ES, Mehlman CT. Risk factors for avascular necrosis after femoral neck fractures in children: 25 Cincinnati cases and meta-analysis of 360 cases. *J Orthop Trauma*. 2006;20(5):323-9. <https://doi.org/10.1097/00005131-200605000-00005> PMID:16766935
17. Ratliff AH. Fractures of the neck of femur in children. *J Bone Joint Surg Br*. 1962;44-B:528-42. <https://doi.org/10.1302/0301-620X.44B3.528> PMID:14038616
18. Gupta AK, Sanjai R, Nath R. Internal fixation and muscle pedicle bone grafting in femoral neck fractures. *Indian J Orthop*. 2008;42(1):39-42. <https://doi.org/10.4103/0019-5413.38579> PMID:19823653
19. Nilsdotter A, Bremander A. The HHS was developed for the assessment of the results of hip surgery. *Arthritis Care Res*. 2011;63:S200-7.
20. Frihagen F, Grotle M, Madsen JE, Wyller TB, Mowinckel P, Nordsletten L. Outcome after femoral neck fractures: A comparison of Harris Hip Score, Eq-5d and barthel index. *Injury*. 2008;39(10):1147-56. <https://doi.org/10.1016/j.injury.2008.03.027> PMID:18656868