



# Diagnostic Accuracy of Lung Ultrasound in Patients with Community-Acquired Pneumonia: A Single Center Observational Study

Marwa Elsayed<sup>1\*</sup>, Moataz Ahmed Hesham<sup>2</sup>, Khaled Mahmoud Kamel<sup>3</sup>, Yasser Sadek Nassar<sup>1</sup>

<sup>1</sup>Department of Critical Care, Cairo University, Giza, Egypt; <sup>2</sup>Cairo University Student Hospital, Giza, Egypt; <sup>3</sup>Department of Pulmonology Medicine, Cairo University, Giza, Egypt

## Abstract

**BACKGROUND:** Pneumonia is a prevailing and severe infectious disease that can lead to increased fatality.

**AIM:** We conducted this study to assess the role of lung ultrasound (LUS) in the diagnosis of community-acquired pneumonia (CAP) in comparison to CXR and CT Chest.

**METHODS:** An observational study on 120 patients with suspected CAP was done in the ICU of the Critical care department at Cairo University Hospital. Clinical and laboratory data were recorded on admission including different scoring systems (SOFA, APACHE II, confusion, uremia, respiratory rate and blood pressure 65, and pulmonary severity index). All patients, within 6 h of admission, were investigated by a LUS, CXR, and CT Chest. All imaging techniques were repeated after 48 h if the initial CT chest was negative.

**RESULTS:** The study population had a mean age of  $70.6 \pm 6.9$ -years-old, most of them were male (75.8%). Using CT chest as a reference imaging tool to confirm the diagnosis of pneumonia, LUS showed 94.1% sensitivity, 97.1% specificity, positive predictive value (PPV) 98.8%, negative predictive value (NPV) 87.2%, accuracy 95.0%, and area under a curve (AUC) 0.92. LUS was found to be a highly significant imaging tool in predicting diagnosis of pneumonia ( $p < 0.001$ ). Chest X-ray had 69.4% sensitivity, 94.3% specificity, PPV 96.7%, NPV 55.9%, 76.6% accuracy, and AUC 0.6 in the detection of pneumonia. CXR was found to be an insignificant imaging tool in predicting diagnosis of pneumonia ( $P = 0.19$ ).

**CONCLUSION:** LUS is a very promising, sensitive, and feasible imaging tool in the diagnosis of CAP in comparison with CT chest.

**Edited by:** Mirko Spiroski  
**Citation:** Elsayed M, Hesham MA, Kamel KM, Nassar YS. Diagnostic Accuracy of Lung Ultrasound in Patients with Community-Acquired Pneumonia: A Single Center Observational Study. Open Access Maced J Med Sci. 2022 Nov 05; 10(B):2405-2410. https://doi.org/10.3889/oamjms.2022.10975  
**Keywords:** Lung ultrasound; Community-Acquired Pneumonia; CT chest; CXR; ICU  
**\*Correspondence:** Marwa Elsayed, Department of Critical Care, Cairo University, Giza, Egypt. E-mail: marwaelsayed@kasralainy.edu.eg  
**Received:** 19-Sep-2022  
**Revised:** 22-Oct-2022  
**Accepted:** 25-Oct-2022  
**Copyright:** © 2022 Marwa Elsayed, Moataz Ahmed Hesham, Khaled Mahmoud Kamel, Yasser Sadek Nassar  
**Funding:** This research did not receive any financial support  
**Competing Interests:** The authors have declared that no competing interests exist  
**Open Access:** This is an open-access article distributed under the terms of the Creative Commons Attribution-NonCommercial 4.0 International License (CC BY-NC 4.0)

## Introduction

Pneumonia has an increased medical and economic burden with a considerable impact on mortality and morbidity worldwide. It had a constant incidence over the last few decades affecting 3–5 persons/1000/year, more among the young and elderly [1].

Pneumonia is commonly classified according to the site of occurrence:

- Community-acquired pneumonia (CAP) is an acute infection of the lung parenchyma acquired out of the medical facility.
- Nosocomial pneumonia is an acute infection of the lung parenchyma acquired in-hospital settings and includes both ventilator-associated pneumonia (VAP) and hospital-acquired pneumonia.

The diagnosis of CAP is based on the detection of an infiltrate on the chest radiogram in a patient with clinically-compatible symptoms (pyrexia, dyspnea, cough, and expectoration) [2]. CXR is the most

common imaging approach [3]. The chest CT scan is considered the gold-standard imaging approach for pneumonia [4].

The use of lung ultrasound (LUS) was limited to the diagnosis of pleural effusions, pleural tapping, and biopsy [5]. The use of LUS has gained popularity in critical care settings and emergency rooms in the last decade and has become increasingly utilized as a diagnostic tool for CAP [6].

Alveolar consolidation is the diagnostic feature of pneumonia. The definition of consolidation is an isochoic tissue-like structure, which is caused by the loss of lung aeration. Power Doppler is sometimes used to differentiate tissue-like structures (e.g., echoic pleural effusion) from consolidation. The shred sign is a characteristic of consolidation [7].

Therefore, the utilization of LUS can lower the frequency of chest X-rays and CT scans and lowers the patient's radiation exposure. It can be repeated easily at the bedside and gives more accurate diagnostic data than CXR in the critically-ill and emergency patients with lung consolidation.

The BLUE protocol is a rapid protocol (<3 min), which provides the diagnosis of acute respiratory failure. It includes a venous analysis done in appropriate cases. Pulmonary embolism pulmonary edema, pneumonia, asthma, chronic obstructive pulmonary disease, and pneumothorax yield specific profiles. The FALLS protocol adapts the BLUE protocol to acute circulatory failure [8]. LUS provided a high accuracy in diagnosing different causes of acute respiratory distressed patients. The BLUE protocol avoided the need for urgent transfer of unstable patients for CT scanning [9].

## Methods

An observational study on patients with suspected CAP admitted to the ICU of the Critical care department at Kasr El Ainy University Hospital was done. The study took place from November 2020 to June 2021 (Figure 1).

### Inclusion criteria

The following criteria were included in the study:

- Adult patients with suspected pneumonia on clinical background were admitted to our ICU
- Confusion, uremia, respiratory rate, and blood pressure-65 score equal to 3 or more.

### Exclusion criteria

The following criteria were excluded from the study:

- Pregnancy
- Nosocomial pneumonia
- Hemodynamically unstable patient
- Multiple organ failure and terminal malignancy.

After the selection of the patients according to inclusion and exclusion criteria, all patients were subjected to the following

- Obtaining an informed, written consent to participate in the study from the patient on his legal representation
  - History and clinical examination
  - Calculation of CURB 65, pulmonary severity index (PSI), SOFA, and APACHE II scoring systems
  - Laboratory investigations: Including CBC, C-reactive protein (CRP), procalcitonin (PCT), and ABG. Furthermore, sputum culture was sent whenever possible either expectorated or taken through an endotracheal tube with a protected and aseptic technique
- All patients within 6 h of admission performed

a LUS, CXR, and CT chest. If initial CT within 6 h was negative, a follow-up CT scan after 48 h was done, together with LUS and CXR.

### LUS technique

- LUS was done according to BLUE Protocol [10]. Specifically, the blue points were used to detect signs of pneumonia [11] (Figure 2).

### Statistical analysis

Data were checked, coded, and analyzed using SPSS version 23 for data processing. Data were expressed as number and percentage for qualitative variables and mean  $\pm$  standard deviation for quantitative-one. The receiver-operating characteristics curves for LUS and CXR were compared for CT chest, and sensitivity, specificity, negative predictive value (NPV), positive predictive value (PPV), and area under a curve (AUC) were calculated.  $p < 0.5$  was considered significant.

## Results

Regarding demographics, our study showed that the mean age of the studied group was  $70.6 \pm 6.9$ , most of them (75.8%) were males. For comorbidities, the most common comorbidities among the studied group were diabetes mellitus, hypertension, and asthma.

Our study showed a mean serum CRP  $160.2 \pm 34.9$  and serum PCT was  $2.87 \pm 0.34$ . The mean APACHE was  $14.14 \pm 7.9$ , mean SOFA score was  $3.84 \pm 1.4$ , mean PSI score was  $157.9 \pm 36.9$ , and mean CURB score was  $3.99 \pm 0.15$  (Table 1).

On admission, LUS was able to detect 75 cases (96.1%) out of 78 positive cases, after 48 h LUS was able to detect five cases (71.4%) out of seven cases. Lung US was able to detect 80 positive cases (94.1%) out of 85 CT chest confirmed pneumonia cases while LUS failed to detect 5 cases confirmed pneumonia by CT Chest (Table 2).

LUS was able to exclude pneumonia in 34 out of 35 negative cases that were confirmed negative by CT Chest, while LUS failed to exclude one case. There was no statistically significant difference between LUS and CT chest, as regarding the ability to detect pneumonia ( $p = 0.11$ ) with a high degree of agreement between them (Kappa agreement 0.913).

As a remarkable observation, LUS detected one case early on admission to be pneumonia while it was not detected by CT scan on admission; however, it was confirmed pneumonia by CT scan later after 48 h.

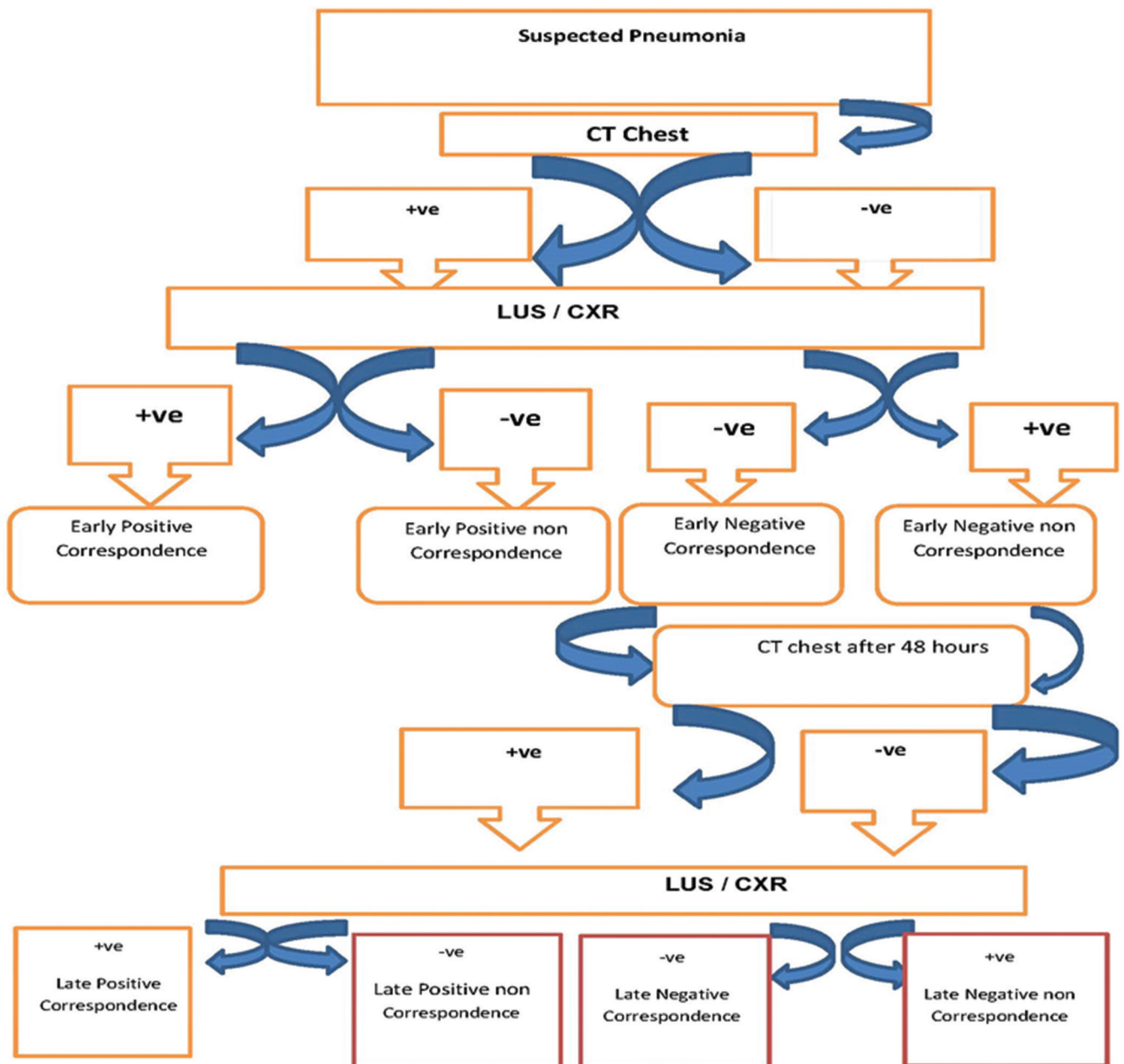


Figure 1: Flow chart of study methods

On the admission, CXR was able to detect 59 cases (75.6%) out of 78 positive cases, after 48 h LUS was able to detect 1 case (14.2%) out of seven cases. Chest X-ray was able to detect 59 positive cases (69.4%) out of 85 CT chest confirmed pneumonia cases while chest X-ray failed to detect 26 cases confirmed pneumonia by CT chest on admission and after 48 h.

Chest X-ray was able to exclude 33 out of 35 negative cases that were excluded by CT chest while chest X-ray failed to exclude one case. There was a high statistically significant difference between chest X-ray and CT chest as regarding the diagnosis of pneumonia ( $p < 0.001$ ) with a moderate degree of agreement between them (Kappa agreement 0.624).

## Discussion

LUS is a practical, portable, easy to learn, and non-ionizing radiation technique. The use of LUS has long been limited to the diagnosis of pleural effusions, plural tapping, and biopsy-guided procedures; however, it has been shown to be highly effective in diagnosing pulmonary diseases such as pneumonia and pneumothorax.

We conducted an observational study on 120 patients admitted to ICU with the suspected diagnosis of CAP. For them, the CT chest was done for confirmation of the diagnosis and both LUS and CXR were done for comparison.

Regarding the accuracy of LUS for the diagnosis of pneumonia, we demonstrated that LUS is a reliable

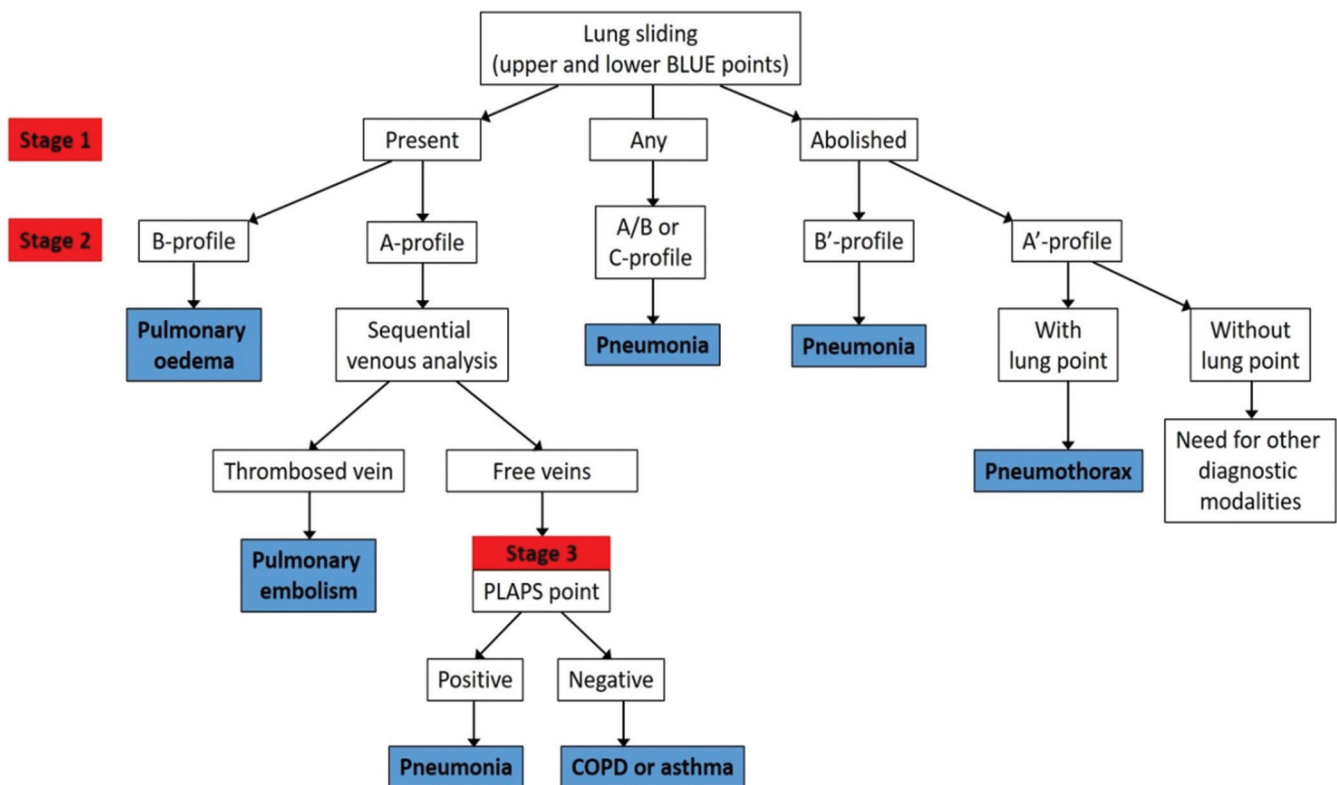


Figure 2: The BLUE protocol of lung ultrasound [10]

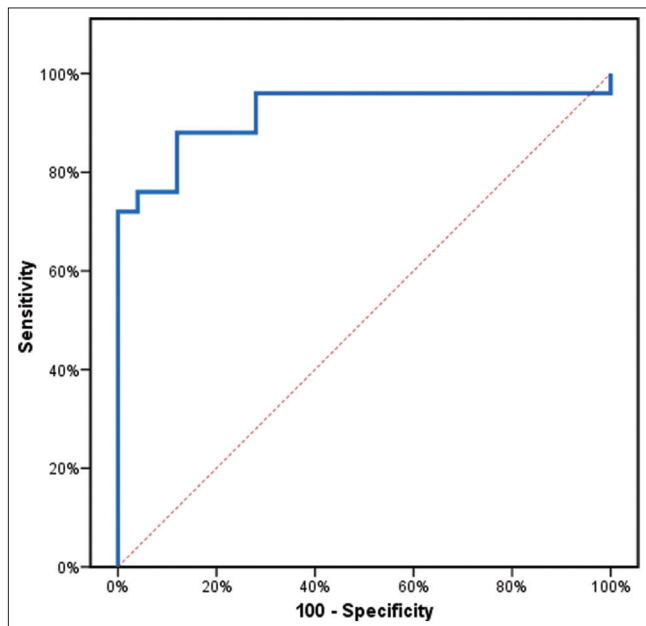


Figure 3: Receiver-operating characteristics curve for lung ultrasound to predict community-acquired pneumonia

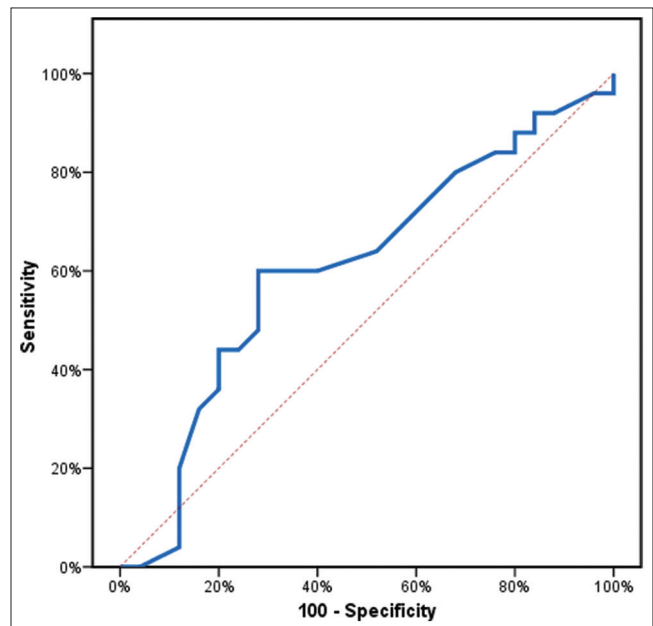


Figure 4: ROC curve for chest X-ray to predict community-acquired pneumonia

non-invasive technique for the detection of pneumonia cases with a high 94.1% sensitivity, 97.1% specificity, and 95% accuracy. On the contrary, we demonstrated that CXR is an unreliable technique; with a very low 69.4% sensitivity, 94.3% specificity, and 76.6% accuracy in the detection of Pneumonia (Tables 3-8 and figures 3-4).

In agreement with our study, Reissig *et al.* showed that in 229 patients with CAP, LUS revealed 93.4% sensitivity and 97.7% specificity. The study

demonstrated that CAP may be diagnosed and followed up with LUS and that the CT chest is necessary in cases with negative ultrasound results [12].

Similarly, Nafae *et al.* studied 80 cases with confirmed pneumonia by CT chest. LUS was positive in 78 cases, while CXR was positive in 62 cases only. LUS revealed 97.5% sensitivity, 75% specificity, and 93% accuracy, while CXR revealed 77.5% sensitivity, 60% specificity, and 74% accuracy [13].



**Table 1: Demographic, clinical and laboratory data of the studied group**

Variable	The studied group (n = 120) Mean ± SD
Age (years)	70.6 ± 6.9
Gender, n (%)	
Males	91 (75.8%)
Females	29 (24.2%)
Smoking	
Non	30 (25.0%)
Smokers	90 (75.0%)
Comorbidities*	
DM	82 (68.3%)
HTN	78 (65.0%)
COPD	55 (45.8%)
Asthmatic	78 (65.0%)
IHD	59 (49.2%)
HF	31 (25.8%)
CKD	58 (48.3%)
APACHE II	14.14 ± 7.9
SOFA	3.84 ± 1.4
PSI	157.9 ± 36.9
CURB 65	3.99 ± 0.15
Mechanical Ventilation	28 (23.3%)
Respiratory rate (breath/minute)	26.6 ± 4.1
Mean Arterial blood pressure	97 ± 17.5
TLC(*1000)	11.99 ± 5.69
Serum CRP	160.2 ± 34.9
Serum PCT	2.87 ± 0.34

\*One patient may have multiple comorbidities. HF: Heart failure, TLC: Total leukocyte count, DM: Diabetes mellitus, SOFA: Sequential organ failure assessment, APACHE: Acute physiology and chronic health evaluation, PCT: Procalcitonin, HTN: Hypertension, CRP: C-reactive protein, COPD: Chronic obstructive pulmonary disease, CURB: Confusion, uremia, respiratory rate and blood pressure, CKD: Chronic kidney disease, PSI: Pulmonary severity index, IHD: Ischemic heart disease.

Bourcier *et al.* study revealed a significantly higher sensitivity of LUS for the diagnosis of acute pneumonia compared to chest radiography (95% vs. 60%). Moreover, when cases were compared to CT chest LUS showed a very high 100% accuracy while CXR had a very low 52% accuracy [14].

**Table 2: Detection of pneumonia by CT chest, CXR and LUS among the studied group**

Variables	The studied group (n = 120)		On Admission	
	No.	(%)	No.	(%)
Pneumonia by CT Chest				
Positive	85	(70.8%)	78	(65%)
Negative	35	(29.2%)	42	(35%)
Pneumonia by CXR				
Positive	61	(50.8%)	61	(50.83%)
Negative	59	(49.2%)	59	(49.1%)
Pneumonia by Lung US				
Positive	81	(67.5%)	76	(63.33%)
Negative	39	(32.5%)	44	(36.66%)

LUS: Lung ultrasound.

Nazerian *et al.* concluded that LUS is a reliable method for the diagnosis of pulmonary consolidations when compared to chest CT in patients with respiratory complaints of unexplained origin. LUS had 82.8% sensitivity and 95.5% specificity [15].

**Table 3: Diagnosis of pneumonia among the studied group between CT chest as gold standard reference and LUS**

On admission	
Early positive CT	
+ve LUS	75 (62.5%)
-ve LUS	3 (2.5%)
Early negative CT	
-ve LUS	41 (34.17%)
+ve LUS	1 (0.83%)
48 h imaging to negative cases	
Turning positive after negative CT	
+ve LUS	5
-ve LUS	2
Persistent negative CT	
-ve LUS	34
+ve by LUS	1

LUS: Lung ultrasound.

**Table 4: Diagnosis of pneumonia among the studied group between CT chest as gold standard reference and CXR**

On admission	
Early positive CT	
+ve CXR	59
-ve CXR	19
Early negative CT	
-ve CXR	40
+ve CXR	2
48 h imaging to negative cases	
Turning positive after Negative CT	
+ve CXR	1
-ve CXR	6
Persistent negative CT	
-ve CXR	34
+ve CXR	1

Berlet *et al.* demonstrated that LUS is a useful tool in the diagnostic workup of critically ill patients with suspected VAP. LUS was able to detect 100% of cases with confirmed positive sputum cultures [16].

**Table 5: Comparing the ability of LUS in detection of pneumonia using CT chest as a gold standard among the studied group**

Variables	CT chest for pneumonia		Mc Nemar test	p-value
	Yes (85)	No (35)		
LUS for pneumonia				
Yes (81)	80	1	1.5	0.11
No (39)	5	34		

Kappa agreement = 0.913.

Sezgin *et al.* studied 125 patients with suspected pneumonia, 61 cases were diagnosed pneumonia according to CT chest as the gold standard. LUS was able to detect 48 out of 61 cases and one case was detected with pneumonia despite the negative CT chest. There was no follow-up imaging to confirm which modality was more accurate. LUS showed 98% sensitivity, 91% specificity, and 96.7% accuracy, while CXR showed 89.8% sensitivity, 83.3% specificity, and 88.5% accuracy [17].

**Table 6: Comparing the ability of CXR in detection of pneumonia using CT chest as a gold standard among the studied group**

Variables	CT chest for pneumonia		Mc Nemar test	p-value
	Yes (85)	No (35)		
CXR for pneumonia				
Yes (61)	59	2	18.89	<0.001
No (59)	26	33		

Kappa agreement = 0.624.

We demonstrated a case diagnosed pneumonia on admission by LUS alone while it was excluded by CT chest and CXR. The case, after 48 h of following up, turned out to be positive by CT suggesting that LUS may be more sensitive in early detection of pneumonia than CT itself.

**Table 7: Validity (AUC, sensitivity, and specificity) for Chest U/S to predict CAP**

	AUC	p	95% CI	Sensitivity	Specificity	PPV	NPV	Accuracy
Chest U/S	0.922	<0.001*	0.836–1.00	94.1%	97.1%	98.8%	87.2%	95%

AUC: Area under a curve, p value: Probability value, CI: Confidence intervals, NPV: Negative predictive value, PPV: Positive predictive value, CAP: Community-acquired pneumonia.

We recommend that LUS as a very promising, sensitive and feasible imaging tool in pneumonia diagnosis and follow-up that will make the assessment of pneumonia patients at intensive care units earlier and easier.

**Table 8: Validity (AUC, sensitivity, and specificity) for Chest X-ray to predict CAP**

	AUC	p	95% CI	Sensitivity	Specificity	PPV	NPV	Accuracy
Chest X-ray	0.608	0.190	0.448–0.768	69.4%	94.3%	96.7%	55.9%	76.6%

AUC: Area under a curve, p value: Probability value, CI: Confidence intervals, NPV: Negative predictive value, PPV: Positive predictive value, CAP: Community-acquired pneumonia.

## Conclusion

Lung US is a reliable non-invasive technique for detection of CAP cases that showed 94.1% sensitivity, 97.1% specificity, 98.8% PPV, 87.2% NPV, and 95.0% accuracy.

Chest X-ray had 69.4% sensitivity, 94.3% specificity, 96.7% PPV, 55.9% NPV, and 76.6% accuracy in detection of CAP.

Using CT chest as the gold standard imaging module, lung US was found to be a highly significant imaging tool in predicting the diagnosis of CAP ( $p < 0.001$ ), while CXR was found to be an insignificant imaging tool in predicting the diagnosis of CAP ( $p = 0.19$ ).

## References

- Ewig S, Birkner N, Strauss R, Pauletzki J, Bischoff H, Schraeder P, *et al*. New perspectives on community-acquired pneumonia in 388 406 patients. Results from a nationwide mandatory performance measurement programme in healthcare quality. *Thorax*. 2009;64(12):1062-9. <https://doi.org/10.1136/thx.2008.109785>  
PMid:19454409
- Metlay JP, Waterer GW, Long AC, Anzueto A, Brozek J, Crothers K, *et al*. Diagnosis and treatment of adults with community-acquired pneumonia. An official clinical practice guideline of the American thoracic society and infectious diseases society of America. *Am J Respir Crit Care Med*. 2019;200(7):e45-67. <https://doi.org/10.1164/rccm.201908-1581ST>  
PMid:31573350
- Brent RL. The effect of embryonic and fetal exposure to x-ray, microwaves, and ultrasound: Counseling the pregnant and nonpregnant patient about these risks. *Semin Oncol*. 1989;16(5):347-68.  
PMid:2678486
- Brenner DJ, Hall EJ. Computed tomography-an increasing source of radiation exposure. *N Engl J Med*. 2007;357(22):2277-84. <https://doi.org/10.1056/NEJMra072149>  
PMid:18046031
- Volpicelli G, Elbarbary M, Blaivas M, Lichtenstein DA, Mathis G, Kirkpatrick AW, *et al*. International evidence-based recommendations for point-of-care lung ultrasound. *Intensive Care Med*. 2012;38(4):577-91. <https://doi.org/10.1007/s00134-012-2513-4>  
PMid:22392031
- Cortellaro F, Colombo S, Coen D, Duca PG. Lung ultrasound is an accurate diagnostic tool for the diagnosis of pneumonia in the emergency department. *Emerg Med J*. 2012;29(1):19-23. <https://doi.org/10.1136/emj.2010.101584>  
PMid:21030550
- Alzahrani SA, Al-Salamah MA, Al-Madani WH, Elbarbary MA. Systematic review and meta-analysis for the use of ultrasound versus radiology in diagnosing of pneumonia. *Crit Ultrasound J*. 2017;9(1):6. <https://doi.org/10.1186/s13089-017-0059-y>  
PMid:28244009
- Lichtenstein D. FALLS-protocol: Lung ultrasound in hemodynamic assessment of shock. *Heart Lung Vessel*. 2013;5(3):142-7.  
PMid:24364005
- Patel CJ, Bhatt HB, Parikh SN, Jhaveri BN, Puranik JH. Bedside lung ultrasound in emergency protocol as a diagnostic tool in patients of acute respiratory distress presenting to emergency department. *J Emerg Trauma Shock*. 2018;11(2):125-9. [https://doi.org/10.4103/JETS.JETS\\_21\\_17](https://doi.org/10.4103/JETS.JETS_21_17)  
PMid:29937643
- Lichtenstein DA. BLUE-protocol and FALLS-protocol: Two applications of lung ultrasound in the critically ill. *Chest*. 2015;147(6):1659-70. <https://doi.org/10.1378/chest.14-1313>  
PMid:26033127
- Lichtenstein DA, Meziere GA. Relevance of lung ultrasound in the diagnosis of acute respiratory failure: The BLUE protocol. *Chest*. 2008;134(1):117-25. <https://doi.org/10.1378/chest.07-2800>  
PMid:18403664
- Reissig A, Copetti R, Mathis G, Mempel C, Schuler A, Zechner P, *et al*. Lung ultrasound in the diagnosis and follow-up of community-acquired pneumonia: A prospective, multicenter, diagnostic accuracy study. *Chest*. 2012;142(4):965-72. <https://doi.org/10.1378/chest.12-0364>  
PMid:22700780
- Nafae R, Eman SR, Mohamad NA, El-Ghamrya R, Raghebb AS. Adjuvant role of lung ultrasound in the diagnosis of pneumonia in intensive care unit-patients. *Egypt J Chest Dis Tuberc*. 2013;62(2):281-5. <https://doi.org/10.1016/j.ejcdt.2013.04.007>
- Bourcier JE, Paquet J, Seinger M, Gallard E, Redonnet JP, Cheddadi F, *et al*. Performance comparison of lung ultrasound and chest x-ray for the diagnosis of pneumonia in the ED. *Am J Emerg Med*. 2014;32(2):115-8. <https://doi.org/10.1016/j.ajem.2013.10.003>  
PMid:24184011
- Nazerian P, Volpicelli G, Vanni S, Gigli C, Betti L, Bartolucci M, *et al*. Accuracy of lung ultrasound for the diagnosis of consolidations when compared to chest computed tomography. *Am J Emerg Med*. 2015;33(5):620-5. <https://doi.org/10.1016/j.ajem.2015.01.035>  
PMid:25758182
- Berlet T, Etter R, Fehr T, Berger D, Sendi P, Merz TM. Sonographic patterns of lung consolidation in mechanically ventilated patients with and without ventilator-associated pneumonia: A prospective cohort study. *J Crit Care*. 2015;30(2):327-33. <https://doi.org/10.1016/j.jcrc.2014.11.021>  
PMid:25499414
- Sezgin C, Gunalp M, Genc S, Acar N, Ustuner E, Oguz AB, *et al*. Diagnostic value of bedside lung ultrasonography in pneumonia. *Ultrasound Med Biol*. 2020;46(5):1189-96. <https://doi.org/10.1016/j.ultrasmedbio.2020.01.014>  
PMid:32063393