



# Intrahepatic Stone in Post Liver Transplanted Patient

Fahad Al Shehri\* 

Department of Radiology, College of Medicine, Qassim University, Buraydah, Saudi Arabia

## Abstract

**Edited by:** Ksenija Bogoeva-Kostovska

**Citation:** Al Shehri F. Intrahepatic Stone

in Post Liver Transplanted Patient.

Open Access Maced J Med Sci. 2022 Nov 20; 10(C):323-326.

https://doi.org/10.3889/oamjms.2022.10999

**Keywords:** Intra biliary stones; MRCP; ERCP; Liver

transplant; Post-operative complication; CBD stones

\***Correspondence:** Fahad Al Shehri, Department of

Radiology, College of Medicine, Qassim University,

Buraydah, 52581, Saudi Arabia. E-mail: f.alshhri@

qu.edu.sa

**Received:** 24-Sep-2022

**Revised:** 25-Oct-2022

**Accepted:** 10-Nov-2022

**Copyright:** © 2022 Fahad Al Shehri

**Funding:** This research did not receive any financial

support

**Competing Interests:** The authors have declared that no

competing interests exist

**Open Access:** This is an open-access article distributed

under the terms of the Creative Commons Attribution-

NonCommercial 4.0 International License (CC BY-NC 4.0)

**BACKGROUND:** The complication of the bile duct is quite a typical case of indisposition after liver transplant from a deceased or a live donor. The morbidity rates of the patients that underwent orthotopic liver transplantation were reported. In this case report, the intrahepatic stone formation was studied in post liver transplanted patients.

**CASE REPORT:** This report presents a sporadic case of 53-year-old male patient in post-operative liver transplant. The initial post-transplant course of the patient was quite favorable, but after a week post-surgery, the patient developed the case of jaundice and came on with yellow discoloration in the skin. The endoscopic retrograde cholangiopancreatography (ERCP) was initially performed and the common bile duct (CBD) stent was inserted. Routine post-operative examination and follow-ups showed that the onset of jaundice. Further investigations with ERCP and the magnetic resonance cholangiopancreatography (MRCP) to determine the complete mapping of the biliary region showed the presence of biliary stones in the CBD. In short, this is a rare finding that presents a sporadic case of post-operative liver transplant complications of biliary stones. The patient underwent a liver transplant but came back with post-surgery complications. MRCP and ERCP techniques were used for the imaging and providing an accurate diagnosis, indicating the presence of biliary stones in the CBD.

**CONCLUSION:** Intrahepatic stone was found in patients with post liver transplanted patient.

## Introduction

The complication of the bile duct is quite a typical case of indisposition after liver transplant from a deceased or a live donor. The morbidity rates of the patients that underwent orthotopic liver transplantation were reported to be in the range of 34–50% in the 25–30% of patients who underwent a liver transplant. The organ selection improvement, reconstruction of bile, techniques if implantation, and perioperative care have reduced the incidence of biliary complication considerably [1]. The detection of the biliary stones is mostly dependent on the technological factors and post-operative care by the interpreting physician. This requires a thorough understanding of the critical radiological findings through magnetic resonance imaging (MRI) and computerized tomography (CT) diagnosis of the biliary stone disease [2].

The common bile duct stones are commonly classified according to their origin, forming three main types: (1) The primary bile duct stones that initially form in the bile ducts; (2) the secondary to gallbladder stones, that originate in the gallbladder and then pass onto the bile ducts; and (3) the rocks secondary to or coexisting with the intrahepatic bile duct. The primary bile-duct stones that are not associated with the gallbladder are also comprised predominantly of bilirubin, which is associated presumably with the infection and biliary stasis. The risk factors related to the gallstones include biological,

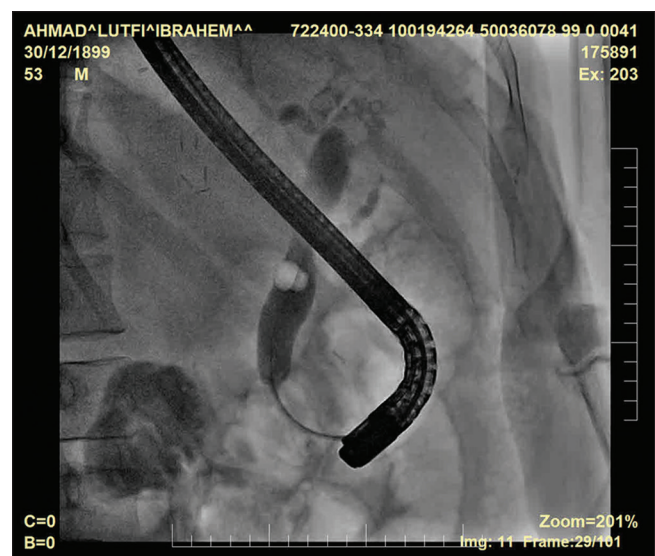

Figure 1: ERCP on May 2020

congenital, and behavioral factors. There are other essential factors for the primary common bile duct (CBD) stone formation, such as the infection and bile stasis, and based on this, an anatomical abnormality that causes the bile stasis is the significant risk factors associated with the bile infection. In addition to it all, the distention of the CBD is more commonly in association with the bile duct stones after the cholecystectomy. Furthermore, a cystic duct dilation in the aged gallbladder stone population is directly associated with the channeling of the gallbladder

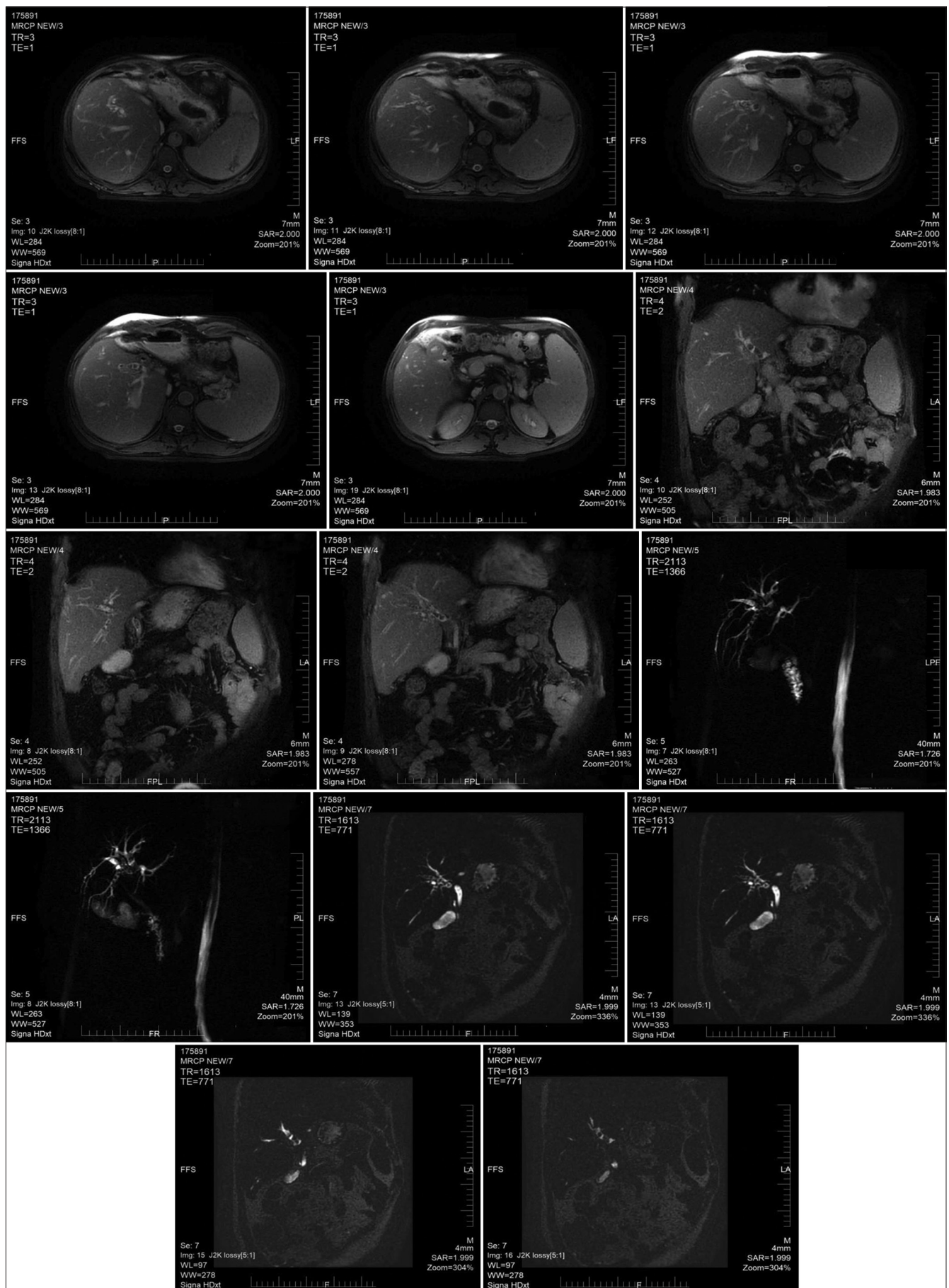


Figure 2: MRCP on June 2020

stone directly into the bile duct resulting in the formation of the secondary bile duct stones. Gallstones also carry a significant risk factor for biliary tract cancers, especially in patients who have a 60–80% of a history of gallstones in the past [3], [4].

### Case Report

The patient was a 53-year-old male in post-operative liver transplant in August 2018. The initial post-transplant course of the patient was quite favorable, but after a week post-surgery, the patient developed the case of jaundice and came on with yellow discoloration in the skin. The endoscopic retrograde cholangiopancreatography (ERCP) was done initially, and the common bile duct (CBD) stent was inserted in October 2018. The CBD stent inserted migrated, and reinsertion was done of the CBD stent.

After the stent insertion, the patient's regular laboratory investigation was routine for some time, and it was decided that the CBD stent be removed in June 2019. Routine post-operative examination and follow-ups were done, and once again, the patient developed

jaundice, ERCP was also performed and the CBD stent was again inserted in January 2020. However, a blockage was observed in the CBD stent, and the stent was decided to be removed in February 2020. ERCP was again performed on May 2020, for the complete mapping of the biliary region (Figure 1). Magnetic resonance cholangiopancreatography (MRCP) was performed on the patient in June 2020 (Figure 2).

### Discussion

After the MRCP, the findings observed were that the CBD diameter was found to be at 7.67 mm at a maximum caliber in the present study. There was a slight prominence in the common hepatic duct and presence of multiple signal voids, and some beaded appearances were observed in the right hepatic duct, raising the possibility of the occurrence of intrabiliary stones due to bile stagnation. For complete visualization of the case of the stones, a CT scan of the abdomen was recommended for the intrabiliary stones' visualization in June 2020 (Figure 3). The ERCP also showed a filling defect in the right biliary radicle, suggesting a tumor or any other form

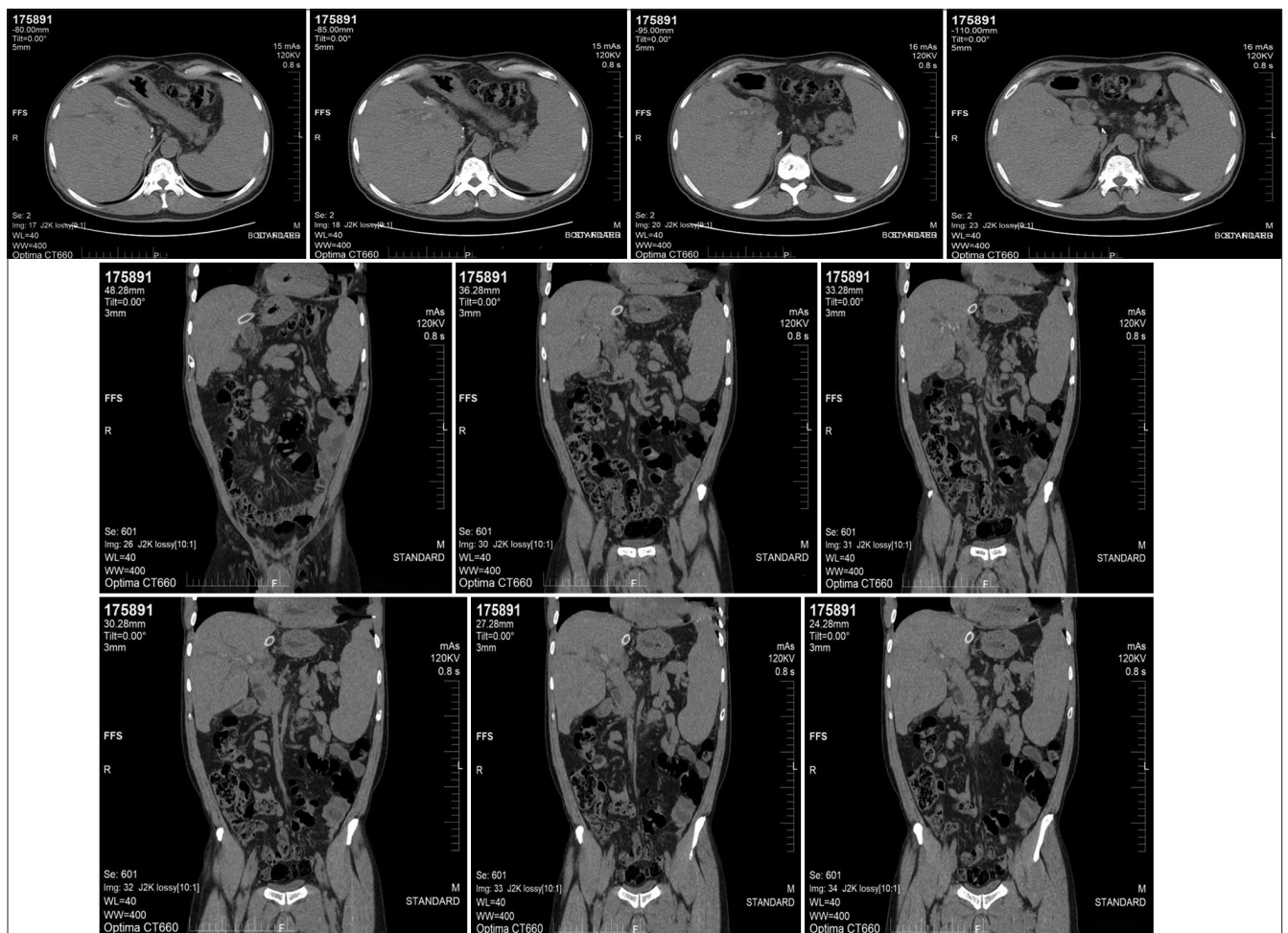


Figure 3: CT of June 2020. The stent is shown migrating in Image 17 and 18

of growth. From the CT scan, it was observed that the stent was migrating and was seen out of the biliary tree, though the most prominent visualization from the CT was the presence of multiple stones in the intrabiliary region with the CBD measuring 15 mm due to the presence of calculi. The spleen was also observed to be enlarged with it measuring 18.9 cm. There was no anomaly observed in the pancreas and both the kidneys, neither any free fluid.

The CBD and the intrahepatic stones are quite frequent in the countries of the East as opposed to the West, this is due to the genetic, ethnic, and the environmental factors. The estimated prevalence of CBD stones in the Western world is approximately 3%–16%. Even though many stones have their origin from the gallbladder, bile stasis-associated biliary stenosis (BS) can be the cause of primary duct stones. The underlying etiologies include the iatrogenic injury after complex biliary reconstructions and cholecystectomy, congenital biliary cysts, or primary sclerosing cholangitis (PSC). Only a few cases of patients having biliary duct stones remain symptomless. The challenge is the diagnosis of the indeterminate biliary stricture and the management of difficult bile stones endoscopically. The recent standard of care for the evaluation of the biliary stones is seen on MRCP, CT, or ultrasound beginning with ERCP, this technique utilizes fluoroscopy for the creation of 2D images for the localization and characterization of the bile duct pathology extent [5], [6].

The complication in the biliary region is commonly reported in 10–30% of the patients of a liver transplant. Many different cases of biliary complications such as leakage, ischemia, necrosis, hemobilia, biliary hematoma, and biliary stricture have been reported; however, even with all these complications, biliary stones are quite a rate complication for post-operative liver transplant patients. The primary biliary stones have a history of being quite tricky to being eradicated. The advances in the imaging hepatobiliary, flexible choledochoscopy, applying stone fragmentation technology, and employing innovative approaches surgically have been used to remove stones in the biliary region. The diagnosis of biliary stones is quite challenging, due to the inadequacy of the laboratory and clinical findings for predicting the CBD stones' presence, the techniques for imaging are considered the backbone for the establishment of the diagnosis. The CT and ultrasonography are readily available, but often-times do not provide complete information regarding the diagnosis, there are other options of intraductal biopsies and cytology brushings as well for the diagnostic of biliary lesions or strictures. Hence, the MRCP and ERCP techniques were employed to accurately diagnose the presence of biliary stones or any other anomaly. ERCP is one of the leading tools for the treatment of CBD stones; however, almost 10–15% of the CBD stones are unable to be removed by the traditional ERCP techniques [1], [6], [7], [8].

## Authors' Declaration Statements

### Patients consents

Written informed consent has been taken from the studied patient.

### Data availability statement

The data used to support the findings of this study are included within the article.

## References

1. Nagata S, Ikegami T, Takeishi K, Toshima T, Sugimachi K, Gion T, *et al.* Acute biliary obstruction due to a large intracholedochal hematoma after living-donor liver transplantation: Report of a case. *Surg Today.* 2010;40(5):474-6. <https://doi.org/10.1007/s00595-009-4088-4>  
PMid:20425554
2. Yeh BM, Liu PS, Soto JA, Corvera CA, Hussain HK. MR imaging and CT of the biliary tract. *Radiographics.* 2009;29(6):1669-88. <https://doi.org/10.1148/rg.296095514>  
PMid:19959515
3. Tazuma S. Epidemiology, pathogenesis, and classification of biliary stones (common bile duct and intrahepatic). *Best Pract Res Clin Gastroenterol.* 2006;20(6):1075-83. <https://doi.org/10.1016/j.bpg.2006.05.009>  
PMid:17127189
4. Hsing AW, Bai Y, Andreotti G, Rashid A, Deng J, Chen J, *et al.* Family history of gallstones and the risk of biliary tract cancer and gallstones: A population-based study in Shanghai, China. *Int J Cancer.* 2007;121(4):832-8. <https://doi.org/10.1002/ijc.22756>  
PMid:17450525
5. Cappelli A, Mosconi C, Cucchetti A, Pettinari I, Andreone A, Zanardi S, *et al.* Outcomes following percutaneous treatment of biliary stones. *HPB(Oxford).* 2019;21(8):1057-63. <https://doi.org/10.1016/j.hpb.2018.12.007>  
PMid:30738713
6. Yan S, Tejaswi S. Clinical impact of digital cholangioscopy in management of indeterminate biliary strictures and complex biliary stones: A single-center study. *Ther Adv Gastrointest Endosc.* 2019;12:2631774519853160. <https://doi.org/10.1177/2631774519853160>  
PMid:31218297
7. Kubota Y, Takaoka M, Yamamoto S, Shibatani N, Shimatani M, Takamido S, *et al.* Diagnosis of common bile duct calculi with intraductal ultrasonography during endoscopic biliary cannulation. *J Gastroenterol Hepatol.* 2002;17(6):708-12. <https://doi.org/10.1046/j.1440-1746.2002.02753.x>  
PMid:12100618
8. Jin Z, Wei Y, Tang X, Shen S, Yang J, Jin H, *et al.* Single-operator peroral cholangioscope in treating difficult biliary stones: A systematic review and meta-analysis. *Dig Endosc.* 2019;31(3):256-69. <https://doi.org/10.1111/den.13307>  
PMid:30468534