



Serum Concentrations of Some T_{helper} 1-Derived Cytokines in Generalized Erythema Multiforme

Tran Thi Huyen^{1,2*}, Pham Thi Minh Phuong², Le Huu Doanh^{1,2}, Pham Thi Lan^{1,2}, Nguyen Thi Ha Vinh^{1,2}

¹Department of Dermatology and Venereology, Hanoi Medical University, Hanoi, Vietnam; ²Department of Outpatient, National Hospital of Dermatology and Venereology, Hanoi, Vietnam

Abstract

Edited by: Ksenija Bogoeva-Kostovska
Citation: Huyen TT, Phuong PTM, Doanh LH, Lan PT, Vinh NTH. Serum Concentrations of Some T_{helper} 1-Derived Cytokines in Generalized Erythema Multiforme. Open Access Maced J Med Sci. 2023 Jun 10; 11(B):665-670. https://doi.org/10.3889/oamjms.2023.11706
Keywords: Erythema multiforme; Herpes simplex virus; Interferon-gamma; Interleukin-2; Tumor necrosis factor; *Mycoplasma pneumoniae*
***Correspondence:** Dr. Tran Thi Huyen, Hanoi Medical University, Hanoi, Vietnam, 1A Ton That Tung Street, Dong Da, Hanoi, Vietnam. E-mail: drhuyentran@gmail.com
Received: 16-May-2023
Revised: 23-May-2023
Accepted: 29-May-2023
Copyright: © 2023 Tran Thi Huyen, Pham Thi Minh Phuong, Le Huu Doanh, Pham Thi Lan, Nguyen Thi Ha Vinh
Funding: This research did not receive any financial support
Competing Interests: The authors have declared that no competing interests exist
Open Access: This is an open-access article distributed under the terms of the Creative Commons Attribution-NonCommercial 4.0 International License (CC BY-NC 4.0)

BACKGROUND: Erythema multiforme (EM) is an acute mucocutaneous syndrome characterized by typical and/or atypical target lesions on the skin. The etiology is still not clear, but EM may be related to infection or medication. Clinically, there are cases of EM with atypical target lesions with generalized distribution without, or with minimal, mucosal lesions. The causes remain unknown. However, T helper cells 1 (Th1) may play an important role in EM.

AIMS: The aim of the study was to investigate serum concentrations of some Th1-derived cytokines in generalized EM or generalized EM-like eruptions.

METHODS: This was a sectional and descriptive study conducted at the National Hospital of Dermatology and Venereology, in Hanoi, Vietnam, from April 2017 to August 2019. There were 33 EM patients, and 32 healthy controls (HCs) participated. Serum interleukin (IL)-2, interferon-gamma (IFN- γ), and tumor necrosis factor-alpha (TNF- α) levels were measured using the fluorescence covalent microbead immunosorbent assay (ProcartaPlex Immunoassay Panels kit, Thermo Fisher Scientific, USA). The Mann-Whitney U-test was used to compare the serum IL levels of the two groups. Differences were considered to be statistically significant at $p < 0.05$.

RESULTS: The mean age of the EM patients was 42.2 ± 17.5 years, ranging from 19 to 76 years old. Men accounted for 30.3%, women accounted for 69.7%. There were 22 patients with <1 week of onset, accounting for 66.7%; 11 patients with 1 week and those with more than 1 week accounted for 33.3%. There were 60.6% of patients using drugs before the onset. Most patients had pruritus (97%), and all had diffusely distributed skin lesions. Only 15.2% of the patients had mucosal lesions. There are 30.3% of patients with fever. The serum IFN- γ concentration of the EM group was 5.35 ± 9.88 pg/mL, higher than that of the HCs group (0.35 ± 0.77 pg/mL), the difference was statistically significant with $p = 0.01$ (Mann-Whitney U). The concentrations of IL-2 and TNF- α of the HCs were 24.32 ± 27.94 pg/mL and 109.74 ± 126.73 pg/mL, respectively, higher than those of the EM group (3.37 ± 5.94 pg/mL and 5.86 ± 11.88 pg/mL, respectively). The difference was statistically significant with $p < 0.001$. Age did not correlate with serum concentrations of cytokines in the EM group.

CONCLUSION: In generalized EM, serum concentrations of IFN- γ are statistically significantly higher than those of HCs but serum concentrations of IL-2 and TNF- α were lower. There is no correlation between age and serum concentrations of cytokines in generalized erythema multiforme.

Introduction

Erythema multiforme (EM) is an acute mucocutaneous eruption first described by von Hebra in 1860 as erythema exudativum multiforme [1]. It is characterized by typical and/or atypical target lesions on the skin. Mucosal sites such as the mouth, eyes, nose, and genital region may also be affected. The etiology is still not fully understood, but EM may be related to infectious conditions or medications. Among infections, herpes simplex virus (HSV) is considered the most common agent, and the term "HSV-related EM" is used [2], [3], [4]. In HSV-related EM, the disease can be divided into EM minus (typical targets, acral skin, and lip involvement, and no mucosal erosions) and EM majus (typical targets, acral skin involvement, and mucosal erosions) [1], [4]. In addition, there are cases of atypical EM majus (giant targets, central

distribution, and prominent mucosal erosions). In mucosal EM majus, there are no or minimal skin lesions, but prominent mucosal erosions, the cause may be *Mycoplasma pneumoniae* [5], [6], [7]. In drug-induced EM, the skin lesions usually distribute generalized with atypical target lesions [1]; however, in some cases, mucocutaneous lesions are limited [8], [9].

The underlying mechanisms of EM associated with HSV have been thoroughly investigated [1]. However, whether these same mechanisms apply to EM caused by other factors is uncertain. While complete, infectious HSV has never been isolated from lesions of HSV-associated EM; numerous studies using PCR assays have reported the presence of HSV-DNA fragments in skin lesions [3]. These DNA fragments, including the viral polymerase (Pol) gene, are found in basal keratinocytes and lower spinous cell layers, where they are responsible for synthesizing which viral Pol protein. HSV-specific T cells, including cytotoxic

cells, are recruited to the site of infection, followed by a non-specific inflammatory response from autoreactive T cells. The cytokines produced in these cells result in a delayed hypersensitivity-like appearance in the histopathologic evaluation of biopsy sections of EM lesions [1].

It has been proposed that autoreactive T cells are triggered by viral antigen-positive cells containing the HSV-DNA polymerase gene [10], [11]. These cells generate and transport HSV-DNA fragments through peripheral blood mononuclear cells, mainly macrophages, and CD341 Langerhans cell precursors, presumably through the vascular route. Inflammatory responses are initiated by viral gene expression in the skin, which leads to the recruitment of HSV-specific CD41 Th1 cells. Interferon-gamma (IFN- γ) generated by this response upregulates cytokines and chemokines that amplify cutaneous inflammatory events, both by increasing sequestration of circulating leukocytes, monocytes, and natural killer cells and by recruiting autoreactive T cells to the epidermis [10], [11].

Clinically, there are cases of EM with atypical target lesions with generalized distribution without, or with minimal, mucosal lesions, the causes remain unknown. The question is if they have the same mechanism through Th1 as mentioned above. Therefore, this study was conducted to investigate serum concentrations of some Th1-derived cytokines in generalized EM or generalized EM-like eruptions.

Methods

Study design and ethical clearance

This cross-sectional and descriptive study was approved by the Ethical Review Committee on Research Involving Human Subjects, Hanoi Medical University (Number 04NCS17, dated February 8, 2018). Written consent was obtained from all participants. It was conducted at the National Hospital of Dermatology and Venereology, in Hanoi, Vietnam, from April 2017 to August 2019.

Patients

In total, 33 patients with generalized EM were enrolled. Diagnostic criteria for EM: Having atypical and/or typical target lesions on the skin with or without mucosal lesions. According to the current classification, typical target lesions consist of at least three concentric components: (1) a dusky central disk or blister; (2) more peripherally, an infiltrated pale ring; and (3) an erythematous halo. Not all lesions of EM are typical; some display two rings only (raised atypical targets). In some patients with EM, most lesions are violaceous vesicles

overlying a just slightly darker central portion, encircled by an erythematous margin. Larger lesions may have a central bulla and a marginal ring of vesicles [1], [4]. The skin lesions distribution generalized, not only on the acral sites. The patients had their vital signs, systemic symptoms, mucosal lesions, and the number of target lesions on the skin examined. Inclusion criteria were age more than 17 years old, generalized target lesions on the skin with or without mucosal lesions, the causes were infectious, drug-induced, or unknown. Exclusion criteria were human immunodeficiency virus positivity and cases of multi-organ failure and sepsis. In addition, 32 healthy controls (HCs) participated in this study as control groups.

Analysis cytokines

For both generalized EM patients and HCs, the blood was taken at 1 point (before the treatment of EM). All blood samples were left to coagulate at room temperature for 10–20 min, then centrifuged for 20 min at a speed of 2000–3000 r.p.m. Finally, serum was taken and stored at -80°C until proceeding with the cytokine measurement. We measured serum IFN- γ , interleukin (IL)-2, and tumor necrosis factor-alpha (TNF- α) levels using the fluorescence covalent microbead immunosorbent assay (ProcartaPlex Immunoassay Panels kit, Thermo Fisher Scientific, USA).

Statistical analysis

Data entry and analysis were conducted using SPSS software version 20.0 (IBM, Armonk, NY, USA). The Mann–Whitney U-test was used to compare the two groups' serum levels of IFN- γ , IL-2, and TNF- α . Differences were considered to be statistically significant at $p < 0.05$.

Results

There were 33 patients with diffuse EM participating in the study. The mean age of the patients was 42.2 ± 17.5 years, ranging from 19 to 76 years old. Men accounted for 30.3%, women accounted for 69.7%. There were 22 patients with <1 week of onset, accounting for 66.7%; 11 patients with 1 or more than 1 week, accounting for 33.3%. There were 60.6% of patients using drugs before onset. Most patients had pruritus (97%), and all had diffusely distributed skin lesions. Only 15.2% of the patients had mucosal lesions. There are 30.3% of patients with fever. The majority of patients had more than 50 skin lesions (typical/atypical targets, papules). About 54.5% of patients have increased white blood cell count (Table 1).

Table 1: Characteristics of participants (n = 33)

| Characteristic | Result | % |
|---|-------------|--------|
| Age, year | | |
| Mean ± SD | 42.2 ± 17.5 | |
| Range | 19–76 | |
| Gender, n (%) | | |
| Female | 23 | (69.7) |
| Male | 10 | (30.3) |
| Time of onset, n (%) | | |
| <1 week | 22 | (66.7) |
| >1 week | 11 | (33.3) |
| Using medicines before the onset, n (%) | | |
| Yes | 20 | (60.6) |
| No | 13 | (39.4) |
| Itching, n (%) | | |
| Yes | 32 | (97) |
| No | 1 | (3) |
| Distributing skin lesions, n (%) | | |
| Generalized | 33 | (100) |
| Mucosal lesions, n (%) | | |
| Yes | 5 | (15.2) |
| No | 28 | (84.8) |
| Fever, n (%) | | |
| Yes | 10 | (30.3) |
| No | 23 | (69.7) |
| Number of target lesions, n (%) | | |
| 20-50 | 3 | (9.1) |
| >50 | 30 | (90.9) |
| Elevated white blood cell counts, n (%) | | |
| Yes | 18 | (54.5) |
| No | 15 | (45.5) |

The serum IFN-γ concentration of the EM group was 5.35 ± 9.88 pg/mL, higher than that of the HCs group (0.35 ± 0.77 pg/mL), the difference was statistically significant with p = 0.01 (Mann–Whitney U-test). The concentrations of IL-2 and TNF-α of the HCs group were 24.32 ± 27.94 pg/mL and 109.74 ± 126.73 pg/mL, respectively, higher than those of the EM group (3.37 ± 5.94 pg/mL and 5.86 ± 11.88 pg/mL, respectively), the difference was statistically significant with p < 0.001 (Table 2).

Table 2: Serum concentrations of IFN-γ, IL-2, and TNF-α in the EM and HCs groups

| Cytokine (pg/mL) | EM group | HCs group | p-value* |
|------------------|--------------|-----------------|----------|
| IFN-γ | | | 0.01 |
| Mean ± SD | 5.35 ± 9.88 | 0.35 ± 0.77 | |
| Range | 0.07–39.29 | 0.07–2.97 | |
| Median | 0.07 | 0.07 | |
| IL-2 | | | 0.000 |
| Mean ± SD | 3.37 ± 5.94 | 24.32 ± 27.94 | |
| Range | 2.34–36.46 | 2.34–79.63 | |
| Median | 2.34 | 3.51 | |
| TNF-α | | | 0.000 |
| Mean ± SD | 5.86 ± 11.88 | 109.74 ± 126.73 | |
| Range | 1.26–50.74 | 1.26–446.45 | |
| Median | 1.26 | 56.6 | |

*Mann–Whitney U-test.

In the EM group, serum cytokine levels did not differ by sex and by disease duration (Tables 3 and 4) and were not correlated with age (Figures 2-4). The

Table 3: Serum levels of IFN-γ, IL-2, and TNF-α in female and male patients

| Cytokine (pg/mL) | Female (n = 23) | Male (n = 10) | p-value* |
|------------------|-----------------|---------------|----------|
| IFN-γ | | | >0.05 |
| Mean ± SD | 5.13 ± 10.43 | 5.86 ± 9 | |
| Range | 0.07–39.29 | 0.07–20.85 | |
| Median | 0.07 | 0.07 | |
| IL-2 | | | >0.05 |
| Mean ± SD | 3.82 ± 7.11 | 2.34 ± 0 | |
| Range | 2.34–36.46 | 2.34–2.34 | |
| Median | 2.34 | 2.34 | |
| TNF-α | | | >0.05 |
| Mean ± SD | 6.51 ± 12.84 | 4.35 ± 9.78 | |
| Range | 1.26–50.74 | 1.26–32.2 | |
| Median | 1.26 | 1.26 | |

*Mann–Whitney U-test.

Table 4: Serum levels of IFN-γ, IL-2, and TNF-α according to time of onset

| Cytokine (pg/mL) | <1 week (n = 22) | ≥1 week (n = 11) | p-value* |
|------------------|------------------|------------------|----------|
| IFN-γ | | | >0.05 |
| Mean ± SD | 7.13 ± 11.48 | 1.79 ± 3.85 | |
| Range | 0.07–39.29 | 0.07–10.32 | |
| Median | 0.07 | 0.07 | |
| IL-2 | | | >0.05 |
| Mean ± SD | 3.89 ± 7.27 | 2.34 ± 0 | |
| Range | 2.34–36.46 | 2.34–2.34 | |
| Median | 2.34 | 2.34 | |
| TNF-α | | | >0.05 |
| Mean ± SD | 8.16 ± 14.09 | 1.26 ± 0 | |
| Range | 1.26–50.74 | 1.26–1.26 | |
| Median | 1.26 | 1.26 | |

*Mann–Whitney U-test.

serum concentrations of IFN-γ, IL-2, and TNF-α in female patients were 5.13 ± 10.43 pg/mL; 3.82 ± 7.11 pg/mL; and 6.51 ± 12.84 pg/mL, respectively. The serum concentrations of IFN-γ, IL-2, and TNF-α in male patients were 5.86 ± 9 pg/mL; 2, 34 pg/mL, and 4.35 ± 9.78 pg/mL, respectively. The serum concentrations of IFN-γ, IL-2, and TNF-α in patients with an onset of <1 week were 7.13 ± 11.48 pg/mL; 3.89 ± 7.27 pg/mL, and 8.16 ± 14.09 pg/mL, respectively, not statistically significantly different from those of patients with an onset of 1 week or more.

Discussion

In this study, there were 33 EM patients with diffuse skin lesions, distributed in the trunk, arms, and legs, with a large number of lesions (typical/atypical target images) (Figure 1). The time from the onset of the disease to the time the lesion spread was quite fast, with 66.7% of patients with less than a week. Among these patients, 60.6% had a history of using medication before the onset of the disease, notably allopurinol, antibiotics, and traditional medicine. There were 39.4% of patients with no history of using medication or infectious conditions. All patients in the study had no documented HSV infection before disease onset. Most patients presented with pruritus at the skin lesion. Mucosal lesions are characteristic of severe EM, however, in this study, despite extensive skin lesions, only a small percentage of patients had mucosal lesions, mainly oral mucosa with 15.2%.

Classically, cases of EM having diffuse skin lesions are often drug-induced [1], but many patients have no history of prior use of medication or clinical signs of infections (HSV, *M. pneumoniae*). In general, the etiology of EM is still not fully understood [1]. There have been several recent reports of EM or diffuse EM-like reactions following COVID-19 vaccination [10], [11], [12], [13], [14], [15], [16]. Moreover, the disease may be idiopathic, and of unknown etiology [1].

Caproni et al. showed that skin biopsies of Stevens-Johnson syndrome (SJS)/toxic epidermal necrolysis (TEN) expressed all cytokines, TNF-α,

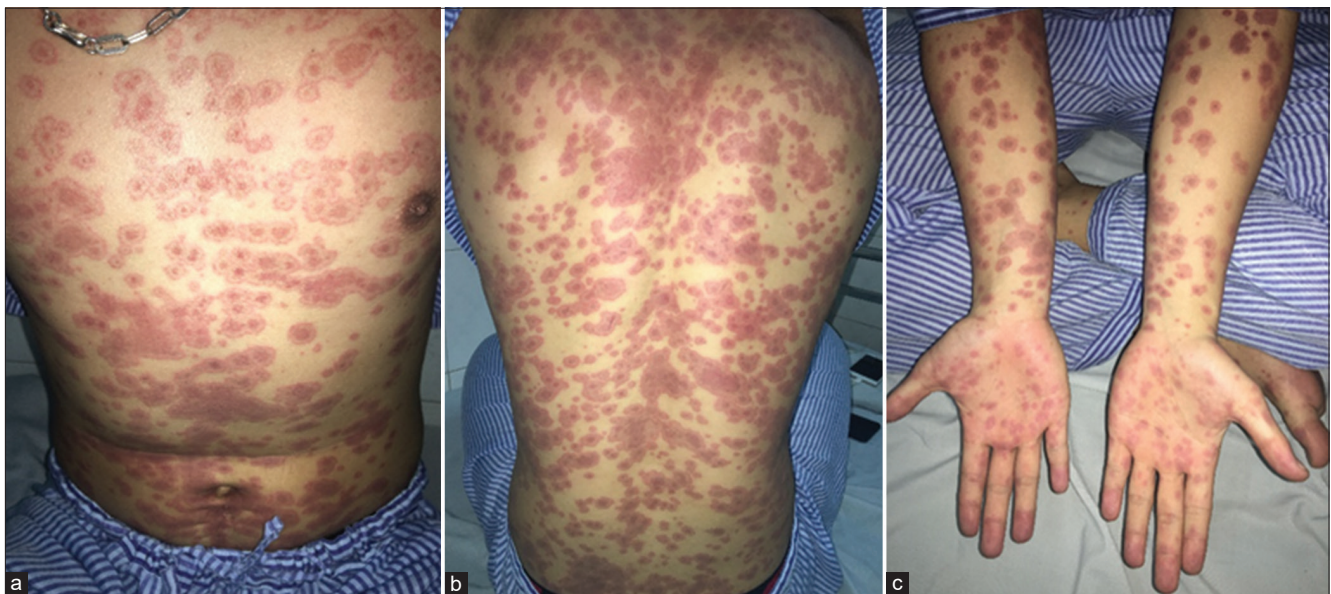


Figure 1: (a-c) A male patient with generalized EM had a lot of typical or atypical target lesions on the skin without mucosal lesions. He participated in this study

IFN- γ , IL-2, IL-5, IL-13, CCR3 (C-C chemokine receptor type 3), CXCR3 (C-X-C motif chemokine receptor 3), and CXCR4, stronger than EM skin samples. All skin samples of SJS/TEN and EM expressed cytokines than healthy human skin samples. Comparison of Th1- or Th2-derived cytokines showed a dominant Th1 response in EM, the imbalance between Th1 and Th2 was not significant in SJS/TEN. TNF- α was strongly expressed in skin lesions of SJS/TEN, which may be related to epidermal necrosis. IFN- γ plays an important role in both EM and SJS/TEN [17].

In our study, IFN- γ serum levels were higher in the EM group than in the HCs group. This is consistent with the pathogenesis of EM disease, in which the Th1-mediated response plays a key role, releasing a

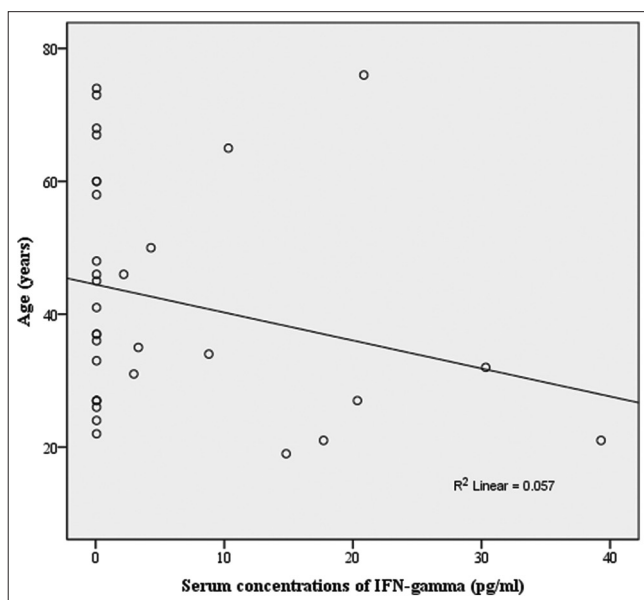


Figure 2: The correlation between serum concentration of IFN- γ and the age. ($r = -0,238$; $p > 0.05$)

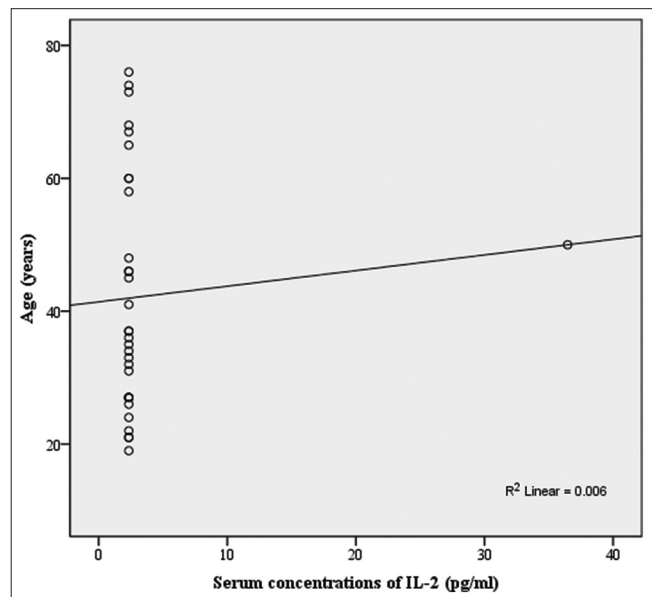


Figure 3: The correlation between serum concentration of IL-2 and the age ($r = 0,08$; $p > 0.05$)

lot of IFN- γ . Its turn, IFN- γ upregulates cytokines and chemokines. They amplify cutaneous inflammatory events by increasing circulating leukocytes, monocytes, and natural killer cells and recruiting of autoreactive T-cells to the epidermis. Th1 cells produce IFN- γ under stimulation of IL-12, and IL-18 [18]. Natural killer cells produce IFN- γ under the influence of cytokines released by macrophages, including IFN- γ , IL-12, and IL-18. IFN- γ has antiviral activity but is less potent than Class 1 of IFNs (IFN- α). The main physiological role of IFN- γ is to regulate immune responses, helping to biosynthesize many proteins that are essential in the presentation of antigens to T cells, including glycoproteins of both human leukocyte antigen Class I and class II. These changes increase antigen presentation to TCD4+ and TCD8+ cells. IFN- γ is also

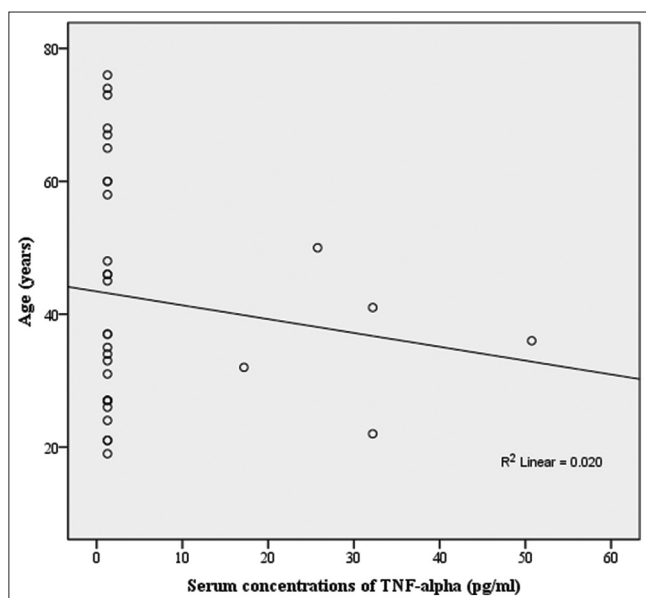


Figure 4: The correlation between serum concentration of TNF- α and the age ($r = -0,141$; $p > 0.05$)

required for macrophages to complete their resistance ability to microorganisms [19].

In this study, serum levels of IL-2 and TNF- α were higher in the HCs group than in the EM group. IL-2 is produced mainly by Th1 cells; it is a growth factor for Th1 and stimulates Th2 proliferation. Increased IL-2 levels indicated increased Th1 cell activity. Typically, the immunopathology of allergic diseases involves Th2 and its cytokines. However, in chronic allergic diseases (such as asthma, atopic dermatitis, and allergic contact dermatitis), the Th cell response is quite complex, involving the active interaction of both Th1 and Th2 cells. IL-2 is a potent cytokine that attracts eosinophils and stimulates T cells to increase IL-5 production but inhibits memory CD8 + cells. Meanwhile, IL-15 helps this cell clon to proliferate and differentiate [19]. Akkurt *et al.* study (2014) showed the hat serum IL-2 concentration of the EM group (32 patients) was 13.65 pg/mL, higher than that of the HCs group [20]. This result is different from our study.

TNF- α is a potent pro-inflammatory cytokine that plays a role in many infectious and non-infectious diseases. A lot of cells secrete this cytokine, including immune cells (macrophages, mast cells, and T cells) and non-immune cells (epithelial and airway smooth muscle cells, keratinocytes) [21]. Initially, TNF- α was considered to have two biological effects: Hemorrhagic necrosis of malignancies and anti-inflammation. In addition, it is an important mediator of inflammatory skin conditions, with almost all inflammatory dermatosis producing TNF- α , even when the skin is exposed to ultraviolet light. When stimulated by TNF- α , Langerhans cells migrate to the lymph nodes, sensitizing naive T cells [19]. In contrast to viral-associated EM, drug-induced EM is associated with TNF- α , perforin, and granzyme B, which cause the epidermal necrolysis seen in the disease with the involvement of CD8+ T cell attacks [10], [11].

Conclusion

In generalized EM, serum concentrations of IFN- γ are statistically significantly higher than those of HCs but serum concentrations of IL-2 and TNF- α were lower. There is no correlation between these ages and serum concentrations of these cytokines in generalized EM. Th1-derived cytokines may have a role in the physiopathology of generalized E, particularly IFN- γ .

References

1. Roujeau JC, Mockenhaupt M. Fitzpatrick's Dermatology. 9th ed. New York: McGraw Hill Education; 2019. p. 159-92.
2. Brice SL, Krzemien D, Weston WL, Huff JC. Detection of herpes simplex virus DNA in cutaneous lesions of erythema multiforme. *J Invest Dermatol.* 1989;93(1):183-7. <https://doi.org/10.1111/1523-1747.ep12277397>
PMid:2545789
3. Ng PP, Sun YJ, Tan HH, Tan SH. Detection of herpes simplex virus genomic DNA in various subsets of Erythema multiforme by polymerase chain reaction. *Dermatology.* 2003;207(4):349-53. <https://doi.org/10.1159/000074112>
PMid:14657624
4. Bastuji-Garin S, Rzany B, Stern RS, Shear NH, Naldi L, Roujeau JC. Clinical classification of cases of toxic epidermal necrolysis, Stevens-Johnson syndrome, and erythema multiforme. *Arch Dermatol.* 1993;129(1):92-6.
PMid:8420497
5. Canavan TN, Mathes EF, Frieden I, Shinkai K. *Mycoplasma pneumoniae*-induced rash and mucositis as a syndrome distinct from Stevens-Johnson syndrome and erythema multiforme: A systematic review. *J Am Acad Dermatol.* 2015;72(2):239-45. <https://doi.org/10.1016/j.jaad.2014.06.026>
PMid:25592340
6. Sauteur PM, Goetschel P, Lautenschlager S. *Mycoplasma pneumoniae* and mucositis--part of the Stevens-Johnson syndrome spectrum. *J Dtsch Dermatol Ges.* 2012;10(10):740-6. <https://doi.org/10.1111/j.1610-0387.2012.07951.x>
PMid:22672205
7. Prindaville B, Newell BD, Nopper AJ, Horii KA. *Mycoplasma pneumoniae*--associated mucocutaneous disease in children: Dilemmas in classification. *Pediatr Dermatol.* 2014;31(6):670-5. <https://doi.org/10.1111/pde.12482>
PMid:25424207
8. Patel R, Mohan A, Omar N, Pardi M. Drug-induced erythema multiforme major in an elderly female. *J Community Hosp Intern Med Perspect.* 2022;12(3):71-4. <https://doi.org/10.55729/2000-9666.1057>
PMid:35711389
9. Shah SN, Chauhan GR, Manjunatha BS, Dagrus K. Drug induced erythema multiforme: Two case series with review of literature. *J Clin Diagn Res.* 2014;8(9):ZH01-4. <https://doi.org/10.7860/JCDR/2014/10173.4761>
PMid:25386550
10. Samim F, Auluck A, Zed C, Williams PM. Erythema multiforme: A review of epidemiology, pathogenesis, clinical features, and treatment. *Dent Clin North Am.* 2013;57(4):583-96. <https://doi.org/10.1016/j.cden.2013.07.001>

- PMid:24034067
11. Aurelian L, Ono F, Burnett J. Herpes simplex virus (HSV)-associated erythema multiforme (HAEM): A viral disease with an autoimmune component. *Dermatol Online J.* 2003;9(1):1. PMid:12639459
 12. Kim MJ, Kim JW, Kim MS, Choi SY, Na JI. Generalized erythema multiforme-like skin rash following the first dose of COVID-19 vaccine (Pfizer-BioNTech). *J Eur Acad Dermatol Venereol.* 2022;36(2):e98-100. <https://doi.org/10.1111/jdv.17757> PMid:34661942
 13. Batta S, Miller AC, Adjei S, Temiz LA, Tying SK. Erythema multiforme after third COVID-19 vaccination (Pfizer-BioNTech). *Proc (Bayl Univ Med Cent).* 2022;35(6):811-2. <https://doi.org/10.1080/08998280.2022.2097572> PMid:36304618
 14. Katayama S, Ota M. Erythema multiforme after BNT162b2 vaccination. *Intern Med.* 2022;61(12):1929. <https://doi.org/10.2169/internalmedicine.9544-22> PMid:35431308
 15. Kothari RS, Subramani D, Asnani DR, Raman A, Deora MS, Gupta A. Erythema multiforme after Covishield/ChAdOx1 vaccination. *Dermatol Ther.* 2022;35(3):e15289. <https://doi.org/10.1111/dth.15289> PMid:34962029
 16. Lopes NT, Pinilla CE, Gerbase AC. Erythema multiforme after CoronaVac vaccination. *J Eur Acad Dermatol Venereol.* 2021;35(11):e717-9. <https://doi.org/10.1111/jdv.17495> PMid:34236724
 17. Caproni M, Torchia D, Schincaglia E, Volpi W, Frezzolini A, Schena D, *et al.* Expression of cytokines and chemokine receptors in the cutaneous lesions of erythema multiforme and Stevens-Johnson syndrome/toxic epidermal necrolysis. *Br J Dermatol.* 2006;155(4):722-8. <https://doi.org/10.1111/j.1365-2133.2006.07398.x> PMid:16965421
 18. Nassif A, Moslehi H, Le Gouvello S, Bagot M, Lyonnet L, Michel L, *et al.* Evaluation of the potential role of cytokines in toxic epidermal necrolysis. *J Invest Dermatol.* 2004;123(5):850-5. <https://doi.org/10.1111/j.0022-202X.2004.23439.x> PMid:15482470
 19. Ho AW, Kupper TS. *Fitzpatrick's Dermatology. Soluble Mediators of the Cutaneous Immune System.* 9th ed., Vol. 1. United States: McGraw Hill Education; 2019.
 20. Akkurt ZM, Uçmak D, Türkcü G, Yüksel H, Yıldız K, Arıca M. Expression of interleukin-17 in lesions of erythema multiforme may indicate a role for T helper 17 cells. *Cent Eur J Immunol.* 2014;39(3):370-6. <https://doi.org/10.5114/cej.2014.45950> PMid:26155150
 21. Schulte W, Bernhagen J, Bucala R. Cytokines in sepsis: Potent immunoregulators and potential therapeutic targets--an updated view. *Mediators Inflamm.* 2013;2013:165974. <https://doi.org/10.1155/2013/165974> PMid:23853427