



Clinical Importance of Evaluating the Results of Excised Perianal Lesions

Sümeýra Emine Bölük^{1*}, Salih Bölük², Mahmut Salih Genç¹, Berkay Özcan¹, Merve Karadağ¹, Ugur Kesici³

¹University of Health Sciences, Sultan Abdülhamid Han Training and Research Hospital, Istanbul, Türkiye; ²Gebze Medical Park Hospital, Gebze, Türkiye; ³Okmeydanı Training and Research Hospital, Istanbul, Türkiye

Abstract

Edited by: Ksenija Bogoeva-Kostovska
Citation: Bölük SE, Bölük S, Genç MS, Özcan B, Karadağ M, Kesici U. Clinical Importance of Evaluating the Results of Excised Perianal Lesions. Open Access Maced J Med Sci. 2024 Mar 20; 12(2):Ahead of Print <https://doi.org/10.3889/oamjms.2024.11874>
Keywords: Condyloma; Fibroepithelial polyps; Perianal lesions
***Correspondence:** Sümeýra Emine Bölük, University of Health Sciences, Sultan Abdülhamid Han Training and Research Hospital, Istanbul, Türkiye.
E-mail: smyra_3@hotmail.com
Received: 08-Feb-2024
Revised: 24-Feb-2024
Accepted: 10-Mar-2024
Ahead of Print: 20-Mar-2024
Copyright: © 2024 Sümeýra Emine Bölük, Salih Bölük, Mahmut Salih Genç, Berkay Özcan, Merve Karadağ, Ugur Kesici
Funding: This research did not receive any financial support
Competing Interests: The authors have declared that no competing interests exist
Open Access: This is an open-access article distributed under the terms of the Creative Commons Attribution-NonCommercial 4.0 International License (CC BY-NC 4.0)

BACKGROUND: Perianal and anal region lesions are mostly benign, typically polypoid formations seen adjacent and distal to the anal canal. Fibroepithelial anal polyps are benign lesions commonly found in the perianal region, composed of squamous epithelium and subepithelial connective tissue. Despite their benign nature, excision may be necessary in cases where they cause pain, progressively increase in size, or give rise to suspicion of an infectious or malignant disease, as well as during treatment for accompanying perianal conditions. Follow-up of the pathology results for all removed lesions is important, as the patient's follow-up and treatment process may vary based on the pathology results. Based on this perspective, patients who underwent excision of perianal lesions during surgery for a preliminary diagnosis of benign anorectal diseases were retrospectively evaluated in our clinic. The importance of the excision and pathological examination of these lesions was discussed based on the results.

AIM: The study retrospectively evaluated patients who underwent surgery for anal fistula, anal fissure, or palpable lesions in the anal or perianal area and had accompanying lesions that were pre-diagnosed as sentinel tags excised.

MATERIALS AND METHODS: The patients who underwent surgery due to anal, perianal lesions, anal fistula, or anal fissures in the general surgery clinic were retrospectively evaluated between January 2017 and February 2022. Their medical history, surgical notes, and pathology results were reviewed. Patients who underwent excision of lesions from the perianal and anal regions were evaluated. The age, gender, pathology results, pre-operative diagnoses, number and size of polyps, and the presence of concomitant hemorrhoids, anal fissures, and fistulas were recorded. The Number Cruncher Statistical System (NCSS) 2020 Statistical Software (NCSS LLC, Kaysville, Utah, USA) program was used for statistical analysis for the evaluation of the findings obtained in the study.

RESULTS: A total of 49 patients were evaluated. Three patients were excluded from the study as their pathology results were not recorded, even though a lesion excision was mentioned in their surgical notes. One patient who underwent surgery for an incisional biopsy was also evaluated separately. Of the patients, 20 were female and 25 were male. The average age of the patients was 41 (ranging from 21 to 86 years old). The average diameter of the excised polypoid lesions was 1.29 cm. When the final pathology results of the cases were reviewed, it was found that 37.8% (n = 17) had anal condyloma, 35.6% (n = 16) had fibroepithelial polyp, 8.9% (n = 4) had pyogenic granuloma, 4.4% (n = 2) had hemorrhoid, 4.4% (n = 2) had inflammatory polyp, 2.2% (n = 1) had multiple squamous papilloma, 2.2% (n = 1) had basal cell carcinoma, 2.2% (n = 1) had hypertrophic anal papilla, and 2.2% (n = 1) had pilonidal sinus. One notable result was that, despite the pre-operative diagnosis not being malignant, one patient had a pathology result of basal cell carcinoma. In addition, it is important to note that low-grade dysplasia was also detected in a patient with anal condyloma.

CONCLUSION: While perianal and anal lesions are generally benign, it is noteworthy that malignant cases can still occur, although rarely. Therefore, it is important to subject every excised perianal and anal lesion to pathological evaluation, as it is crucial for the proper follow-up and treatment of patients.

Introduction

Perianal and anal lesions, mostly in the form of polypoid structures, are predominantly benign. Fibroepithelial polyps (FEPs) are the most commonly observed lesions in this area. They are also referred to as hypertrophic anal papillae or skin tags and originate from the squamous epithelium and subepithelial connective tissue. They mostly develop as a reaction to infection, inflammation, and irritation [1], [2]. There is no significant difference in the incidence of FEPs between men and women [3]. Hemorrhoids and anal fissures create a pre-disposition for FEP formation and are also benign lesions.

These conditions can cause symptoms such as burning, stinging, and itching. Polypoid structures in the perianal area usually present with palpable masses, whereas lesions in the anal canal can sometimes be detected only through straining or by causing discomfort in the anal region. In the literature, cases of anal canal polyps causing mechanical obstruction have also been reported [4]. Particularly, if polyps related to the anal canal are detected during a physical examination, it is appropriate to evaluate the colon for additional pathologies through endoscopic examination. If there is no concomitant pathology, the treatment is local excision.

Lesions commonly observed in the perianal and anal regions, apart from FEP, include condyloma,

inflammatory polyps, granulomatous lesions, and malignancies. Treatment modalities for these diagnoses vary according to the patient and diagnosis.

Although FEP is frequently observed in the perianal area, other lesions can also be seen. Condylomas and anal malignancies are pathologies that can be seen in both the anal canal and perianal area [5]. Condyloma acuminata is a disease that is mostly transmitted sexually. Clinically, its appearance in the anal area can be in the form of multiple cauliflower-like lesions or a single lesion that resembles FEP.

Anal region malignancies are rare but important pathologies to consider in the differential diagnosis of perianal lesions. Anal cancers constitute approximately 1–4% of all colorectal cancers. Malignant lesions that can be seen in the anal region include squamous cell carcinoma, adenocarcinoma, neuroendocrine carcinoma, basal cell carcinoma, and malignant melanoma [6].

Perianal and anal region lesions are mostly benign formations that are rarely observed but are important in terms of diagnosis and treatment as they can cause symptoms such as pain, itching, discomfort, or palpable lesions. However, it should be noted that malignancies can also be observed. In addition, it should not be forgotten that pathological evaluation of the excised specimen is important for differential diagnosis and treatment planning.

Materials and Methods

The study retrospectively evaluated patients who underwent surgery for anal fistula, anal fissure, or palpable lesions in the anal or perianal area and had accompanying lesions that were pre-diagnosed as sentinel tags excised, between January 2017 and February 2022 at the Department of General Surgery. Patient history and surgical and pathological notes were analyzed. The patient's age, gender, pathology results, pre-operative diagnosis, whether colonoscopy was performed in the pre-operative period, the number and diameter of polyps, and any concomitant hemorrhoids, anal fissures, and fistulas were recorded. The pathology results of perianal polypoid lesions were reviewed with the number of polyps, diameter, and accompanying perianal diseases based on the findings.

Statistical analysis

The Number Cruncher Statistical System (NCSS) 2020 Statistical Software (NCSS LLC, Kaysville, Utah, USA) program was used for statistical analysis for the evaluation of the findings obtained in the study. Descriptive statistical methods such as mean, standard deviation, median, min, and max values were used to

evaluate quantitative variables, whereas frequency and percentage were used for qualitative variables. The suitability of the data for normal distribution was evaluated using the Shapiro–Wilks test and Box Plot graphics.

A student t-test was used for the evaluation of two quantitative groups that showed a normal distribution. Mann–Whitney U-test was used for the evaluation of variables that did not show a normal distribution between the two groups. The Chi-square test, Fisher's exact test, and Fisher Freeman–Halton test were used for the comparison of qualitative data.

The results were evaluated at a confidence interval of 95% and a significance level of $p < 0.05$.

Results

In the study, a total of 45 cases were retrospectively analyzed in the general surgery clinic between January 2017 and February 2022, of whom 55.6% ($n = 25$) were male and 44.4% ($n = 20$) were female. The age of the cases ranged from 21 to 86 years, with a mean of 42.80 ± 12.75 .

Table 1: Distribution of descriptive characteristics

Characteristics	n (%)
Gender	
Male	25 (55.6)
Female	20 (44.4)
Age	
Mean±standard deviation	42.80±12.75
Median (min-max)	41 (21–86)

When the pre-operative diagnoses of the cases included in the study were reviewed, it was found that 66.7% ($n = 30$) were FEPs and polypoid lesions, whereas 33.3% ($n = 15$) were condyloma.

As for the final pathology results of the cases, it was seen that 37.8% ($n = 17$) had anal condyloma, 2.2% ($n = 1$) had basal cell carcinoma, 35.6% ($n = 16$) had fibroepithelial polyp, 4.4% ($n = 2$) had hemorrhoid, 4.4% ($n = 2$) had inflammatory polyp, 2.2% ($n = 1$) had multiple squamous papilloma, 2.2% ($n = 1$) had hypertrophic anal papilla, and 8.9% ($n = 4$) had pyogenic granuloma.

The concordance rate between pre-operative diagnoses and final pathology results was 77.7% ($n = 35$), while 22.2% ($n = 10$) had different diagnoses.

On analysis of the patients' complaints, it was found that 40% ($n = 18$) reported pain, 53.3% ($n = 24$) presented with palpable lesions, 13.3% ($n = 6$) reported bleeding, 40% ($n = 18$) experienced swelling, 11.1% ($n = 5$) reported anal discharge, and 20% ($n = 9$) complained of itching.

Among the study participants, 40.9% ($n = 19$) had a single polyp, while 59.1% ($n = 26$) had multiple polyps.

It was observed that 57.8% ($n = 26$) of the cases had concurrent perianal disease, with 34.6% ($n = 9$) presenting with hemorrhoids, 30.8% ($n = 8$) with perianal fistula, and 34.6% ($n = 9$) with anal fissure.

Table 2: Distribution of pre-operative preliminary diagnosis and pathology results

Diagnosis and pathology	n (%)
Pre-operative preliminary diagnosis	
Fibroepithelial polyp	30 (66.7)
Condyloma	15 (33.3)
Pathology	
Condyloma	17 (37.8)
Fibroepithelial polyp	16 (35.6)
Pyogenic granuloma	4 (8.9)
Hemorrhoids	2 (4.4)
Inflammatory polyp	2 (4.4)
Hypertrophic anal papilla	1 (2.2)
Multiple squamous papilloma	1 (2.2)
Pilonidal sinus	1 (2.2)
Basal cell carcinoma	1 (2.2)
Concordance between pre-operative diagnosis and pathology results	
Not concordant	10 (22.2)
Concordant	35 (77.7)

The rate of concomitant perianal disease in patients with a pathological diagnosis of condyloma was found to be statistically significantly lower compared to those with other pathological diagnoses (such as fibroepithelial neoplasm and inflammatory polyp) ($p = 0.003$; $p < 0.01$).

The size of the polyps varied between 0.2 and 3 cm, with an average size of 1.29 ± 0.76 cm.

There was no statistically significant difference in terms of gender and age among patients diagnosed with anal condyloma ($p > 0.05$). However, the rate of multiple polyps in patients diagnosed with anal condyloma was found to be statistically significantly higher than those without anal condyloma ($p = 0.013$; $p < 0.05$) (Figure 1).

Discussion

The anal canal can be defined in two different ways: Surgical anal canal and anatomical anal canal. The surgical anal canal starts from the anorectal ring formed by the puborectalis muscle and extends to the anal verge, located approximately 2 cm distal to the dentate line. The anatomical anal canal, on the other hand, lies between the dentate line and the anal verge. It is approximately 2.5–3 cm long. The perianal region encompasses the area surrounding the anal verge [7].

Although lesions in the distal area are rare, perianal and anal canal lesions are pathologies of clinical importance. These lesions are mostly benign and polypoid, but malignancy can also be a possibility. They can be classified as non-neoplastic, neoplastic, inflammatory, and cystic. Non-neoplastic lesions include FEPs, endometriosis, and hemorrhoids; neoplastic lesions include carcinomas, sarcomas, and melanomas; inflammatory lesions include condylomas and granulomatous infections; and cystic lesions include dermoid and epidermoid cysts.

FEPs are the most commonly encountered non-neoplastic lesions in this region. FEPs can also be

found in skin folds such as the axilla, inguinal area, and neck. They are observed in up to 25% of the population and their incidence increases with age. There is no significant difference between men and women in terms of FEP occurrence throughout the body [8]. In the anal region, they can be referred to as hypertrophied anal papilla or skin tags. These lesions arise from squamous epithelium and subepithelial connective tissue. They mostly develop in response to infection, inflammation, and irritation [1]. They often present with symptoms such as pain, itching, bleeding, discharge, and palpable lesions due to the accompanying benign perianal disease. These complaints were also present in varying degrees in the cases of our study (Table 3).

Table 3: Distribution of disease-related features

Variable	n (%)
*Complaint	
Pain	18 (40.0)
Palpable lesion	24 (53.3)
Bleeding	6 (13.3)
Swelling	18 (40.0)
rectal discharge	5 (11.1)
Itching	9 (20.0)
Number of polyps	
Single	19 (40.9)
Multiple	26 (59.1)
Concomitant perianal disease	
None	19 (42.2)
Existent	26 (57.8)
Hemorrhoids	9 (34.6)
Perianal fistula	8 (30.8)
Anal fissure	9 (34.6)
Polyp size (cm)	
Mean±standard deviation	1.29±0.76
Median (Min-Max)	1 (0.2–3)

*More than one complaint is present.

FEPs are generally millimetric lesions, but can also present in larger sizes. Lesions larger than 15 cm have been reported in axillary and vulvar areas [9], [10]. In the cases presented in the study, the smallest polypoid lesion size was 0.2 cm, while the largest lesion size was recorded as 3 cm. The average polyp size was 1.29 cm (Table 3). One patient had a broad-stem polypoid lesion with a 2.5-cm diameter. To exclude other pathologies and assess their size, magnetic resonance imaging was performed preoperatively (Figure 2). The result of the pathology evaluation of this lesion was a FEP.

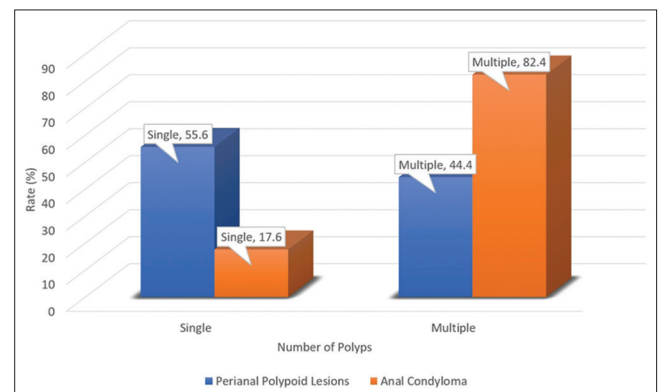


Figure 1: Distribution of the number of polyps of anal condyloma and perianal polypoid lesions

The pathogenesis of FEPs involves chronic irritation and inflammation. They arise from the epithelium



Figure 2: Magnetic resonance imaging of the perianal lesion

and connective tissue [1]. Chronic irritation is often due to associated conditions such as hemorrhoids, fissures, and fistulas accompanying the polyps (Figure 3). In our study, the rate of perianal diseases accompanying FEPs was statistically significantly higher than that of condylomas (Table 4).

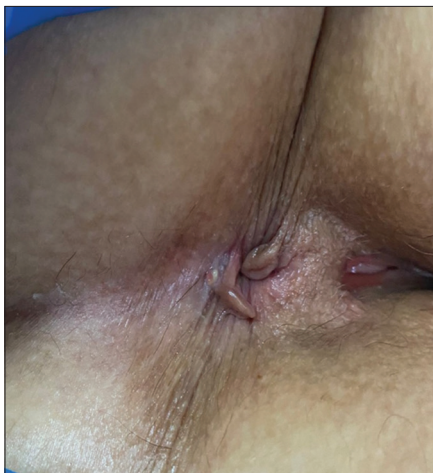

Figure 3: Skin tag accompanying anal fissure

In the perianal region, FEPs are the most common lesions encountered in clinical practice. However, other pathologies can also be found in this area. It is well known that human papillomavirus can cause condylomas in the perianal region. Approximately 60% of condylomas are sexually transmitted, while some can be transmitted through maternal-fetal routes [11]. There are different treatment methods, but recurrence rates are high [12].

Table 4: Comparison of concomitant perianal disease according to pathological diagnoses

Perianal disease	Pathological Diagnosis		p-value
	Other (n = 28)	Condyloma (n = 17)	
Concomitant perianal disease			
No	7 (25.0)	12 (70.6)	*0.003**
Yes	21 (75.0)	5 (29.4)	

*Mann-Whitney U-Test.

Condylomas that occur in the perianal region usually appear in multiples. Surgical excision is not always the first option for all condylomas. Other treatment options, such as cauterization and cryotherapy, are

available. However, if alternative treatment methods are ineffective, surgical excision can also be performed. It should be noted, however, that no method reduces the recurrence rate (Table 5).

Out of the 45 patients presented, 18 of them had a pathology result that showed condyloma and squamous papilloma (Table 2). However, in these patients, it was noteworthy that the pathological evaluation results came back as anal condyloma in four patients, despite the preliminary diagnosis of FEP. It is of great importance to note that there were accompanying anal pathologies such as anal fissure, fistula, and hemorrhoid in these four patients. The diagnoses were established through the excision of the polypoid structure and pathological examination. The follow-up and treatments after surgery were planned based on the pathology results. In addition, it was also noteworthy that the pathology result of one patient with a preliminary diagnosis of condyloma was consistent with a condyloma with dysplasia.

Rarely, malignant lesions can be seen among perianal region lesions. In two of our 46 patients, malignancy was detected. In one patient, the pre-operative diagnosis was thought to be malignant. One patient had a pre-operative diagnosis of FEP; however, the final pathology result after excision showed basal cell carcinoma. The pathology result for the other patient was squamous cell carcinoma.

Basal cell carcinoma is a locally invasive skin tumor that exhibits a slow growth pattern [13]. It can be seen anywhere on the body but is seen in the head and neck area in 80% of cases [14]. Treatment options for basal cell carcinoma vary depending on factors such as the tumor's location, size, and edge characteristics. Surgical excision is the main treatment option, with a 4–5 mm surgical margin being sufficient for a high cure rate. Other treatment options, such as cryotherapy, immunotherapy, and radiotherapy, are also available [15].

One of our patients, whose pre-operative diagnosis was not malignancy but the final pathology result was basal cell carcinoma with positive surgical margins, underwent re-excision by plastic surgery. There was no recurrence detected during the patient's 3-year follow-up.

Anal region carcinomas constitute 1–4% of all colorectal cancers. While squamous cell cancers are the most common anal malignancies, adenocarcinomas are observed in second place [6]. Before the 1980s, abdominoperineal resection was the standard treatment for squamous cell carcinomas. However, due to the significant burden of the operation, the need for permanent colostomy, and the lack of significant differences in recurrence and survival rates, chemoradiotherapy has gradually become a treatment option for suitable patients. Surgical treatment has become prominent in recurrent cases or cases that do not respond to chemoradiotherapy [16].

Table 5: Comparison of disease-related features of anal condyloma and perianal lesions

Variable	Perianal lesions other than anal condyloma (n = 28)	Anal condyloma (n = 17)	P
Gender			
Male	17 (60.7)	8 (47.1)	0.371
Female	11 (39.3)	9 (52.9)	
Age			
Mean \pm standard deviation	45.54 \pm 13.02	38.29 \pm 11.32	0.065
Median (Min-Max)	44.5 (21–86)	39 (23–58)	
Number of polypoid lesions (n = 45)			
Single	16 (55.6)	3 (17.6)	0.013*
Multiple	12 (44.4)	14 (82.4)	

Pearson Chi-square test, student-t test, *p < 0.05.

The patient who was diagnosed with squamous cell carcinoma based on the pathology report had a pre-operative diagnosis of malignancy. A deep biopsy from the perianal area under anesthesia was planned for the patient. For this reason, the patient was not included in the statistical analysis and was separately reviewed. Due to the patient's age and comorbidities, chemoradiotherapy was planned for the squamous cell carcinoma diagnosis. During follow-up, the patient developed metastases and died.

Pyogenic granuloma is a benign soft-tissue tumor that can develop due to causes such as trauma and local irritation. It is mostly observed in the gums, commonly in women [17]. Treatment involves removing pre-disposing factors and, if necessary, surgical excision. Four of the patients we presented had pathology results of pyogenic granuloma. Consistent with the literature, three patients were women, and three had accompanying anal fissures. Local excision was sufficient for the patients, and no problems were detected during follow-up.

In our study, other pathological findings were hemorrhoids, inflammatory polyps, and pilonidal sinus. Hemorrhoid results were not excluded from the study because preoperatively they had a polypoid appearance, and the preliminary diagnosis was FEP, as the patients did not have symptoms such as pain and bleeding in the anal area. The pilonidal sinus was included in the study because it was located in the perianal region.

In our study, it was also noted whether the pre-operative diagnosis of the polypoid lesion in the perianal and anal region was concordant with the final pathological results. This was emphasized to highlight the importance of patients who received a diagnosis and treatment plan change due to pathological evaluation results.

The weakness of the study was the small number of patients. Accessing the post-operative pathologies of all patients was the strength of the study.

Conclusion

The majority of lesions seen in the perianal region are benign and do not carry the risk of malignancy. These lesions are often accompanied by pathologies such as anal fissures or fistulas. During the operations, they are usually excised to ensure the

patient's comfort. Although the preliminary diagnosis for these lesions is usually benign, it is important to follow-up on the pathological results for the patient's diagnosis and treatment.

References

- Bettington M, Brown I. Polyps and polypoid lesions of the anus. *Diagn Histopathol*. 2014;20(1):38-45.
- Sakai Y, Matsukuma S. CD34+ stromal cells and hyalinized vascular changes in the anal fibroepithelial polyps. *Histopathology*. 2002;41(3):230-5. <https://doi.org/10.1046/j.1365-2559.2002.01428.x> PMID:12207784
- Rasi A, Soltani-Arabshahi R, Shahbazi N. Skin tag as a cutaneous marker for impaired carbohydrate metabolism: A case-control study. *Int J Dermatol*. 2007;46(11):1155-9. <https://doi.org/10.1111/j.1365-4632.2007.03287.x> PMID:17988334
- Galanis I, Dragoumis D, Tsolakis M, Zarampoukas K, Zarampoukas T, Atmatzidis K. Obstructive ileus due to a giant fibroepithelial polyp of the anus. *World J Gastroenterol*. 2009;15(29):3687-90. <https://doi.org/10.3748/wjg.15.3687> PMID:19653351
- Lee PK, Wilkins KB. Condyloma and other infections including human immunodeficiency virus. *Surg Clin North Am*. 2010;90(1):99-112, Table of Contents. <https://doi.org/10.1016/j.suc.2009.09.005> PMID:20109635
- Chawla AK, Willett CG. Squamous cell carcinoma of the anal canal and anal margin. *Hematol Oncol Clin North Am*. 2001;15(2):321-44, vi. [https://doi.org/10.1016/s0889-8588\(05\)70215-x](https://doi.org/10.1016/s0889-8588(05)70215-x) PMID:11370496
- Corman ML, Corman ML. *Colon and Rectal Surgery*. Vol. 178. Philadelphia, PA: Lippincott Williams & Wilkins; 2005.
- Banik R, Lubach D. Skin tags: Localization and frequencies according to sex and age. *Dermatologica*. 1987;174(4):180-3. <https://doi.org/10.1159/000249169> PMID:3582706
- Agrawal A, Garg C, Mukherjee S, Kakkar KP. Giant acrochordon of the vulva: A rare occurrence. *Nepal J Dermatol Venereol Leprol*. 2015;3(1):70-2.
- Alkhalili E, Prapasiri S, Russell J. Giant acrochordon of the axilla. *BMJ Case Rep*. 2015;2015:bcr2015210623. <https://doi.org/10.1136/bcr-2015-210623> PMID:26142392
- Lacey CJ, Woodhall SC, Wikstrom A, Ross J. 2012 European guideline for the management of anogenital warts. *J Eur Acad Dermatol Venereol*. 2013;27(3):e263-70. <https://doi.org/10.1111/j.1468-3083.2012.04493.x>

- PMid:22409368
12. Forman D, de Martel C, Lacey CJ, Soerjomataram I, Lortet-Tieulent J, Bruni L, *et al.* Global burden of human papillomavirus and related diseases. *Vaccine*. 2012;30 Suppl 5:F12-23. <https://doi.org/10.1016/j.vaccine.2012.07.055>
PMid:23199955
13. Cigna E, Tarallo M, Maruccia M, Sorvillo V, Pollastrini A, Scuderi N. Basal cell carcinoma: 10 years of experience. *J Skin Cancer*. 2011;2011:476362. <https://doi.org/10.1155/2011/476362>
PMid:21151696
14. Handa Y, Kato Y, Ishikawa H, Tomita Y. Giant superficial basal cell carcinoma of the scrotum. *Eur J Dermatol*. 2005;15(3):186-8.
PMid:15908305
15. Telfer NR, Colver GB, Morton CA. Guidelines for the management of basal cell carcinoma. *Br J Dermatol*. 2008;159(1):35-48.
<https://doi.org/10.1111/j.1365-2133.2008.08666.x>
PMid:18593385
16. Flam M, John M, Pajak TF, Petrelli N, Myerson R, Doggett S, *et al.* Role of mitomycin in combination with fluorouracil and radiotherapy, and of salvage chemoradiation in the definitive nonsurgical treatment of epidermoid carcinoma of the anal canal: Results of a phase III randomized intergroup study. *J Clin Oncol*. 1996;14(9):2527-39. <https://doi.org/10.1200/JCO.1996.14.9.2527>
PMid:8823332
17. Al-Khateeb T, Ababneh K. Oral pyogenic granuloma in Jordanians: A retrospective analysis of 108 cases. *J Oral Maxillofac Surg*. 2003;61(11):1285-8. [https://doi.org/10.1016/s0278-2391\(03\)00729-8](https://doi.org/10.1016/s0278-2391(03)00729-8)
PMid:14613084