


# Pyogenic Abscess Liver Secondary to Perforated Appendicitis

Syahar Banu\* 

Department of Surgery, General Surgery Unit, RA Kartini General Hospital, Jepara, Central Java, Indonesia

## Abstract

**Edited by:** Igor Spiroski

**Citation:** Banu S. Pyogenic Abscess Liver Secondary to Perforated Appendicitis. Open Access Maced J Med Sci. 2024 Dec 15; 12(4):502-504.

<https://doi.org/10.3889/oamjms.2024.11892>

**Keywords:** Pyogenic liver abscess; perforated appendicitis; appendectomy

\***Correspondence:** Syahar Banu, Department of Surgery, General Surgery Unit, RA Kartini General Hospital, Jepara, Central Java, Indonesia. E-mail: syaharbanu98@gmail.com

**Received:** 07-Mar-2022

**Revised:** 11-Apr-2024

**Accepted:** 21-Jun-2024

**Ahead of print:** 20-Nov-2024

**Copyright:** © 2024 Syahar Banu. This is an open-access article distributed under the terms of the Creative Commons Attribution-NonCommercial 4.0 International License (CC BY-NC 4.0)

**Funding:** This research did not receive any financial support

**Competing Interests:** The authors have declared that no competing interests exist

**BACKGROUND:** Pyogenic liver abscess (PLA) secondary to perforated appendicitis can be potentially life-threatening. However, the mortality of PLA has decreased due to earlier and improved diagnosis, development of intensive care, and progression of minimally invasive treatment. Here we present a patient with a pyogenic liver abscess formed after appendectomy.

**CASE REPORT:** A 40-year-old man complained of abdominal pain in the right upper quadrant for the last month. Examination of his abdomen showed enlarged liver, approximately 3 fingers below costae. Laboratory results showed an increased white blood count of 14,000 /mL and slight hypoalbuminemia of 2.9 g/dL. An ultrasound showed liver abscess. The abdominal CT revealed a 6,78 cm x 6,18 cm x 5,4 cm lobulated hypodense cystic mass. The patient was treated with 3rd generation Cephalosporin and underwent percutaneous drainage with Escherichia coli growth on the culture result. The patient was discharged on the 8th day after admission with significant improvement than there are no other complications.

**CONCLUSION:** Early diagnosis and prompt treatment can lead to a better prognosis. Antibiotic is recommended in early treatment to lower bacterial load and control the symptoms of systemic infections. However, effective drainage is recognized as the most effective treatment for large liver abscess, since it could lower bacterial load and increase antibiotic penetration into the abscess.

## Introduction

Pyogenic liver abscess (PLA) secondary to perforated appendicitis is a rare manifestation that can be potentially life threatening. PLA is caused by infection in the liver parenchyma. In Asia, several studies have reported high prevalence of Gram-negative organisms such as Klebsiella pneumonia, Escherichia coli [1]. PLA were not uncommon in the pre-antibiotic era, and appendicitis was often their cause, as reviewed in case report studies of Oschner and DeBakey in 1938. They described appendicitis as the antecedent cause of 11% - 34% cases of PLA and the incidence of PLA after appendicitis was estimated 0.1-0.4% [2].

Abdominal ultrasonography and computerized tomography are frequently used to diagnose liver abscess. The diagnosis may be confirmed by ultrasound-guided percutaneous aspiration and drainage, then appropriate therapy can be planned according to culture and antimicrobial sensitivity test.

We report a case of pyogenic liver abscess formed after appendectomy and treated successfully with percutaneous drainage and antibiotics.

## Case Report

A 40-year-old man complained of abdominal pain in right upper quadrant in the last one month ago. The pain was described as intermittent, non-radiating and squeezing, 6/10 in severity, associated with nausea, weight loss of  $\pm$  4 kg over one month. He had a history of perforated appendicitis and appendectomy was done three months ago. He reported the appendectomy went well and he was discharged after 5 days.

On physical examination, he had marked tenderness in the right upper quadrant of the abdomen, his blood pressure was 100/60 mmHg, pulse rate of 105 beats per minute, respiration rate 24 breaths per minute, and temperature was 38.4°C. Examination of his abdomen showed an enlarged liver, approximately 3 fingers below costae. Laboratory results showed an increased white blood count 14,000 /mL and slightly hypoalbuminemia 2.9 g/dL. An ultrasound was done and showed liver abscess. He underwent computed tomography on the abdomen and revealed 6.78 cm x 6.18 cm x 5.4 cm lobulated hypodense cystic mass.

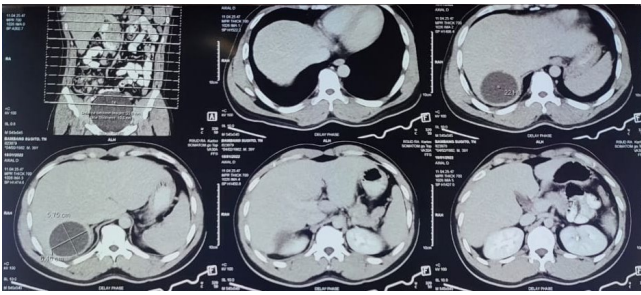


Figure 1: CT Scan abdomen. Axial view

He underwent percutaneous drainage, approximately 150 cc yellow brownish pus was drainage. Pus was sent to microbiology lab. Culture showed *Escherichia coli* growth. He was treated with 3rd generation Cephalosporin.

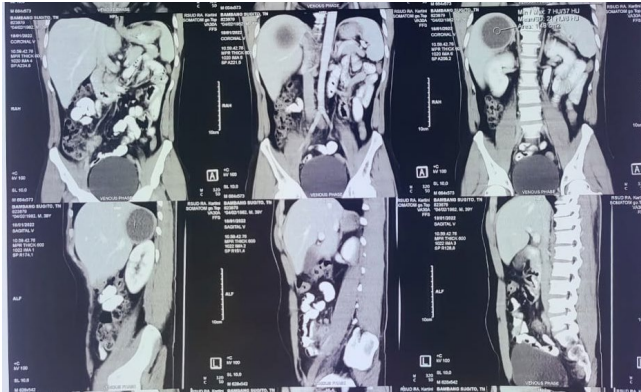


Figure 2: CT Scan Abdomen. Coronal and Sagittal view

## Discussion

PLA is usually caused by acute appendicitis, but recently the incident has decreased because of medical development. These complications counted as Grade IIIb surgical complications.<sup>3</sup> Patients who develop these abscesses have a mean age of 62.4 years old +/- 14 years, with predominance males. Our patient was younger, maybe because of the history of alcoholism [4]. Microbes enter the liver through vessels of the bile ducts or directly. Most PLA in Asia are caused by Gram negative organisms such as *Klebsiella pneumonia* and *Escherichia coli* [1]. This study is similar in this case, which we found *E. coli* in pus culture. In this case, patients suffered from PLA 3 months after laparotomy surgical.

It was difficult to diagnose PLA early because it could be asymptomatic or have general sign of infection. Patients reported symptoms and sign of PLA for the first time a month after appendectomy. His chief complaint was abdominal pain on the right upper quadrant; but he also complained about fever sometimes, nausea, and loss of weight. There was no jaundice. From the laboratory results, we only found leukocytosis and slightly hypoalbuminemia. No other abnormalities of laboratory results, even in liver

function tests. This symptom was similar with other infections as in previous studies [5], [6].

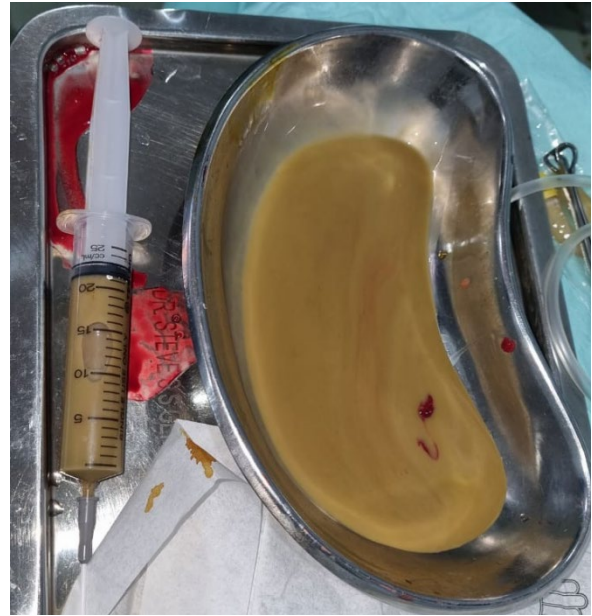

Figure 3: Yellow brownish colored Abscess liver.

We diagnosed liver abscess from abdominal MSCT. The diagnosis later confirmed with USG-guided percutaneous aspiration and drainage and from pus culture. Abdominal CT showed cystic hypodense lesion with firm border on 7th segment of liver. Studies have shown that T has 97% sensitivity in liver abscess [5].

Nowadays, the combination of percutaneous drainage and antimicrobial therapy has become the first choice of liver abscess treatment. Percutaneous drainage was done in this patient because abscess size larger than 5 cm and to prevent abdominal spillage, like guidelines; percutaneous drainage is done if the abscess larger than 5 cm or continuous pyrexia after 48-72 hours of adequate therapy and impending perforation [5], [7], [8]. Surgical drainage considered if percutaneous drainage failed or patient has another complication: jaundice, decreased renal function, and multilocular abscess [6], [9]. We treated with 3rd generation Cephalosporin and Metronidazole treatment at his first admission. After the culture result was done, we found *Escherichia coli* growth and continued 3rd generation cephalosporin therapy for total 7 days. Patients were discharged on the 8th day after admission with significant improvement. Liver abscess could lead to fatal conditions. In this case, patients have no other complication because of early diagnosis, younger age, and prompt treatment.

## References

1. Cerwenka H. Pyogenic liver abscess: Differences in etiology and treatment in Southeast Asia and Central Europe World J. Gastroenterol. 2010;16: 2458-62.

- <https://doi.org/10.3748/wjg.v16.i20.2458> PMID:20503444  
PMCID:PMC2877174
2. Ochsner A, DeBakey M, Murray S. Pyogenic abscess of the liver. *Am J Surg*. 1938;40(1):292-319. [https://doi.org/10.1016/S0002-9610\(38\)90618-X](https://doi.org/10.1016/S0002-9610(38)90618-X)
3. Dindo D, et al. Classification of Surgical Complications. *Annals of Surgery*. 2004; 240(2):205-13. <https://doi.org/10.1097/01.sla.0000133083.54934.ae>  
PMid:15273542 PMCID:PMC1360123
4. Kaplan GG, Gregson DB, Laupland KB. Population-based study of the epidemiology of and the risk factors for pyogenic liver abscess. *Clin Gastroenterol Hepatol*. 2004;2:1032-8. [https://doi.org/10.1016/S1542-3565\(04\)00459-8](https://doi.org/10.1016/S1542-3565(04)00459-8) PMid:15551257
5. Kania BE, Koj J, Farokhian A, Mekheal N, Bellardini A. Pyogenic Liver Abscess Secondary to Appendicitis. *Cureus*. 2021;13(11). <https://doi.org/10.7759/cureus.19188> PMid:34873528  
PMCID:PMC8635680
6. Damanik EH and Ginting F. Case report: liver abscess pyogenic after peritonitis appendix perforation. *IOP Conf Series*. 2018. <https://doi.org/10.1088/1755-1315/125/1/012055>
7. Heneghan HM, Healy NA, Martin ST, Ryan RS, Nolan N, Traynor O, Waldron R. Modern management of pyogenic hepatic abscess: a case series and review of the literature. *BMC Res. Notes*. 2011;4:1-8. <https://doi.org/10.1186/1756-0500-4-80> PMid:21435221  
PMCID:PMC3073909
8. Witkin LR, Nguyen HT, Silberstein CE, Fayad LM, McFarland EG. Abscess after laparoscopic appendectomy presenting as low back pain in a professional athlete. *Sports Health*. 2011;3:41-5. <https://doi.org/10.1177/1941738110374637> PMid:23015989  
PMCID:PMC3445186
9. Zerem E and Susic A. Multiple pyogenic liver abscesses formed after appendectomy: The role of percutaneous drainage in a critically ill patient. *Acta Medica Academica*. 2012;41(2):210-13. <https://doi.org/10.5644/ama2006-124.53> PMid:23331395