



Histamine-1 Receptors Expression in Primary Pterygium Tissue is Higher than Normal Conjunctival Tissue

Putu Yuliawati^{1*}, M. Cynthia Dewi¹, A. A. A. Sukartini Djelantik¹, Putu Budhiastra¹, N. K. Niti Susila¹, P. Cok Istri Dewiyan², I. W. Gede Raka³, I. G. K. Nyoman Arijana⁴

¹Department of Ophthalmology, Faculty of Medicine, Udayana University, Sanglah Hospital, Denpasar, Bali, Indonesia;

²Department of Ophthalmology, Faculty of Medicine, Udayana University, Bali Mandara Eye Hospital, Denpasar, Bali, Indonesia;

³Department of Internal Medicine, Faculty of Medicine, Udayana University, Sanglah Hospital, Denpasar, Bali, Indonesia;

⁴Department of Histology, Faculty of Medicine, Udayana University, Denpasar, Bali, Indonesia

Abstract

Edited by: Slavica Hristomanova-Mitkowska
Citation: Yuliawati P, Dewi MC, Djelantik AAAS, Budhiastra P, Susila NKN, Dewiyani PCI, Raka IWG, Arijana IGKN. Histamine-1 Receptors Expression in Primary Pterygium Tissue is Higher than Normal Conjunctival Tissue. Open Access Maced J Med Sci. 2020 Feb 05; 8(A):841-845.
<https://doi.org/10.3889/oamjms.2020.3378>

Keywords: Histamine-1 receptors; Pterygium tissue; Conjunctival tissue

***Correspondence:** Putu Yuliawati, Department of Ophthalmology, Faculty of Medicine, Udayana University-Sanglah Hospital, Denpasar, Bali, Indonesia.
E-mail: agrasid01@icloud.com

Received: 16-Jul-2019

Revised: 01-Oct-2020

Accepted: 05-Oct-2020

Copyright: © 2020 Putu Yuliawati, M. Cynthia Dewi,

A. A. A. Sukartini Djelantik, Putu Budhiastra,

N. K. Niti Susila, P. Cok Istri Dewiyan,

I. W. Gede Raka, I. G. K. Nyoman Arijana

Funding: This research did not receive any financial support
Competing Interests: The authors have declared that no competing interests exist

Open Access: This is an open-access article distributed under the terms of the Creative Commons Attribution-NonCommercial 4.0 International License (CC BY-NC 4.0)

BACKGROUND: Pterygium is an eye disease with multifactorial etiopathogenesis. Molecular factors such as cell proliferation and inflammatory mediators are associated with increased calcium mobilization and activation of nuclear factor $\kappa\beta$ mediated by histamine-1 receptors (H1R).

AIM: This study aims to determine whether the expression of H1R primary pterygium tissue is higher than normal conjunctival tissue and the expression of H1R based on pterygium grades.

METHODS: This study was an analytic observational study with a case-control study approach at Sanglah General Hospital, Bali Mandara Eye Hospital, and Mangusada Hospital. The study was conducted from November 2017 to April 2018. The pterygium and conjunctival tissues obtained from 28 subjects in the same eye and examined for H1R expression by immunohistochemistry.

RESULTS: The results of this study obtained 64.3% of women with a mean age of 54.2 ± 7.8 years. There was no difference in mean H1R expression between pterygium grades in the final score ($p = 0.759$). There was a mean difference of H1R between primary pterygium (42.50) and normal conjunctival tissue (14.50) with $p < 0.001$. Only tissue types affected the expression of H1R in the final score ($B = 4.893$; 95% CI 4.363–5.423; $p < 0.001$).

CONCLUSION: It was concluded that the expression of H1R primary pterygium tissue was higher in primary pterygium than normal conjunctival tissue.

Introduction

Pterygium is a disorder characterized by the growth of fibrovascular conjunctival lesion with wing-shaped, most occurs in the nasal side with a horizontal direction that invades the corneal surface [1], [2]. Pterygium has the potential to cause blindness, and for the late stages requires complex surgery for visual rehabilitation [3].

Based on the Basic Health Research Indonesia in 2013, the prevalence rate of pterygium in Indonesia was 8.3%, of which the highest in Bali was 25.2% [6].

Etiology and pathogenesis of pterygium are unclear. Environmental factors such as ultraviolet (UV) radiation, low humidity, and dust are related to pterygium pathogenesis [7], [8], [9].

Histamine is the main mediator in allergy, inflammatory reactions, and also in the modulation of cell proliferation and migration [10], [11].

A study proved for the first time that histamine has an important role in pterygium proliferation through

histamine-1 receptors (H1R), where H1R has the highest expression level and H4R with the lowest expression level. In normal conjunctival tissue also found H1R, H2R, and H4R, where the expression level of H1R conjunctival tissue is only half of the pterygium tissue [10].

This research was conducted because of the high prevalence of pterygium in Indonesia and Bali, in particular, where Indonesia is in the equatorial region. Until now, as far as the author's knowledge, research to determine the expression of H1R in primary pterygium compared to normal conjunctival tissue is still limited. Based on the above, this study was conducted to determine whether the expression of H1R primary pterygium tissue is higher than normal conjunctival tissue.

Materials and Methods

This is an analytic observational study with a case-control study approach. This study included 28

study subjects with primary pterygium aged ≥ 40 years and signed informed consent. The study was conducted at Sanglah Hospital, Bali Mandara Eye Hospital, and Mangusada Hospital from November 2017 to April 2018. The sample was all patients with consecutive primary pterygium who met the inclusion and exclusion criteria. Exclusion criteria were the use of topical/systemic anti-allergy drugs in the last 2 weeks, recurrent pterygium, surgical history/conjunctival trauma, and ocular infection.

Research protocol

The preparation stage was carried out interviews, eye examination, and eye documentation by the researcher. Criteria for pterygium grading based on an extension to the cornea shown in Figure 1 [17].

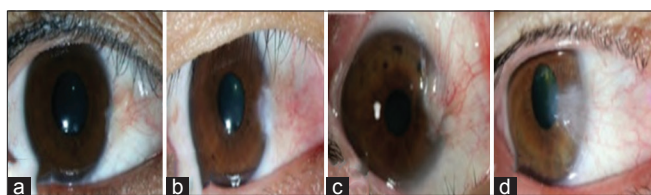

Figure 1. The grading of pterygium is based on an extension to the cornea. Grade I (a), Grade II (b), Grade III (c), and Grade IV (d) [17].

A sampling of the primary and normal conjunctival pterygium tissue is performed on the same surgery eye of the study subject during. The conjunctival tissue is taken in the normal superotemporal conjunctiva (furthest from the pterygium) during graft removal. The sample size of more than 2×2 mm stored separately in a container containing buffer formalin 10%. Immunohistochemical (IHC) examination of H1R expression was performed at the Histology Laboratory of Udayana University, Denpasar. The H1R expression was obtained from the semiquantitative final score and shown in Table 1.

Table 1: Assessment score system [18]

% positive cell (A)	Intensity reaction (B)	Final score
0 = 0	0 = no reaction	$A \times B = \text{score}$
1 \leq 30	1 = weak	
2 = 30–60	2 = mild	
3 \geq 60	3 = strong	

Statistical analysis

Data processing was performed using the SPSS. Categorical scale descriptive data are in the form of frequencies and percentages, while the data are numerically scaled in the form of mean and standard deviation. An unpaired t-test to examine the differences in expression of H1R between the primary pterygium tissue and the normal conjunctiva was used. The difference in mean H1R expression between pterygium degrees was analyzed by one way ANOVA test. Generalized linear model was used for analyzing control variables on different expressions of H1R. The level of significance was at $p < 0.05$.

Results

The proportion of females was 18 people (64.3%) more than males as many as ten people (35.7%) with a mean age of 54.2 ± 7.8 years and the age range of 42–70 years. Most subjects (64.3%) performed outdoor activities 5 h/day with an average length of 4.6 h/day. Smoking was found in 6 people (21.4%), and the presence of ocular allergy was found in 7 people (25.0%). The highest grade of pterygium is 16 in Grade II (57.1%) without any Grade I in the subject (57.1%) (Table 2).

Table 2: Characteristics of subjects

Variable	n (%)	Mean \pm SD
Age (year)		54.2 ± 7.8
Gender		
Male	10 (35.7)	
Female	18 (64.3)	
Outdoor activities (h/day)		
≤ 5	18 (64.3)	
> 5	10 (35.7)	
Onset (year)		
< 40	6 (21.4)	
≥ 40	22 (78.6)	
Smoking status		
Yes	6 (21.4)	
No	22 (78.6)	
Ocular allergy		
Yes	7 (25.0)	
No	21 (75.0)	
Pterygium grading		
I	-	
II	16 (57.1)	
III	11 (39.3)	
IV	1 (3.6)	

Description of tissue with IHC examination on pterygium tissue (A) shows H1R expression (brown color) more than conjunctival tissue (B). The red arrow indicates the cell expressing H1R. The black arrow shows cells that do not express H1R. In normal conjunctival tissue, there is almost no H1R expression (Figure 2).

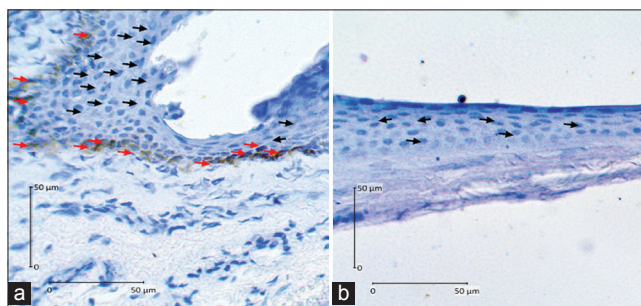


Figure 2: (a and b) H1R expression in pterygium and conjunctival tissue with IHC examination

The expression of H1R primary pterygium tissue based on its grade was assessed from the percentage of positive cells, reaction intensity, and final score in the IHC examination can be seen in Table 3. Based on the results of the table, there was no difference in mean H1R expression between pterygium grades.

Table 3: H1R expression based on pterygium grading

Variables	Pterygium grading	H1R expression	p-value
% Positive cell (A)	II	14.63	0.926
	III	14.23	
	IV	15.50	
Intensity reaction (B)	II	14.63	0.760
	III	13.91	
	IV	19.00	
Final score (AxB)	II	14.66	0.759
	III	13.86	
	IV	19.00	

H1R: Histamine-1 receptors
H1R: Histamine-1 receptors.

Expression of H1R pterygium and conjunctival tissue based on the percentage of positive cells, reaction intensity, and the final score on the IHC examination can be seen in Table 4.

Table 4: Differences in the expression of H1R pterygium and conjunctival tissue

	H1R expression		p-value
	Pterygium	Conjunctiva	
% Positive cell (A)	42.14	14.86	0.000
Intensity reaction (B)	42.50	14.50	0.000
Final score (AxB)	42.50	14.50	0.000

H1R: Histamine-1 receptors.

Based on the results of Table 4, there was a difference in the mean expression of H1R between the primary pterygium tissue and the normal conjunctiva, where the mean rank expression of H1R primary pterygium tissue was almost 3 times higher than the normal conjunctival tissue.

According to the results of Table 5, only the type of tissue (primary pterygium tissue vs. normal conjunctival tissue) affects the expression of H1R, while other variables do not affect.

Table 5: Differences in H1R expression after controlling gender, age, ocular allergy, outdoor activity, smoking status, onset, pterygium grading, and type of tissue

H1R expression	Variable	B	95% CI	p-value
% positive cell	Gender: Male	-0.014	-0.358-0.330	0.934
	Ref: Female			
	Age (year)	0.008	-0.009-0.025	0.340
	Ocular allergy: Yes	0.040	-0.263-0.343	0.793
	Ref: No			
	Outdoor activity ≤5 h	0.125	-0.153-0.404	0.370
	Ref: >5 h			
	Smoking status yes	-0.035	-0.435-0.365	0.860
	Ref: No			
	Pterygium onset (year)	0.087	-0.230-0.404	0.583
	Pterygium grading	-0.043	-0.285-0.199	0.720
	Type of tissue (Pterygium vs. Conjunctiva)	1.571	1.357-1.786	0.000
	Intensity reaction	Gender: Male	0.066	-0.333-0.466
Ref: Female				
Age (year)		0.011	-0.008-0.031	0.256
Ocular allergy: Yes		0.124	-0.228-0.476	0.483
Ref: No				
Outdoor activity ≤5 h		0.035	-0.289-0.358	0.831
Ref: >5 h				
Smoking status: Yes		-0.029	-0.493-0.435	0.900
Ref: No				
Pterygium onset (year)		0.253	-0.116-0.621	0.174
Pterygium grading		-0.196	-0.477-0.084	0.166
Type of tissue (Pterygium vs. Conjunctiva)		2.357	2.108-2.606	0.000

H1R: Histamine-1 receptors.

et al. found prevalence rates above 33% in older age (≥50 years) in China [5]. A study in Central India by Nangia et al. found the mean age of subjects with pterygium 56.6 ± 13 years and age range of 30–85 years [2]. Nemet et al. in Israel stated that the mean age of pterygium patients was 58.4 ± 14 years [4]. Age as a significant risk factor for pterygium is associated with increased susceptibility to UV exposure in older people with increasing age and spending most of the outdoor activities resulting in the accumulation of UV damage. The results obtained may differ from other studies due to differences in age ranges in collecting study samples.

Some literature shows a higher prevalence in women than men as in studies conducted in Dali populations in China, Doumen County in China, populations in the Barbados Islands, and Kathmandu in Nepal [5], [19], [20], [21]. In this study, the percentage of female subjects (64.3%) was more than that of men (35.7%). Research subjects were patients with pterygium who underwent surgery at the hospital. Women also pay more attention to cosmetic reasons so that they perform eye examinations for surgery.

The tropical climate as a risk factor for pterygium is strongly associated with outdoor activity and UV exposure [4]. Research in Indonesia has a higher prevalence of pterygium in groups with outdoor activity 10 years earlier [22]. A study in Sumatra (Indonesia) by Gazzard et al. found a history of outdoor activities >5 h/day for the past 10 years associated with a doubled risk for pterygium compared without the history [3]. This study obtained outdoor activities >5 h/day in the last 5 years, amounting to 21.4% of the subjects. Bali is located at 8° south latitude, which is included in the “pterygium belt” region with high UV exposure.

Lee et al. (2017) in Korea stated that current smoking history was significantly lower in the pterygium group than without pterygium, according to previous studies that found that smoking protects against pterygium [23]. Conversely, Pyo et al. reported that pterygium in Korea is associated with a lifestyle without smoking [24]. Histamine through H1R can cause immunomodulatory effects, itching, swelling, erythema, increased vascular permeability, and pain [25]. Ocular symptoms can occur in 40–60% of allergy patients [26]. In this study, 28.6% of the subjects were found with ocular allergy. These results were obtained based on interviews with research subjects, where ocular allergy can occur unnoticed by the subject so that further examination is needed for diagnosis.

A study by Shrestha and Kaiti (2016) obtained 58% of pterygium with Grade I followed by Grade II at 41% [19]. A study by Tan et al. in the Riau Islands of Indonesia obtained the highest 59.3% pterygium Grade I [22]. In this study, 57.1% pterygium II Grade was obtained without any Grade I. The subjects in this study were the only pterygium which caused complaints and performed surgery so that pterygium Grade I was

Discussion

The relationship between sex and age with the development of pterygium is still debatable. Wu

not found because it was generally asymptomatic and did not carry out examinations to health services. The varying degrees of pterygium division between different studies cause difficulties in comparing the severity of the inter-study.

The relationship between H1R and primary pterygium tissue has been demonstrated in this study and other previous studies. This study is the first study to assess RH-1 expression based on pterygium grading. Based on the grade of pterygium, the mean rank of expression of H1R pterygium Grade II was 14.66, Grade III 13.86, and Grade IV 19.0 in the final score which did not have a significant difference between pterygium grades with $p = 0.759$. Pterygium I Grade was not found in this study. The results showed no relationship between pterygium grading and H1R expression.

H1R paired with $G_{q/11}$ proteins activate intracellular Ca^{2+} signaling, cGMP, phospholipase D, phospholipase A_2 , and $NF\kappa\beta$ [27]. Active HR and epidermal growth factors have been found in pterygium tissue. The H1R is the dominant receptor and is known to increase intracellular Ca^{2+} levels [9]. According to Qin *et al.*, the highest H1R expression and H4R were lowest in pterygium fibroblasts, where the proliferative effect of histamine works mainly through H1R. Expression of H1R on pterygium fibroblasts was investigated from conjunctival fibroblasts with RT-qPCR and DNA agarose gel electrophoresis [10].

In this study, the mean rank of H1R primary pterygium tissue was 42.14 and normal conjunctival tissue was 14.86 in the final score with $p < 0.001$ so that there was a significant difference in H1R expression between pterygium and the conjunctiva tissue. Mean rank expression of H1R primary pterygium tissue is almost 3 times higher than normal conjunctival tissue. H1R included in GPCR can increase intracellular Ca^{2+} levels and activate $NF\kappa\beta$ which is a prominently inflammatory transcription factor [9], [12], [13], [14], [15], [16]. Calcium signaling activity is associated with excess cell proliferation, trans-differentiation, and angiogenesis. Active $NF-\kappa\beta$ in pterygium contribute to several biological effects such as collecting inflammatory cells in pterygium tissue, increasing cell motility and invasion, influencing the expression of pro-apoptotic and anti-apoptotic genes and cell cycle proteins [7].

Conclusion

Based on the results of the study, it was concluded that H1R expression primary pterygium tissue was higher than normal conjunctival tissue and without mean differences between pterygium grades. This finding shows cell proliferation and inflammatory factors are molecular factors associated with the

development of pterygium. The further biomolecular study is needed to investigate the susceptibility of H1R expression.

References

1. American Academy of Ophthalmology and Staff. External Eye Disease and Cornea. United State of America: American Academy of Ophthalmology; 2015-2016. p. 324-325.
2. Nangia V, Jonas JB, Nair D, Saini N, Nangia P, Panda-Jonas S. Prevalence and associated factors for pterygium in rural agrarian Central India. The Central India eye and medical study. PLoS One. 2013;8(2):e82439. <https://doi.org/10.1371/journal.pone.0082439>
PMid:24324789
3. Gazzard G, Saw SM, Farook M, Koh D, Widjaja D, Hong CY, *et al.* Pterygium in Indonesia: Prevalence, severity and risk factors. Br J Ophthalmol. 2002;86(12):1341-6. <https://doi.org/10.1136/bjo.86.12.1341>
PMid:12446360
4. NemetAY, Vinker S, Segal O, Mimouni M, Kiserman I. Epidemiology and associated morbidity of pterygium: A large, community-based case-control study. Semin Ophthalmol. 2016;31(5):446-51. <https://doi.org/10.3109/08820538.2014.962169>
PMid:25392263
5. Wu K, He M, Xu J, Li S. Pterygium in aged population in Doumen country, China. Yan Ke Xue Bao. 2002;18(3):181-4.
PMid:15510751
6. Kementerian Kesehatan RI. Riset Kesehatan Dasar Tahun; 2013. Available from: <http://www.depkes.go.id/resources/download>. [Last accessed 2020 Jan 10].
7. Cardenas-Cantu E, Zavala J, Valenxuela J, Valdez-Garcia JE. Molecular basis of pterygium development. Semin Ophthalmol. 2014;31(6):567-83. <https://doi.org/10.3109/08820538.2014.971822>
PMid:25415268
8. Alqahtani JM. The prevalence of pterygium in Al-Khobar: A hospital-based study. J Family Community Med. 2013;20(3):159-61. <https://doi.org/10.4103/2230-8229.121980>
PMid:24672272
9. Fang C. Elucidating the Regulatory Mechanisms of Pterygium (Thesis). Norwich, UK: School of Biological Sciences, University of East Anglia; 2013.
10. Qin Z, Fu Q, Zhang L, Yin H, Jin X, Tang Q, *et al.* Proliferative effects of histamine on primary human pterygium fibroblasts. Mediators Inflamm. 2016;2016:9862496. <https://doi.org/10.1155/2016/9862496>
PMid:27872516
11. Bielory L, Ghafoor S. Histamine receptors and the conjunctiva. Curr Opin Allergy Clin Immunol. 2005;5(5):437-40. <https://doi.org/10.1097/01.all.0000183113.63311.11>
PMid:16131920
12. Jemima EA, Prema A, Thangam EB. Functional characterization of histamine H4 receptor on human mast cells. Mol Immunol. 2014;62(1):19-28. <https://doi.org/10.1016/j.molimm.2014.05.007>
PMid:24934979
13. Panula P, Chazot PL, Cowart M, Gutzmer R, Leurs R, Liu WL, *et al.* International union of basic and clinical pharmacology. XCVIII. Histamine receptors. Pharmacol Rev.

- 2015;67(3):601-55. <https://doi.org/10.1124/pr.114.010249>
PMid:26084539
14. Criado PR, Maruta CW, Criado RF, Filho CA. Histamine, histamine receptors and antihistamines: New concepts. *An Bras Dermatol.* 2010;85(2):195-210. <https://doi.org/10.1590/s0365-05962010000200010>
PMid:20520935
 15. Tripathi T, Shahid M, Khan HM, Khan RA, Siddiqui M, Mahdi AA. The influence of histamine H1-receptor on liver functions in immunized rabbits. *Saudi J Biol Sci.* 2011;18(4):411-8. <https://doi.org/10.1016/j.sjbs.2011.07.002>
PMid:23961154
 16. Siak JJ, Ng SL, Seet LF, Beuerman RW, Tong L. The nuclear-factor kappaB pathway is activated in pterygium. *Invest Ophthalmol Vis Sci.* 2011;52(1):230-6. <https://doi.org/10.1167/iovs.10-5735>
PMid:20811049
 17. Seid A, Bejiga A. Free conjunctival autograft in the management of advanced primary and recurrent pterygia. *East Afr Med J.* 2000;77(11):588-91. <https://doi.org/10.4314/eamj.v77i11.46727>
PMid:12862103
 18. Klein M, Vignaud JM, Hennequin V, Toussaint B, Bresler L, Plenat F, et al. Increased expression of the vascular endothelial growth factor is a pejorative prognosis marker in papillary thyroid carcinoma. *J Clin Endocrinol Metab.* 2001;86(2):656-8. <https://doi.org/10.1210/jcem.86.2.7226>
PMid:11158026
 19. Shrestha P, Kaiti R. A hospital based study of pterygium in tertiary care hospital of Nepal. *Kathmandu Univ Med J (KUMJ).* 2016;14(55):192-7.
PMid:28814677
 20. Zhong H, Cha X, Wei T, Lin X, Li X, Li J, et al. Prevalence of and risk factors for pterygium in rural adult Chinese populations of the bai nationality in Dali: The Yunnan minority eye study. *Invest Ophthalmol Vis Sci.* 2012;53(10):6617-21. <https://doi.org/10.1167/iovs.11-8947>
PMid:22956605
 21. Luthra R, Nemesure BB, Wu SY, Xie SH, Leske MC. Frequency and risk factors for pterygium in the Barbados eye study. *Arch Ophthalmol.* 2001;119(12):1827-32. <https://doi.org/10.1001/archophth.119.12.1827>
PMid:11735795
 22. Tan CS, Lim TH, Koh WP, Liew GC, Hoh ST. Epidemiology of pterygium on a tropical Island in the Riau Archipelago. *Eye (Lond).* 2006;20(8):908-12. <https://doi.org/10.1038/sj.eye.6702046>
PMid:16167080
 23. Lee YB, Kim SY, Park YG, Han KD, Kim JW, Chae HS, et al. Evaluation of socioeconomic status as a risk factor of pterygium using the Korean national health and nutrition examination survey 2010 to 2011: A STROBE-compliant article. *Medicine (Baltimore).* 2017;96(11):e6343. <https://doi.org/10.1097/md.00000000000006343>
PMid:28296766
 24. Pyo EY, Mun GH, Yoon KC. The prevalence and risk factors for pterygium in South Korea: The Korea national health and nutrition examination survey (KNHANES) 2009-2010. *Epidemiol Health.* 2016;38:e2016015. <https://doi.org/10.4178/epih.e2016015>
PMid:27156345
 25. Wade L, Bielory L, Rudner S. Ophthalmic antihistamines and H1-H4 receptors. *Curr Opin Allergy Clin Immunol.* 2012;12(5):510-6. <https://doi.org/10.1097/aci.0b013e328357d3ba>
PMid:22918191
 26. Leonardi A, Bogacka E, Fauquert JL, Kowalski ML, Groblewska A, Jedrzejczak-Czechowicz M, et al. Ocular allergy: Recognizing and diagnosing hypersensitivity disorders of the ocular surface. *Allergy.* 2012;67(11):1327-37. <https://doi.org/10.1111/all.12009>
PMid:22947083
 27. Jutel M, Blaser K, Akdis CA. Histamine in chronic allergic responses. *J Invest Allergy Clin Immunol.* 2005;15(1):1-8.
PMid:15864876