



The Rare Five Finger Pectoralis Nerves: A Case Report

Adegbenro Omotuyi John Fakoya^{1*}, Michelanthony Lee Rosado-Velazquez², Kirthana Sugunathevan², Kai Anika Prophete², Surpreet Kaur Khunkhun², Emilio Aguinaldo², Abayomi Gbolahan Afolabi¹, Thomas McCracken¹

¹Department of Anatomical Sciences, University of Medicine and Health Sciences, Basseterre, St. Kitts and Nevis; ²Medical Student, University of Medicine and Health Sciences, Basseterre, St. Kitts and Nevis

Abstract

The brachial plexus is a complex network of nerve tissue in the human body that has been reported to vary from person to person. We describe a very rare variation of the brachial plexus found on a routine cadaveric dissection. On the left side of the chest, we identified two lateral pectoral nerves arising from the lateral cord and innervating the pectoralis major muscle; two medial pectoral nerves (MPNs) arising from the medial cord that innervates both pectoral muscles and a communicating branch that connects the lateral and MPN. In addition, this communicating branch had a nerve that innervated the pectoralis minor muscle. Knowing the variations of branching of the pectoral nerves is critical when performing any medical procedure in the pectoral region, such as plastic breast reconstruction surgery after modified radical mastectomy in breast cancer, removal of the pectoral muscles, anesthetizing the brachial plexus, or axillary dissection.

Edited by: Slavica Hristomanova-Mitkovska

Citation: Fakoya AOJ, Rosado-Velazquez ML, Sugunathevan K, Prophete KA, Khunkhun SK, Aguinaldo E, Afolabi AG, McCracken T. The Rare Five Finger Pectoralis Nerves: A Case Report. Open Access Maced J Med Sci. 2020 Aug 20; 8(A):548-551. <https://doi.org/10.3889/oamjms.2020.4563>

Keywords: Lateral and medial pectoral nerves; Pectoral muscles; Brachial plexus variations; Communicating branch; Nerve to the communicating branch, Modified radical mastectomy

***Correspondence:** Dr. Adegbenro Omotuyi John Fakoya, Department of Anatomical Sciences, University of Medicine and Health Sciences, Basseterre, St. Kitts and Nevis. E-mail: afakoya@umhs-sk.net

Received: 04-Mar-2020

Revised: 18-Jul-2020

Accepted: 22-Jul-2020

Copyright: © 2020 Adegbenro Omotuyi John Fakoya,

Michelanthony Lee Rosado-Velazquez,

Kirthana Sugunathevan, Kai Anika Prophete,

Surpreet Kaur Khunkhun, Emilio Aguinaldo,

Abayomi Gbolahan Afolabi, Thomas McCracken

Funding: This research did not receive any financial

support

Competing Interest: The authors have declared that no

competing interest exists

Open Access: This is an open-access article distributed

under the terms of the Creative Commons Attribution-

NonCommercial 4.0 International License (CC BY-NC 4.0)

Introduction

The two pectoral muscles are the pectoralis major muscle (PMM) and pectoralis minor muscle (PmM). The PMM is innervated by both the lateral pectoral nerves (LPNs) and the medial pectoral nerves (MPNs), while the PmM is innervated by the MPN [1]. Usually, the lateral pectoral nerve arises from the lateral cord of the brachial plexus and is made up of nerve roots C5, C6, and C7, giving motor control to the clavicular and sternocostal head of the PMM [1]. The MPN, on the other hand, arises from the medial cord of the brachial plexus and consists of the nerve roots, C8 and T1 (with some branches piercing through the PmM), and gives motor control to the sternocostal head of the PMM [2]. The PMM and PmM are essential muscles of the chest, allowing for flexion, internal rotation, and adduction of the arms as well as depression and protraction of the scapula, respectively [1]. Both muscles are also considered to be accessory muscles of respiration and play a part in deep inhalation by pulling the ribcage to create room for the lungs to expand [3].

There are previous studies that have reported many different variations of the LPN and MPN with regard to where they arise from the brachial plexus (Table 1). There are also reports on how the LPN and MPN traverse through the pectoral muscles (Table 2). However, there is an interesting anomalous connection of the pectoral nerves that have not been mentioned in the past literature, which is mentioned in our case report. Thus, we present a case of two LPN and MPN coming off the lateral and medial cord, respectively, with a communicating branch.

Case Presentation

Medical students at the University of Medicine and Health Sciences in St. Kitts and Nevis performed a routine cadaveric dissection of a 70-year-old Caucasian male in the anatomy laboratory. This dissection revealed two LPN branching from the lateral cord which innervated the PMM (Figure 1). Similarly,

Table 1: Summary of reported literature of the pectoral nerves branching pattern variants

Authors	Branching pattern variant	Year discovered	References
Lee	-C5, C6, C7 gave rise to LPN 50% of the time -C6, C7 gave rise to LPN 50% of the time -C8, T1 gave rise to MPN 73.3% of the time -C8 only gave rise to MPN 23.4% of the time -T1 only gave rise to MPN 3.3% of the time	2007	4
Shetty, et al.	- LPN from AD	2014	5
Kg and Saniya	- MPN from MT - 2 LPN from LC - LPN from 2AD+MT - LPN+MPN from common trunk in LC - CB between LPN+MPN	2014	6
Goel, et al.	-2 LPN and 1 MPN were seen to arise from the lateral and medial cord respectively.	2014	7
Tigga, et al.	-LPN and MPN forming AP	2016	8
Singh	-2 LPN: 1 LPN from AD of UT -1 LPN from AD of MT	2017	9

LPN: Lateral pectoral nerve, AD: Anterior division, MPN: Medial pectoral nerve, MT: Middle trunk, AP: Ansa pectoralis, LC: Lateral cord, CB: Communication branch, UT: Upper trunk.

there was two branches of the medial pectoral nerve arising from the medial cord of the brachial plexus. One of the branches directly innervated the PmM while the other directly innervated the PMM without piercing the PmM (Figure 1). There was also a communicating branch that innervated the PMM (Figure 1). The LPN was found lateral to the thoracoacromial trunk while the MPN was found medial to it. The MPN also crossed the axillary artery to form the ansa pectoralis with the LPN (Figure 1).

Discussion

The brachial plexus is one of the five spinal plexuses, which is responsible for the motor and sensory and sympathetic supply for the upper limbs [16]. In its origin, the brachial plexus is a somatic nerve plexus that arises from C5 to C8 nerve roots, then forms trunks, divisions, cords, and branches [5].

The discovery of this variation in our cadaver coincides with other studies that showed the MPN piercing the PmM, as a single trunk in 76%, and as dividing branches in 34% specimens [6].

At present, in MRM procedures, there are various sites used to administer anesthesia. One common site for post-operative analgesia includes the usage of the pectoral nerves. Zhao *et al.* (2019) evaluated the analgesic efficacy of the PECS block post-radical mastectomy and found that pectoral nerve block is effective as it reduces the need for post-operative rescue analgesia [17]. Even though there are controversies regarding efficacy, understanding the anatomy and locations of the pectoral nerves along with its variants is crucial in understanding how anesthesia can be administered for common procedures.

Aside from nerve blocks, on performing breast augmentation surgery, understanding the anatomy and variations of the MPN and LPN are important as any

Table 2: Summary of reported literature of anatomical variants in PMM and PmM innervations

Authors	Innervation variation	Year discovered	References
Hoffman and Elliott	-62% of patients the MPN courses through the PmM to innervate the lower half or two-thirds of the PmM. -In the other 38% of patients, the MPN exits around the lateral aspect of the PmM.	1987	10
Rai, et al.	-Three pectoral nerves were seen to supply PMM only	2008	11
Provencher, et al.	-The PMM is supplied primarily by the LPN, which originates from the C5-6 roots. It supplies the clavicular portion of the muscle -The middle pectoral nerve originates at C7 and joins with the LPN shortly thereafter -The MPN also supplies a portion of the inferior segment of the muscle. This nerve exits at C8-T1 as a single branch, coursing posterior to the subclavian artery. It makes an upward right angle around the lateral thoracic artery joining with the middle pectoral nerve, which has a divided course with 75% of it piercing through the PmM and 25% coursing around the lateral portion of the PmM before innervating the PMM	2010	12
Mehta, et al.	-MPN various branches pierce PmM	2012	13
Authors	Innervation variation	Year Discovered	Reference
David, et al.	-Three constant branches of the pectoral nerve were found -Superior branch travelled straight to PMM to innervate clavicular aspect -Middle branch coursed under the PMM, near the pectoral branch of the thoracoacromial artery to innervate sternal aspect -Inferior branch passed beneath PmM to innervate PmM and the costal aspect of the PMM	2012	14
Kg and Saniya	- Three MPN pierce PmM - NCB piercing PmM	2014	6
Goel, et al.	-Two LPNs, one supplying pectoralis major and the other supplying pectoralis minor -MPN divided into two branches, one supplying PMM without piercing PmM and the other supplying PMM only	2014	7
Haladaj, et al.	-MPN innervates solely the lower PMM	2019	15

MPN: Medial pectoral nerve, PmM: Pectoralis minor muscle, PMM: Pectoralis major muscle, NCB: Nerve of the communicating branch.

injury to these nerves can result in total denervation of the PMM [18].

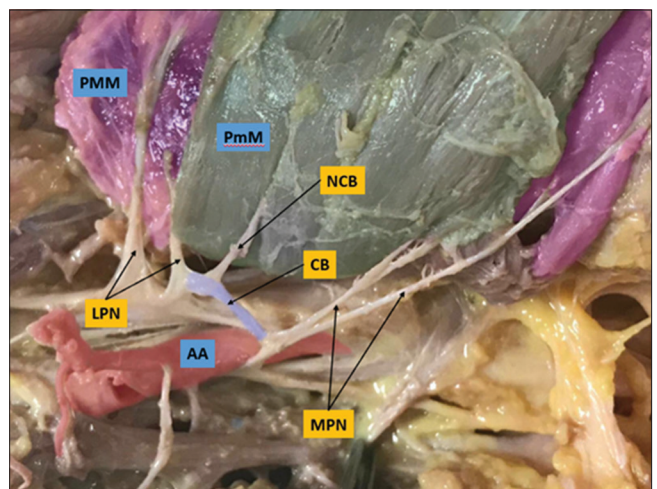


Figure 1: Dissection showing the variation of the left pectoral region. The axillary artery (AA) in red, left pectoralis major muscle (PMM) in purple, left pectoralis minor muscle (PmM) in green, two lateral pectoral nerves (LPN), two medial pectoral nerves (MPN), a communicating branch (CB) in blue, and a nerve of the communicating branch (NCB)

Furthermore, understanding the anatomical variants can help surgeons avoid complications such as capsule formation around breast implants, which has been implicated as causing compression of the medial and LPN under the PMM [19]. If a patient presented with an anatomical variation similar to what was reported in the cadaver, the surgeon can better place the breast implant to reduce the amount of pain or discomfort felt from capsule formation.

Supportive research additionally shows the anatomical relationship between the LPN and MPN and its variations can be studied to help surgeons easily identify where the MPN exits. This location is known to be an intraoperative location at the end of the lateral thoracic artery [20]. Once the location has been identified, the location, length, and amount of motor axons of the inferior pectoral nerve can be useful in procedures involving the reinnervation of the musculocutaneous nerve in upper brachial plexus injuries [20].

In addition, understanding the anatomical variants can help surgeons to localize nerve injuries and lesions to the PMM and PmM with a high degree of accuracy [27].

A limitation to the study was that Sihler's technique was not used to determine the innervation pattern (Figure 1). Sihler's staining technique would better clarify as it allows visualization of the nerve distribution within soft tissues without extensive dissection [21]. However, this technique would still fail to provide the ability to trace where the NCB originated. A different technique could be used to define the neural circuit of the NCB *in vivo* [22].

Conclusion

The brachial plexus is known to have many variations, and it is crucial to describe rare variations to reduce the risk of iatrogenic injuries during surgery. In our study, we had two LPNs piercing the PMM, two MPNs individually piercing PmM and PMM, and an NCB piercing the PmM. These anomalies have not been mentioned before in literature. Our anomaly impacts surgical procedures such as brachial plexus blockade, mastectomies, and more as discussed. Although our study did not find the origin of NCB, further study can investigate a technique that could be used to find the origin of NCB *in vivo*.

References

1. Netter F. Atlas of Human Anatomy, Professional Edition. Saint Louis: Elsevier Health Sciences; 2014.
2. Bagheri S, Bell R, Khan H. Current Therapy in Oral and Maxillofacial Surgery. St. Louis: Elsevier Saunders; 2012.
3. De Troyer A, Kirkwood P, Wilson T. Respiratory action of the intercostal muscles. *Physiol Rev.* 2005;85(2):717-56. PMID:15788709
4. Lee K. Anatomic variation of the spinal origins of lateral and medial pectoral nerves. *Clin Anat.* 2007;20(8):915-8. <https://doi.org/10.1002/ca.20556> PMID:17948291
5. Shetty P, Nayak SB, Kumar N, Thangarajan R, D'Souza MR. Origin of medial and lateral pectoral nerves from the supraclavicular part of brachial plexus and its clinical importance-a case report. *J Clin Diagn Res.* 2014;8(2):133-4. <https://doi.org/10.7860/jcdr/2014/7082.4029> PMID:24701504
6. Kg P, Saniya K. Anatomical study of pectoral nerves and its implications in surgery. *J Clin Diagn Res.* 2014;8(7):AC01-5. PMID:25177552
7. Goel S, Rustagi S, Kumar A, Mehta V, Suri R. Multiple unilateral variations in medial and lateral cords of brachial plexus and their branches. *Anat Cell Biol.* 2014;47(1):77-80. <https://doi.org/10.5115/acb.2014.47.1.77> PMID:24693486
8. Tigga S, Wadhwa S, Goswami P. Unusual communications of the brachial plexus. *Int J Appl Basic Med Res.* 2016;6(1):68-70. <https://doi.org/10.4103/2229-516x.174021> PMID:26958529
9. Singh R. Variations of cords of brachial plexus and branching pattern of nerves emanating from them. *J Craniofac Surg.* 2017;28(2):543-7. <https://doi.org/10.1097/scs.0000000000003341> PMID:28033192
10. Hoffman G, Elliott L. The anatomy of the pectoral nerves and its significance to the general and plastic surgeon. *Ann Surg.* 1987;205(5):504-7. <https://doi.org/10.1097/00000658-198705000-00008> PMID:3579399
11. Yang Y, Fan D. P532: Pectoralis major and pectoral reflex in patients with amyotrophic lateral sclerosis. *Clin Neurophysiol.* 2014;125:S193-4. [https://doi.org/10.1016/s1388-2457\(14\)50631-1](https://doi.org/10.1016/s1388-2457(14)50631-1)
12. Provencher C, Handfield K, Boniquit N, Reiff S, Sekiya J, Romeo A. Injuries to the pectoralis major muscle: Diagnosis and management. *Am J Sports Med.* 2010;38(8):1693-705. <https://doi.org/10.1177/0363546509348051> PMID:20675652
13. Beheiry E. Innervation of the pectoralis major muscle: Anatomical study. *Ann Plast Surg.* 2011;68:209-14.
14. David S, Balaguer T, Baque P, Peretti F, Valla M, Lebreton E, et al. The anatomy of the pectoral nerves and its significance in breast augmentation, axillary dissection and pectoral muscle flaps. *J Plast Reconstr Aesthet Surg.* 2012;65(9):1193-8. <https://doi.org/10.1016/j.bjps.2012.03.032> PMID:22534124
15. Haładaj R, Wyśiadecki G, Clarke E, Polguj M, Topol M. Anatomical variations of the pectoralis major muscle: Notes on their impact on pectoral nerve innervation patterns and discussion on their clinical relevance. *Biomed Res Int.* 2019;2019:1-15. <https://doi.org/10.1155/2019/6212039>
16. Johnson E, Vekris M, Zoubos A, Soucacos P. Neuroanatomy of the brachial plexus: The missing link in the continuity between the central and peripheral nervous systems. *Microsurgery.* 2006;26(4):218-29. <https://doi.org/10.1002/micr.20233> PMID:16628658

17. Zhao J, Han F, Yang Y, Li H, Li Z. Pectoral nerve block in anesthesia for modified radical mastectomy. *Medicine*. 2019;98(18):e15423. <https://doi.org/10.1097/md.00000000000015423>
PMid:31045802
18. Kirik A, Mut S, Daneyemez M, Secer H. Anatomical variations of brachial plexus in fetal cadavers. *Turk Neurosurg*. 2017. <https://doi.org/10.5137/1019-5149.jtn.21339-17.2>
PMid:29131235
19. Won S, Kim D, Yang H, Park J, Kwak H, Hu K, et al. Clinical and anatomical approach using Sihler's staining technique (whole mount nerve stain). *Anat Cell Biol*. 2011;44(1):1-7. <https://doi.org/10.5115/acb.2011.44.1.1>
PMid:21519543
20. van Heerden J, Jackson I, Martin J, Fisher J. Surgical technique and pitfalls of breast reconstruction immediately after mastectomy for carcinoma: Initial experience. *Mayo Clinic Proceedings*. 1987;62(3):185-91. [https://doi.org/10.1016/s0025-6196\(12\)62440-9](https://doi.org/10.1016/s0025-6196(12)62440-9)
PMid:3821180
21. Aszmann O, Rab M, Kamolz L, Frey M. The anatomy of the pectoral nerves and their significance in brachial plexus reconstruction. *J Hand Surg Am*. 2000;25(5):942-7. <https://doi.org/10.1053/jhsu.2000.17818>
PMid:11040310
22. Bohórquez D, Shahid R, Erdmann A, Kreger A, Wang Y, Calakos N, et al. Neuroepithelial circuit formed by innervation of sensory enteroendocrine cells. *J Clin Invest*. 2015;125(2):782-6.
PMid:25555217