



# Oral Hard Tissue Lesions: A Radiographic Diagnostic Decision Tree

Hamed Mortazavi<sup>1\*</sup>, Yaser Safi<sup>2</sup>, Somayeh Rahmani<sup>1</sup>, Kosar Rezaiefar<sup>3</sup>

<sup>1</sup>Department of Oral Medicine, School of Dentistry, Shahid Beheshti University of Medical Sciences, Tehran, Iran;

<sup>2</sup>Department of Oral and Maxillofacial Radiology, School of Dentistry, Shahid Beheshti University of Medical Sciences, Tehran, Iran; <sup>3</sup>Department of Oral Medicine, School of Dentistry, Ahvaz Jundishapur University of Medical Sciences, Ahvaz, Iran

## Abstract

**BACKGROUND:** Focusing on history taking and an analytical approach to patient's radiographs, help to narrow the differential diagnoses.

**AIM:** This narrative review article aimed to introduce an updated radiographical diagnostic decision tree for oral hard tissue lesions according to their radiographic features.

**METHODS:** General search engines and specialized databases including PubMed, PubMed Central, Scopus, Embase, EBSCO, ScienceDirect, and authenticated textbooks were used to find relevant topics by means of MeSH keywords such as "jaw diseases," "maxilla," "mandible," "radiolucent," "radiopaque," "odontogenic," "nonodontogenic," "cysts," and "tumors." Related English-language articles published from 1973 to 2020, including reviews, meta-analyses, and original papers (randomized or non-randomized clinical trials; prospective; or retrospective cohort studies), case reports, and case series about oral hard tissue lesions were appraised.

**RESULTS:** In this regard, bony lesions have been classified according to their radiographic pattern (radiolucent, mixed, radiopaque, and rarified), position (periapical, pericoronal and interradicular), margins (well and ill-defined), relation to dentition (with and without dental association), and number (solitary and multiple). In total, 50 entities were organized in the form of a decision tree.

**CONCLUSION:** In this paper, an updated decision tree was proposed to help dental practitioners to make more accurate diagnoses and better treatment plans on the basis of radiographic characteristics.

**Edited by:** Filip Koneski  
**Citation:** Mortazavi H, Safi Y, Rahmani S, Rezaiefar K. Oral Hard Tissue Lesions: A Radiographic Diagnostic Decision Tree. Open Access Maced J Med Sci. 2020 Aug 25; 8(F):180-196. https://doi.org/10.3889/oamjms.2020.4722  
**Keywords:** Radiolucent; Radiopaque; Maxilla; Mandible; Odontogenic; Nonodontogenic  
**\*Correspondence:** Hamed Mortazavi, Department of Oral Medicine, School of Dentistry, Shahid Beheshti University of Medical Sciences, Tehran, Iran. E-mail: hamedmortazavi2013@gmail.com  
**Received:** 02-Apr-2020  
**Revised:** 17-Jul-2020  
**Accepted:** 30-Jul-2020  
**Copyright:** © 2020 Hamed Mortazavi, Yaser Safi, Somayeh Rahmani, Kosar Rezaiefar  
**Funding:** This research did not receive any financial support  
**Competing Interests:** The authors have declared that no competing interests exist  
**Open Access:** This is an open-access article distributed under the terms of the Creative Commons Attribution-NonCommercial 4.0 International License (CC BY-NC 4.0)

## Introduction

Oral pathologies can be generally categorized into two major groups as soft-tissue and hard-tissue lesions. For proper diagnosis of any case in the oral cavity, especially in hard-tissue lesions, radiographs have a very important key role [1]. They enable the dentist to identify many conditions that may otherwise go undetected and to find conditions that cannot be seen clinically [2]. Many lesions that occur in the jawbones have a similar radiographic feature and it is often difficult to distinguish among them [1], [3]. Radiographic evaluation of the central lesion characteristics, which includes location, margin, cortical integrity, density, relation to dentition, effect on surrounding structures, and along with knowledge of clinical data, helps in narrowing the differential diagnosis [1]. Review of the literature showed that some authors have developed guidelines and classifications to help dental practitioners evaluate radiographs more precisely [1], [2], [3]. In this regard, we propose an updated radiographical diagnostic decision tree (Figure 1), this will help clinicians make

more accurate diagnoses and better treatment plans according to the patient's radiographs.

## Methods

### Search strategy

General search engines and specialized databases including PubMed, PubMed Central, Scopus, Embase, EBSCO, ScienceDirect, and authenticated textbooks were used to find relevant topics using MeSH keywords such as "jaw diseases," "maxilla," "mandible," "radiolucent," "radiopaque," "odontogenic," "nonodontogenic," "cysts" and "tumors." Related articles published from 1973 to 2020, including reviews, original papers (randomized or non-randomized clinical trials; and prospective or retrospective cohort studies), case reports, and case series were reviewed. Out of more than 500 articles and textbooks, of which about 200 articles were relevant to the topic. We ultimately included 84 articles and one textbook that were more closely related to the topic of interest. Other papers were excluded due to a lack of full texts, being written in languages other than English or containing repetitive material.

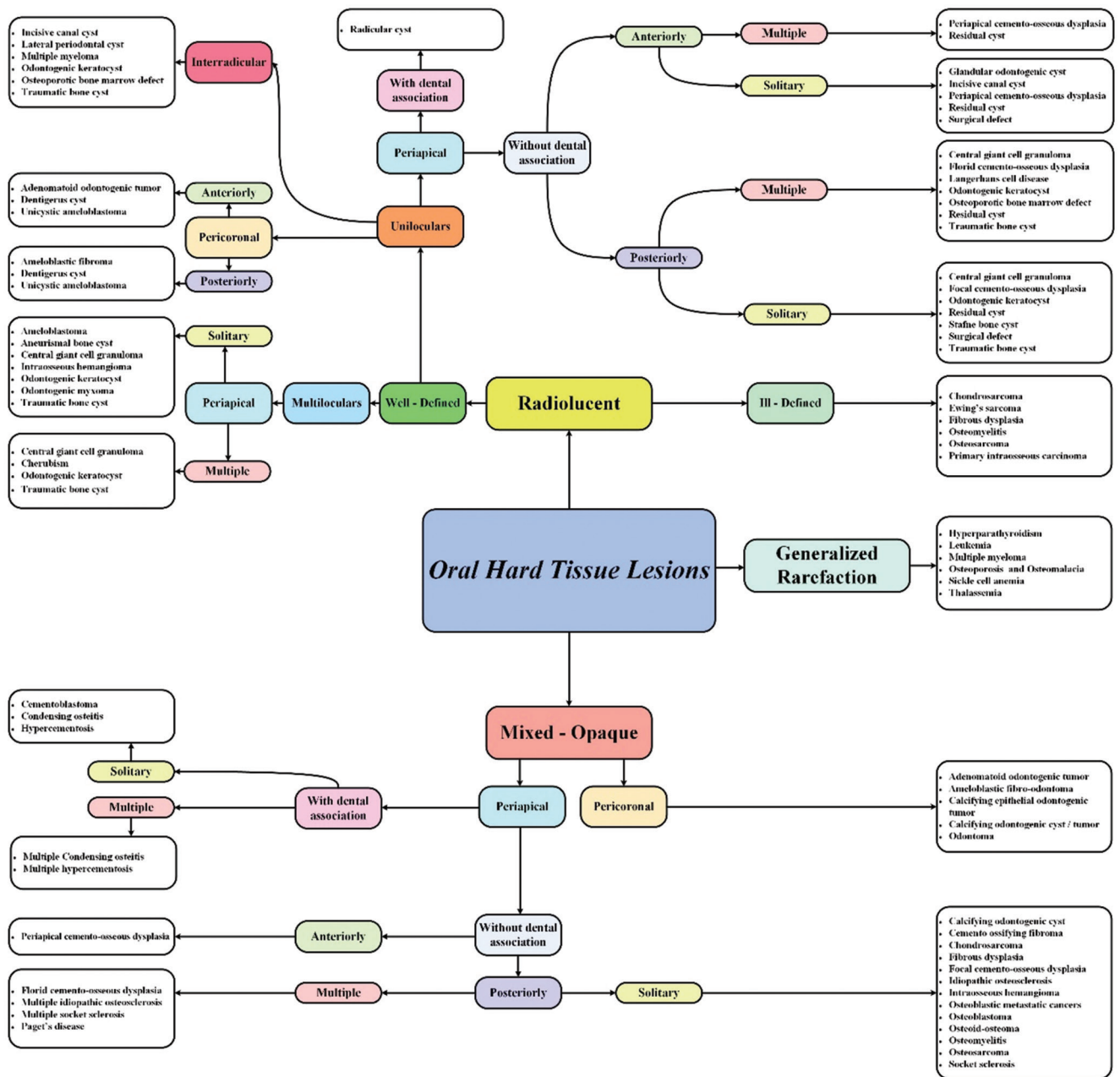


Figure 1: Decision tree of oral hard-tissue lesions

**Results**

In this regard, we described 50 most common oral bony lesions (Table 1), based on their pattern (radiolucent, mixed-opaque, and rarified), position (periapical, pericoronal, and interradicular), margin (well or ill-defined), location (anterior or posterior portion of jaws), dental association (with or without dental association), and number (solitary or multiple).

**• A) Radiolucent lesions**

**A-1-1) Well-defined → Unilocular → Periapical → With dental association**

**• Radicular cyst**

The radicular or periapical cyst/granuloma is the most common odontogenic cyst which is in association with necrotic tooth or faulty root canal therapy [4], [5]. There is a slight sex predilection in men and most cases have been reported in the third and fourth decades of life [5]. It is usually asymptomatic and discovered when the periapical radiograph is taken from a non-vital tooth [5]. Radiographically, it appears as periapical or lateral round to oval well-defined radiolucent lesion with cortical margins [4]. It also can cause expansion, invaginate into the maxillary sinus, or depress the mandibular canal [4].

**A-1-2) Well-defined → Unilocular → Periapical → Without dental association → Anteriorly → Solitary**

**Table 1: Characteristics of oral hard-tissue lesions by alphabetical order**

Entity	Gender predominance	Age predominance (decades)	Common location	Common radiographic feature	Clinical feature
Adenomatoid odontogenic tumor	Female	2	Maxilla	Well-defined mixed lesion	NA*
Ameloblastic fibroma	Male	1 – 2	Mandible	Well-defined radiolucent lesion	Asymptomatic swelling
Ameloblastic fibro-odontoma	Male=Female	1 – 2	Mandible	Well-defined Mixed lesion	Asymptomatic swelling
Ameloblastoma	Male	3 – 5	Mandible	Well-defined radiolucent/mixed lesion	Asymptomatic swelling
Aneurysmal Bone cyst	Male=Female	1 – 2	Mandible	Well-defined Radiolucent lesion	Symptomatic swelling
Calcifying epithelial odontogenic tumor	Female	4 – 5	Mandible	Well-defined mixed lesion	Asymptomatic swelling
Calcifying odontogenic cyst	Male=Female	2 – 6	Mandible	Well-defined Mixed lesion	NA
Cementoblastoma	Female	2 – 3	Mandible	Radiopaque lesion with radiolucent rim	Symptomatic swelling
Cemento-ossifying fibroma	Female	2 – 4	Mandible	Radiolucent/mixed/radiopaque lesion with a radiolucent rim	Asymptomatic swelling
Central giant cell granuloma	Female	1 – 2	Mandible	Well-defined radiolucent lesion	Asymptomatic swelling
Cherubism	Male=Female	2 – 7 years	Mandible and Maxilla	Radiolucent lesion	Asymptomatic swelling
Chondrosarcoma	Female	4 – 7	Maxilla	Ill-defined radiolucent/mixed lesion	Symptomatic swelling
Condensing osteitis	Male=Female	4	Mandible	Well-defined radiopaque lesion	NA
Dentigerous Cyst	Male	2 – 3	Mandible	Well-defined radiolucent lesion	NA
Ewing's sarcoma	Female	15 years	Mandible	Ill-defined radiolucent lesion	Symptomatic swelling
Fibrous dysplasia	Female	1 – 3	Maxilla	Ill-defined radiolucent/mixed lesion	Asymptomatic swelling
Florid cement-osseous dysplasia	Female	4 – 5	Mandible	Radiolucent/mixed/radiopaque lesion with a radiolucent rim	Asymptomatic swelling
Focal cement-osseous dysplasia	Female	4 – 5	Mandible	Radiolucent/mixed/radiopaque lesion with a radiolucent rim	NA
Glandular odontogenic cyst	Male=Female	Middle-aged	Mandible	Well-defined radiolucent lesion	Asymptomatic swelling
Hypercementosis	-	Adult	Mandible	Radiopaque with smooth outline	NA
Hyperparathyroidism	Female	Middle-aged	-	Radiolucent lesion	Symptomatic swelling
Idiopathic osteosclerosis	Female	3	Mandible	Well-defined radiopaque lesion	NA
Incisive canal cyst	Male	4 – 6	Maxilla	Well-defined radiolucent lesion	NA
Intraosseous hemangioma	Female	2 – 5	Mandible	Well/ill-defined radiolucent/mixed lesions	Asymptomatic swelling
Langerhans cell histiocytosis	Male	1 – 2	Mandible	Ill-defined radiolucent lesion	Symptomatic swelling
Lateral periodontal cyst	Male=Female	5 – 7	Mandible	Well-defined radiolucent lesion	Asymptomatic swelling
Leukemia	-	Young	-	Generalized rarefaction	Asymptomatic swelling
Multiple myeloma	Male=Female	40 – 70 years	Mandible	Well-defined radiolucent lesion	Symptomatic swelling
Odontogenic keratocyst	Male	2 – 5	Mandible	Well-defined Radiolucent lesion	NA
Odontogenic myxoma	Female	2 – 3	Mandible	Well-defined Radiolucent lesion	Symptomatic/asymptomatic swelling
Odontoma complex compound	Male=Female	The first two decades	Mandible maxilla	Well-defined radiopaque lesion with radiolucent rim	NA
Osteoblastic Metastatic Cancer	Male=Female	40 – 70 years	Mandible	Ill-defined Radiolucent/ Radiopaque lesion	Symptomatic swelling
Osteoblastoma	Male	2 – 3	Mandible	Mixed with radiolucent rim	Symptomatic swelling
Osteoid osteoma	Female	2 – 3	Mandible	Radiolucent/mixed/radiopaque lesion with a radiolucent rim	Pain
Osteoporotic bone marrow defect	Female	4 – 6	Mandible	Well/ill-defined, radiolucent lesion	NA
Osteomyelitis	Male	Wide age range	Mandible	Ill-defined Mixed lesion	Symptomatic/asymptomatic swelling
Osteoporosis and osteomalacia	Female	50 years	Mandible	Radiolucent lesion	NA
Osteosarcoma	Male=Female	5 – 25 years	Mandible	Ill-defined mixed lesion	Symptomatic swelling
Paget's disease	Male	5 – 6	Maxilla	Radiopaque lesion	Symptomatic swelling
Preapical cement-osseous dysplasia	Females	30 years	Mandible	Radiolucent/mixed/radiopaque lesion with a radiolucent rim	NA
Primary intraosseous carcinoma	Male	6 – 7	Mandible	Ill-define radiolucent lesions	Symptomatic swelling
Radicular cyst	Male	3 – 4	-	Well-defined radiolucent lesion	NA
Residual cyst	Male	3 – 4	Maxilla	Well-defined radiolucent lesion	NA
Sickle cell anemia	-	Childhood	-	Generalized rarefaction	Pain
Socket sclerosis	Male=Female	-	-	Radiopaque lesion	NA
Stafne bone cyst	Male	5 – 6	Mandible	Well-defined radiolucent lesion	NA
Surgical defect	-	-	-	Well-defined radiolucent lesion	NA
Thalassemia	-	Young	-	Generalized rarefaction	Asymptomatic swelling
Traumatic bone cyst	Male	2 – 3	Mandible	Well-defined radiolucent lesion	NA
Unicystic ameloblastoma	Male	2	Mandible	Well-defined radiolucent lesion	Asymptomatic swelling

NA\*: Not Assigned.

### • Glandular odontogenic cyst (GOC)

GOC is a developmental odontogenic cyst [6]. There is no sex predilection and mostly affects middle-aged persons [7]. It presents clinically as a slow-growing, asymptomatic swelling generally occurring in the anterior portion of jaws especially the mandible. Few bilateral cases have been also reported [6]. Radiographically, it represents as an unilocular or multilocular, well-defined radiolucent lesion with scalloped and sclerotic border. Root resorption, tooth displacement, and association with impacted tooth and some lesions such as dentigerous cyst (DC) and lateral periodontal cyst (LPC) have been also found in some cases [7]. In addition to radiographic findings, a clear and low viscosity fluid content on aspiration may be helpful in the diagnosis of GOC [6].

### • Incisive canal cyst (ICC)

ICC is the most common non-odontogenic, developmental cyst, arising from the degeneration of nasopalatine ducts [8]. There is a sex predilection in men with the peak incidence in the fourth to sixth decades of life [8], [9]. It clinically represents an asymptomatic lesion that develops in the midline of anterior maxilla near the incisive foramen [8]. In some cases, patients may suffer from swelling, drainage, and pain [10]. Radiographically, it appears as a well-defined, unilocular, round, oval, and heart-shaped radiolucency with cortical margin in the midline and between the central incisors [8], [9]. Furthermore, tooth displacement, root resorption, nasal septum deviation, thinning, and perforation of the buccal cortical plates have been also reported in some cases [8], [9]. In the large lesions, it might show the roots of the adjacent incisors to be within the cyst cavity; however, the lamina dura is an intact and dental pulp is vital [8].

- *Periapical cement-osseous dysplasia (PCOD)*

PCOD, also known as periapical fibrous dysplasia (FD), is considered as a benign fibro-osseous lesion originated from undifferentiated cells of the periodontal ligament (PDL) tissue [11]. There is a sex predilection in women with age over 30 years [1]. The most affected site in the oral cavity is the anterior portion of the mandible (incisor and canine region) and the teeth involved remain vital [11]. The lesions may be solitary or multiple, asymptomatic and do not involve alteration to the periodontal tissues [11], [12]. Radiographically, in the osteolytic phase, a well-defined radiolucent lesion is seen at the apex of the root; in the cementoblastic stage, the radiolucent lesion assumes a mixed appearance and in the final or mature stage gives rise to a completely radiopaque lesion [1], [11]. During the time, the lesion becomes a calcified mass that can reach 10 cm in diameter and is often surrounded by a radiolucent rim [1], [11].

- *Residual cyst (RC)*

RC is an inflammatory cyst that persists after the removal of its associated tooth [13]. There is sex predilection in men and it is more common in the third to fourth decades of life [4], [13]. The maxilla is more commonly involved than mandible and the lesions usually occur in the alveolar process and body of the jawbones in edentulous areas, it may also be found in lower ramus [13]. It is an asymptomatic lesion and radiographically appears as a well-defined radiolucent lesion with cortical margins. Occasionally, in longstanding lesions, calcified particles may be seen [4], [13]. Furthermore, the same findings to the radicular cyst can be found in the RC [4].

- *Surgical defect*

The surgical defect is a structural alteration that is in association with a surgical procedure, accounts for 3% of all periapical radiolucencies [14]. It is clinically asymptomatic and radiographically represents as a round or oval, well-defined radiolucent lesion with <1 cm in diameter. In 45% of cases, it is completely healed but in 25% of cases, it remains unhealed for a long time [14]. If changing the angle of radiation leads to change the position of the radiolucent lesion around the periapical region, it is demonstrated that the lesion is not periapically, whereas it is located in the buccal or lingual cortical plates such as a surgical defect [14].

**A-1-3) Well-defined → Unilocular →  
Periapical → Without dental association →  
Anteriorly → Multiple**

- PCOD  
(See the section A-1-2).
- RC  
(See the section A-1-2).

**A-1-4) Well-defined → Unilocular →  
Periapical → Without dental association →  
Posteriorly → Solitary**

- *Central giant cell granuloma (CGCG)*

CGCG is a proliferative intra-osseous lesion [4]. There is a slight sex predilection in women with the peak incidence in the first to second decades of life [4], [15]. This entity can be divided into two subgroups as aggressive and non-aggressive. The aggressive type of lesion tends to present in younger patients with more discrepancies [15]. It occurs with a higher frequency in the mandible than maxilla and most cases are found in the anterior portion of the jaws than in the posterior portion [4]. Clinically, it can reach to a swelling >5 cm in diameter and cross the midline in 50% of mandibular cases [4], [15]. Radiographically, it is characterized by a unilocular to multilocular radiolucent lesion with well-defined margins. A stubble granular pattern of calcification has been also reported. In some cases, the septae are located perpendicular to the periphery and creating a honeycomb pattern [4]. CGCG can cause tooth displacement, root resorption, as well as bone perforation [15]. The lamina dura of the teeth within the lesion is usually missing [4], [15].

- *Focal cemento-osseous dysplasia (FCOD)*

FCOD is a benign fibro-osseous lesion with PDL cell origin [10]. It is more frequent in women than men with a peak incidence in the fourth and fifth decades [1], [10]. The majority of cases occur in the periapical area of posterior mandibular teeth with vital pulps or in regions of dental extractions [10], [11]. It is linked to one tooth and causes no symptoms and is detected only on routine radiographic examinations [1], [12]. Radiographically, in the early stage, it is seen as a well-defined radiolucency, in the intermediate stage also is seen as a radiolucent-opaque lesion with a well-defined radiolucent halo and in the late stage, the lesion is characterized by a definite radiopacity surrounded by a uniform radiolucent rim [1], [10]. It is also mentioned that FCOD can be transformed into FCOD and therefore emphasized the importance of recall visits [10].

- *Odontogenic kerato cyst (OKC)*

OKC is an odontogenic cyst representing the third most common cyst of the jaw bones [16]. There is a slight sex predilection in males with a peak incidence in the second and fifth decades of life [17], [18]. More than 80% of cases have been reported in the mandible, especially in the body followed by angle and vertical ramus [17]. Maxillary lesions are most frequently seen between canine and lateral incisor,

and the third molar region [18]. Large size lesions are more common at the angle and ramus of the mandible. OKC can be presented as a periapical, pericoronal, and interradicular lesion [17], [18]. Radiographically, it is characterized by a well-defined unilocular or multilocular radiolucency with smooth or scalloped and often corticated margins. It tends to grow in an anteroposterior direction within the jawbone without causing considerable expansion [17], [18]. In some cases, dystrophic calcifications may develop in long-lasting cysts as radiopaque particles [17].

- RC  
(See the section A-1-2) (Figure 2).

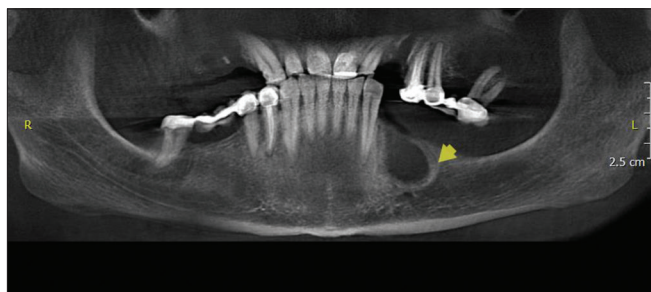


Figure 2: Panoramic reconstructed cone-beam computed radiographic image shows residual cyst; a well-defined radiolucent, unilocular solitary lesion in left mandible in the edentulous area of 34, 35

- *Stafne bone cyst (SBC)*

SBC is an asymptomatic congenital cyst-like bone defect due to entrapment of a glandular tissue portion (submandibular or submental salivary glands) during mandibular development [19], [20]. There is a sex predilection in men with a peak incidence in the fifth and sixth decades of life [19]. Most cases have been detected in the posterior portion of the mandible; however, anterior variant of the disease is usually found periapical, interradicular, or at the previous sites of tooth extraction [19]. Radiographically, it appears as a circumscribed, unilocular, radiolucent lesion with different sizes from 0.5 cm to 2 cm [19], [20].

- Surgical defect  
(See the section A-1-2).

- *Traumatic bone cyst (TBC)*

TBC also known as a simple bone cyst, idiopathic bone cyst, and primary bone cyst is a pseudocyst that mostly occurs in the second and third decades of life and has a slight male predominance or no sex predilection [21], [22]. Clinically, it often presents as an asymptomatic lesion without any bone expansion and most cases have been located in the posterior portion of the mandible [21]. In addition, presence of pain, buccal cortical expansion, and lower lip paresthesia are rare but possible chief complaint of patients with TBC [22]. There is no evidence of tooth mobility and they are barely sensitive to percussion [22]. The mandible is

more affected than maxilla and the majority of cases have been located in the body and symphysis of the mandible [23]. Radiographically, it presents as solitary/multiple, unilocular/multilocular radiolucent lesion with well-defined borders that can be either scalloped or irregular [21], [22] (Figure 3).

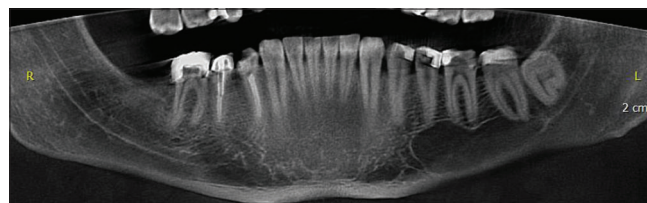

Figure 3: Panoramic reconstructed cone-beam computed radiographic image shows traumatic bone cyst; well-defined radiolucent, posterior unilocular lesion in the left side of the mandible

**A-1-5) Well-defined → Unilocular → Periapical → Without dental association → Posteriori → Multiple**

- CGCG  
(See the section A-1-4).
- Florid cemento-osseous dysplasia (FLCOD)
- FCOD

FLCOD also known as multiple enostosis is a reactive fibro-osseous lesion with PDL cell origin [1]. It is more common in females than males with a peak incidence in the fourth and fifth decades [24]. This entity usually appears as symmetrical, bilateral, asymptomatic, and extensive lesions in all four quadrants of the jaws mostly in the molar and premolar regions [1], [25]. The uncommon clinical symptoms observed are swelling, pain, and local drainage but these are only encountered in cases of secondary infection when the lesions are exposed in the oral cavity [25]. The diagnosis of FLCOD is based on its typical radiographic appearances which are described in three stages as the osteolytic stage (well-defined radiolucent areas), the cementoblastic stage (mixed radiolucent-radiopaque appearance), and osteogenic stage (lobular radiopacity throughout the lesion, and surrounded by a radiolucent rim) [1], [25].

- *Langerhans cell histiocytosis (LCH)*

LCH is a rare hematologic disorder divided into three types [26]. There is a sex predilection in men with the peak incidence in the first to second decades of life, generally, LCH is considered a pediatric disease [27]. The mandible is more affected than maxilla especially in the premolar and molar regions [26]. It appears clinically as uni-focal or multi-focal painful swelling, tooth mobility, gingival enlargement, and mucosal ulcerations [26]. Radiographically, it is characterized by sharply punched out or ill-defined radiolucencies without corticated borders. Alveolar bone involvement may lead to a tooth floating appearance, causing tooth mobility and thereby mimicking the periodontitis feature [26], [27]. Corticosteroid therapy, surgery, and chemotherapy have been suggested as the treatment of choice [26].

- OKC  
(See the section A-1-4).
- Osteoporotic bone marrow defect (OBMD)

OBMD is an osteolytic lesion of the jawbones. There is a sex predilection in women with a peak incidence in the fourth to sixth decades of life [28], [29]. The mandible is affected more than maxilla especially in the premolar/molar region [29]. It is an asymptomatic condition and may be related to some underlying diseases such as sickle cell anemia, rheumatoid arthritis, and osteoporosis [28], [29]. Because most patients had previous root canal therapy in the affected sites, it is noted that NaOCl or Ca(OH)<sub>2</sub> apical extrusion may be an etiologic factor for this defect [29]. Radiographically, it appears as well-defined or ill-defined, unilateral or bilateral, focal or multifocal radiolucencies with different sizes and shapes, they may not be visible on plain X-rays and in some cases, neither on computed tomography [29].

- RC  
(See the section A-1-2).
- TBC  
(See the section A-1-4).

#### A-1-6) Well-defined → Unilocular → Interradicular

- OBMD  
(See the section A-1-5).
- ICC  
(See the section A-1-2) (Figure 4).

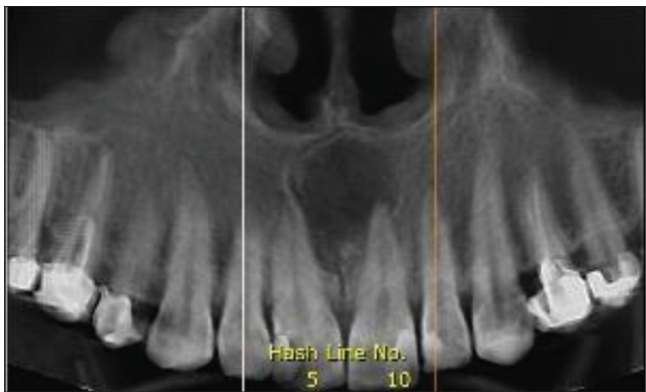


Figure 4: Panoramic reconstructed cone-beam computed radiographic image shows incisive canal cyst; a well-defined radiolucent, anterior unilocular inter-radicular lesion in midline of maxilla

#### • Lateral periodontal cyst (LPC)

LPC is a non-inflammatory, developmental odontogenic cyst, arising on the lateral surface of vital tooth roots [30], [31]. There is no sex predilection and most cases have been reported in the fifth and seven decades of life [31]. It occurs most frequently in the mandibular canine/premolar or maxillary anterior regions [30]. It presents clinically as an asymptomatic gingival swelling on the facial aspect between two teeth [30], [31]. Radiographically, it appears as a round or oval unilocular well-defined radiolucent lesion. This radiographic feature is not pathognomonic for LPC and can resemble an OKC or lateral radicular cyst [31]. Root

resorption, tooth displacement, pain, and expansion have also been reported [31].

#### • Multiple myeloma (MM)

MM is the most commonly affecting patients between the fourth and seventh decades of life. The mandible is involved more frequently than the maxilla and the most common affected sites are the premolar region, angle, and ascending ramus. When the mandible is involved, paresthesia or numbness of the lip, as well as looseness, migration of the teeth and swelling may be complaints. Radiographically, it appears as small, circular, multiple but separate, and well-defined (punched-out) radiolucencies. In advanced cases, it may appear as a generalized rarefaction of the skeleton or as numerous radiolucencies with ill-defined and ragged borders [13].

- OKC  
(See the section A-1-4).
- TBC  
(See the section A-1-4).

#### A-1-7) Well-defined → Unilocular → Pericoronal → Anteriorly

#### • Adenomatoid odontogenic tumor (AOT)

AOT is a benign odontogenic tumor that is more common in women than men with the peak incidence in the second decades of life [17], [32]. The lesions are more prevalent in the maxilla and 90% of them occur in the anterior portion of the jaws [17], [33]. In more than 70% of cases, AOT is in association with an impacted or un-erupted tooth, mostly maxillary canine followed by lateral incisors and mandibular premolars [17]. It is usually asymptomatic and does not exceed 3 cm in diameter and displacement of adjacent teeth may be seen [17], [33]. Radiographically, it frequently looks like a DC and characterized by a corticated circumscribed unilocular radiolucency surrounding an impacted tooth. In addition, internal radiopaque foci develop in two-thirds of cases [17], [32]. Multilocular appearance, bone perforation, ill-defined borders, and root resorption have been reported in few cases [33].

#### • Dentigerous cyst (DC)

DC is the second most common odontogenic cyst after radicular cyst enclosing the crown of an unerupted tooth at the cemento enamel junction [17]. Most of the cases have been found in the second to third decades of life and there is a sex predilection in males [17], [34]. The most frequently affected teeth are the mandibular third molars, followed by the maxillary canines, maxillary third molars, and mandibular second premolars [17]. This lesion is usually asymptomatic and is generally detected by a radiographic examination to find the reason for the delayed eruption [34], [35].

Radiographically, DC typically shows a well-defined unilocular, pericoronal radiolucent area close to an un-erupted tooth. The radiolucent space should be at least 3 to 4 mm in diameter [17]. The relationship between DCs and the crown of the impacted tooth shows three types of radiographic patterns: central, lateral, and circumferential [17]. Displacement of the involved tooth and root resorption of the adjacent erupted tooth have been reported [17], [34], [35].

- *Unicystic ameloblastoma (UA)*

UA is a variant of ameloblastoma, accounts for about 6% of all intraosseous ameloblastomas [36]. There is a sex predilection in men and about 50% of the cases occur in the second decade of life [17], [36]. More than 90% of lesions have been reported in the posterior portion of the mandible, followed by the parasymphysis region, anterior maxilla, and the posterior maxilla [17]. The lesion typically found in association with an impacted mandibular third molar but can be seen also in interradicular, periapical, and edentulous areas as well [36]. It can also arise from other bone lesions such as residual, radicular, and primordial cysts [17]. Radiographically, it presents as unilocular, scalloped macromultilocular, pericoronal, interradicular, or periapical expansive [17], [36]. Cortical perforation and root resorption have been reported in radiographic views of UA [17].

**A-1-8) Well-defined → Unilocular → Pericoronal → Posteriorly**

- *Ameloblastic fibroma (AF)*

AF is a rare, benign slow-growing neoplasm, constitutes 2% of odontogenic tumors [37]. It is reported that this lesion has a propensity to affect men more than women with a peak incidence in the first to second decades of life [17], [37]. The most commonly affected site is the posterior mandible (premolar and molar regions) and 75% of cases are in association with impacted teeth [17]. It presents clinically as a unilateral painless swelling, delayed/failure of tooth eruption, tooth mobility, displacement of the involved teeth, pathological fracture, and paresthesia [37]. Radiographically, it is usually seen as well-defined, corticated, pericoronal radiolucency, and may vary from a small unilocular lesion to an extensive multilocular lesion. Root resorption and expansion of buccal and lingual cortices have also been reported in some cases [17], [37].

- DC  
(See the section A-1-7) (Figure 5).

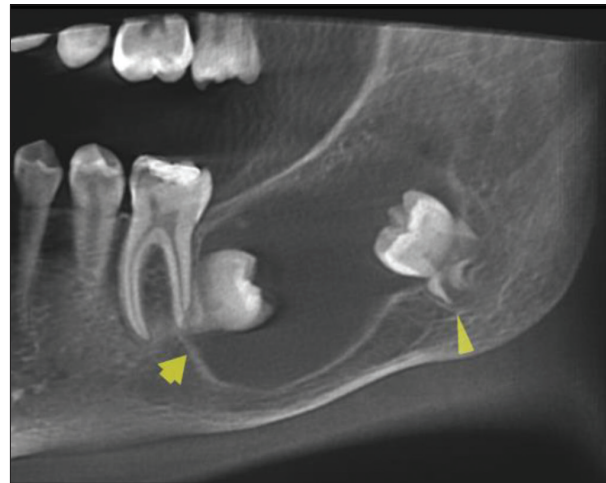


Figure 5: Panoramic reconstructed cone-beam computed radiographic image show dentigerous cyst; a well-defined radiolucent posterior unilocular, pericoronal lesion in the left side of mandible

- UA  
(See the section A-1-7)  
**A-1-9) Well-defined → Multilocular → Periapical → Solitary**

- *Ameloblastoma*

Ameloblastoma is the second most common odontogenic tumor after odontoma [38]. There is a slight sex predilection in men with the peak incidence in the third to fifth decades of life [17]. It presents clinically as a locally aggressive, slow-growing, and painless tumor [38]. More than 80% of cases occur in the mandible and mostly are in association with an un-erupted third molar [17]. Radiographically, it can be a multi or unilocular cyst-like lesion. The lesion varies from radiolucent to mixed, with the presence of coarse and curved bony septae. These septae often make soap-bubble or honeycomb patterns. The margins of the lesion in the mandible are well-defined, occasionally scalloped, and frequently corticated whereas, in the maxilla, the margins are ill-defined because the lesion tends to grow along the bone rather than expanding it. Root resorption, tooth displacement, bone expansion, and perforation have been also reported in some cases [17], [38] (Figure 6).

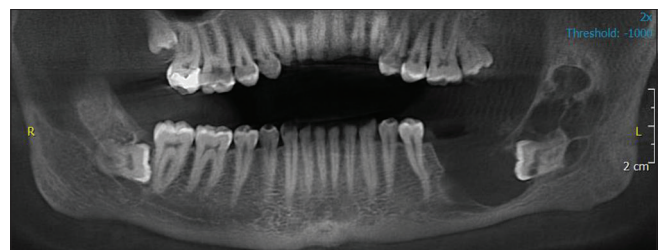


Figure 6: Panoramic reconstructed cone-beam computed radiographic image shows ameloblastoma; a radiolucent, posterior multilocular, periapical lesion in the left side of mandible

- **Aneurismal bone cyst (ABC)**

ABC is a rare pseudocyst filled with blood [4]. There is no sex predilection and most of the patients are in the first to second decades of life [39]. This entity is more common in mandible than maxilla and frequently has been reported in the body of the mandible, followed by mandibular ramus, angle, coronoid process, and condyle [4], [39]. It is clinically represented as a tender, painful, and rapidly growing lesion that causes bone swelling [4]. Their radiographic features may vary from unilocular radiolucency to a “ballooned-out” multilocular radiolucency with a honeycomb or soap-bubble pattern. Aneurysmal bone cysts can cause expansion, destruction, periosteal reaction, root resorption and perforation of bone, and soft-tissue herniation [4], [39].

- CGCG  
(See the section A-1-4).

- **Intraosseous hemangioma (IH)**

IH is a vascular malformation/tumor, comprises about 1% of all bone tumors [40], [41]. There is a sex predilection in women with the peak incidence in the second to fifth decades of life [41]. The mandible is more affected than maxilla especially in the premolar/molar region, some condylar lesions have also been reported [40], [41]. Swelling, tooth mobility, mucosal discoloration at the affected site, massive bleeding after dental extraction, pain and paresthesia of the lip, or mental region are most clinical findings [40], [41], [42]. Radiographically, it can appear as unilocular/multilocular, well-defined/ill-defined, radiolucent/mixed cystic lesions. In addition, honeycomb, soap-bubble, sun-burst, and tennis racket appearances have been reported in some cases [40], [41].

- OKC  
(See the section A-1-4).

- **Odontogenic myxoma (OM)**

OM is an uncommon benign but locally aggressive tumor [43], [44]. It most frequently occurs in the second to third decades of life with a slight sex predilection in women [43]. Clinically, it represents as a painful/painless slow-growing mass, which may cause tooth mobility, bone expansion, paresthesia, and facial distortion [43], [44]. The mandible is more frequently involved than maxilla, especially in the premolar/molar region [44]. It can cross the midline when occurring in the mandible [44]. Radiographically, it is characterized by a well-defined multilocular radiolucency, consisting of fine trabeculae, arranged at right angles, known as “tennis racket” or “step-ladder” pattern. A “sun-ray,” “sun-burst,” “soap bubble,” and “honeycomb” appearances have also been reported [43], [44]. The “honeycomb” appearance seems to be characteristic of mandibular lesions [44].

- TBC  
(See the section A-1-4).

**A-1-10) Well-defined → Multilocular → Periapical → Multiple**

- CGCG  
(See the section A-1-4).

- **Cherubism**

Cherubism is a rare hereditary non-neoplastic bone lesion that affects only the jaw bones that typically appears at the age of 2–7 years [45]. There is no sex predilection and the hallmark of cherubism is the development of symmetrical expansile lesions in the mandible and/or the maxilla that begins to regress with the onset of puberty [23]. Clinically, it is presented as a hard and asymptomatic swelling in the affected areas. In addition, submandibular and upper cervical lymphadenopathy has been also reported [23], [45]. Radiographically, it is characterized by bilateral, multilocular radiolucent lesions in the mandible. Bone lesions generally start at the angle and ascending ramus of the mandible. Involvements of the mandibular body, coronoid process, and mandibular canal displacement have been also found in some cases [45]. Maxillary involvement is rare and less extensive [23], [45]. In mild forms of disease, no treatment is required to regress spontaneously after puberty [23].

- OKC  
(See the section A-1-4).
- TBC  
(See the section A-1-4).

**A-2-1) Ill-Defined**

- **Chondrosarcoma**

Chondrosarcoma is the third most common bone tumor after MM and osteosarcoma [46]. There is a slight sex predilection in women and it may present at any age; however, primarily occurs in the fourth to seventh decades of life [47]. Clinically, it represents as painful or painless swelling associated with loosening of the involved tooth, especially in the maxilla [46]. In the mandibular lesions, paresthesia of the lower lip, as well as tooth mobility, has been also reported [47]. Radiographically, it may mimic osteosarcoma and there is no pathognomonic image finding for this entity [46]. Solitary or multiple radiolucencies with irregular/indistinct borders, ground-glass or sun-ray/sun-burst appearance, uniform widening of the PDL, endosteal scalloping, and bone destruction associated with calcifications may occasionally be present. In tooth-bearing areas, a widened PDL may be noticed as an early sign of chondrosarcoma [46], [47].



- **Ewing's sarcoma (ES)**

ES is the fourth most frequent bone malignancy after MM, osteosarcoma, and chondrosarcoma; it also is the second most common bone tumor in infancy and childhood, after osteosarcoma [48]. Head and neck are affected only in 1–4% of all cases and there is a sex predilection in the female with a mean age of 15 years [48], [49]. Clinically, it usually represents as a symptomatic swelling and it is more common in the mandible than maxilla [48], [49]. Few patients reported conditions of fever, neck adenopathies, tooth mobility, and paresthesia [48], [49]. Radiographically, more than 50% of cases showed an osteolytic, ill-defined lesion with cortical destruction [49].

- **Fibrous Dysplasia (FD)**

FD is a condition that normal bone is replaced with abnormal fibro-osseous tissue [50]. There is a sex predilection in women with the peak incidence in the first to third decades of life [50], [51]. The maxilla is affected 2 times more than mandible and most cases have been located unilaterally in the posterior regions of the jawbones [50]. It clinically appears as a slow-growing painless swelling that may become arrested at a time coinciding with the onset of puberty [51]. Radiographically, it presents as radiolucent, mixed radiolucent-radiopaque, an ill-defined lesion with ground glass, or orange peel appearance [50], [51]. In addition, upward displacement of the mandibular canal has been considered as pathognomonic for this lesion [4].

- **Osteomyelitis (OM)**

OM is an inflammatory process of the medullary portion of the affected bone [52]. The jaw lesions are predominantly seen in the mandible, whereas, the maxilla by virtue of its vascularity and the thin cortical plate is less frequently involved [53]. In the mandible, the most affected site is the body which is followed by the symphysis, angle, ascending ramus, and condyle [52]. There is a sex predilection in men with a wide reported age range [52]. It presents clinically as fever, tenderness, painful/painless swelling, intra-oral/extra-oral fistula, purulent discharge, hypoesthesia/paresthesia, and pathologic fractures [52]. Radiographically, it is typically seen as a mixed radiolucent-radiopaque, ill-defined lesion. Lamination of periosteal new bone and sequestra is characteristic features of OM. Periosteal bone reaction and onion-skin appearance have also been reported [52], [53].

- **Osteosarcoma**

Osteosarcoma is the most common malignant bone tumor after MM; however, it is a rare entity in the

jaw [42], [46]. There is no sex predilection and over 80% of cases occurred in patients between 5 and 25 years, a second peak incidence has been also reported in the fifth and sixth decades of life [46]. Clinically, it is usually represented as a rapidly growing mass and it is more common in the mandible than maxilla [46], [54]. Pain, paresthesia, tooth mobility, and facial asymmetry have been found in some cases [42]. Radiographically, it manifests as an ill-defined mixed radiolucent-radiopaque lesion. A radiopaque lesion with moth-eaten pattern, a codman triangle, sun-burst appearance, (PDL) widening, fusiform, or tube-like widening of the mandibular canal is among other findings of osteosarcoma [42], [46]. The triad of widening of PDL, mandibular canal, and a sunburst appearance are pathognomonic for this phenomenon [42] (Figure 7).

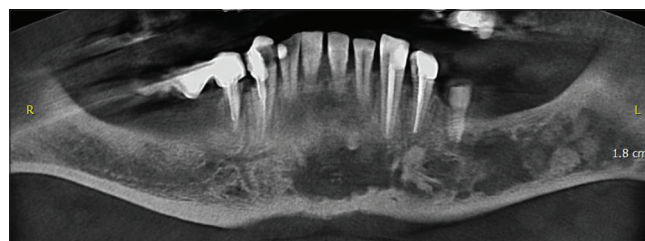


Figure 7: Panoramic reconstructed cone-beam computed radiographic image shows osteosarcoma; a periapical ill-defined lesion in the left side of mandible which crosses the midline and extends to the right

- **Primary intraosseous carcinoma (PIOC)**

PIOC is a unique tumor of the jaws that is classified in four subtypes as follows: (Type 1) PIOC ex-odontogenic cyst, (Type 2a) malignant ameloblastoma, (Type 2b) ameloblastic carcinoma arising *de novo*, ex-ameloblastoma or exodontogenic cyst, and (Type 3) PIOC arising *de novo*: (a) Keratinizing, (b) non-keratinizing types, and (Type 4) intraosseous mucoepidermoid carcinoma [55]. Thomas *et al.* in a pooled analysis of world literature about PIOC reported that majority of PIOC were keratinizing, the tumor affects males more than females with the peak incidence in the sixth or seventh decades of life [56]. The mandible is more affected than maxilla and most cases arise in the posterior portion where remnants of dental lamina can be the source of epithelium. In addition, anterior lesions may have arisen from epithelial remnants in line of fusion of facial processes [55]. Clinically, patients may experience painful swelling, tooth mobility, paresthesia, and numbness, mimicking facial neurological problems [55]. There is no diagnostic feature in radiographs and they usually appear as destructive unilocular, ill-define radiolucent lesions [55], [56].

### **B) Mixed-opaque lesions**

B-1-1) Periapical → With dental association → Solitary

- **Cementoblastoma**

Cementoblastoma is a rare slow-growing, benign odontogenic tumor, accounting for about 6% of all odontogenic tumors [1]. It is predominantly seen in the second to third decades of life and there is a slight sex predilection in women [57]. It occurs most commonly in the premolar/molar region of the mandible and in 50% of cases, mandibular first molar is affected, which remains vital [1], [57], [58]. Patients may experience swelling, pain, jaw deformity, and adjacent tooth displacement [57]. Radiographically, it is presented as a well-defined radiopaque lesion surrounded by a thin, radiolucent rim of non-mineralized tissue, in close association with roots of the involved tooth. Loss of usual outline and obliteration of the PDL are common radiographic features. Attachment of the lesion to the roots of the involved tooth is nearly pathognomonic [1] (Figure 8).

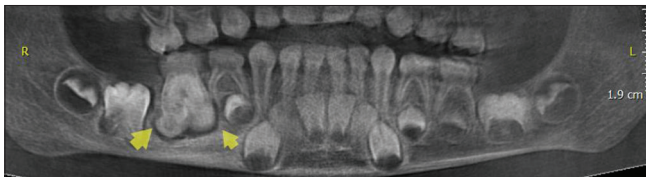

Figure 8: Panoramic reconstructed cone-beam computed radiographic image shows cementoblastoma a posterior periapical opaque lesion in the right side of mandible at the apex of 46 teeth

- **Condensing osteitis (CO)**

CO or chronic focal sclerosing OM is pathologic bone that grows due to mild infection of the dental pulp [59]. It is an asymptomatic lesion that only can be detected on radiographs. There is no sex predilection with the peak incidence in the fourth decade of life [60]. The mandible is more affected than maxilla and it is most commonly localized adjacent to the second premolars (60%), followed by first molars (22%) [60]. Radiographically, it usually appears as a uniform dense well-defined radiopaque lesion near the apex of the necrotic tooth, with the mean distance 5 mm [59], [60]. It can find in different sizes and shapes such as round, irregular, and U-shape [59], [60].

- **Hypercementosis**

Hypercementosis is a phenomenon in which non-neoplastic cementum is deposited along the root portion, affecting one tooth or more and changing dental morphology [61]. It was detected in 1.7% of dental patients and being predominant in adults [61], [62]. Mandibular molars are the most affected teeth, followed by mandibular premolar and maxillary second premolars [61]. Most of the cases are unilateral; however, bilateral involvement is not uncommon [62]. In most cases, it is found as an idiopathic or age-related entity [62]. Radiographically, it is presented as an excessive buildup of cementum around all or part of

a root. The outline of the lesion is usually smooth but in some cases, it can be irregular and the continuity of the lamina dura and PDL space is observed around the lesion [61], [62].

- **B-1-2) Periapical → With dental association → Multiple**

- Multiple CO (See the section B-1-1).
- Multiple hypercementosis (See the section B-1-1).

- **B-1-3) Periapical → Without dental association → Anteriorly**

- PCOD (See the section A-1-2).

- **B-1-4) Periapical → Without dental association → Posteriorly → Solitary**

- **Calcifying odontogenic cyst (COC)**

COC is a benign odontogenic cyst [63]. There is no sex predilection and most cases have been reported in the second and sixth decades of life [17]. The lesion is usually asymptomatic and can occur also in extraosseous regions such as gingival [63]. In general, the mandible is more affected than maxilla; however, a predilection for the upper jaw has been noted in Asians [17], [57]. More than 60% of the lesions have been found to be associated with an impacted tooth, mostly canines [17]. Radiographically, it appears as a well-defined unilocular/multilocular, periapical/pericoronal radiolucency containing small irregular calcified bodies. Dental impaction or displacement, which is more common in the posterior segment of the jaw and root resorption of neighboring teeth have been also reported with some frequency [17].

- **Cemento-ossifying fibroma (COF)**

COF is a progressively growing neoplasm, consisting of fibrous tissue arising from the progenitor cells of the periodontium [1], [64]. There is a sex predilection in women and patients most affected in their second to fourth decades of life [1]. This lesion occurs much more frequently in the premolar/molar region of the mandible [1]. While 50% of all cases are asymptomatic, the growth of the lesion during the time may lead to expansion, facial asymmetry, and dental root displacement [64]. Although the main etiology of this entity is not known, most cases in the literature had a history of trauma in the affected site [64]. Radiographically, lesions in the early stage are small and radiolucent, they become mixed radiolucent-radiopaque and eventually become radiopaque with radiolucent rim [64].

- Chondrosarcoma (See the section A-2-1).
- FD (See the section A-2-1).

- **FCOD**  
(See the section A-1-4) (Figure 9).

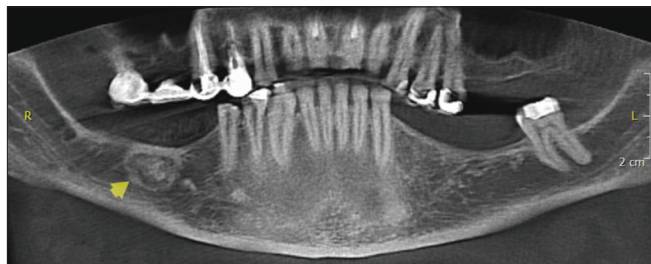


Figure 9: Panoramic reconstructed cone-beam computed radiographic image shows focal cemento-osseous dysplasia; a posterior periapical mixed-opaque lesion in the right side of mandible

- **Idiopathic osteosclerosis (IO)**

IO is known as an intra-osseous anatomic variation that mostly found in routine radiographic evaluations [60]. There is a sex predilection in women with the peak incidence in the third decade of life [60], [65]. The mandible is more affected than maxilla and most cases have been detected in the premolar/molar region, at the periapical, inter radicular, away from the teeth, and in edentulous areas [65]. Radiographically, it usually appears as well-defined radiopaque areas with different sizes, mostly round or ovoid in shape but sometimes irregular. In some cases, it can be similar to a residual root [60], [65].

- **IH**  
(See the section A-1-9).

- **Osteoblastic metastatic cancers (MCs)**

MCs to the maxillofacial region are uncommon and may occur in the soft or hard tissues [66]. There is no sex predilection in jawbone metastases and generally, they are seen in patients between 40 and 70 years, in younger patients metastases are more common in jawbones than soft tissues [66], [67]. The mandible is more affected than maxilla especially in the premolar/molar region [66], [67].

The clinical manifestations of this phenomenon are included a bone swelling with tenderness, pain, hemorrhage, ulcer, paresthesia, and pathological fractures [66]. The breast, prostate, thyroid gland, kidney, and lungs are the most common primary sites for tumors that metastasize to the jawbones [66], [67]. Radiographically, it represents the absence of any manifestations to radiolucent or opaque lesion with ill-defined margins [66], [67]. Metastases from prostate cancer are osteoblastic whereas, bone metastases from kidney, lung, and breast are more often osteolytic [66].

- **Osteoblastoma**

Osteoblastoma is a rare benign tumor that accounts for about 1% of all bone tumors [68]. Patients in the second to third decades of life are most commonly

affected and there is a sex predilection in men [1]. The involvement of mandible, especially the posterior segments, is more common than maxilla [1], [69]. Clinically, it is characterized by swelling, mild pain, and cortical expansion [1]. The size of the lesion does not usually exceed 4 cm in diameter and the pain does not relieve by aspirin or other nonsteroidal anti-inflammatory drugs [1]. A solitary mixed radiolucent-radiopaque circumscribed lesion is a common radiographic feature for osteoblastoma [1], [69]. The presence of a radiolucent rim or halo around the lesion has been also reported [1].

- **Osteoid osteoma (OO)**

OO is a low growth neoplasm of bone accounting for <1% in the jaws [70], [71]. It is more frequent in women than men and mostly observed in the second to third decades of life [1], [64]. Clinically, patients usually experience a dull, throbbing, intermittent, local, and nocturnal pain in the involved bone that alleviated by nonsteroidal anti-inflammatory drugs [1]. It can involve a single bone or several bones. The mandible is more affected than maxilla and the lingual surface and lower border of the body are the most common locations of the lesions [71]. The diagnosis of this phenomenon usually is obtained by radiographs confirmed by histopathological analysis [70]. Radiographically, it is described as a small radiolucent intracortical nidus, <1 cm in diameter, surrounded by a large, dense sclerotic zone of cortical thickening [71]. In the late stages mixed or high-density appearance can be detected in some cases. The presence of periosteal reaction and radiolucent rim around the mixed or radiopaque OO has been also reported [1].

- **OM**  
(See the section A-2-1).
- **Osteosarcoma**  
(See the section A-2-1).

- **Socket sclerosis (SS)**

SS is an abnormal bone healing after dental extraction, occurs in 2.7% of cases [72]. There is no sex predilection and it is characterized by deposition of sclerotic bone within the confines of lamina dura with a characteristic pattern [72], [73]. Radiographically, the density of the sclerotic bone is similar to the root dentin and the central area potentially mimics a root canal. At this point in the healing process, the dentist may be erroneously accused of having failed to extract the root [73]. It is demonstrated that this phenomenon can be related to some systemic diseases such as renal failure and digestive problems [72].

**B-1-5) Periapical → Without dental association → Posteriorly → Multiple**

- **FLCOD**  
(See the section A-1-5).
- **Multiple IO**  
(See the section B-1-4).

- Multiple SS  
(See the section B-1-4).

- *Paget's disease (PD)*

PD is a chronic progressive bone disorder [74]. There is a sex predilection in men with peak incidence in the fifth to sixth decades of life [74], [75]. Facial disfigurement may be a consequence of the enlargement of the maxilla and/or mandible; however, the maxilla is affected twice more than the mandible [74]. It usually presents as maxillofacial bone enlargement, pain, widened alveolar ridge, flattened palate, tooth mobility, tooth migration, poor healing in affected sites, excessive post-surgical bleeding, OM, and various infections [74]. Radiographically, in the early stage, it is characterized as a ground glass trabecular pattern, and with progression, diffuse sclerosis is seen as the cotton wool appearance of opacification [74], [75]. Other radiographic findings are also included a loss of lamina dura, root resorption, pulpal calcification, and hypercementosis [75]. It is mentioned that viral infection and Vitamin D deficiency in children may express later as PD [75].

### B-2-1) Pericoronal

- AOT  
(See the section A-1-7).

- *Ameloblastic fibro-odontoma (AFO)*

AFO is a benign mixed odontogenic tumor [76]. There is no sex predilection and this entity usually is seen in the first and second decades of life, which might also be a characteristic of the lesion [77]. It is clinically represented as an asymptomatic swelling, delayed tooth eruption and displacement of adjacent teeth [76], [77]. They are more frequent in the posterior areas of the mandible and the involved tooth is often displaced in an apical position, which demonstrated that the origin of the lesion is above the tooth [17], [76]. Radiographically, it presents as a well-defined unilocular or infrequently multilocular radiolucency containing various amounts of radiopaque material [17], [36], [76]. The malignant transformation of AFO into ameloblastic fibro-sarcoma has been reported, which can change the clinical and radiographical features of this entity [17].

- *Calcifying epithelial odontogenic tumor (CEOT)*

CEOT or Pindborg tumor is a benign, locally aggressive odontogenic neoplasm [78]. The lesions are more common in women than men with the peak incidence in the fourth to fifth decades of life [17]. The most frequent location of the lesion is the mandibular premolar/molar region and half of the cases are associated with an impacted tooth, mostly the

mandibular third molar or an odontoma [17], [79]. It is usually characterized by a pericoronal radiolucency, as well as radiolucent areas with diffuse opacities [17], [78]. A mixed well-defined, radiolucent-radiopaque pattern is the most common form of the lesion, followed by radiolucent and completely radiopaque cases [17]. Unilocular radiolucencies are more frequent in the maxilla than in the mandible and maxillary lesions might be more aggressive [78]. The appearance of radiopacities close to the crown of an un-erupted tooth has been mentioned as the most characteristic and pathognomonic feature in this entity [17]. In some cases, small, thin, and opaque trabeculae may cross the radiolucency in many directions [17]. Malignant transformation has been reported in some cases between 40 and 83 years [79].

- COC  
(See the section B-1-4).

- *Odontoma*

Odontoma is the most frequent benign odontogenic tumor, accounting for 67% of jaw tumors and divided into two subgroups as complex and compound odontoma [1], [80]. There is no sex predilection and mostly manifests during the first two decades of life [80], [81]. Compound odontoma is more common than complex odontoma and is frequently seen in the anterior maxilla, whereas complex odontoma is seen most commonly in the posterior mandible, where it appears as a pericoronal lesion around un-erupted teeth or as an inter-radicular lesion [80]. Clinically, they are asymptomatic lesions that are associated with altered tooth eruption in the permanent or primary dentition [1]. Radiographically, compound odontomas present as well-defined lesion containing radiodense foci with a radiolucent rim. Several follicular structures contain denticles, which are separated by fibrous septae. However, in complex odontoma, opaque foci present as a haphazard mass with no similarity to dental structure [1] (Figure 10).

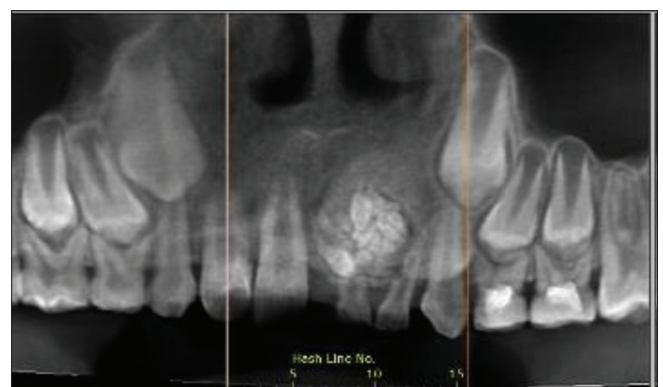


Figure 10: Panoramic reconstructed cone-beam computed radiographic image show odontoma; a pericoronal mixed-opaque lesion in anterior of maxilla

### C) Generalized rarefaction

- *Hyperparathyroidism (HPT)*

HPT is an endocrinopathy with excessive secretion of parathyroid hormone [82]. There is a sex predilection in women and usually seen in middle-aged people [82], [83]. In the oral cavity, it represents as pain, swelling, tooth mobility, drifting of tooth, sensitive teeth in mastication and percussion, developmental dental anomalies, soft-tissue calcifications, alteration in dental eruption, and facial deformity [82], [83]. Malocclusion with definite spacing of the teeth may be one of the first signs of disease [83]. Radiography, it is characterized by generalized rarefaction of the jawbone, ground glass appearance, floating teeth appearance, reduction of lamina dura, pulp stones, pulp chamber narrowing, lytic bone cysts (brown tumors), and loss of cortical thickness at the angle and inferior border of the mandible [83].

- *Leukemia*

Leukemia is a malignancy of the hematopoietic tissue that occurs primarily in young persons. The patient may exhibit pallor and weakness, as well as petechiae or ecchymoses in the mucous membrane or skin. Leukemic infiltration of the oral soft tissues may produce swelling of the palate and other regions of the jaws. Radiographic changes: Delayed or incomplete formation of tooth crowns and roots, destruction of cortices of the tooth crypts, enlargement of the crypts, rapid tooth eruption, and osteoporosis with the destruction of the apical portion of the cortex around the distal crypt of the developing mandibular molar [13].

- MM  
(See the section A-1-6).

- *Osteoporosis and osteomalacia*

Osteoporosis is a common metabolic disease characterized by low bone mass and density. It affects one in three women and one in four men over the age of 50 years [84]. In the maxillofacial region, the mandibular cortical bone undergoes resorptive activity in osteoporotic patients, leading to decreased thickness, deformity and more porous inferior border, characteristics that can be determined by panoramic radiographs [84]. The same bone changes can be seen in osteomalacia. Osteomalacia is a disease of bone caused by Vitamin D3 deficiency and most patients with this problem experience bone pain and muscle weakness [85]. These diseases radiographically appear as reduced bone opacity and pseudofractures. An increase in mandibular angle and maxillary micrognathia have been reported [85]. Periodontal disease and aplasia/hypoplasia of cementum have been also reported in these patients [85].

- *Sickle cell anemia*

Sickle cell anemia is a hereditary blood disease. The manifestations usually appear early in childhood. Oral pain occurs in sickle cell patients and is not related to common dental problems. Oral ulcers may also be present, particularly on the gingival. Radiographically, it is characterized by reduced in the number of trabeculae, coarsened and sharply defined trabeculae, presence of horizontal trabeculae between the teeth roots (stepladder appearance), generalized jawbone rarefaction, thinning of the inferior border of the mandible, and the alveolar crestal cortex may be observed [14].

- *Thalassemia*

Thalassemia is recognized as a blood disorder that occurs primarily in young persons, mostly in the first 2 years of life. The most common clinical presentations are included as pallor, weakness, severe anemia, irritability, and lethargy. Patients with the minor type of the disease are usually asymptomatic or have barely perceptible symptoms. In severe cases, the maxillary bone enlargements resulting in prominent cheek bones and anterior displacement of the incisors produce a characteristic "rodent" faces. On radiographs, the cortices may be thinned and the tooth roots may be short and spike-shaped. There is a generalized rarefaction, and occasionally a honeycomb pattern is seen throughout the jaws. In addition, the sinus hypoplasia has been mentioned as pathognomonic of thalassemia [14].

## Discussion

Any jaw lesions should be evaluated taking into consideration the following radiographical presentations:

Density, locularity, and borders: Jaw lesions can be explained as having a radiolucent, mixed, opaque or rarified appearance, relative to the density of the adjacent normal bone (Figure 1). More than 80% of bony lesions are radiolucent [2]. In terms of internal pattern, the lesions can be uni- or multi-locular. Unilocular and multilocular with well-defined borders indicate benign and benign with locally aggressive natures, respectively. In addition, mixed or radiopaque lesions with well-defined margins usually represent a benign or inflammatory process. In general, lesions with well-defined borders have a benign nature whereas; those with ill-defined borders represent the locally aggressive, inflammatory, or neoplastic phenomena. Mixed or opaque lesions can be related to metabolic abnormalities, inflammatory process, fibro-osseous entities, or less commonly malignant disorders. Rarified appearance is also related to a systemic disease such as endocrinopathies or blood dyscrasias [2], [3].

Specific location and relation to dentition: Certain lesions have a predilection for a particular position whereas others can occur anywhere in the jaw. Lesions below the mandibular canal are likely to be non-odontogenic such as SBC but the lesions over it is usually odontogenic in nature such as radicular cyst. Non-odontogenic lesions have no relationship to the dentition whereas odontogenic lesions typically involve teeth or a specific part of the tooth such as DC [2], [3].

Cortical integrity and periosteal reaction: Slow-growing lesions are usually benign and cause expansion with cortical bowing while cortical perforation without noticeable expansion denotes infected or malignant lesions, for example, infected odontogenic cysts or intraosseous carcinomas. The presence of periosteal reaction is also suggestive of an inflammatory or malignant process such as chronic OM or osteosarcoma [2], [3].

Effect on surrounding structures: Tooth displacement is usually related to a benign lesion. Lesions that are over the crown of the tooth can displace it apically and those are in the ramus such as cherubism may push the tooth in the anterior direction. Root resorption can occur in chronic, slow-growing benign lesions, however, malignant lesions also occasionally resorb teeth. PDL widening, inferior alveolar nerve canal widening, and displacement should also be mentioned in differential diagnosis such as malignancies, vascular, and neural lesions [4], [42].

## Conclusion

This updated radiographical diagnostic decision tree allows dental practitioners to narrow the differential diagnosis and arrives at the most probable diagnosis through a systematic approach.

## References

- Mortazavi H, Baharvand M, Rahmani S, Jafari S, Parvaei P. Radiolucent rim as a possible diagnostic aid for differentiating jaw lesions. *Imaging Sci Dent.* 2015;45(4):253-61. <https://doi.org/10.5624/isd.2015.45.4.253> PMID:26730374
- Neyaz Z, Gadodia A, Gamanagatti S, Mukhopadhyay S. Radiographical approach to jaw lesions. *Singapore Med J.* 2008;49(2):165-77.
- George G, Padiyath S. Unicystic jaw lesions: A radiographic guideline. *J Indian Acad Oral Med Radiol.* 2010;22:S31-6. <https://doi.org/10.5005/jp-journals-10011-1065>
- Mortazavi H, Baharvand M, Safi Y, Behnaz M. Common conditions associated with displacement of the inferior alveolar nerve canal: A radiographic diagnostic aid. *Imaging Sci Dent.* 2019;49(2):79-86. <https://doi.org/10.5624/isd.2019.49.2.79> PMID:31281784
- Narula H, Ahuja B, Yeluri R, Baliga S, Munshi AK. Conservative non-surgical management of an infected radicular cyst. *Contemp Clin Dent.* 2011;2(4):368-71. <https://doi.org/10.4103/0976-237x.91806> PMID:22346170
- Shah AA, Sangle A, Bussari S, Koshy AV. Glandular odontogenic cyst: A diagnostic dilemma. *Indian J Dent.* 2016;7(1):38-43. <https://doi.org/10.4103/0975-962x.179371> PMID:27134453
- Ferreira JC, Vêncio EF, de Sá RT, Gasperini G. Glandular odontogenic cyst in dentigerous relationship: An uncommon case report. *Case Rep Dent.* 2019;2019:8647158. <https://doi.org/10.1155/2019/8647158> PMID:31355014
- Ahmad A, Tadinada A. Evaluation of incisive canal cysts: 2-D vs 3-D imaging. Have we learnt anything new? *Oral Surg Oral Med Oral Pathol Oral Radiol.* 2019;128(4):e163. <https://doi.org/10.1016/j.oooo.2019.01.034>
- Dedhia P, Dedhia S, Dhokar A, Desai A. Nasopalatine duct cyst. *Case Rep Dent.* 2013;2013:869516. <https://doi.org/10.1155/2013/869516> PMID:24307954
- Bhandari R, Sandhu SV, Bansal H, Behl R, Bhullar RK. Focal cemento-osseous dysplasia masquerading as a residual cyst. *Contemp Clin Dent.* 2012;3 Suppl 1:S60-2. <https://doi.org/10.4103/0976-237x.95107> PMID:22629069
- Roghi M, Scapparone C, Crippa R, Silvestrini-Biavati A, Angiero F. Periapical cemento-osseous dysplasia: Clinico pathological features. *Anticancer Res.* 2014;34(5):2533-6. PMID:24778071
- Brody A, Zalathnai A, Csomo K, Belik A, Dobo-Nagy C. Difficulties in the diagnosis of periapical translucencies and in the classification of cemento-osseous dysplasia. *BMC Oral Health.* 2019;19(1):139. <https://doi.org/10.1186/s12903-019-0843-0> PMID:31291935
- Sridevi K, Nandan SR, Ratnakar P, Srikrishna K, Pavani BV. Residual cyst associated with calcifications in an elderly patient. *J Clin Diagn Res.* 2014;8(2):246-9. PMID:24701547
- Wood NK, Goaz PW. *Differential Diagnosis of Oral and Maxillofacial Lesions.* 5<sup>th</sup> ed. St Louis: Mosby-Year Book Inc.; 1997.
- Wang Y, Le A, El Demellawy D, Shago M, Odell M, Johnson-Obaseki S. An aggressive central giant cell granuloma in a pediatric patient: Case report and review of literature. *J Otolaryngol Head Neck Surg.* 2019;48(1):32. <https://doi.org/10.1186/s40463-019-0356-5> PMID:31319877
- Alves DB, Tuji FM, Alves FA, Rocha AC, Santos-Silva AR, Vargas PA, et al. Evaluation of mandibular odontogenic keratocyst and ameloblastoma by panoramic radiograph and computed tomography. *Dentomaxillofac Radiol.* 2018;47(7):20170288. <https://doi.org/10.1259/dmfr.20170288> PMID:29791200
- Mortazavi H, Baharvand M. Jaw lesions associated with impacted tooth: A radiographic diagnostic guide. *Imaging Sci Dent.* 2016;46(3):147-57. <https://doi.org/10.5624/isd.2016.46.3.147> PMID:27672610
- Borghesi A, Nardi C, Giannitto C, Tironi A, Maroldi R, Di Bartolomeo F, et al. Odontogenic keratocyst: Imaging features of a benign lesion with an aggressive behaviour. *Insights Imaging.* 2018;9(5):883-97. <https://doi.org/10.1007/s13244-018-0644-z>

- PMid:30066143
19. Shokri A, Baharvand M, Mortazavi H. Is cone-beam computed tomography diagnostic for anterior Stafne bone cyst: Report of a rare case? *Dent Hypotheses*. 2015;6(1):31-3. <https://doi.org/10.4103/2155-8213.150872>
  20. Lee JI, Kang SJ, Jeon SP, Sun H. Stafne bone cavity of the mandible. *Arch Craniofac Surg*. 2016;17(3):162-4. <https://doi.org/10.7181/acfs.2016.17.3.162>  
PMid:28913275
  21. Kumar LK, Kurien N, Thaha KA. Traumatic bone cyst of mandible. *J Maxillofac Oral Surg*. 2015;14(2):466-9. <https://doi.org/10.1007/s12663-010-0114-8>  
PMid:26028875
  22. Razmara F, Ghoncheh Z, Shabankare G. Traumatic bone cyst of mandible: A case series. *J Med Case Rep*. 2019;13(1):300. <https://doi.org/10.1186/s13256-019-2220-7>  
PMid:31530284
  23. Papadaki ME, Lietman SA, Levine MA, Olsen BR, Kaban LB, Reichenberger EJ. Cherubism: Best clinical practice. *Orphanet J Rare Dis*. 2012;7 Suppl 1:S6. <https://doi.org/10.1186/1750-1172-7-s1-s6>  
PMid:22640403
  24. Das BK, Das SN, Gupta A, Nayak S. Florid cemento-osseous dysplasia. *J Oral Maxillofac Pathol*. 2013;17(1):150. <https://doi.org/10.4103/0973-029x.110735>  
PMid:23798858
  25. Daviet-Noual V, Ejeil AL, Gossiome C, Moreau N, Salmon B. Differentiating early stage florid osseous dysplasia from periapical endodontic lesions: A radiological-based diagnostic algorithm. *BMC Oral Health*. 2017;17(1):161. <https://doi.org/10.1186/s12903-017-0455-5>  
PMid:29284472
  26. Nangalia R, Chatterjee RP, Kundu S, Pal M. Langerhans cell histiocytosis in an adult with oral cavity involvement: Posing a diagnostic challenge. *Contemp Clin Dent*. 2019;10(1):154-7. [https://doi.org/10.4103/ccd.ccd\\_432\\_18](https://doi.org/10.4103/ccd.ccd_432_18)  
PMid:32015659
  27. Islinger RB, Kuklo TR, Owens BD, Horan PJ, Choma TJ, Murphey MD, *et al*. Langerhans' cell histiocytosis in patients older than 21 years. *Clin Orthop Relat Res*. 2000;379:231-5. <https://doi.org/10.1097/00003086-200010000-00027>  
PMid:11039811
  28. Ida-Yonemochi H, Tanabe Y, Ono Y, Murata M, Saku T. Focal osteoporotic bone marrow defects associated with a cystic change of the maxilla: A possible histopathogenetic background of simple bone cyst. *Oral Med Pathol*. 2010;15:35-8. <https://doi.org/10.3353/omp.15.35>
  29. Simancas-pallares M, Arevalo-tovat L, Marincola M. Focal osteoporotic bone marrow defects on dental implant treated patients: A 5-year period prevalence study. *Int J Odontostomatol*. 2016;10(1):23-8. <https://doi.org/10.4067/s0718-381x2016000100005>
  30. Ramalingam S, Alrarrayes YF, Almutairi KB, Bello IO. Lateral periodontal cyst treated with enucleation and guided bone regeneration: A report of a case and a review of pertinent literature. *Case Rep Dent*. 2019;2019:4591019. <https://doi.org/10.1155/2019/4591019>
  31. Meseli SE, Agrali OB, Peker O, Kuru L. Treatment of lateral periodontal cyst with guided tissue regeneration. *Eur J Dent*. 2014;8(3):419-23. <https://doi.org/10.4103/1305-7456.137661>  
PMid:25202227
  32. Vasudevan K, Kumar S, Vijayasamundeeswari, Vigneswari S. Adenomatoid odontogenic tumor, an uncommon tumor. *Contemp Clin Dent*. 2012;3(2):245-7. <https://doi.org/10.4103/0976-237x.96837>  
PMid:22919236
  33. Chrcanovic BR, Gomez RS. Adenomatoid odontogenic tumor: An updated analysis of the cases reported in the literature. *J Oral Pathol Med*. 2019;48(1):10-6. <https://doi.org/10.1111/jop.12783>  
PMid:30256456
  34. Demiriz L, Misir AF, Gorur DI. Dentigerous cyst in a young child. *Eur J Dent*. 2015;9(4):599-602. <https://doi.org/10.4103/1305-7456.172619>  
PMid:26929702
  35. Ghandour L, Bahmad HF, Bou-Assi S. Conservative treatment of dentigerous cyst by marsupialization in a young female patient: A case report and review of the literature. *Case Rep Dent*. 2018;2018(2):7621363. <https://doi.org/10.1155/2018/7621363>
  36. Agani Z, Hamiti-Krasniqi V, Recica J, Loxha MP, Kurshumliu F, Rexhepi A. Maxillary unicystic ameloblastoma: A case report. *BMC Res Notes*. 2016;9(1):469. <https://doi.org/10.1186/s13104-016-2260-7>  
PMid:27756334
  37. Carroll C, Gill M, Bowden E, O'Connell JE, Shukla R, Sweet C. Ameloblastic fibroma of the mandible reconstructed with autogenous parietal bone: Report of a case and literature review. *Case Rep Dent*. 2019;2019:5149219. <https://doi.org/10.1155/2019/5149219>
  38. Effiom OA, Ogundana OM, Akinshipo AO, Akintoye SO. Ameloblastoma: Current etiopathological concepts and management. *Oral Dis*. 2018;24(3):307-16. <https://doi.org/10.1111/odi.12646>  
PMid:28142213
  39. Devi P, Thimmarasa V, Mehrotra V, Agarwal M. Aneurysmal bone cyst of the mandible: A case report and review of literature. *J Oral Maxillofac Pathol*. 2011;15(1):105-8. <https://doi.org/10.4103/0973-029x.80014>  
PMid:21731290
  40. Dereci O, Acikalin MF, Ay S. Unusual intraosseous capillary hemangioma of the mandible. *Eur J Dent*. 2015;9(3):438-41. <https://doi.org/10.4103/1305-7456.163236>  
PMid:26430377
  41. Dhiman NK, Jaiswara C, Kumar N, Patne SC, Pandey A, Verma V. Central cavernous hemangioma of mandible: Case report and review of literature. *Natl J Maxillofac Surg*. 2015;6(2):209-13. <https://doi.org/10.4103/0975-5950.183866>  
PMid:27390499
  42. Mortazavi H, Baharvand M, Safi Y, Dalaie K, Behnaz M, Safari F. Common conditions associated with mandibular canal widening: A literature review. *Imaging Sci Dent*. 2019;49(2):87-95. <https://doi.org/10.5624/isd.2019.49.2.87>  
PMid:31281785
  43. Gupta S, Grover N, Kadam A, Gupta S, Sah K, Sunitha JD. Odontogenic myxoma. *Natl J Maxillofac Surg*. 2013;4(1):81-3. <https://doi.org/10.4103/0975-5950.117879>  
PMid:24163558
  44. Shivashankara C, Nidoni M, Patil S, Shashikala KT. Odontogenic myxoma: A review with report of an uncommon case with recurrence in the mandible of a teenage male. *Saudi Dent J*. 2017;29(3):93-101. <https://doi.org/10.1016/j.sdentj.2017.02.003>  
PMid:28725126
  45. Deshmukh R, Joshi S, Deo PN. Nonfamilial cherubism: A case report and review of literature. *J Oral Maxillofac Pathol*. 2017;21(1):181. <https://doi.org/10.4103/0973-029x.203791>  
PMid:28479714
  46. Mortazavi H, Baharvand M. Review of common conditions associated with periodontal ligament widening. *Imaging Sci Dent*. 2016;46(4):229-37. <https://doi.org/10.5624/isd.2016.46.4.229>

- PMid:28035300
47. Sammartino G, Marenzi G, Howard CM, Minimo C, Trosino O, Califano L, et al. Chondrosarcoma of the jaw: A closer look at its management. *J Oral Maxillofac Surg.* 2008;66(11):2349-55. <https://doi.org/10.1016/j.joms.2006.05.069>  
PMid:18940505
  48. Margaix-Muñoz M, Bagán J, Poveda-Roda R. Ewing sarcoma of the oral cavity. A review. *J Clin Exp Dent.* 2017;9(2):e294-301. <https://doi.org/10.4317/jced.53575>  
PMid:28210452
  49. Casaroto AR, DA Silva Sampieri MB, Soares CT, DA Silva Santos PS, Yaedu RY, Damante JH, et al. Ewing's sarcoma family tumors in the jaws: Case report, immunohistochemical analysis and literature review. *In Vivo.* 2017;31(3):481-91. <https://doi.org/10.21873/invivo.11087>  
PMid:28438883
  50. Yang HY, Su BC, Hwang MJ, Lee YP. Fibrous dysplasia of the anterior mandible: A rare case report. *Ci Ji Yi Xue Za Zhi.* 2018;30(3):185-7. [https://doi.org/10.4103/tcmj.tcmj\\_57\\_18](https://doi.org/10.4103/tcmj.tcmj_57_18)  
PMid:30069129
  51. Ogunsalu C, Smith NJ, Lewis A. Fibrous dysplasia of the jaw bone: A review of 15 new cases and two cases of recurrence in Jamaica together with a case report. *Aust Dent J.* 1998;43(6):390-4. <https://doi.org/10.1111/j.1834-7819.1998.tb00198.x>  
PMid:9973707
  52. Gudmundsson T, Torkov P, Thygesen T. Diagnosis and treatment of osteomyelitis of the jaw—a systematic review (2002-2015) of the literature. *J Dent Oral Disord.* 2017;3(4):1066.
  53. Koobusch GF, Deatherage JR, CuréJK. How can we diagnose and treat osteomyelitis of the jaws as early as possible? *Oral Maxillofac Surg Clin North Am.* 2011;23(4):557-67. <https://doi.org/10.1016/j.coms.2011.07.011>  
PMid:21982609
  54. Babazade F, Mortazavi H, Jalalian H. Bilateral metachronous osteosarcoma of the mandibular body: A case report. *Chang Gung Med J.* 2011;34 Suppl 6:66-9.  
PMid:22490463
  55. Sengupta S, Vij H, Vij R. Primary intraosseous carcinoma of the mandible: A report of two cases. *J Oral Maxillofac Pathol.* 2010;14(2):69-72. <https://doi.org/10.4103/0973-029x.72504>  
PMid:21731266
  56. Thomas G, Pandey M, Mathew A, Abraham EK, Francis A, Somanathan T, et al. Primary intraosseous carcinoma of the jaw: Pooled analysis of world literature and report of two new cases. *Int J Oral Maxillofac Surg.* 2001;30(4):349-55. <https://doi.org/10.1054/ijom.2001.0069>  
PMid:11518362
  57. Garg B, Chavada R, Pandey R, Gupta A. Cementoblastoma associated with the primary second molar: An unusual case report. *J Oral Maxillofac Pathol.* 2019;23 Suppl 1:111-4. [https://doi.org/10.4103/jomfp.jomfp\\_83\\_18](https://doi.org/10.4103/jomfp.jomfp_83_18)  
PMid:30967738
  58. Borges DC, Rogério de Faria P, Júnior HM, Pereira LB. Conservative treatment of a periapical cementoblastoma: A case report. *J Oral Maxillofac Surg.* 2019;77(2):272.e1-7. <https://doi.org/10.1016/j.joms.2018.10.003>  
PMid:30414393
  59. Holly D, Jurkovic R, Mračna J. Condensing osteitis in oral region. *Bratisl Lek Listy.* 2009;110(11):713-5.  
PMid:20120441
  60. Farhadi F, Ruhani MR, Zarandi A. Frequency and pattern of idiopathic osteosclerosis and condensing osteitis lesions in panoramic radiography of Iranian patients. *Dent Res J (Isfahan).* 2016;13(4):322-6. <https://doi.org/10.4103/1735-3327.187880>  
PMid:27605989
  61. Pinto AS, Carvalho MS, de Farias AL, da Silva Firmino B, da Silva Dias LP, Neto JM, et al. Hypercementosis: Diagnostic imaging by radiograph, cone-beam computed tomography, and magnetic resonance imaging. *J Oral Maxillofac Radiol.* 2017;5(3):90-3. [https://doi.org/10.4103/jomr.jomr\\_27\\_17](https://doi.org/10.4103/jomr.jomr_27_17)
  62. Mortazavi H, Parvaie P. Multiple hypercementosis: Report of a rare presentation. *J Dent Mater Tech.* 2016;5(3):158-60. Available from: [http://www.jdmt.mums.ac.ir/article\\_6872.html](http://www.jdmt.mums.ac.ir/article_6872.html). <https://doi.org/10.22038/JDMT.2016.6872>
  63. Santos HB, de Moraes EF, Moreira DG, Neto LF, Gomes PP, Freitas RA. Calcifying odontogenic cyst with extensive areas of dentinoid: Uncommon case report and update of main findings. *Case Rep Pathol.* 2018;2018:8323215. <https://doi.org/10.1155/2018/8323215>  
PMid:29862107
  64. Ram R, Singhal A, Singhal P. Cemento-ossifying fibroma. *Contemp Clin Dent.* 2012;3(1):83-5. <https://doi.org/10.4103/0976-237x.94553>  
PMid:22557904
  65. Tolentino ES, Gusmão PH, Cardia GS, Tolentino LS, Iwaki LC, Amoroso-Silva PA. Idiopathic osteosclerosis of the jaw in a Brazilian population: A retrospective study. *Acta Stomatol Croat.* 2014;48(3):183-92. <https://doi.org/10.15644/asc48/3/2>  
PMid:27688365
  66. Kumar G, Manjunatha B. Metastatic tumors to the jaws and oral cavity. *J Oral Maxillofac Pathol.* 2013;17(1):71-5. <https://doi.org/10.4103/0973-029x.110737>  
PMid:23798834
  67. Hirshberg A, Berger R, Allon I, Kaplan I. Metastatic tumors to the jaws and mouth. *Head Neck Pathol.* 2014;8(4):463-74. <https://doi.org/10.1007/s12105-014-0591-z>  
PMid:25409855
  68. Kaur H, Verma S, Jawanda MK, Sharma A. Aggressive osteoblastoma of the mandible: A diagnostic dilemma. *Dent Res J (Isfahan).* 2012;9(3):334-7.  
PMid:23087741
  69. Sahu S, Padhiary S, Banerjee R, Ghosh S. Osteoblastoma of mandible: A unique entity. *Contemp Clin Dent.* 2019;10(2):402-5.  
PMid:32308310
  70. Khaitan T, Ramaswamy P, Ginpally U, Kabiraj A. A bizarre presentation of osteoid osteoma of maxilla. *Iran J Pathol.* 2016;11(5):431-4.  
PMid:28974960
  71. Karandikar S, Thakur G, Tijare M, Shreenivas K, Agrawal K. Osteoid osteoma of mandible. *BMJ Case Rep.* 2011;2011:bcr1020114886. <https://doi.org/10.1136/bcr.10.2011.4886>  
PMid:22669768
  72. Burrell KH, Goepf RA. Abnormal bone repair in jaws, socket sclerosis: A sign of systemic disease. *J Am Dent Assoc.* 1973;87(6):1206-15. <https://doi.org/10.14219/jada.archive.1973.0556>  
PMid:4521580
  73. Khurana NA, Khurana G, Uppal N. Socket sclerosis, a rare complication in orthodontic tooth movement. *Contemp Clin Dent.* 2010;1(4):255-8.  
PMid:22114433
  74. Jayachandran S, Vasudevi R, Kayal L. Atypical presentation of Paget's disease with secondary osteomyelitis of mandible. *J Indian Acad Oral Med Radiol.* 2017;29(3):227-30. [https://doi.org/10.4103/jiaomr.jiaomr\\_54\\_17](https://doi.org/10.4103/jiaomr.jiaomr_54_17)
  75. Karunakaran K, Murugesan P, Rajeshwar G, Babu S.



- Paget's disease of the mandible. *J Oral Maxillofac Pathol.* 2012;16(1):107-9. <https://doi.org/10.4103/0973-029x.92984> PMID:22434946
76. Piva CG, Miyagaki DC, Linden MS, de Conto F, Rinaldi I, de Carli J. Ameloblastic fibro-odontoma: Case report. *RGO Rev Gaúcha Odontol.* 2017;65(3):265-9. <https://doi.org/10.1590/1981-863720170002000133222>
77. Kumar LK, Manuel S, Khalam SA, Venugopal K, Sivakumar TT, Issac J. Ameloblastic fibro-odontoma. *Int J Surg Case Rep.* 2014;5(12):1142-4. <https://doi.org/10.1016/j.ijscr.2014.11.025> PMID:25437658
78. Cankaya B, İşler SC, Gümüşdal A, Genç B, Asadov C. Unusual location of calcifying epithelial odontogenic tumor. *J Oral Maxillofac Radiol.* 2019;7(2):44-8. [https://doi.org/10.4103/jomr.jomr\\_18\\_19](https://doi.org/10.4103/jomr.jomr_18_19)
79. Fazeli SR, Giglou KR, Soliman ML, Ezzat WH, Salama A, Zhao Q. Calcifying epithelial odontogenic (pindborg) tumor in a child: A case report and literature review. *Head Neck Pathol.* 2019;13(4):580-6. <https://doi.org/10.1007/s12105-019-01009-1> PMID:30771214
80. Prabhu N, Issrani R, Patil S, Srinivasan A, Alam MK. Odontoma-an unfolding enigma. *J Int Oral Health.* 2019;11:334-9. [https://doi.org/10.4103/jioh.jioh\\_115\\_19](https://doi.org/10.4103/jioh.jioh_115_19)
81. Gedik R, Müftüoğlu S. Compound odontoma: Differential diagnosis and review of the literature. *West Indian Med J.* 2014;63(7):793-5. <https://doi.org/10.7727/wimj.2013.272> PMID:25867569
82. Aerden T, Grisar K, Nys M, Politis C. Secondary hyperparathyroidism causing increased jaw bone density and mandibular pain: A case report. *Oral Surg Oral Med Oral Pathol Oral Radiol.* 2018;125(3):e37-41. <https://doi.org/10.1016/j.oooo.2017.11.020> PMID:29310888
83. Mittal S, Gupta D, Sekhri S, Goyal S. Oral manifestations of parathyroid disorders and its dental management. *J Dent Allied Sci.* 2014;3(1):34-8. <https://doi.org/10.4103/2277-4696.156527>
84. Gulsahi A. Osteoporosis and jawbones in women. *J Int Soc Prev Community Dent.* 2015;5(4):263-7. PMID:26312225
85. Wankhede AN, Sayed AJ, Gattani DR, Bhutada GP. Periodontitis associated with osteomalacia. *J Indian Soc Periodontol.* 2014;18(5):637-40. <https://doi.org/10.4103/0972-124x.142461> PMID:25425827