



Do we Trust the Polymerase Chain Reaction Test Result in Children to Diagnose COVID-19? A Case Report of COVID-19

Amir Nasimfar¹, Rohollah Valizadeh^{2,3}, Mohammad Nanbakhsh^{4*}

¹Department of Pediatric, Shahid Motahari Hospital, Urmia University of Medical Sciences, Urmia, Iran; ²Student Research Committee, School of Public Health, Iran University of Medical Sciences, Tehran, Iran; ³Nickan Research Institute, Isfahan, Iran; ⁴Department of Pulmonology, Shahid Motahari Children Hospital, Urmia University of Medical Sciences, Urmia, Iran

Abstract

BACKGROUND: Coronavirus disease-19 (COVID-19) resulted in widespread concern in global public health and has a bad prognosis despite drug therapy.

CASE REPORT: The patient was an 11-year-old girl referred to a children hospital with a dry cough, fever, and headache symptoms, without comorbidity. She was hospitalized following the results of high-resolution computed tomography (HRCT). The patient was treated with ceftriaxone 1 g every 12 h and the oseltamivir capsule 45 mg every 12 h and azithromycin 250 mg tablet once daily and 200 mg hydroxychloroquine tablet every 12 h for a total of 5 days. After 5 days, the patient had suitable chest status and then was discharged. Azithromycin for 5 days and hydroxychloroquine for 10 days were prescribed for the patient to take at home. The patient's polymerase chain reaction (PCR) was negative at baseline through the nasopharyngeal swap, but HRCT of the patient's was completely consistent with COVID-19 accompanied by consolidation and ground-glass opacity in the left lower and right upper lobes.

CONCLUSION: The numerous technical errors in taking the nasopharyngeal swap were the main reasons for the negative PCR. The main lesson from this case report is the high sensitivity and specificity of HRCT compared to the PCR.

Edited by: Mirko Spiroski
Citation: Nasimfar A, Valizadeh R, Nanbakhsh M. Do we Trust the Polymerase Chain Reaction Test Result in Children to Diagnose COVID-19? A Case Report of COVID-19. Open Access Maced J Med Sci. 2020 Jun 10; 8(T1):32-35. https://doi.org/10.3889/oamjms.2020.4742
Keywords: Coronavirus disease-19; Novel coronavirus; Polymerase chain reaction; Children
***Correspondence:** Mohammad Nanbakhsh, Department of Pulmonology, Shahid Motahari Children Hospital, Urmia University of Medical Sciences, Urmia, Iran. E-mail: mohammad_nanbakhsh@yahoo.com
Received: 06-Apr-2020
Revised: 13-May-2020
Accepted: 21-May-2020
Copyright: © 2020 Amir Nasimfar, Rohollah Valizadeh, Mohammad Nanbakhsh
Funding: Publication of this article was financially supported by the Scientific Foundation SPIROSKI, Skopje, Republic of Macedonia
Competing Interests: The authors have declared that no competing interests exist
Open Access: This is an open-access article distributed under the terms of the Creative Commons Attribution-NonCommercial 4.0 International License (CC BY-NC 4.0)

Introduction

Coronavirus disease-19 (COVID-19) is caused by severe acute respiratory syndrome coronavirus 2 (SARS-COV2) and is a causative agent of a potentially fatal disease that has caused widespread concern in the global public health. Coronavirus is one of the largest pathogens that mainly target the human respiratory tract, which has a bad prognosis despite drug therapy [1], [2].

Moreover, SARS-COV2 results in multi-organ failure, such as renal and liver failure [3], [4]. Regarding prevalence, these patients were associated with a wholesale market for seafood and wet animals in Wuhan, Hubei Province, China [5], [6]. Preliminary reports predicted the launch of a potential coronavirus epidemic with a basic reproduction number (R_0) varying from 2.24 to 3.58 [7]. A study by Wang *et al.* showed that the ratio of male-to-female mortality was 3.25 to 1, the median age of death was 75 years, the median time from the first symptoms to death was 14 days, and the median time from the initial symptoms to death above

70 years was shorter (11.5 days) than in people under 70 years of age (20 days). These findings suggest that the disease may progress more rapidly in adults than in young people [8].

Li *et al.* reported the mean age of 59 years for coronavirus-positive patients, of which 56% were men, the mean incubation period was 2.5 days, and almost half of the adult patients were 60 years and older [9]. The treatment of coronavirus in most cases is unnecessary because most patients have mild or moderate symptoms. However, it may be necessary to identify an etiological factor in epidemiological studies, especially during epidemic outbreaks. Since the novel coronavirus-2019 has not been found in humans before, no specific vaccine or treatment has been provided. In the current state of emergency, the number of cases is rapidly increasing. Therefore, it is important to diagnose all suspected cases as soon as possible and to remove them quickly to cutoff the source of the infection. New diagnostic solutions, including reverse transcription PCR and microscopic-based measurements, may be effective in monitoring epidemiological measures, along with preventive measures [10]. Coronavirus Novin-2019 nucleic acids can be detected in samples such

as nasopharyngeal swabs, sputum, lower respiratory tract secretions, blood, and feces [11], [12]. Therefore, we present a case report of different radiologic findings apart from PCR results.

Case Presentation

The patient was an 11-year-old girl referred to a children hospital with a dry cough, fever, and headache symptoms, without comorbidity, and with a history of adenoidectomy and ventilation tube implantation in both ears 9 months ago. She was hospitalized following the results of high-resolution computed tomography (HRCT) and imaging due to the aggravation of coughs. At the time of admission, height, weight, SpO_2 , respiratory rate, heart rate, and axillary temperature were 145 cm, 24 kg, 97% (on room air), 17 breaths/min, 97 beats/min, and 38.5°C , respectively. Laboratory results were as following:

C-reaction protein = +1, white blood cell (WBC): $5200/\text{mm}^3$, lymph: 17%, neut: 75%, platelet) = 216,000, hemoglobin: 12.5 mg/dl, aspartate aminotransferase (AST) = 30 IU/l, alanine transaminase (ALT) = 35 IU/l, alkaline phosphatase = 135 IU/l, prothrombin time = 13 s, partial thromboplastin time = 45 s, international normalized ratio = 1.1, serum calcium (Ca) = 8.8 mg/dl, 25 (oH) Vitamin D level = 52 ng/ml, blood urea nitrogen = 8 mg/dl, creatinine (Cr) = 0.6 mg/dl, erythrocyte sedimentation rate = 30 mm/hand, and lactate dehydrogenase = 461 IU/L.

The patient was treated with ceftriaxone 1 g every 12 h and the oseltamivir capsule 45 mg every 12 h and azithromycin 250 mg tablet once daily and 200 mg hydroxychloroquine tablet every 12 h for a total of 5 days. After 5 days, the patient had suitable chest status and then was discharged. Azithromycin for 5 days and hydroxychloroquine for 10 days were prescribed for the patient to take at home.

The patient's PCR was negative at baseline through the nasopharyngeal swap. HRCT of the patient's, which was reported by two radiologists, was completely consistent with COVID-19.

In Iran, there is no kit to detect coronavirus antibodies (IgM and IgG). The patient had previously been visited by an otorhinolaryngologist and had no upper airway problems and most of the symptoms were in the lower airway.

Due to the absence of respiratory distress and SpO_2 above 94%, blood gas was not taken from the patient. Due to the good general condition, the PCR test was not taken after discharge and was quarantined for only 2 weeks. Due to a large number of false negatives in the nasopharyngeal swab sample and the failure to obtain the correct sample or CT scan based

on COVID19, which was reported by two radiologists, the PCR test and CT were not performed again.

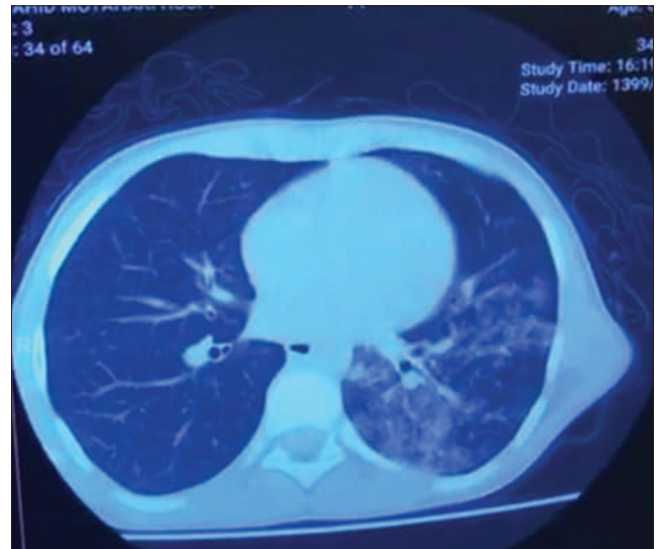


Figure 1: Consolidation and ground-glass opacity in the left lower lobe in high-resolution computed tomography

Figure 1 represents a consolidation and ground-glass opacity (GGO) in the left lower lobe. Figure 2 represents consolidation and GGO in the right upper lobe. Figure 3 shows no significant findings in the chest-X ray.

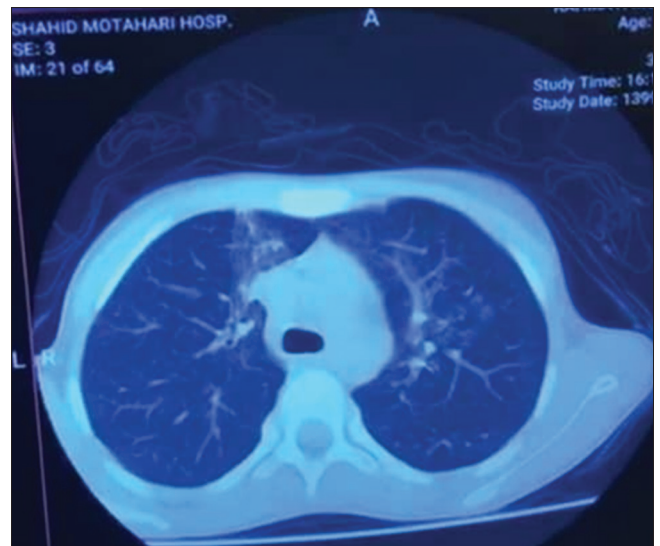


Figure 2: Consolidation and ground-glass opacity in the right upper lobe in high-resolution computed tomography

Discussion

Guan *et al.* reported 1099 cases of the novel 2019 coronavirus infection. They found that fever (78.9%) and cough (67.7%) were the most common symptoms. Abnormalities in CT images of the chest were observed in 96% of patients infected with the novel coronavirus-2019,

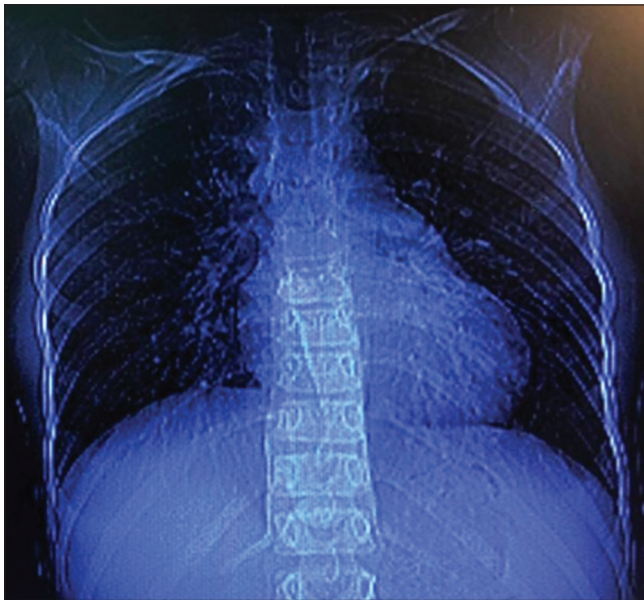


Figure 3: Normal chest-X ray of the patient

and lymphocytopenia was recorded in 82.1% of them [9]. Our case was the same indicating that dry cough and fever can be common in the children too. WBC of $5200/\text{mm}^3$, lymph of 17%, and neut of 75% showed lymphocytopenia of our case. In some studies, it has been reported that chest X-rays do not have enough sensitivity and specificity; thus, CT scans should be done like our case [13], [14], [15]. In the present case, chest X-ray was normal and could not detect COVID-19; then, we had no choice to check the CT scan of the patients. In the assessment of HRCT, we found that the lung had consolidation and GGO in the right upper and left lower lobes. In spite of the negative result of PCR, the radiologic findings approved COVID-19. Therefore, clinicians should check CT to approve the definite diagnosis of COVID-19. Hence, the majority of patients infected with the novel coronavirus-2019 can be diagnosed by CT. The fact that "children are not very susceptible" may jeopardize their health. Children should be prevented to have a close contact with the epidemic area and people [16], [17].

Huang *et al.* found that 98% of patients with COVID-19 had a fever. They reported that 76% of patients had a cough with dyspnea. Furthermore, a small number of patients had expectoration sputum. Laboratory tests showed that 25% of infected patients had leukopenia and 64% had lymphocytopenia. AST levels were elevated in 37% of patients. Abnormalities in chest CT images were observed in 100% of patients. GGO and consolidation areas were found in 37% of the lungs on both sides of infected patients [18]. The findings of CT of the present case were consistent with the study of Huang *et al.* In the present case, liver function tests were normal ($\text{AST}=30 \text{ IU/l}$, $\text{ALT}=35 \text{ IU/l}$, and $\text{ALO}=135 \text{ IU/l}$), in such a way that was inconsistent with the study by Huang *et al.* [18].

Conclusion

The number and severity of pulmonary involvement in children are lower than adults based on Chinese and the previous articles. In our case, the severity of the symptoms was mild, and the numerous technical errors in taking the nasopharyngeal swap were the main reasons for the negative PCR, but HRCT apparently showed COVID-19. The main lesson from this case report is the high sensitivity and specificity of HRCT compared to the PCR.

References

1. Dadashzadeh N, Farshid S, Valizadeh R, Nanbakhsh M, Rahimi MM. Acute respiratory distress syndrome in COVID-19 disease. *Immunopathol Persa.* 2020;6(2):e16.
2. Valizadeh R, Dadashzadeh N, Zakeri R, Kellner SJ, Rahimi MM. Drug therapy in hospitalized patients with very severe symptoms following COVID-19. *J Nephropharmacol.* 2020;9(2):e21.
3. Valizadeh R, Baradaran A, Mirzazadeh A, Bhaskar LV. Coronavirus-nephropathy; renal involvement in COVID-19. *J Renal Inj Prev.* 2020;9(2):e18. <https://doi.org/10.34172/jrip.2020.18>
4. Mubarak M, Nasri N. COVID-19 nephropathy; an emerging condition caused by novel coronavirus infection. *J Nephrothol.* 2020;9(3):e21. <https://doi.org/10.34172/jnp.2020.21>
5. Bogoch II, Watts A, Thomas-Bachli A, Huber C, Kraemer MU, Khan K. Pneumonia of unknown etiology in Wuhan, China: Potential for international spread via commercial air travel. *J Trav Med.* 2020;27(2):taaa008. <https://doi.org/10.1093/jtm/taaa008> PMID:31943059
6. Lu H, Stratton CW, Tang YW. Outbreak of pneumonia of unknown etiology in Wuhan, China: The mystery and the miracle. *J Med Virol.* 2020;92(4):401-2. <https://doi.org/10.1002/jmv.25678> PMID:31950516
7. Zhao S, Lin Q, Ran J, Musa SS, Yang G, Wang W, *et al.* Preliminary estimation of the basic reproduction number of novel coronavirus (2019-nCoV) in China, from 2019 to 2020: A data-driven analysis in the early phase of the outbreak. *Int J Infect Dis.* 2020;92:214-7. <https://doi.org/10.1101/2020.01.23.916395> PMID:32007643
8. Wang W, Tang J, Wei F. Updated understanding of the outbreak of 2019 novel coronavirus (2019-nCoV) in Wuhan, China. *J Med Virol.* 2020;92(4):441-7. <https://doi.org/10.1002/jmv.25689>
9. Li Q, Guan X, Wu P, Wang X, Zhou L, Tong Y, *et al.* Early transmission dynamics in Wuhan, China, of novel coronavirus-infected pneumonia. *N Engl J Med.* 2020;382(13):1199-207. PMID:31995857
10. Forouzesh M, Azadeh R, Valizadeh R, Dadashzadeh N, Mirzazadeh A. Clinical display, diagnostics and genetic implication of novel coronavirus (COVID-19). *Eur Rev Med Pharmacol Sci.* 2020;24(8):4607-15. PMID:32374001
11. Emery SL, Erdman DD, Bowen MD, Newton BR, Winchell JM, Meyer RF, *et al.* Real-time reverse transcription-polymerase chain reaction assay for SARS-associated coronavirus. *Emerg Infect Dis.* 2004;10(2):311-6. <https://doi.org/10.3201/eid1002.030759> PMID:15030703

12. Gaunt ER, Hardie A, Claas EC, Simmonds P, Templeton KE. Epidemiology and clinical presentations of the four human coronaviruses 229E, HKU1, NL63, and OC43 detected over 3 years using a novel multiplex real-time PCR method. *J Clin Microbiol.* 2010;48(8):2940-7. <https://doi.org/10.1128/jcm.00636-10>
PMid:20554810
13. Qiu H, Wu J, Hong L, Luo Y, Song Q, Chen D. Clinical and epidemiological features of 36 children with coronavirus disease 2019 (COVID-19) in Zhejiang, China: An observational cohort study. *Lancet Infect Dis.* 2020;20(6):689-96. [https://doi.org/10.1016/s1473-3099\(20\)30198-5](https://doi.org/10.1016/s1473-3099(20)30198-5)
14. Le HT, Nguyen LV, Tran DM, Do HT, Tran HT, Le YT, et al. The first infant case of COVID-19 acquired from a secondary transmission in Vietnam. *Lancet Child Adolesc Health.* 2020;4(5):405-6. [https://doi.org/10.1016/s2352-4642\(20\)30091-2](https://doi.org/10.1016/s2352-4642(20)30091-2)
PMid:32213326
15. Liu W, Zhang Q, Chen J, Xiang R, Song H, Shu S, et al. Detection of Covid-19 in children in early January 2020 in Wuhan, China. *N Engl J Med.* 2020;382(14):1370-1. <https://doi.org/10.1056/nejmc2003717>
PMid:32163697
16. Jahromi AH, Mazloom S, Ballard DH. What the European and American health care systems can learn from China COVID-19 epidemic; action planning using purpose designed medical telecommunication, courier services, home-based quarantine, and COVID-19 walk-in centers. *Immunopathol Persa.* 2020;6(2):e17. <https://doi.org/10.1016/j.tmaid.2020.101676>
17. Ghelichi-Ghojogh M, Kalteh EA, Fararoei M. Coronavirus disease 2019; epidemiology and recommendations. *J Prev Epidemiol.* 2020;5(1):e01.
18. Huang C, Wang Y, Li X, Ren L, Zhao J, Hu Y, et al. Clinical features of patients infected with 2019 novel coronavirus in Wuhan, China. *Lancet.* 2020;395(10223):497-506. [https://doi.org/10.1016/s0140-6736\(20\)30183-5](https://doi.org/10.1016/s0140-6736(20)30183-5)
PMid:31986264