



Severe Acute Respiratory Syndrome-coronavirus 2 Interstitial Bilateral Pneumonia: A Case Report and Review of Literature

Danilo Coco^{1*}, Silvana Leanza²

¹Department of General Surgery, Ospedali Riuniti Marche Nord, Pesaro, Italy; ²Department of General Surgery, Carlo Urbani Hospital, Jesi, Ancona, Italy

Abstract

Edited by: Ksenija Bogoeva-Kostovska
Citation: Coco D, Leanza S. Severe Acute Respiratory Syndrome-coronavirus 2 Interstitial Bilateral Pneumonia: A Case Report and Review of Literature. Open Access Maced J Med Sci. 2020 Sep 03; 8(T1):229-232. <https://doi.org/10.3889/oamjms.2020.4851>
Keywords: Severe acute respiratory syndrome-coronavirus 2; Interstitial bilateral pneumonitis; X-ray; Computed tomography scan
***Correspondence:** Danilo Coco MD, Ospedali Riuniti Marche Nord, Pesaro, Italy. Tel.: +393400546021. E-mail: webcostruction@msn.com
Received: 27-Apr-2020
Revised: 14-Aug-2020
Accepted: 18-Aug-2020
Copyright: © 2020 Danilo Coco, Silvana Leanza
Funding: Publication of this article was financially supported by the Scientific Foundation SPIROSKI, Skopje, Republic of Macedonia
Competing Interests: The authors have declared that no competing interest exists
Open Access: This is an open-access article distributed under the terms of the Creative Commons Attribution-NonCommercial 4.0 International License (CC BY-NC 4.0)

In December 2019, novel cases of pneumonia were reported for the 1st time in Wuhan, Hubei, China. A novel virus of the big family of coronavirus (COV) was identified as the pathogen, which causes severe acute respiratory syndrome (SARS). The disease is called COV Disease-19 and then SARS-COV 2. The infectious disease has spread worldwide with major number of patients in China, Italy, Spain, France, and the USA. On March 11, 2020, the WHO declared the outbreak of SARS-CoV-2 a pandemic. Morbidity and mortality of the disease cannot yet estimate but have already seen that lethality appears to be particularly higher in older patients. The aim of this article is to present a characteristic clinical picture as case report SARS-COV 2 pneumonia and to provide an overview of the existing literature.

Introduction

In December 2019, many pneumonia cases were reported in China, Wuhan. The source has shown Huanan Seafood Market as the origin discovering an unexplained pneumonia on December 12, 2019 [1]. On January 22, 2020, novel coronavirus (CoV) has been declared to be originated from wild bats as part of beta-COV who cause severe acute respiratory syndrome-associated COV (SARS-CoV). COVs are zoonotic pathogens that are present in humans and various animals with a wide range of clinical features from asymptomatic course to requirement of hospitalization in the intensive care unit, causing infections in respiratory, gastrointestinal, hepatic, and neurologic systems. All CoVs are pleomorphic RNA viruses characteristically crown shape with 80–160 nm in size and 27–32 kb positive polarity [2], [3], [4], [5]. The disease caused by SARS-CoV-2 is called COV disease (COVID)-19 which has since spread worldwide with major number of patients in China, Italy, Spain, France, and the USA. On March 11, 2020, the WHO declared the outbreak of SARS-CoV-2 a pandemic. Morbidity and mortality of the disease cannot yet estimate but have already seen that lethality appears to be particularly higher in older patients. In a cohort study

of 41 hospitalized patients, fever, dry cough, myalgia, and fatigue symptoms were reported in most patients, and less often, symptoms of expectoration, headache, hemoptysis, and diarrhea were also observed [6]. Comorbidities such as underlying hypertension, diabetes mellitus, and cardiovascular disease, and autoimmune diseases were found in about half of these patients. Dyspnea, acute respiratory distress syndrome, and cardiovascular complications accompanied by abnormal thorax computed tomography (CT) compatible with pneumonia mean 8 days after the admission. X-rays or thorax CT images of the patients revealed bilateral multilobar ground-glass opacities (GGOs), with peripheral posterior distribution [7], [8].

The aim of this article is to present a characteristic clinical picture as case report as SARS-COV-2 pneumonia and to provide an overview of the existing literature.

Case report

A 60-year-old man with a medical history of prostatectomy for cancer, osseous metastases,

and hormone therapy, presented to the emergency department in mid-March after fever, cough, ageusia, and anosmia at home for 20 days. He referred myalgias and cough at the beginning followed by fevers and said that his symptoms persisted despite the medication with paracetamol and antibiotics. The patient stated that he had shortness of breath in the past 3 days. He had had no recent travel outside of the state or internationally. On admission, the patient was afebrile with a mild non-productive cough. He had limitation in exercise tolerance during this acute illness. Admission vital signs were heart rate 80 beats/min, blood pressure 150/90 mmHg, respiratory rate 18, pulse oximetry 99% on air, and temperature 36.5°C. The results of routine laboratory parameters are shown: Leukocytes $10.78 \times 10^3/\text{mmc}$, lymphocytes 17.6%, D-DIMERO 5.246 ng/ml fibrinogen equivalent units, Polymerase Chain Reaction (PCR) 1.10 mg/dl, and pro-calcitonin 0.03 ng/ml. Arterial blood gases (ABGs): pH 7, 450, PCO_2 35.0 mmHg, PO_2 68.0 mmHg, PO_2/FiO_2 (P/F ratio) 324.0 mmHg. PCR testing for other respiratory viruses, *Mycoplasma pneumoniae* and *Chlamydia pneumoniae*, on the throat swab was negative. Nose and throat samples for SARS-CoV-2 PCR were obtained that returned positive. Examination of the lungs reveals murmur reduced and reduce vesicular murmur and tactile vocal fremitus bilaterally. He had also bilateral scleral injection. After arrival, the patient was placed on maximum isolation precautions (negative pressure room, with anyone entering the room required to wear an N95 respirator, face shield, disposable gown, and gloves). A CT chest showed bilaterally multiple patchy GGOs and crazy paving is seen. Some of the opacities are round and some geographic shaped. Partially, the lesions are sharply demarcated against the surrounding healthy lung. The left lower lobe and the periphery of the lungs are predominantly involved (Figure 1a-i). He subsequently worsened because of his SO_2 became 85% despite 12l/min of oxygen and his P/F ratio was inferior to 200 in a new ABG. Hence, he was admitted in an intensive care unit for mild respiratory failure. He was treated with oxygen therapy using continuous positive airway pressure, adjusted following continuous ABG. We associated antibiotics such as azithromycin 500 mg a day, hydroxycloquine 400 mg day for the first 48 h, and then 200 mg for other 10 days and enoxaparin adjusted following patient weight. Darunavir/cobicistat 800/150 mg a day was avoided because 20 days of symptoms onset and tocilizumab was not necessary because the patients improved. He was discharged 15 days after.

Discussion

Novel CoV has been declared to be originated from wild bats as part of beta-COV who

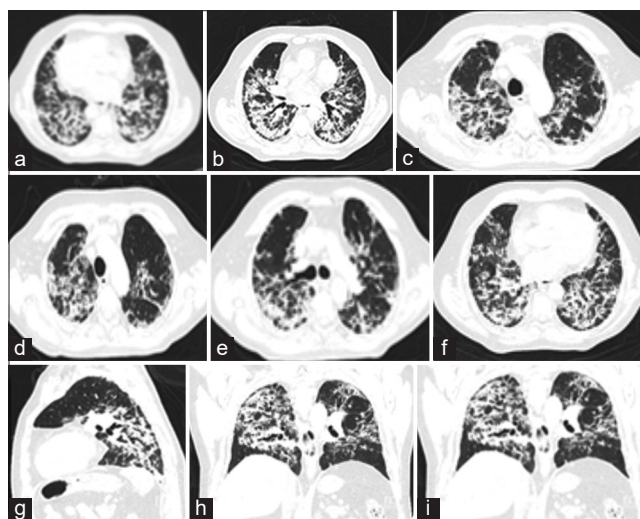


Figure 1: (a-i) Bilaterally multiple patchy ground-glass opacities and crazy paving are seen. Some of the opacities are round and some geographic shaped. Partially, the lesions are sharply demarcated against the surrounding healthy lung. The left lower lobe and the periphery of the lungs are predominantly involved Images

cause SARS-associated COV (SARS-CoV). COVs are zoonotic pathogens that are present in humans and various animals with a wide range of clinical features from asymptomatic course to requirement of hospitalization in the intensive care unit, causing infections in respiratory, gastrointestinal, hepatic, and neurologic systems. Coronaviridae was discovered in the 1960s. The name COV originates from the Latin word corona, meaning "crown" or "halo," due to its characteristic appearance under two-dimensional transmission electron microscopy. COVs have club-shaped spike peplomers covering their surfaces [9] (Figure 2a and b). SARS-CoV, Middle East respiratory syndrome (MERS)-CoV, and SARS-CoV-2 belong to the Coronaviridae family. This family of viruses contains a relatively large single-stranded, positive-sense RNA genome of around 27–32 kb. The most important potential therapeutic target is the spike (S) glycoprotein, which is responsible for the binding of the virus to the host cells. It has been reported that the binding of the viral S protein to angiotensin-converting enzyme (ACE)2 receptors. Increased ACE activity consequently results in the elevated levels of angiotensin II. Once angiotensin II binds to its receptor, AGTR1A, pulmonary vascular permeability is increased [10], [11], [12]. As of April 06, 2020, a total of 1,285,257 cases of COVID-19 occurring in at least 170 countries and territories were reported, with approximately 5.4 % of fatality rate

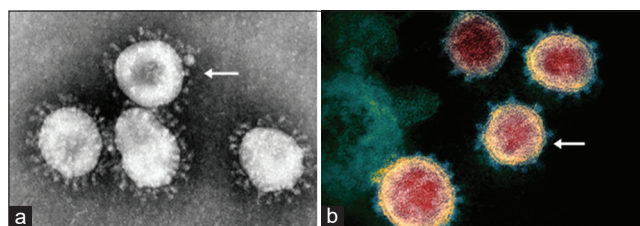


Figure 2: (a and b) Electron microscopy image of SARS-CoV-2

(70,344/1,285,257) [13]. In a study of 1099 patients in China with confirmed COVID-19, the most commonly reported symptom was fever (43.8% on initial admission and 88.7% during hospitalization) followed by cough (67.8%) [14], [15]. Atypical chest and back pain has also been reported as presenting symptoms. Chest CT is more efficient in detecting pneumonia at the early stages of COVID-19. The most common patterns of COVID-19 on chest CT scans include multiple GGO (56.4%), and bilateral patchy shadowing (51.8%), and the other patterns consist of local patchy shadowing (28.1%) and interstitial abnormalities (4.4%) [6], [16], [17]. Today, there is no vaccine or effective treatment to prevent COVID-19 infection. Early diagnosis, reporting, isolation, and basic measures such as hand washing, using disinfectant solutions, avoiding contact with patients, and supportive treatments are the most helpful. There are publications demonstrating that remdesivir has a strong antiviral activity in epithelial cell cultures against SARS-CoV, MERS-CoV, and related zoonotic bat CoV [18], [19]. As part of MERS cure, a randomized control trial (MIRACLE Trial 2016) from South Korea determines that the combination of lopinavir/ritonavir (anti-HIV drugs), pegylated interferon, and ribavirin provided a successful viral clearance [16]. Chloroquine, typically used in the context of malarial or autoimmune disease, has also shown promising results [20], [21]. Tocilizumab is a humanized monoclonal antibody against interleukin-6 receptor (Ab), commonly used as an immunosuppressive in the treatment of rheumatoid arthritis and systemic juvenile idiopathic arthritis seems to be successful [22], [23]. The duration between onset of symptoms and isolation is about 6 days, and it is expected that each 1 day reduction in this period will decrease the size of peak population by 72–84% and cumulative infected cases and deaths by 68–80%. It is estimated that with the effects of integrated interventions such as promoting the use of face masks and reduced traveling, each 10% reduction in transmission rate, the size of peak population will decrease by 20–47%, and cumulative infected cases and deaths will decrease by 23–49% [24].

Conclusions

SARS-CoV-2 is the COV responsible for the COVID-19 pandemic of 2020. The mean incubation time is 5.1 days (95% confidence interval [CI]: 4.5–5.8 days), with 97.5% of those who develop symptoms doing so within 11.5 days (95% CI: 8.2–15.6 days). Symptoms may vary from mild to severe. Those most affected by COVID-19 are those of advanced age and those with pre-existing chronic medical conditions. Mortality rates are currently unknown: From 0.25% to 10%. Treatment options are limited. Supportive care is the best choice. Ongoing studies are evaluating the efficacy of remdesivir,

chloroquine, hydroxychloroquine, tocilizumab, lopinavir, and ritonavir. At present, no vaccine is available but there are progresses to developing a vaccine over the coming year.

References

- Hamer OW, Salzberger B, Gebauer J, Stroszczynski C, Pfeifer M. CT morphology of COVID-19: Case report and review of literature. *Rofo*. 2020;192(5):386-92. <https://doi.org/10.1055/a-1142-4094>
PMid:32215898
- Sahin AR, Erdogan A, Agaoglu PM, Dineri Y, Cakirci AY, Senel ME, *et al*. 2019 Novel coronavirus (COVID-19) outbreak: A review of the current literature. *EJMO*. 2020;4(1):1-7. <https://doi.org/10.14744/ejmo.2020.12220>
- Woo PC, Huang Y, Lau SK, Yuen KY. Coronavirus genomics and bioinformatics analysis. *Viruses*. 2010;2(8):1804-20. <https://doi.org/10.3390/v2081803>
PMid:21994708
- Drexler JF, Gloza-Rausch F, Glende J, Corman VM, Muth D, Goettsche M, *et al*. Genomic characterization of severe acute respiratory syndrome-related coronavirus in European bats and classification of coronaviruses based on partial RNA-dependent RNA polymerase gene sequences. *J Virol*. 2010;84(21):11336-49. <https://doi.org/10.1128/jvi.00650-10>
PMid:20686038
- Yin Y, Wunderink RG. MERS, SARS and other coronaviruses as causes of pneumonia. *Respirology*. 2018;23(2):130-7. <https://doi.org/10.1111/resp.13196>
PMid:29052924
- Huang C, Wang Y, Li X, Ren L, Zhao J, Hu Y, *et al*. Clinical features of patients infected with 2019 novel coronavirus in Wuhan, China. *Lancet*. 2020;395(10223):497-506. [https://doi.org/10.1016/s0140-6736\(20\)30183-5](https://doi.org/10.1016/s0140-6736(20)30183-5)
PMid:31986264
- Wang C, Horby PW, Harden FG, Gao GF. A novel coronavirus outbreak of global health concern. *Lancet*. 2020;95(10223):470-3. [https://doi.org/10.1016/s0140-6736\(20\)30185-9](https://doi.org/10.1016/s0140-6736(20)30185-9)
PMid:31986257
- Salehi S, Abedi A, Balakrishnan S, Gholamrezanezhad A. Coronavirus disease 2019 (COVID-19): A systematic review of imaging findings in 919 patients. *AJR Am J Roentgenol*. 2020;215(1):83-93. <https://doi.org/10.2214/ajr.20.23034>
PMid:32174129
- Goldsmith C, Tatti K, Ksiazek T, Rollin PE, Comer JA, Lee WW, *et al*. Ultrastructural characterization of SARS coronavirus. *Emerg Infect Dis*. 2004;10(2):320-6. <https://doi.org/10.3201/eid1002.030913>
PMid:15030705
- Pyrc K, Dijkman R, Deng L, Jebbink MF, Ross HA, Berkhout B, *et al*. Mosaic structure of human Coronavirus NL63, one thousand years of evolution. *J Mol Biol*. 2006;364(5):964-73. <https://doi.org/10.1016/j.jmb.2006.09.074>
PMid:17054987
- Hoffmann M, Kleine-Weber H, Schroeder S, Krüger N, Herrler T, Erichsen S, *et al*. SARS-CoV-2 cell entry depends on ACE2 and TMPRSS2 and is blocked by a clinically proven protease inhibitor. *Cell*. 2020;181(2):271-80.e8. <https://doi.org/10.1016/j.cell.2020.02.052>

- PMid:32142651
12. Kuba K, Imai Y, Rao S, Gao H, Guo F, Guan B, *et al.* A crucial role of angiotensin converting enzyme 2 (ACE2) in SARS coronavirus-induced lung injury. *Nat Med.* 2005;11(8):875-9. <https://doi.org/10.1038/nm1267>
PMid:16007097
 13. Tu YF, Chien CS, Yarmishyn AA, Lin YY, Luo YH, Lin YT, *et al.* A review of SARS-CoV-2 and the ongoing clinical trials. *Int J Mol Sci.* 2020;21(7):2657. <https://doi.org/10.3390/ijms21072657>
PMid:32290293
 14. Guan WJ, Ni Z, Hu Y, Liang WH, Ou CQ, He JX, *et al.* Clinical Characteristics of Coronavirus Disease 2019 in China. *N Engl J Med.* 2020;382:1708-20.
 15. Yoon SH, Lee YH, Kim JY, Lee YK, Ko H, Kim KH, *et al.* Chest radiographic and CT findings of the 2019 novel Coronavirus disease (COVID-19): Analysis of nine patients treated in Korea. *Korean J Radiol.* 2020;21(4):494-500. <https://doi.org/10.3348/kjr.2020.0132>
PMid:32100485
 16. Chen N, Zhou M, Dong X, Qu J, Gong F, Han Y, *et al.* Epidemiological and clinical characteristics of 99 cases of 2019 novel coronavirus pneumonia in Wuhan, China: A descriptive study. *Lancet.* 2020;395(10223):507-13. [https://doi.org/10.1016/s0140-6736\(20\)30211-7](https://doi.org/10.1016/s0140-6736(20)30211-7)
PMid:32007143
 17. Wang D, Hu B, Hu C, Zhu F, Liu X, Zhang J, *et al.* Clinical characteristics of 138 hospitalized patients with 2019 novel coronavirus-infected pneumonia in Wuhan, China. *JAMA.* 2020;323(11):1061-9. <https://doi.org/10.1001/jama.2020.1585>
PMid:32031570
 18. Cockrell AS, Yount BL, Scobey T, Jensen K, Douglas M, Beall A, *et al.* A mouse model for MERS coronavirus-induced acute respiratory distress syndrome. *Nat Microbiol.* 2016;2(2):16226. <https://doi.org/10.1038/nmicrobiol.2016.226>
PMid:27892925
 19. Brown AJ, Won JJ, Graham RL, Dinnon KH 3rd, Sims AC, Feng JY, *et al.* Broad spectrum antiviral remdesivir inhibits human endemic and zoonotic deltacoronaviruses with a highly divergent RNA dependent RNA polymerase. *Antiviral Res.* 2019;169:104541. <https://doi.org/10.1016/j.antiviral.2019.104541>
PMid:31233808
 20. Wang M, Cao R, Zhang L, Yang X, Liu J, Xu M, *et al.* Remdesivir and chloroquine effectively inhibit the recently emerged novel coronavirus (2019-nCoV) *in vitro*. *Cell Res.* 2020;30(3):269-71. <https://doi.org/10.1038/s41422-020-0282-0>
PMid:32020029
 21. Gao J, Tian Z, Yang X. Breakthrough: Chloroquine phosphate has shown apparent efficacy in treatment of COVID-19 associated pneumonia in clinical studies. *Biosci Trends.* 2020;14(1):72-3. <https://doi.org/10.5582/bst.2020.01047>
PMid:32074550
 22. Martinez M. Compounds with therapeutic potential against novel respiratory 2019 coronavirus. *Antimicrob Agents Chemother.* 2020;1:1-18. <https://doi.org/10.1128/aac.00399-20>
 23. Mehta P, McAuley D, Brown M, Sanchez E, Tattersall R, Manson J. COVID-19: Consider cytokine storm syndromes and immunosuppression. *Lancet.* 2020;395(10229):1033-4. [https://doi.org/10.1016/s0140-6736\(20\)30628-0](https://doi.org/10.1016/s0140-6736(20)30628-0)
PMid:32192578
 24. Shen M, Peng Z, Xiao Y, Zhang L. Modelling the Epidemic Trend of the 2019 Novel Coronavirus Outbreak in China. *United States: BioRxiv;* 2020. <https://doi.org/10.1101/2020.01.23.916726>