



Conservative Management of the Horizontal Root Fracture in the Middle Third using Fiber Post as an Intraradicular Splint

Sneha Dhruvkumar Vaswani*, Sathish Abraham, Harshal Balasaheb Najan, Rohini Ramesh Karad

Department of Conservative Dentistry and Endodontics, S.M.B.T. Dental College and Hospital, Sangamner, Maharashtra, India

Abstract

Edited by: Filip Koneski
Citation: Vaswani SD, Abraham S, Najan HB, Karad RR. Conservative Management of the Horizontal Root Fracture in the Middle Third using Fiber Post as an Intraradicular Splint. Open Access Maced J Med Sci. 2020 Feb 05; 8(C):146-150. <https://doi.org/10.3889/oamjms.2020.4865>
Keywords: Fiber post; Horizontal root fracture; Intraradicular
***Correspondence:** Sneha Dhruvkumar Vaswani, Department of Conservative Dentistry and Endodontics, S.M.B.T. Dental College and Hospital and Post Graduate Research Centre, Ghulewadi, Amrutnagar, Sangamner - 422 608, Maharashtra, India. Phone: +91-9011340100. Fax: (02425) 222867. E-mail: vaswanisneha03@gmail.com

Received: 30-Apr-2020

Revised: 14-Aug-2020

Accepted: 18-Aug-2020

Copyright: © 2020 Sneha Dhruvkumar Vaswani, Sathish Abraham, Harshal Balasaheb Najan, Rohini Ramesh Karad

Funding: This research did not receive any financial support.

Competing Interest: The authors have declared that no competing interest exists.

Open Access: This is an open-access article distributed under the terms of the Creative Commons Attribution-NonCommercial 4.0 International License (CC BY-NC 4.0)

BACKGROUND: Root fractures are uncommon injuries in permanent teeth and account for only 0.5–7% of dental trauma. It occurs more frequently in fully erupted permanent teeth, in which the completely formed root with closed apices is solidly supported in the bone and periodontium. This may lead to complex consequences due to the combined damage to the pulp, dentine, cementum, bone, and periodontium. They are transverse to oblique in direction and result from a horizontal impact. Their incidence is more in the middle third of the root than at the cervical and apical thirds.

CASE REPORT: This paper describes a case of complicated horizontal root fracture at the middle third of the maxillary right central incisor. After receiving an endodontic treatment, the fractured root fragments of the maxillary right central incisors were united with the help of a glass fibre post. Eventually, the incisor was restored with a zirconia crown.

CONCLUSION: Follow-up after a year revealed a well-stabilized assembly of the root fragments and the post.

Introduction

Among all dental traumatic injuries, root fractures account for only 0.5w-up after a year revealed a single tooth.[1] A root fracture is defined as account for only 0.5w-up after a ye, and pulp 0.5w-up after a ye after a ye defined as account for only 0.5w-up after a year revealed a well-stabilized assembly of the root fragments and the posoronal third (9%).[2] Traumatic injuries are more prone to occur in maxillary central incisors (approximately 68%) probably due to their position in the dental arch. The next in line is the maxillary lateral incisors (27%), followed by mandibular incisors (5%),[3] affecting the age group between 11 and 20 years old and male patients[4] as a result of trauma associated with automobile accidents, sports injuries, and fights.[5]

Root fracture divides the root into coronal and apical fragments as it results from an impact force on the top of the root and frontal forces affect the compression zone labially and lingually/palatally. Proper clinical and radiographic examination is required for the correct diagnosis of root fracture.[3] A clinician must also check

for the severity of trauma and the pulp vitality.[3,6] Root fractures present clinically as a slightly extruded tooth, often palatally displaced. The tooth is often mobile, but the degree of mobility is frequently determined by the fracture location.[5] In some cases, the patient can report pain during chewing.[7] Radiographically, a radiolucent line is seen separating the apical and coronal fragments.[3] Additional radiographs with increased or decreased vertical angulation of 15 degrees are specifically suggested for diagnosis of the angle of fracture.[6] The American Academy of Pediatric Dentistry suggests performing a radiographic examination using different angulations and projections (periapical with 90al with 90ne is seenocclusal view, and periapical with distal or mesial angulation).[7] Widening of the fracture line, loss of lamina dura, and rarefaction of the adjacent alveolar bone are typical radiographic findings.[8]

A multidisciplinary approach is clinically considered necessary to manage dental trauma.[7] Treatment outcome of fractured teeth may be influenced by several factors such as degree of dislocation, stage of root formation, location of the fracture, type of dental trauma, and the time duration between trauma

and treatment. If a rupture of the pulp takes place, revascularization of the coronal region should occur before fracture healing. However, it is believed that one of two events occurs: Invasion of cells from the apical pulp or periodontal ligament. If the pulp becomes necrotic and infected, the coronal portion will require root canal treatment.[5] Fractures in the apical third of the root usually display no mobility and do not require any treatment. Root fracture at the cervical third shows severe mobility often requires extraction.[3]

Root fractures at the middle third of the root have a favorable prognosis. When the coronal fragment is displaced, the initial treatment should be repositioning the fragments, followed by splinting to stabilize the coronal fragment and allow the surrounding periodontal tissues to recover. Tooth colored fiber posts have been introduced with the ever-increasing demand for esthetics that can be used as a medium to retain the two fractured root fragments in conjunction with bonding agents and composite resins.[3] The objective of this case report is to describe horizontal root fracture at the middle third of the root, in which fragments were united with the help of glass fiber posts, followed by core build-up and coronal coverage.

Case Report

A 28-year-old male patient has referred to the Department of Conservative Dentistry and Endodontics following trauma to the maxillary anterior region due to a road accident about 3 weeks ago. He complained of sharp, shooting pain in the maxillary right central incisor for 10 days. Clinical examination of the patient revealed extruded and palatally displaced maxillary right central incisor with Grade I mobility (Figure 1a and b).

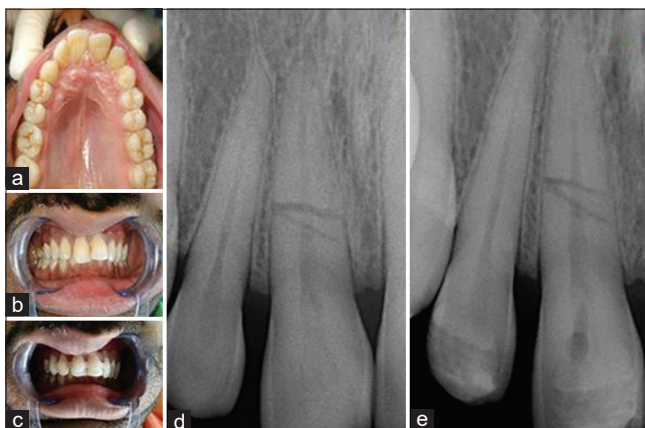


Figure 1: (a) Pre-operative clinical occlusal view shows palatally displaced maxillary right central incisor. (b) Pre-operative clinical photograph shows palatally displaced maxillary right central incisor. (c) Clinical photograph after repositioning and ribbon splinting. (d) Pre-operative radiograph shows horizontal root fracture with the maxillary right central incisor. (e) Repositioning and splinting with maxillary right central incisor

The tooth was tender on percussion. Radiographic examination revealed oblique radiolucent lines in the middle third of the root suggesting of horizontal root fracture at the middle third of the maxillary right central incisor (Figure 1d). No signs of alveolar bone fracture were observed. The responses to cold and electric pulp tester were negative suggestive of pulpal necrosis. He had a superficial laceration on the inner surface of the upper lip. After explaining the treatment plan to the patient and obtaining his consent, repositioning of the coronal segment with finger pressure under local anesthesia was done. The reduction was confirmed radiographically. Teeth were isolated, etched with 37% phosphoric acid (Ivoclar Vivadent Marketing (India) Pvt. Ltd. Andheri (West), Mumbai), rinsed and dried followed by application of bonding agent (Ivoclar Vivadent Marketing (India) Pvt. Ltd. Andheri (West), Mumbai) and light-cured for 40 s. A semi-rigid ribbon splint (Ribbond Inc., Seattle, WA, USA) was placed from 13 to 23 using a flowable, and packable light cure composite (Ivoclar Vivadent Marketing (India) Pvt. Ltd. Andheri (West), Mumbai) (Figure 1c and e).

The access was established under a rubber dam (GDC Fine Crafted Dental Pvt. Ltd. Hoshiarpur, India) using a split dam technique with the maxillary right central incisor. The working length was correctly determined radiographically using #15 K file (Mani Inc., Japan) (Figure 2a) and confirmed with an apex locator (Root ZX mini, Tokyo, Japan), followed by chemo-mechanical preparation using K files (Mani Inc., Japan) in a step-back manner to an apical file size #60 under copious irrigation using 2 ml of 5.25% NaOCl (Prime Dental Products Pvt. Ltd. Thane, India) and saline (Eurolife Healthcare Pvt. Ltd. Mumbai) after every instrument. The remainder of the canal was shaped to obtain a uniform taper from the apex toward coronal. An inter-appointment calcium hydroxide (Prime Dental Products Pvt. Ltd. Thane, India) dressing was placed using lentulospiral (Mani Inc., Japan) and the patient

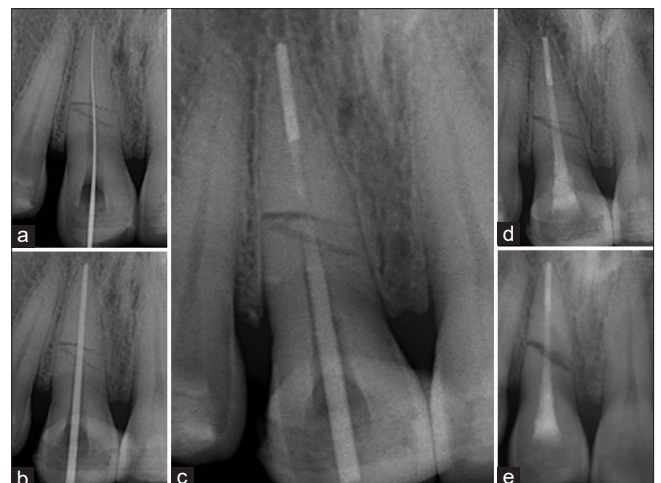


Figure 2: (a) Working length determination using #15 k file. (b) Master cone selection. (c) Sectional obturation and fiber post-selection. (d) Fiber post-cementation. (e) Post-operative radiograph after removal of splint

was recalled after 7 days. Gentle tooth brushing, rinsing with chlorhexidine mouthwash, soft diet, and avoidance of biting on the maxillary right central incisor was recommended. On the second visit, after removal of calcium hydroxide dressing, 2 ml of 17% EDTA (MAARC ENDO-L, Palghar, Mumbai, Maharashtra, India) for 5 min was used for final rinse followed by saline. The canal was dried using sterile paper points (DENTSPLY MAILLEFER, Ballaigues, Switzerland) of appropriate size. The root canal was sectionally obturated using gutta-percha cone (DENTSPLY MAILLEFER, Ballaigues, Switzerland) and AH plus sealer (Dentsply DeTrey GmbH, Konstanz, Germany). A gutta-percha cone of the same size of the prepared root canal (size #60, with a taper of 2%) was selected and tried into the canal to obtain a snug fit (Figure 2b). It was then cut to obtain a section that would be 4 mm in length from the apex of the root canal. A suitable plugger (Mani Inc., Japan) that loosely fits 4 mm short of the apical root fragment was selected and a stopper was set at this length. The obturation was carried out with sectioned gutta-percha coated with AH plus sealer. The sectioned end of gutta-percha was mounted to a heated plugger and then carried into the canal to the desired length. After this, gutta-percha was disengaged from the plugger by slightly rotating the plugger in an anticlockwise direction (Figure 2c). On the following day, an appropriate glass fiber post (Dentsply Maillefer, Ballaigues, Switzerland) was tried into the canal, adjusted to the desired length until post just passively touched the apical gutta-percha (Figure 2c).

The root canal was etched with 37% phosphoric acid gel, rinsed, and dried with paper points. The canal was coated with a bonding agent and light-cured for 40 s. The fiber post was luted with dual-cure resin cement (Ivoclar Vivadent Marketing [India] Pvt. Ltd. Andheri [West], Mumbai), inserted into the canal without applying any pressure, and then light-cured for 40 s (Figure 2d). The resin was used cautiously to lute the post only in the amount necessary to achieve a desirable bond between the post and the dentin. Coating the root canal walls with resin cement was avoided to prevent the flow of excess cement laterally between the root fragments. These fiber posts served as an intraradicular splint, stabilizing the fractured fragments in position. Following post cementation composite restoration (Ivoclar Vivadent Marketing [India] Pvt. Ltd. Andheri [West], Mumbai) was done. The splint was retained for 4 weeks and then removed (Figure 2e and 3a). The tooth was then restored with a full-coverage zirconia crown and the patient was re-evaluated regularly (Figure 3b-d).

After 12 months of recall, the patient presented with the fractured root fragments was well retained with the aid of a post and esthetically pleasing results along with sound periodontium (Figure 4).

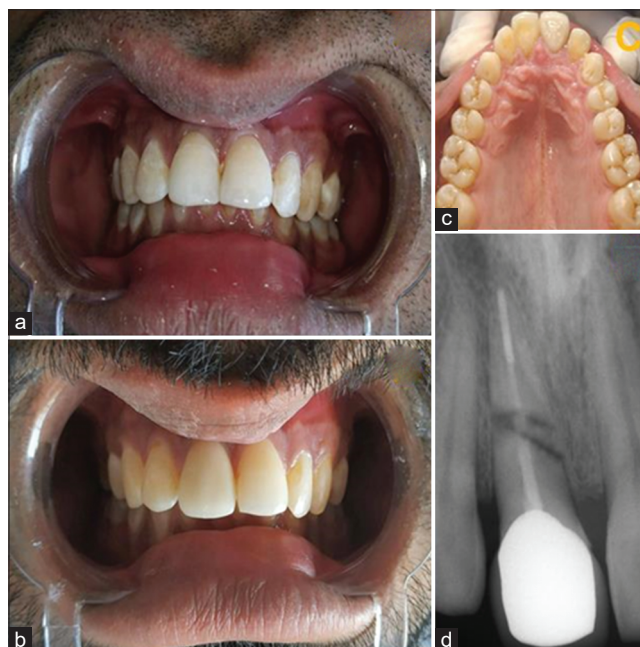

Figure 3: (a) Post-operative clinical photograph after removal of splint. (b) and (c) Post-operative clinical photograph after coronal coverage. (d) Post-operative radiograph after crown cementation

Discussion

Dental pulp necrosis occurs in 20th periodontium (Figure 4). Fragments he tooth was then restored with a full-intervention should be avoided if there are no clinical and/or pathological signs making clinical and radiographic follow-up the treatment of choice. The choice for endodontic treatment might be taken if the tooth still fails to respond to electrometric or thermal pulp testing and if radiographs show radiolucency next to the fracture line after 3 months of follow-up.[5]

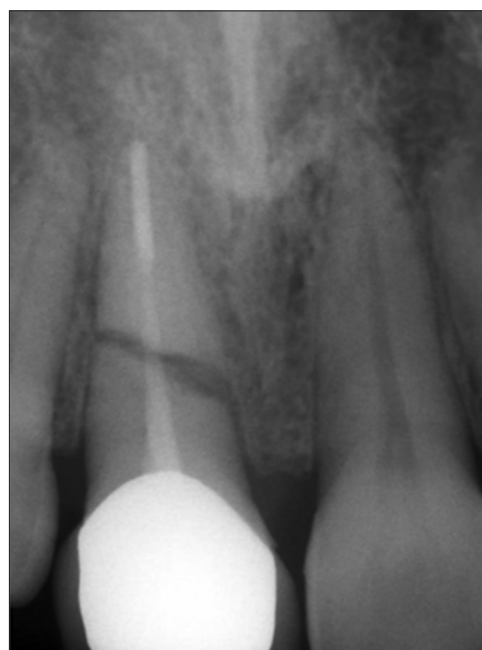


Figure 4: Follow-up of 1 year

Root fracture can be a consequence of dental trauma causing a complex injury to the cementum, dentin, pulp, and periodontal tissues. Maintaining dental trauma causing a complex injury to the cementum, dentin, pulpological signs making clin.[3] Pathological complications encountered in horizontally fractured teeth might include root canal obliteration, inflammation around the fracture line, pulp necrosis, external or internal root resorption, and periapical inflammation.[9]

According to the guidelines of the International Association of Dental Traumatology for the management of horizontal root fractures, the repositioning of the displaced coronal segment and flexible stabilization for 4 weeks is indicated. If the root fracture is near the cervical area of the tooth, stabilization for a longer period (up to 4 months) may be beneficial.[10] Various treatment options include (i) endodontic treatment of the coronal fragment only, (ii) endodontic treatment of the coronal fragment with surgical removal of the apical fragment, (iii) extraction of the coronal fragment, followed by endodontic treatment and surgical/orthodontic extrusion of the apical fragment, (iv) in cases of increased mobility of the coronal segment, intraradicular splinting can be done, and (v) removal of the apical segment and stabilization of the coronal segment with endodontic implants.[2,11] In the present case, the horizontal fracture was present at the coronal-middle third of the tooth root. Removal of the apical fragment would lead to a poor crown-root ratio. Hence, the root canal procedure was performed.

Different types of post materials such as carbon fiber, quartz, and glass fiber have been introduced recently into the dental practice. Glass fiber reinforced post were used as they exhibit high fatigue strength, high tensile strength and have a modulus of elasticity closer to dentin minimizing the risk of root fractures. The fiber posts offer several advantages such as esthetics, good bonding between post and cement, lower chairside time, and minimal tissue removal.[3] In the present case report, the two fragments were splinted using a glass fiber post to act as an intraradicular splint. After coating the post with resin cement, it was inserted passively into the root canal without applying pressure. This is because higher viscosity of the resin in the absence of pressure reduces its flow and prevents the resin from flowing between the root fragments.

The conventional metal posts have a high modulus of elasticity.[12] According to Gurtu and Singhal, post helps to retain the root fragments by radicular anchoring, thereby strengthening the restoration complex, which is subjected to tangential stresses and it also ensures support and stability to the tooth.[13] In addition to bonding, post-placement provides retention through a friction bond and assists in preventing dislodgement to non-axial forces by creating a monoblock between the post, reconstructive material, cement, and the tooth. Thus, to restore the compromised root-filled teeth functionally as well as esthetically, the use of light-transmitting fiber posts has been widely accepted to strengthen and

salvage the teeth for a continued function which earlier would have been condemned to extraction.[3]

Linkow proposed that mobility of the tooth is decreased by inserting a post through the tooth, deep into the bone, and cementing the intradental part to the root canal walls as the fulcrum of movement of a loose tooth is moved deeper into the jaw and bone support is increased.[14] Luting agents such as glass ionomer, resin-modified glass ionomer, zinc phosphate, and zinc polycarboxylate have been used traditionally. They had disadvantages associated such as solubility in oral fluids, especially in the presence of acid and lack of true adhesion. Resin modified glass ionomers exhibit hygroscopic expansion and hence their use declined.[3]

Nowadays, adhesive resin cement has been advocated for the cementation of the post because it bonds the post to the tooth structure. There is not only chemical adhesion but also micromechanical bonding. However, a disadvantage of this resin cement is its technique sensitivity, and also the bonding to root canal dentin could be compromised due to the use of various irrigants and eugenol based sealers. Eugenol can prevent or stop the polymerization reaction and can also interfere with bonding.[15]

Midroot fractures can heal by different mechanisms. Andreasen and Hjørtting-Hansen described four types of healing sequelae: (1) Healing with calcified tissue, (2) healing with interproximal connective tissue, (3) healing with interproximal bone and connective tissue, and (4) interproximal inflammatory tissue without healing.[16] The location of the fracture is an important factor affecting the prognosis and long-term survival of the tooth. The survival rate of horizontal root fractures at the apical third level was 89%, at the middle third 78%, at the cervical-middle 67%, and the cervical third 33%.[17]

A long-term follow-up is required to check for any possible pathological alterations. Follow-up of 1 year, in this case, showed promising outcomes with clinically pleasing esthetics, radiographic healing with calcified tissue, and the fractured line discernible but fragments well stabilized.

Conclusion

Horizontal root fracture following trauma has to no longer be regarded as an indication for extraction. The replacement of a single anterior tooth presents the greatest esthetic challenge to the clinician as many patients are unable to afford implant; thus, retention of natural dentition is the best alternative for horizontal root fracture. Diastasis between root fragments has a great impact on the healing of the fracture line as well as pulpal necrosis. The main aim of the treatment is to keep the tooth steady and maintains its position in

the dental arch. The improvement in restorative resins, bonding agents, and the availability of newer materials such as the fiber posts and dual-cure resin cement have provided clinicians with different modalities for successfully managing root fractures. Management of midroot fractures using fiber posts as an intraradicular splint can be a good alternative for reestablishing the esthetics and functional needs of the patients.

References

- Fagundes DD, de Mendonça IL, de Albuquerque MT, Inojosa ID. Spontaneous healing responses detected by cone-beam computed tomography of horizontal root fractures: A report of two cases. *Dent Traumatol.* 2014;30(6):484-7. <https://doi.org/10.1111/edt.12117>
PMid:24910176
- Prithviraj DR, Balla HK, Vashisht R, Regish KM, Suresh P. An overview of management of root fractures. *Kathmandu Univ Med J (KUMJ).* 2014;12(47):222-30. <https://doi.org/10.3126/kumj.v12i3.13724>
PMid:25863659
- Karhade I, Gulve MN. Management of horizontal root fracture in the middle third via intraradicular splinting using a fiber post. *Case Rep Dent.* 2016;2016:9684035. <https://doi.org/10.1155/2016/9684035>
PMid:26904313
- Kapur A, Utreja A, Goyal A, Pankaj P. Orthodontic movement of a maxillary central incisor with a horizontal root fracture treated using an intra-radicular fibre splint. *Contemp Clin Dent.* 2013;4(2):271-73. <https://doi.org/10.4103/0976-237x.114889>
PMid:24015026
- Roig M, Espona J, Mercadé M, Duran-Sindreu F. Horizontal root fracture treated with MTA, a case report with a 10-year follow-up. *Dent Traumatol.* 2011;27(6):460-63. <https://doi.org/10.1111/j.1600-9657.2011.01018.x>
PMid:21722306
- Rothom R, Chuveera P. Differences in healing of a horizontal root fracture as seen on conventional periapical radiography and cone-beam computed tomography. *Case Rep Dent.* 2017;2017:2728964. <https://doi.org/10.1155/2017/2728964>
PMid:28744379
- Giudice RL, Lizio A, Cervino G, Fabiana N, Francesco P, Ausiello P, *et al.* The horizontal root fractures. Diagnosis, clinical management and three-year follow-up. *Open Dent J.* 2018;12:687-95. <https://doi.org/10.2174/1745017901814010687>
PMid:30369978
- Kaur A, Logani A, Chahar M. Atypical radiographic presentation of a horizontal mid-root fracture in a maxillary central incisor tooth. *J Conserv Dent.* 2018;21(2):233-36. https://doi.org/10.4103/jcd.jcd_288_17
PMid:29674832
- Celikten B, Uzuntas CF, Safaralizadeh R, Demirel G, Sevimay S. Multidisciplinary approach for the treatment of horizontal root-fractured maxillary anterior teeth. *Case Rep Dent.* 2014;2014:472759. <https://doi.org/10.1155/2014/472759>
PMid:25485158
- Flores MT, Andersson L, Andreasen JO, Bakland LK, Malmgren B, Barnett F, *et al.* Guidelines for the management of traumatic dental injuries. I. Fractures and luxations of permanent teeth. *Dent Traumatol.* 2007;23(2):66-71. <https://doi.org/10.1111/j.1600-9657.2007.00592.x>
PMid:17367451
- Chaniotis A. The use of MTA/blood mixture to induce hard tissue healing in a root fractured maxillary central incisor. Case report and treatment considerations. *Int Endod J.* 2014;47(10):989-99. <https://doi.org/10.1111/iej.12237>
PMid:24372408
- Assif D, Oren E, Marshak BL, Aviv I. Photoelastic analysis of stress transfer by endodontically treated teeth to the supporting structure using different restorative techniques. *J Prosthet Dent.* 1989;61(5):535-43. [https://doi.org/10.1016/0022-3913\(89\)90272-2](https://doi.org/10.1016/0022-3913(89)90272-2)
PMid:2664139
- Gurtu A, Reader D, Singhal A. Management of horizontal fracture. *J Dent Sci.* 2012;2012:48-50.
- Linkow LI, Cherchève R. *Theories and Techniques of Oral Implantology.* United States: CV Mosby Co.; 1970.
- Garg N, Garg A. *Textbook of Endodontics.* 4th ed., Ch. 27. New Delhi: Jaypee Brothers Medical Publishers Ltd.; 2019.
- Andreasen JO. Intra-alveolar root fractures: Radiographic and histologic study of 50 cases. *J. Oral Surg.* 1967;25(5):414-26.
PMid:5231441
- Andreasen JO, Ahrensburg SS, Tsilingaridis G. Root fractures: The influence of type of healing and location of fracture on tooth survival rates-an analysis of 492 cases. *Dent Traumatol.* 2012;28(5):404-9. <https://doi.org/10.1111/j.1600-9657.2012.01132.x>
PMid:22443169