



Subcorneal Pustular Dermatoses with Temporary Autoimmune Features during COVID-19 Pandemic

Uwe Wollina^{1*}, André Koch¹, Gesina Hansel¹, Caroline Füllr¹, Jacqueline Schönlebe²

¹Department of Dermatology and Allergology; ²Institute of Pathology "Georg Schmorl," Städtisches Klinikum Dresden, Academic Teaching Hospital of the Technical University of Dresden, Friedrichstrasse 41, 01067 Dresden, Germany

Abstract

Subcorneal pustular dermatosis, Sneddon-Wilkinson, is an uncommon neutrophilic dermatosis of unknown etiology. We report on a 51-year-old woman who presented with multiple superficial erythematous erosions surrounded by annular arranged sterile pustules concentrated on the trunk, the neck, and the proximal extremities during the coronavirus disease-19 pandemic. Large pustules and flaccid bullae showed a hypopyon. There were no fever and no pruritus, general health was unaffected. Laboratory investigations revealed leukocytosis, neutrophilia, lymphopenia, and increased C-reactive protein. Initially, antinuclear antibodies, pemphigoid antibodies, and antibodies to BP 230 were positive, but negative 5 days later. Nasopharyngeal swabs were negative for severe acute respiratory syndrome coronavirus 2 (SARS-CoV-2) RNA tested by real-time reverse-transcriptase-polymerase chain reaction. A diagnostic skin biopsy showed epidermal spongiotic vesiculation and subcorneal pustulation with acantholysis and an inflammatory infiltrate composed of neutrophils and lymphocytes. The confirmed diagnosis was subcorneal pustular dermatosis Sneddon-Wilkinson. She was treated by dapson and corticosteroids with the latter tempered down. Clinical response was rapid. We suggest that the autoimmune features seen on admission may be due to an undefined viral infection, but not SARS-CoV-2.

Edited by: Mirko Spiroski

Citation: Wollina U, Koch A, Hansel G, Füllr C, Schönlebe J. Subcorneal Pustular Dermatoses with Temporary Autoimmune Features during COVID-19 Pandemic. Open Access Maced J Med Sci. 2020 Jun 05; 8(T1):12-15.
<https://doi.org/10.3889/oamjms.2020.4870>

Keywords: Neutrophilic dermatoses; Autoantibodies; Subcorneal pustular dermatosis; Coronavirus disease 2019 pandemic

*Correspondence: Uwe Wollina, Department of Dermatology and Allergology, Städtisches Klinikum Dresden, Friedrichstrasse 41, 01067 Dresden, Germany.
E-mail: Uwe.Wollina@klinikum-dresden.de

Received: 01-May-2020

Revised: 25-May-2020

Accepted: 02-Jun-2020

Copyright: © 2020 Uwe Wollina, André Koch, Gesina Hansel, Caroline Füllr, Jacqueline Schönlebe

Funding: Publication of this article was financially supported by the Scientific Foundation SPIROSKI, Skopje, Republic of Macedonia

Competing Interests: The authors have declared that no competing interests exist

Open Access: This is an open-access article distributed under the terms of the Creative Commons Attribution-NonCommercial 4.0 International License (CC BY-NC 4.0)

Introduction

Neutrophilic dermatoses are a heterogeneous group of chronic inflammatory disorders characterized by the presence of a sterile cutaneous infiltrate of mature neutrophilic leukocytes. Cutaneous presentation can be variable including pustules, papules, plaques, nodules, and ulcerations. Histological examination of skin lesions demonstrates a strong epidermal, dermal, or hypodermal infiltrate composed of neutrophils without any evidence of infection or primary vasculitis. Other important features of neutrophilic dermatoses are the potential occurrence of extracutaneous neutrophilic infiltrates, a frequent association with some systemic diseases, and a possible overlap between several neutrophilic or autoinflammatory disorders [1].

One of the more uncommon neutrophilic dermatoses is subcorneal pustular dermatosis Sneddon-Wilkinson [2]. We report a case during the recent coronavirus disease-19 (COVID-19) pandemic with initially uncommon immunologic findings and discuss the differential diagnosis and treatment.

A 51-year-old woman presented with a rapidly spreading disseminated dermatosis that started 3 days ago. She had no history of fever, infection, or medical drugs. There was no known allergy. She did not use medical drugs and had no chronic disorder. Her family history was negative for skin disease and atopic disease. She was overweight but not obese.

On examination, we observed multiple superficial erythematous erosions surrounded by annular arranged numerous tiny pustules concentrated on the trunk, in particular in the submammary region, the neck, and the proximal extremities. Pustules were asymptomatic and distributed arciform surrounded by an annular erythema (Figure 1).

On the upper extremities, several larger pustules and small flaccid bullae (up to 1 cm in diameter) were observed showing a hypopyon (Figure 2).

Oral and genital mucosa, head, and palmoplantar skin remained unaffected. There was no nail involvement.

She reported no pruritus or pain, but some burning sensations on the erosions. The general health was unaffected.

Laboratory: Leukocytosis of 16.96 Gpt/l (normal range 3.8–11.8), neutrophilia of 13.60 Gpt/l (1.8–7.6), lymphopenia of 10% (25–45), and mild monocytosis of 1.20 Gpt/l (0–1.0). C-reactive protein was 42.7 mg/l (<5). Autoantibodies:antinuclear antibodies (ANAs) 1:160, pemphigus antibodies negative, pemphigoid antibodies initially 1:40, a control 5 days later was negative, antibodies to desmoglein

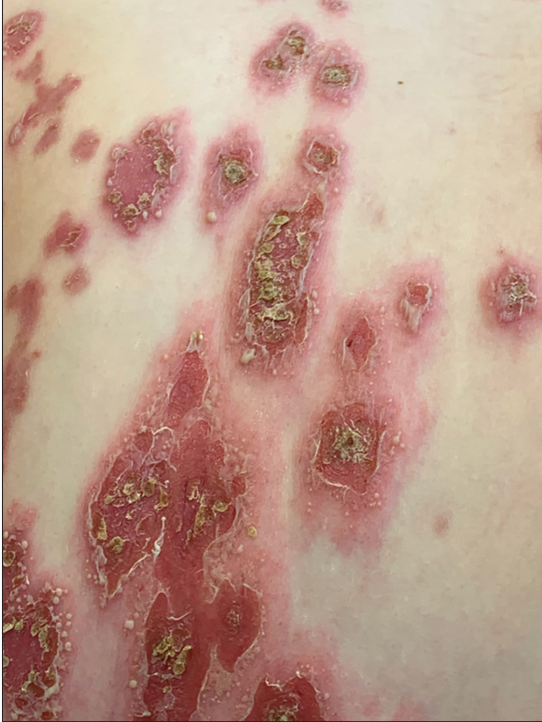


Figure 1: Erythematous erosions surrounded by tiny sterile pustules

1 and 3, IgG and IgA antibodies to gliadin and tissue transglutaminase were negative. Antibodies to BP 180 were negative, while antibodies to BP 230 were positive on admission, but negative 5 days later.

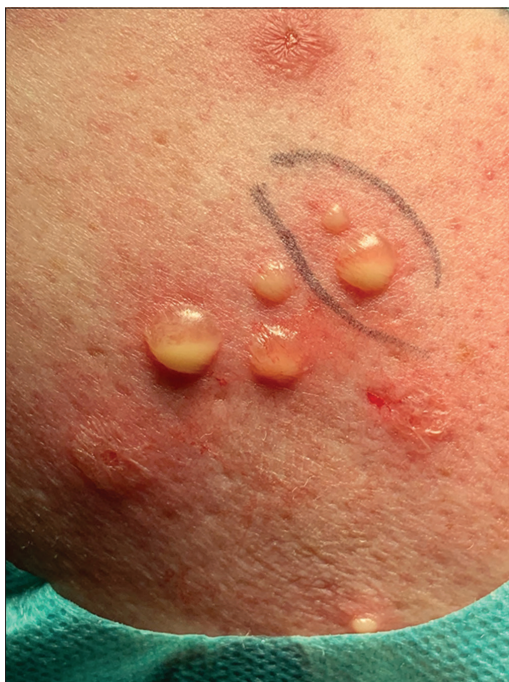

Figure 2: Flaccid pustules and small bullae with hypopyon

No other laboratory abnormalities including protein electrophoresis were noted. Swabs from pustules were sterile. Swabs from erosions, pustules, and nasal mucosa were negative for methicillin-resistant *Staphylococcus aureus*. Nasopharyngeal swabs were negative for severe acute respiratory syndrome coronavirus 2 (SARS-CoV-2) RNA tested by real-time reverse-transcriptase-polymerase chain reaction (rRT-PCR) assay.

A diagnostic skin biopsy was performed from the right upper arm with hypopyon-positive bullae for histopathology and direct immunofluorescence. We performed hematoxylin-eosin, Giemsa, iron, and periodic acid-Schiff stain on formalin-fixed tissue. The orthokeratotic epidermis showed spongiotic vesiculation and centrally subcorneal pustulation with acantholysis. There was a massive subepidermal edema with vesiculation. The upper corium and the stratum papillare demonstrated an inflammatory infiltrate composed of neutrophils and lymphocytes. Some eosinophils were intermingled. The iron reaction remained negative.

Direct immunofluorescence showed an IgG-positive intercellular reaction in the upper epidermis, but remained negative for IgA, IgM, and C3.

The primary differential diagnoses were dermatitis herpetiformis Duhring, pemphigus foliaceus, acute generalized exanthematic pustulosis (AGEP), and subcorneal pustular dermatosis Sneddon-Wilkinson.

Clinical picture, course, laboratory investigations, and histopathology confirmed the diagnosis of Sneddon-Wilkinson disease, probably triggered by an undefined viral infection with pronounced lymphopenia.

We started initially with 100 mg prednisolone per day with minimal improvement but switched to 3 mg × 50 mg dapson/d after laboratory test revealed a normal level of glucose-6-phosphate dehydrogenase. With 24 h after initiation of dapson, almost all pustules disappeared, and the redness of the erosions diminished remarkable (Figures 3 and 4). No new pustules developed thereafter. Systemic corticosteroids were tapered down to zero.

Discussion

Subcorneal pustulosis Sneddon-Wilkinson first described in 1956 is a rare, chronic inflammatory neutrophilic, pseudo-bullous disorder [2]. Middle-aged women are mainly affected, but rare cases from children and elderly people have also been reported [3], [4].

The etiology is unknown, but infections, autoimmune diseases, neoplasia, and blood dyscrasias in patients have been documented with Sneddon-Wilkinson disease. In the present patient, a possible



Figure 3: Dramatic improvement within 24 h of dapsone treatment

viral infection may have been the trigger since we observed a temporary lymphopenia. The most obvious finding is a massive activation of neutrophils in skin and peripheral blood [3].

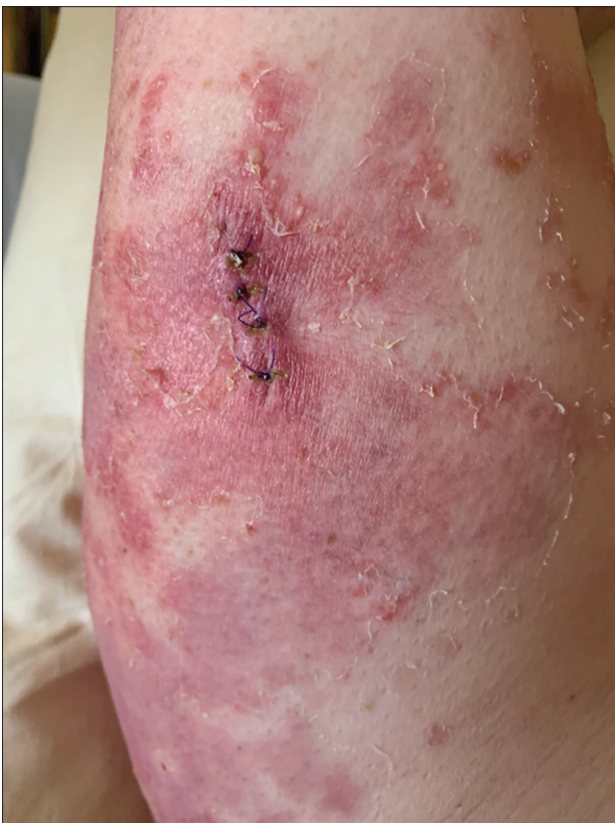

Figure 4: Detail of the skin biopsy area. Most pustules cleared and the inflammation diminished

The differential diagnosis of Sneddon-Wilkinson disease included AGEP, pustular psoriasis, impetigo, and autoimmune bullous disorders including dermatitis herpetiformis Dühring. The hypopyon is seen mainly in Sneddon-Wilkinson disease and Dühring disease [5]. In Dühring disease, however, autoantibodies to gliadin and transglutaminase are present and the cutaneous lesions are extremely pruritic [6].

IgA pemphigus is an important differential diagnosis, where epidermal intercellular IgA and autoantibodies to desmocollin 1, 2, and 3 can be demonstrated [7], [8]. IgA deposits, however, could not be detected in the present case.

The initial intercellular IgG staining of upper epidermis and BP 230 autoantibodies suggested pemphigus foliaceus, but clinical presentation and course argued against. ANAs were positive, but clinically there was no hint for an autoimmune connective tissue disorder. Pemphigoid antibodies were positive, but no clinical signs of this disease, which often affects elderly people, were present. Desmoglein antibodies could not be detected, what is typical in Sneddon-Wilkinson disease [9].

Temporary presence of autoantibodies has been observed in viral infections including HIV, with reduction after decrease of viral load [10], [11]. We suggest that the temporary presence of ANA, pemphigoid and BP 230 autoantibodies, and epidermal intercellular IgG in direct immunofluorescence could be explained by a viral infection. In case of COVID-19 pandemic, we screened for SARS-CoV-2 RNA by RT-PCR, which was negative. The initially observed lymphopenia, however, would be in favor of an (unidentified) viral infection. Within 5 days, all autoimmune features disappeared.

The treatment of choice of Sneddon-Wilkinson disease is oral dapsone. Absolute contraindications for dapsone are hypersensitivity to dapsone or its derivatives including agranulocytosis and hypersensitivity syndrome and glucose-6-phosphate deficiency. The drug needs a regular complete blood count with differential every week for 4 weeks, then every 2 weeks until week 12, then every 3–4 months, a reticulocyte count as needed, and liver function tests and renal function tests every 3–4 months. The methemoglobin level should be measured as clinically indicated [12].

In dapsone-resistant patients or patients with impaired function of glucose-6-phosphate dehydrogenase, therapeutic alternatives include acitretin, psoralen-ultraviolet A photochemotherapy (PUVA), retinoids with PUVA (Re-PUVA), narrowband UVB, and systemic corticosteroids. Anecdotal uses of colchicine, pentoxifylline, ketoconazole, azithromycin, tetracyclines, Vitamin E, ciclosporin, nicotinamide, tumor necrosis-alpha inhibitors, mycophenolate mofetil, and intravenous immunoglobulin have all been reported [3].

Conclusion

Unusual autoimmune phenomena have been observed in Sneddon-Wilkinson disease during the COVID-19 pandemic. Although an infection with SARS-CoV-2 could be excluded another, unidentified viral infection may have caused these temporary laboratory symptoms, lymphopenia, and triggered the onset of subcorneal pustular dermatosis.

References

1. Filosa A, Filosa G. Neutrophilic dermatoses: a broad spectrum of disease. *G Ital Dermatol Venereol.* 2018;153(2):265-272.
2. Sneddon IB, Wilkinson DS. Subcorneal pustular dermatosis. *Br J Dermatol.* 1956;68(12):385-394.
3. Watts PJ, Khachemoune A. Subcorneal Pustular Dermatitis: A Review of 30 Years of Progress. *Am J Clin Dermatol.* 2016;17(6):653-671.
4. Scalvenzi M, Palmisano F, Annunziata MC, Mezza E, Cozzolino I, Costa C. Subcorneal pustular dermatosis in childhood: a case report and review of the literature. *Case Rep Dermatol Med.* 2013;2013:424797.
5. Gillihan R, Merritt J, Beers P, Longo MI. Hypopyon pustules of Sneddon-Wilkinson disease. *Int J Dermatol.* 2019;58(5):605-606.
6. Salmi TT. Dermatitis herpetiformis. *Clin Exp Dermatol.* 2019;44(7):728-731.
7. Düker I, Schaller J, Rose C, Zillikens D, Hashimoto T, Kunze J. Subcorneal pustular dermatosis-type IgA pemphigus with autoantibodies to desmocollins 1, 2, and 3. *Arch Dermatol.* 2009;145(10):1159-1162.
8. Hashimoto T, Teye K, Ishii N. Clinical and immunological studies of 49 cases of various types of intercellular IgA dermatosis and 13 cases of classical subcorneal pustular dermatosis examined at Kurume University. *Br J Dermatol.* 2017;176(1):168-175.
9. Bordignon M, Zattra E, Montesco MC, Alaibac M. Subcorneal pustular dermatosis (Sneddon-Wilkinson disease) with absence of desmoglein 1 and 3 antibodies: case report and literature review. *Am J Clin Dermatol.* 2008;9(1):51-55.
10. Touzeau-Roemer V, Skoll M, Tajpara P, Kienzl P, Wesinger A, Saluzzo S, Bauer M, Aichelburg MC, Bangert C, Bauer W, Stingl G, Rieger A, Grabmeier-Pfistershammer K, Schuster C. Prevalence of Skin-specific Autoantibodies in HIV-infected Patients and Uninfected Controls. *Acta Derm Venereol.* 2019;99(11):978-983.
11. Bundell C, Brunt SJ, Cysique LA, Bruschi A, Brew BJ, Price P. The high frequency of autoantibodies in HIV patients declines on antiretroviral therapy. *Pathology.* 2018;50(3):313-316.
12. Kurien G, Jamil RT, Preuss CV. Dapsone. In: *StatPearls.* Treasure Island (FL): StatPearls Publishing; 2020.