



Short-term Follow-up of Early Reconstructive Surgery Management in Neglected Supracondylar Humeral Fractures

Tito Sumarwoto^{1,2}, Seti Aji Hadinoto^{1,2}, Herlambang Pranandaru^{1,2}, Hanif Andhika^{1,2}, Sholahuddin Rhatomy^{3,4*}, Pamudji Utomo^{1,2}

¹Department of Orthopaedic and Traumatology, Professor Dr. R. Soeharso Orthopaedic Hospital, Surakarta, Jawa Tengah, Indonesia; ²Faculty of Medicine, Sebelas Maret University, Surakarta, Jawa Tengah, Indonesia; ³Department of Orthopaedic and Traumatology, Dr Soeradji Tirtonegoro General Hospital, Klaten, Jawa Tengah, Indonesia; ⁴Faculty of Medicine, Public Health and Nursing, Universitas Gadjah Mada, Yogyakarta, Indonesia

Abstract

Edited by: Ksenija Bogoeva-Kostovska
Citation: Sumarwoto T, Hadinoto SA, Pranandaru H, Andhika H, Rhatomy S, Utomo P. Short-term Follow-up of Early Reconstructive Surgery Management in Neglected Supracondylar Humeral Fractures. Open Access Maced J Med Sci. 2021 Jan 05; 9(B):24-28. https://doi.org/10.3889/oamjms.2021.5577
Keywords: Neglected supracondylar humeral fracture; Quick disabilities of the arm, shoulder, and hand-9 score; Flynn's criteria; Mayo elbow performance score; Early reconstructive surgery
***Correspondence:** Sholahuddin Rhatomy, Department of Orthopaedics and Traumatology, Dr. Soeradji Tirtonegoro General Hospital, Faculty of Medicine, Public Health and Nursing, Universitas Gadjah Mada, Yogyakarta, Indonesia. KRT. Dr. Soeradji Tirtonegoro Street No.1, Tegalyoso, South Klaten, Klaten 57424, Indonesia. Tel.: +62272321102. Fax: +62272321104. E-mail: doktergustomrhatomy@yahoo.com
Received: 16-Nov-2020
Revised: 08-Dec-2020
Accepted: 28-Dec-2020
Copyright: © 2021 Tito Sumarwoto, Seti Aji Hadinoto, Herlambang Pranandaru, Hanif Andhika, Sholahuddin Rhatomy, Pamudji Utomo
Funding: This research did not receive any financial support
Competing Interests: The authors have declared that no competing interests exist
Open Access: This is an open-access article distributed under the terms of the Creative Commons Attribution-NonCommercial 4.0 International License (CC BY-NC 4.0)

BACKGROUND: The supracondylar humeral fracture is a fracture located in the proximal position of the trochlea and humeral capitulum. This fracture is the most common elbow fracture in children. Epidemiological research states that these fractures constitute 58% of all elbow fractures in children. It is also mentioned that 10–20% patients undergo belated admission to get therapy. Based on the literature, the fracture is categorized as neglected if the fracture treatment is 14 days post-trauma. Unfortunately, few reports can provide management guidelines. Some experts mention the “wait and see” attitude toward this fracture until a perfect remodeling happens to correct the deformity; however, a number of studies have shown good results after early reconstruction.

AIM: We aimed to evaluate the short-term follow-up of supracondylar humeral fractures that came after 14 days of injury and then open reduction reconstructions were done, followed by the installation of K-wire and screws with the figure of eight patterns based on the quick disabilities of the arm, shoulder, and hand (Q-DASH) 9-score, Flynn's Criteria, and Mayo Elbow Performance Score (MEPS).

METHODS: The samples were five patients who underwent corrective open reduction and injury fixed with Kirschner (K)-wire and screws with the figure of eight patterns using the posterior approach at the Orthopedic Hospital from December 2019 to February 2020. Results were assessed with the quick disabilities of the arm, shoulder, and hand-9 score (Q-DASH-9 score), Flynn's Criteria, and Mayo Elbow Performance Score (MEPS).

RESULTS: All patients after reconstruction showed an increase in range of motion in the fractured elbow. No complications were found from the surgical treatment.

CONCLUSIONS: Early reconstruction correction of patients with supracondylar humeral fractures gave satisfactory results based on the Q-DASH-9 Score, Flynn's Criteria, and MEPS.

Introduction

Supracondylar humeral fractures are often found in children. The incidence rate ranges from 17.9% of all fracture cases in children [1]. The number reaches 3% of all fractures and is the most common fracture around the elbow in children [2].

Supracondylar humeral fractures are classified according to the modified Gartland classification and most are extension types. This classification is based on the level and direction of displacement and the presence of an intact cortex [3].

Displaced supracondylar humeral fractures are injuries that are difficult to treat and require procedures that are more difficult technically for orthopedic experts [4], [5], [6]. Supracondylar humeral fractures are usually treated in an acute state in pediatric patients [7]. Standard management for this fracture in children is through closed or open reduction and fixation by Kirshner

(K)-wire. However, this procedure cannot be performed on patients who have fractures more than 14 days and have callus formation. There are two options for this case: Doing range of motion (ROM) exercises and then osteotomy after consolidation phase and experiencing cubitus varus or doing an immediate closed reduction and percutaneous fixation with K-wire [8].

If the closed reduction fails, an open reduction is done followed by fixation with K-wire (cross pinning). Open reduction is also often required for supracondylar humeral fractures that come in a neglected state [3]. Severe swelling or problems in the skin around the elbows are acceptable indications for delaying surgical intervention in pediatric supracondylar humeral fractures. In developing countries, problems related to poorly organized health insurance systems and incorrect traditional interventions (by non-medical personnel) can significantly influence the time interval between injury and definitive medical treatment. In these circumstances, many delays in treatment of these

fractures will occur and their management becomes unavoidable for orthopedics [1], [3].

We aimed to evaluate the short-term follow-up of supracondylar humeral fractures that came after 14 days of injury and then open reduction reconstructions were done, followed by the installation of K-wire and screws with the figure of eight patterns based on the quick disabilities of the arm, shoulder, and hand (Q-DASH) 9-score, Flynn's Criteria, and Mayo Elbow Performance Score (MEPS).

Methods

This case series follow-up was conducted in the Orthopedics and Traumatology Department of Prof. Dr. R. Soeharso Orthopaedic Hospital Surakarta from December 2019 to February 2020. Patients with supracondylar humeral fractures who were admitted after 14 days injury and the time of injury not more than 2 months were included in this case series follow-up.

All cases of acute displaced supracondylar humeral fractures or supracondylar humeral fractures after epiphysis closure were not included in this case series. Only patients who had neglected, displaced supracondylar humeral fractures without prior surgical intervention were included as samples.

The clinical evaluation of the patients was conducted carefully preoperatively, including a complete history-taking of the initial trauma along with the injury that followed, the initial treatment, and the reasons why the patient sought for help. The time between the beginning of the injury and the arrival of the patient to the hospital was precisely recorded. Physical examination included careful inspection of the skin and soft tissue around the elbow, deformity or sagging in the elbow area, and active movement of the fingers and elbows. Palpation was done to check the pulsation and tenderness of the elbow area. Radiological examination was done to evaluate the configuration of the fracture and the presence of comminuted fractures or other accompanying injuries around the elbow that can affect management

or prognosis, early callus formation, location of the fracture, and its type, whether extension or flexion type. The Gartland classification was used to categorize the neglected fracture of the supracondylar humeral fracture.

The reconstructive surgery was done under general anesthesia by an upper limb orthopedic surgeon, with an applied tourniquet proximal to the fracture site. The patient was in supine position and posterior approach was used with the incision between 6 and 10 cm of the elbow. After splitting the triceps muscle, the fracture site was found after identifying its exact location on the pre-operative X-ray. Next, any callus was removed in the fracture site, and then open reduction was performed, and the injury was fixed with K-wire 1.6 mm from lateral and medial condyle by screwing cortical screw 3.5 mm-figure of eight snare wire 1.0 mm once the fracture had a satisfactory reduction. All procedures in the surgery always preserved the ulnar nerve at the medial condyle humeral. One day after surgery, the patients were encouraged to attempt early mobilization of the elbow with pain tolerated flexion-extension. Post-operative X-rays were taken to evaluate the result of surgery 1 day afterward.

Results

We identified five cases of neglected supracondylar humeral fractures in children who underwent reconstructive surgery at Prof. Dr. R. Soeharso Orthopedic Hospital that met the inclusion criteria. All of them were males, with their ages between 7 and 12 years. There was no initial medical treatment for all patients and the time period between the initial injury and admission at the hospital for medical treatment varied between 1 and 2 months. Left-sided elbows were affected on two patients (40%) and right elbows on three patients (60%). All of them were closed fractures with no neurovascular injury. There was no previous surgical procedure in the form of closed reduction with the percutaneous K-wire installation before coming to the hospital in a late state see Figure 1 and Table 1a and 1b.

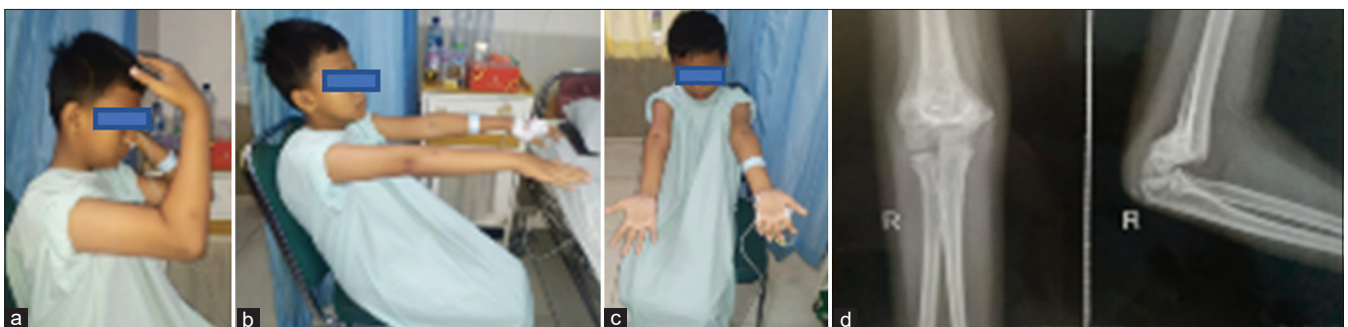

Figure 1: Clinical pictures and X-ray pre-operative JY/12-year-old/male. (a). Patient's elbow movement is limited to 90° of flexion. (b) and (c). Elbow lateral deformity. (d). X-ray finding showed neglected supracondylar humeral fracture

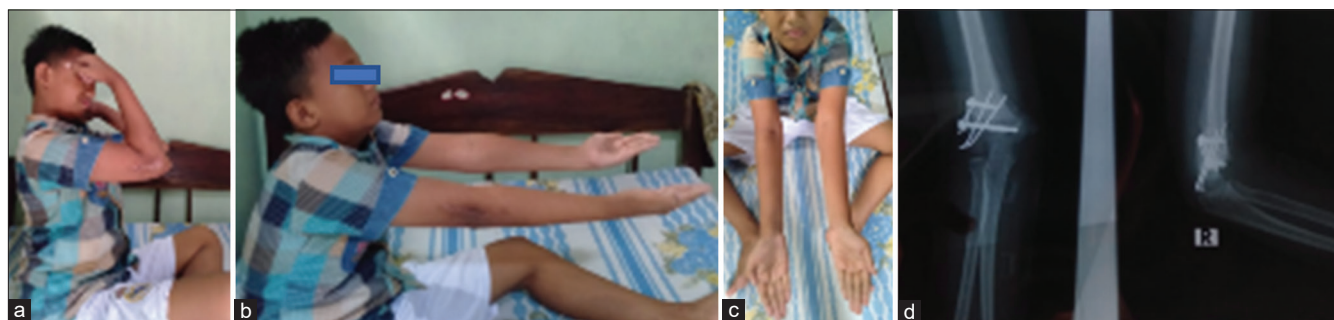


Figure 2: Clinical pictures and X-ray post-operative JY/12-year-old/male. (a). Patient can flex his hand until 90°. (b). Patient can extend his hands with less pain. (c). Patient's hand rearranged to anatomical position. (d). X-ray finding showed good recovery of humerus

Table 1a: Five neglected supracondylar humeral fracture patients – main table

No.	Identity	Diagnosis	MOI	Time of Injury	Non-medical help (bonesetter)	Reconstruction
1.	AD/10 years old/male	Neglected closed supracondylar left humeral fracture extension type Gartland III	Fell while riding a bicycle, left hand held the body and then got crushed by the body	December 2019	3 times	Open reduction – multiple fixation cross k-wire – lateral approach (January 21, 2020)
2.	FP/7 years old/male	Neglected closed supracondylar left humeral fracture extension type Gartland III	Fell while climbing a tree about 1 m height, the left hand holding the body then the left elbow squeezed by the body	November 2019	4 times	Open reduction – multiple fixation cross k-wire – lateral approach (December 19, 2019)
3.	IM/12 years old/male	Neglected closed supracondylar right humeral fracture extension type Gartland III	Fell while climbing a tree about 1 m height, with the outstretched the right hand	January 2020	2 times	Open reduction – multiple fixation cross k-wire – lateral approach (February 27, 2020)
4.	JY/12 years old/male	Neglected closed supracondylar right humeral fracture extension type Gartland III	Fell while running in a position where the right elbow withstands the body's weight first.	December 2019	3 times	Open reduction – k-wire fixation from lateral side – screw + figure of 8 – lateral approach (January 21, 2020)
5.	TS/8 years old/male	Neglected closed supracondylar right humeral fracture extension type Gartland III	Fell when climbing a tree in the position of right elbow withstand the body	October 2019	2 times	Open reduction – multiple fixation cross k-wire – lateral approach (November 17, 2019)

MOI: Mechanism of Injury.

Table 1b: Patients' fractures profiles

No.	Displacement	NVD	Baumann angle		Carrying angle		ROM flexion			ROM extension (lag)			Complication
			n	Post-union	Pre-operative	Post-union	n	side		N	side		
								Pre-operative	Post-operative		Pre-operative	Post-operative	
1.	PM	-	60°	85°	0°	15°	135	45°	95°	0	30°	15°	-
2.	PM	-	70°	75°	-7°	5°	140	90°	135°	0	10°	0°	-
3.	PL	-	75°	80°	-10°	5°	140	80°	125°	0	0°	-5°	-
4.	PL	-	73°	75°	5°	15°	140	60°	130°	0	0°	0°	-
5.	PM	-	75°	65°	3°	20°	140	90°	130°	0	10°	5°	-

NVD: Neurovascular distal; PM: Posteromedial; PL: Posterolateral; ROM: Range of motion.

Each patient showed an increase in ROM in the injured elbow. Evaluation was based on the Q-DASH-9 score, and four patients (80%) achieved the criteria and were classified as “good” and one patient (20%) was included in the “moderate” criteria. Moreover, “bad” criteria were not found in this case series see Table 2 and Figure 2.

Assessment based on MEPS showed four patients (80%) achieved the “excellent” criteria and one patient (20%) was in the “good” criteria. Assessment based on MEPS showed four patients (80%) achieved the “excellent” criteria and one patient (20%) was in the “good” criteria. There were no complications from surgery in the five patients see Table 2.

Flynn's criteria consist of two factors, the “cosmesis factor” (loss of carrying angle) and “functional factor” (loss of motion in degrees) see Table 3.

Discussion

The standard treatment for supracondylar humeral fractures in children is closed reduction or open reduction and K-wire fixation. In neglected cases and those with formed callus, this procedure cannot be performed. There are two treatment options for this case: Osteotomy performed after remodeling and cubitus varus occurred, and pre-operative physiotherapy, or immediate open reduction and K-wire fixation [8].

The late case (neglected) is if the patient comes to the hospital roughly more than 2 days or more than 14 days after the fracture occurs and objectively

Table 2: Q-DASH-9 score and MEPS results

No.	Patient	Q-DASH-9 score	MEPS
1.	AD	15	71
2.	FP	4	93
3.	IM	2	100
4.	JY	2	93
5.	TS	10	80

Q-DASH-9: Quick disabilities of the arm, shoulder, and hand (Q-DASH) 9-score; MEPS: Mayo Elbow Performance Score (MEPS).

Table 3. Final results according to Flynn's Criteria

Result	Level	Amount		Amount		Amount		Amount	
		%		%		%		%	
		Loss of carrying angle				Loss of motion in degree			
		Pre-operative		Post-operative		Pre-operative		Post-operative	
Satisfactory	Excellent (0–5)	2	40	4	80			2	40%
	Good (6–10)	3	60	1	20			2	40
	Fair (11–15)					1	20		
Unsatisfactory	Poor (>15)					4	80	1	20

the callus appears on the X-ray, but the fracture line is still visible [8]. This condition is sometimes due to the economic inability to access medical treatment, assuming that there is no broken bone in the trauma or hindrance in transportation to the hospital. The absence of trained health workers or hospital facilities might also happen in rural areas. In developing countries, the percentage of cases who arrive late increases due to the poor health care system and patients who are far from the hospital, so it is difficult for them to seek immediate treatment [2].

Early treatment of neglected supracondylar humeral fracture can reduce complications, including instability and arthritis [9]. Delaying the surgery can potentially increase the likelihood of compartment syndrome [10]. In neglected cases, there is a risk of failure to obtain satisfactory reduction and repeated closure can lead to post-operative complications [11]. When the callus has already appeared at the fracture site and there is difficulty to recognize the fragment fracture, then obtaining the satisfactory reduction is challenging before it is fixed by K-wire. However, several studies have shown that early surgery provides better results for supracondylar humeral fractures [12]. Reconstruction for displaced supracondylar humeral fractures is relatively more difficult. The disadvantages include iatrogenic nerve injury, increasing radiation exposure, inability to visualize direct quality of the reduction, and requiring more experience [13]. Another meta-analysis of 12 studies with a sample of 1735 fracture cases stated that there was no significant difference between the results for initial surgery versus delayed surgery [14].

The Q-DASH-9 Score, MEPS, and Flynn's criteria are valid instruments for assessing the elbow function. The Q-DASH-9 score includes assessments for activities of daily life, social activities, work, pain, tingling, and sleep. Higher score indicates a greater degree of disability and severity, while a lower score indicates a smaller level of disability, indicating better results [9]. In this case series, each patient showed an increased ROM of the affected elbow.

The MEPS is a performance index that is widely used for evaluating clinical outcomes in various elbow disorders. MEPS is an instrument used to test the elbow limitations caused by pathological conditions during daily life activities. This special test uses four subscales, including pain, ROM/humeroulnar joint arch, flexion strength and elbow extension, and stability [10]. In this study, 80% of patients (four patients) achieved very good results ("excellent") and 20% (one patient) achieved a good result ("good").

Flynn's criteria are used for assessment, based on loss of carrying angle and loss of the total elbow motion range. Based on the carrying angle loss, 80% of patients (four patients) showed satisfactory results with excellent scores (0–5) and 20% (one patient) had good scores (6–10) after reconstructive surgery. These results showed that early reconstructive surgery improves outcome. However, based on the loss of motion in degrees, 80% of patients showed satisfactory results and there was one unsatisfactory patient with a poor score (>15). In late cases of supracondylar humeral fractures with severe displacement, massive edema and soft tissue swelling are often found, which make reconstruction more complicated [15]. Repeated and aggressive reduction manipulations can cause myositis ossificans, joint stiffness, and neuropraxia [16].

ROM flexion-extension of the elbow is very important in daily living activities. Limitations of these ROM tend to decrease quality of life, especially in flexion [7]. All of the patients in this case series had increases in flexion ROM and also decreased lag extension after early reconstructive surgery. Two patients with cubitus varus had already corrected and in the other three, the carrying angle increased. Hence, the cosmesis problem of the elbow had already disappeared. Since we preserved the ulnar nerve in the surgery, none of the patients in this case series showed any nerve complication.

Some limitations found in this study were the small number of patients, short period of time to follow-up, and no comparison with results from other methods. Increasing the number of patients, longer time for the patient follow-up, and then doing a comparison with the results from other methods could give a more comprehensive result of the study.

Conclusions

Immediate surgery of neglected supracondylar humeral fractures gave satisfactory results based on the assessment using the Q-DASH-9 score, Flynn's Criteria, and MEPS, while reducing complications from the time delay of belated reconstruction. Surgical correction management must be performed for pediatric patients with neglected supracondylar humeral fractures to obtain the best functional results.

References

- Mazzini JP, Martin JR, Andres-Esteban EM. Surgical approaches for open reduction and pinning in severely displaced supracondylar humerus fractures in children: A systematic review. *J Child Orthop*. 2010;4(2):143-52. <https://doi.org/10.1007/s11832-010-0242-1>
PMid:21455471
- Eren A, Melih G, Bülent E, Murat C. Delayed surgical treatment of supracondylar humerus fractures in children using a medial approach. *J Child Orthop*. 2008;2(1):21-7. <https://doi.org/10.1007/s11832-007-0072-y>
PMid:19308599
- Kazimoglu C, Cetin M, Sener M, Agus H, Kalanderer O. Operative management of Type III extension supracondylar fractures in children. *Int Orthop*. 2009;33(4):1089-94. <https://doi.org/10.1007/s00264-008-0605-0>
PMid:18597086
- Sadiq MZ, Syed T, Travlos J. Management of grade III supracondylar fracture of the humerus by straight-arm lateral traction. *Int Orthop*. 2007;31(2):155-8. <https://doi.org/10.1007/s00264-006-0168-x>
PMid:16783547
- Oh CW, Park BC, Kim PT, Park IH, Kyung HS, Ihn JC. Completely displaced supracondylar humerus fractures in children: Results of open reduction versus closed reduction. *J Orthop Sci*. 2003;8(2):137-41. <https://doi.org/10.1007/s007760300023>
PMid:12665947
- Kow RY. Surgical management of paediatric neglected humeral supracondylar fracture: A series of 3 cases in 3 years. *Int J Allied Health Sci*. 2019;3(3):783.
- Guo M, Xie Y, Su Y. Open reduction of neglected supracondylar humeral fractures with callus formation in children. *J Pediatr Orthop*. 2020;40(8):e703-7. <https://doi.org/10.1097/bpo.0000000000001518>
PMid:32011548
- Kozin SH, Abzug JM, Safier S, Herman MJ. Complications of pediatric elbow dislocations and monteggia fracture-dislocations. *Instr Course Lect*. 2015;64:493-8.
PMid:25745932
- Putnam M, Christophersen C, Adams J. Pilot report: Non-operative treatment of mayo Type II olecranon fractures in any-age adult patient. *Shoulder Elbow*. 2017;9(4):285-91. <https://doi.org/10.1177/1758573217711889>
PMid:28932286
- Kwok IH, Silk ZM, Quick TJ, Sinisi M, MacQuillan A, Fox M. Nerve injuries associated with supracondylar fractures of the humerus in children: Our experience in a specialist peripheral nerve injury unit. *Bone Joint J*. 2016;98-B(6):851-6. <https://doi.org/10.1302/0301-620x.98b6.35686>
PMid:27235532
- Vaquero-Picado A, González-Morán G, Moraleda L. Management of supracondylar fractures of the humerus in children. *EFORT Open Rev*. 2018;3(10):526-40. <https://doi.org/10.1302/2058-5241.3.170049>
PMid:30662761
- Li J, Rai S, Tang X, Ze R, Liu R, Hong P. Surgical management of delayed Gartland Type III supracondylar humeral fractures in children: A retrospective comparison of radial external fixator and crossed pinning. *Medicine (Baltimore)*. 2020;99(10):e19449. <https://doi.org/10.1097/md.00000000000019449>
PMid:32150100
- Farrow L, Ablett AD, Mills L, Barker S. Early versus delayed surgery for paediatric supracondylar humeral fractures in the absence of vascular compromise: A systematic review and meta-analysis. *Bone Joint J*. 2018;100-B(12):1535-41. <https://doi.org/10.1302/0301-620x.100b12.bjj-2018-0982.r1>
PMid:30499316
- Tomori Y, Nanno M, Takai S. Clinical results of closed versus mini-open reduction with percutaneous pinning for supracondylar fractures of the humerus in children. *Medicine (Baltimore)*. 2018;97(45):e13162. <https://doi.org/10.1302/0301-620x.100b12.bjj-2018-0982.r1>
PMid:30407346
- Prashant K, Lakhota D, Bhattacharyya TD, Mahanta AK, Ravooof A. A comparative study of two percutaneous pinning techniques (lateral vs medial-lateral) for Gartland Type III pediatric supracondylar fracture of the humerus. *J Orthop Traumatol*. 2016;17(3):223-9. <https://doi.org/10.1007/s10195-016-0410-2>
PMid:27312248
- Carter CT, Bertrand SL, Cearley DM. Management of pediatric Type III supracondylar humerus fractures in the United States: Results of a national survey of pediatric orthopaedic surgeons. *J Pediatr Orthop*. 2013;33(7):750-4. <https://doi.org/10.1097/bpo.0b013e31829f92f3>
PMid:24025582