



# The Outcomes of Transcatheter Closure in Patients with Patent Ductus Arteriosus at Haji Adam Malik General Hospital, Indonesia

Putri Amelia<sup>1,2\*</sup>, Rizky Adriansyah<sup>1,2</sup>, Bastian Lubis<sup>3,4</sup>, Muhammad Akil<sup>3</sup>

<sup>1</sup>Department of Child Health, Faculty of Medicine, Universitas Sumatera Utara, Medan, Indonesia; <sup>2</sup>Functional Medical Unit of Child Health, H. Adam Malik Central Hospital, Medan, Indonesia; <sup>3</sup>Department of Anesthesiology, Faculty of Medicine, Universitas Sumatera Utara, Medan, Indonesia; <sup>4</sup>Functional Medical Unit of Anesthesiology, H. Adam Malik Central Hospital, Medan, Indonesia

## Abstract

**Edited by:** Igor Spiroski  
**Citation:** Amelia P, Adriansyah R, Lubis B, Akil M. The Outcomes of Transcatheter Closure in Patients with Patent Ductus Arteriosus at Haji Adam Malik General Hospital, Indonesia. Open Access Maced J Med Sci. 2021 Apr 14; 9(B):208-211. <https://doi.org/10.3889/oamjms.2021.5764>  
**Keywords:** Outcomes; Patent ductus arteriosus; Transcatheter closure  
**\*Correspondence:** Putri Amelia, Division of Cardiology, Department of Child Health, Faculty of Medicine, Universitas Sumatera Utara, Medan, Indonesia.  
E-mail: [putri.amelia@usu.ac.id](mailto:putri.amelia@usu.ac.id)  
**Received:** 22-Jan-2021  
**Revised:** 31-Mar-2021  
**Accepted:** 05-Apr-2021  
**Copyright:** © 2021 Putri Amelia, Rizky Adriansyah, Bastian Lubis, Muhammad Akil  
**Funding:** This article was supported by Universitas Sumatera Utara by Talenta research implementation contracts 2019, number: 248/UN5.2.3.1/PPM/KP-TALENTA USU/2019.  
**Competing Interests:** The authors have declared that no competing interests.  
**Open Access:** This is an open-access article distributed under the terms of the Creative Commons Attribution-NonCommercial 4.0 International License (CC BY-NC 4.0)

**BACKGROUND:** Patent ductus arteriosus (PDA) is one of the most common acyanotic congenital heart diseases. The incidence of PDA is approximately 1 in 500 full-term neonates. The current management of PDA includes pharmacological and surgical treatments. Transcatheter closure is a preferable PDA treatment than pharmacological intervention, for medications have a higher failure rate in premature infants. Several studies have reported the efficacy and safety of transcatheter closure in smaller and lower-weight infants.

**AIM:** This study aims to describe the outcomes of transcatheter closure of PDA, which are complete closure, migrating device, and residuals, while also investigating factors that might affect these outcomes.

**METHODS:** A descriptive cross-sectional study was conducted from January to March 2018 in the pediatric cardiology outpatient clinic of Haji Adam Malik Hospital, Medan, Indonesia. All PDA patients who underwent transcatheter closure were included in this study. We collected patients' demographic data (age and sex), PDA size (categorized into large, moderate, and small), and PDA closure outcomes from medical records. The collected data were then analyzed with SPSS.

**RESULTS:** One hundred and two children were included in this study, comprised 34 (33.3%) males and 68 (66.7%) females, with a mean age of 4.3 ( $\pm 4.02$ ) years old and the mean size of the defects 4.4 ( $\pm 2.25$ ) mm. Transcatheter closure with Lifetech® PDA Occluder was performed in 95 (93.1%) and MFO® in 7 (6.9%) patients. Small residuals were found in three patients, device migration was found in one patient. No relationship was found between the size of PDA and the outcomes measured.

**CONCLUSION:** We concluded that transcatheter closure remains an effective treatment for PDA, with a considerable success rate.

## Introduction

Patent ductus arteriosus (PDA) is one of the most common acyanotic congenital heart diseases (CHD), characterized by a left-to-right shunt [1]. This condition affected 5–10 percent of CHD patients. Recently, there has been an increase in PDA incidence, with 1 in 500 full-term newborns [2]. PDA has affected more than 50 percent of premature neonates, and its presence is associated with high morbidity and mortality rates [3]. PDA with a significant hemodynamic deterioration may cause volume overload in the left ventricle (LV). This problem is usually resolved after the closure of PDA. However, LV systolic dysfunction may persist in some patients [1].

PDA has been managed with prostaglandin antagonists (COX-1 and COX-2 inhibitors), surgical ligation, and even acetaminophen. Drug treatment has shown a high failure rate in most premature infants, from 20 to 30 percent. Therefore, conservative

management and surgery have been suggested as the first-line treatment or an alternative after a failure with prostaglandin inhibitors [3].

In the past decade, percutaneous closure of PDA with detachable coils and Amplatzer Duct Occluder (ADO) has remained a standard therapy [4], [5]. The ADO II is the second generation, which developed to replace the previous version in treating smaller (<2 mm) and nonconical shaped PDA [6], [7], [8]. A study in premature infants suggested that ADO II has improved PDA outcomes, particularly in combination with echocardiography [9]. Transcatheter closure using this device is considered safe and effective in smaller infants, with a weight of 6–10 kg [10], [11], [12]. Furthermore, the ADO II Additional Sizes introduction has made transcatheter occlusion performed with a 4F antegrade delivery sheath become a viable option [3], [13].

This study aims to describe the outcomes of transcatheter closure of PDA at the Haji Adam Malik General Hospital, Medan, and investigate factors that might affect these outcomes.

## Methods

### Study design

This descriptive cross-sectional study investigated the outcomes of transcatheter closure of PDA at the Haji Adam Malik General Hospital, Medan, Indonesia. The procedure was performed by pediatric cardiologists and pediatricians using two types of devices, Lifetech® and MFO®, at the Department of Child Health, Faculty of Medicine, Universitas Sumatera Utara.

We assessed PDA patients' medical records from January 2015 to December 2018. All patients with PDA and treated with transcatheter closure were included in this study. However, we excluded patients with incomplete or broken medical records.

No consent was required for this research. This study was approved by the Ethics Committee of Faculty of Medicine, Universitas Sumatera Utara.

### Data collection

We collected patients' demographic data (age and sex), PDA size (categorized into large, moderate, and small), and PDA closure outcomes. The outcomes investigated were complete closure, residual/incomplete, and migrated device based on echocardiography.

### Statistical analysis

We analyzed the data with SPSS version 26.0. The categorical data were described by their absolute (n) and relative frequencies (%). Meanwhile, the quantitative data were expressed as mean and standard deviation. We used bivariate analysis, the Chi-square or Fisher Exact test, to determine the association between PDA size and transcatheter closure outcomes. The relationship is considered significant if the  $p < 0.05$ .

## Results

We analyzed data from 102 patients who underwent transcatheter closure of PDA in our center over the study period. The mean of patients' ages was 4.3 ( $\pm 4.02$ ) years old. The youngest was 3 months, and the oldest was 16 years old. Thirty-four (33.3%) patients were male, and the remaining 68 patients (66.7%) were female. We performed the closure using Lifetech® PDA Occluder in 95 (93.1%) patients and MFO® in 7 (6.9%) patients (Table 1).

The patients' median weight was 11 ( $\pm 2.25$ ) kg, and the average size of the defects was 4.4 ( $\pm 2.25$ ) mm.

**Table 1: Characteristics of patients**

Characteristic	n
Mean age (SD), years	4.3 (4.02)
Mean weight (SD), kg	13.0 (2.25)
Gender, n (%)	
Male	34 (33.3)
Female	68 (66.7)
Mean size (SD), mm	4.4 (2.25)
Size categories, n (%)	
Small (<1.5 mm)	17 (16.7)
Moderate (1.5-3 mm)	56 (54.9)
Large (>3 mm)	29 (28.4)
Devices, n (%)	
Lifetech® PDA Occluder	95 (93.1)
MFO®	7 (6.9)
Outcomes, n (%)	
Complete closure	98 (96.1)
Residual	3 (2.9)
Migrating device	1 (1.0)

The most common category of the PDA size is the moderate PDA (1.5–3 mm), which was found in 56 (54.9%) patients (Table 1). In contrast, small PDAs (<1.5 mm) were only found in 17 (16.7%) patients, which was the lowest percentage. The proportion of the PDA size categories is illustrated in Figure 1.

We found small residuals in three patients (2.9%) and the device migration in one subject (1%). The complete closure was successfully achieved in most subjects, with 96.1% (Figure 2). We investigated the relationship between the categories of PDA size and the outcomes (complete closure, migrating devices, or residuals) using bivariate analysis. The Fisher Exact test results showed no relationship between the PDA size and the outcomes measured ( $p = 0.27$ ;  $p > 0.05$ ).

## Discussion

In managing PDA, definitive closure should be considered the first-line treatment, except in children with duct-dependent CHD or Eisenmenger syndrome [14], [15], [16]. Drug treatments, such as indomethacin or ibuprofen, have shown a significant failure rate in most premature infants, from 20 to 30 percent [3]. Thus, transcatheter closure might be indicated in every PDA case [14], [15], [16].

Transcatheter closure of PDA has shown a significant success rate in children. In this study, we found that only three children had residuals, and one had the device migrating from its original place. The majority of patients (98 children; 96.1%) were successfully managed with transcatheter closure, completely closing the PDA. A study from Saliba *et al.* suggested a similar success rate (93.7%), and only one patient had a small residual [17]. Likewise, a multicenter study in the USA showed that transcatheter closure was successfully performed in 93% of patients, and complete closure was achieved in 98% of successful implantations [12].

The median age of patients with PDA admitted to our center was 4.3 ( $\pm 4.02$ ) years old. This finding

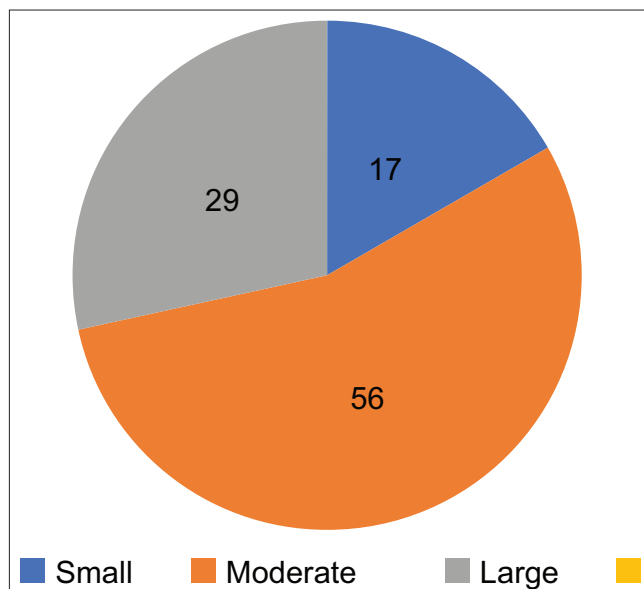


Figure 1: PDA size categories. Small PDA (<1.5 mm): 17 (16.7%), moderate PDA (1.5–3 mm): 56 (54.9%), and large PDA (>3 mm): 29 (28.4%)

is similar to other studies, mostly under 5 years old. A study in Mexico found a mean age of 5 years old (range from 3 months to 14 years) [18], while a study in Korea found a median age of 4.5 years (0.9–6.03 years) [5]. However, some studies investigated PDA in younger age groups in children below 3 years old [2], [3], [11]. The defect's median size was 4.1 (1.2–14.8) mm. Some other studies with similar results are Parra-Bravo *et al.* (mean, 4.4 ± 1.8 mm), Choi *et al.* (median, 3.8 mm), and Park (range 3.2–4.6 mm) [10], [18], [19].

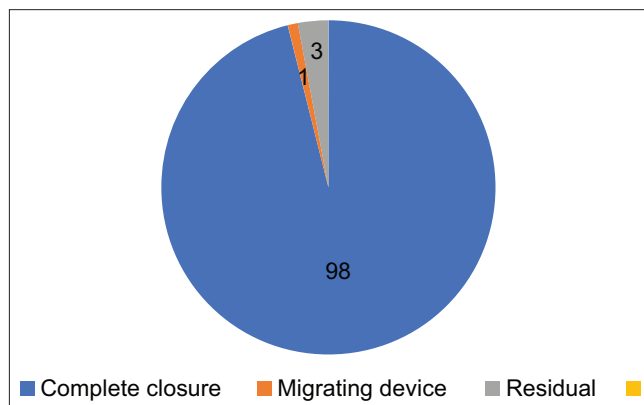


Figure 2: Outcomes of transcatheter closure. Complete closure: 98 (96.1%), migrating device: 1 (1%), residual: 3 (2.9%)

We categorized the size of the defects into three categories: small PDA (<1.5 mm), moderate PDA (1.5–3 mm), and large PDA (>3 mm). We investigated whether there is a relationship between PDA size categories with the outcomes (complete closure, migrating device, and residual) using bivariate analysis. Nevertheless, we failed to find a significant association between these variables ( $p > 0.05$ ). Only a few studies had investigated this relationship before in a relatively small population, and they also suggested no association between PDA size and outcomes of transcatheter closures [20], [21].

Our study showed a considerable success rate of transcatheter closure in children with PDA. The size of defects also not significantly influenced the results of this procedure. Therefore, we can consider that transcatheter closure remains an effective PDA treatment.

## Conclusion

We concluded that transcatheter closure remains an effective treatment for PDA, with a considerable success rate.

## References

- Gupta SK, Krishnamoorthy KM, Tharakan JA, Sivasankaran S, Sanjay G, Bijulal S, *et al.* Percutaneous closure of patent ductus arteriosus in children: Immediate and short-term changes in left ventricular systolic and diastolic function. *Ann Pediatr Cardiol.* 2011;4(2):139-44. <https://doi.org/10.4103/0974-2069.84652> PMID:21976873
- Behjati-Ardakani M, Behjati-Ardakani MA, Hosseini SH, Noori N. Long-term results of transcatheter closure of Patent ductus arteriosus in infants using Amplatzer duct occluder. *Iran J Pediatr.* 2013;23(4):411-6. <https://doi.org/10.4103/1947-2714.157478> PMID:24427494
- Morville P, Akhavi A. Transcatheter closure of hemodynamic significant patent ductus arteriosus in 32 premature infants by Amplatzer ductal occluder additional size-ADOIIAS. *Catheter Cardiovasc Interv.* 2017;90(4):612-7. <https://doi.org/10.1002/ccd.27091> PMID:28471089
- Saliba Z, El-Rassi I, Helou D, Abou-Jaoudeh P, Chehab G, Daou L, *et al.* Development of catheter-based treatment of patent ductus arteriosus: A medium-sized centre experience. *Arch Cardiovasc Dis.* 2009;102(2):111-8. <https://doi.org/10.1016/j.acvd.2008.11.001> PMID:19303578
- Moore JW, Levi DS, Moore SD, Schneider DJ, Berdjis F. Interventional treatment of patent ductus arteriosus in 2004. *Catheter Cardiovasc Interv.* 2005;64(1):91-101. <https://doi.org/10.1002/ccd.20243> PMID:15619281
- Morgan G, Tometzki AJ, Martin RP. Transcatheter closure of long tubular patent arterial ducts: The Amplatzer duct occluder II-a new and valuable tool. *Catheter Cardiovasc Interv.* 2009;73(4):576-80. <https://doi.org/10.1002/ccd.21841> PMID:19235246
- Thanopoulos B, Eleftherakis N, Tzannos K, Stefanadis C. Transcatheter closure of the patent ductus arteriosus using the new Amplatzer duct occluder: Initial clinical applications in children. *Am Heart J.* 2008;156(5):917.e1-6. <https://doi.org/10.1016/j.ahj.2008.08.001> PMID:19061707
- Forsey J, Kenny D, Morgan G, Hayes A, Turner M, Tometzki A, *et al.* Early clinical experience with the new Amplatzer ductal

- occluder II for closure of the persistent arterial duct. *Catheter Cardiovasc Interv.* 2009;74(4):615-23. <https://doi.org/10.1002/ccd.22055>  
PMid:19360878
9. Bass JL, Wilson N. Transcatheter occlusion of the patent ductus arteriosus in infants: Experimental testing of a new Amplatzer device. *Catheter Cardiovasc Interv.* 2014;83(2):250-5. <https://doi.org/10.1002/ccd.22931>  
PMid:24446324
  10. Park YA, Kim NK, Park SJ, Yun BS, Choi JY, Sul JH. Clinical outcome of transcatheter closure of patent ductus arteriosus in small children weighing 10 kg or less. *Korean J Pediatr.* 2010;53(12):1012-7. <https://doi.org/10.3345/kjp.2010.53.12.1012>  
PMid:21253316
  11. Dimas VV, Takao C, Ing FF, Mattamal R, Nugent AW, Grifka RG, et al. Outcomes of transcatheter occlusion of patent ductus arteriosus in infants weighing  $\leq 6$  kg. *JACC Cardiovasc Interv.* 2010;3(12):1295-9. <https://doi.org/10.1016/j.jcin.2010.08.022>
  12. Gruenstein DH, Ebeid M, Radtke W, Moore P, Holzer R, Justino H. Transcatheter closure of patent ductus arteriosus using the AMPLATZER™ duct occluder II (ADO II). *Catheter Cardiovasc Interv.* 2017;89(6):1118-28. <https://doi.org/10.1002/ccd.26968>
  13. Mandhan P, Brown S, Kukkady A, Samarakkody U. Surgical closure of patent ductus arteriosus in preterm low birth weight infants. *Congenit Heart Dis.* 2009;4(1):34-7. <https://doi.org/10.1111/j.1747-0803.2008.00241.x>  
PMid:19207401
  14. Schneider DJ, Moore JW. Patent ductus arteriosus. *Circulation.* 2006;114(17):1873-82.  
PMid:17060397
  15. Yarrabolu TR, Rao PS. Transcatheter closure of patent ductus arteriosus. *Pediatr Ther.* 2012;S5:1-8. <https://doi.org/10.4172/2161-0665.s5-005>
  16. Tharakan J, Venkateshwaran S. Large patent ductus arteriosus: To close or not to close. *Ann Pediatr Cardiol.* 2012;5(2):141-4. <https://doi.org/10.4103/0974-2069.99615>  
PMid:23129902
  17. Saliba Z, El-Rassi IS, Abi-Warde MT, Chehab G, Daou L, Khater D, et al. The Amplatzer duct occluder II: A new device for percutaneous ductus arteriosus closure. *J Interv Cardiol.* 2009;22(6):496-502. <https://doi.org/10.1111/j.1540-8183.2009.00504.x>  
PMid:19780890
  18. Parra-Bravo R, Cruz-Ramírez A, Rebolledo-Pineda V, Robles-Cervantes J, Chávez-Fernández A, Beirana-Palencia L, et al. Transcatheter closure of patent ductus arteriosus using the amplatzer duct occluder in infants under 1 year of age. *Rev Esp Cardiol.* 2009;62:867-74. [https://doi.org/10.1016/s1885-5857\(09\)72651-9](https://doi.org/10.1016/s1885-5857(09)72651-9)  
PMid:19706242
  19. Choi DY, Kim NY, Jung MJ, Kim SH. The results of transcatheter occlusion of patent ductus arteriosus: Success rate and complications over 12 years in a single center. *Korean Circ J.* 2010;40(5):230-4. <https://doi.org/10.4070/kcj.2010.40.5.230>  
PMid:20514333
  20. Hajizeinali A, Sadeghian H, Rezvanfard M, Alidoosti M, Kassaian SE, Nematipour E. Transcatheter closure of patent ductus arteriosus: An initial study on echocardiographic estimation of device size. *J Tehran Heart Cent.* 2010;5(4):199-201.  
PMid:23074593
  21. Azhar AS, Abd El-Azim AA, Habib HS. Transcatheter closure of patent ductus arteriosus: Evaluating the effect of the learning curve on the outcome. *Ann Pediatr Cardiol.* 2009;2(1):36-40. <https://doi.org/10.4103/0974-2069.52804>  
PMid:20300267