



Assessment of Lung Parenchyma Recovery after Antibiotic Administration using Lung Ultrasound in Critically Ill Patients with Pneumonia

MaiAdel Sahbal*¹, Mohammed OmarAlghoneimy¹, Sally Salah Eldine¹, Amr Elsayed Elhadidy¹, Mahmoud Muhammad Kenawy¹

Department of Critical Care Medicine, Cairo University, Giza, Egypt

Abstract

Edited by: Ksenija Bogoeva-Kostovska
Citation: Sahbal MA, Alghoneimy MO, Eldine SS, Elhadidy AE, Kenawy MM. Assessment of Lung Parenchyma Recovery after Antibiotic Administration using Lung Ultrasound in Critically Ill Patients with Pneumonia. Open Access Maced J Med Sci. 2021 Jun 26; 9(B):480-485. https://doi.org/10.3889/oamjms.2021.6153
Keywords: Pneumonia; Lung ultrasound; Thoracic computed tomography
***Correspondence:** Mai Adel Sahbal, Department of Critical Care Medicine, Cairo University, Giza, Egypt. E-mail: dr.maiadelsahbal@gmail.com
Received: 07-Apr-2021
Revised: 12-Jun-2021
Accepted: 16-Jun-2021
Copyright: © 2021 Mai Adel Sahbal, Mohammed Omar Alghoneimy, Sally Salah Eldine, Amr Elsayed Elhadidy, Mahmoud Muhammad Kenawy
Funding: This research did not receive any financial support
Competing Interest: The authors have declared that no competing interest exists
Open Access: This is an open-access article distributed under the terms of the Creative Commons Attribution-NonCommercial 4.0 International License (CC BY-NC 4.0)

BACKGROUND: Pneumonia is a common cause of intensive care unit (ICU) admission, requiring frequent imaging for following up parenchymal lung involvement and antibiotic response. Being bedside and non-invasive technique; lung ultrasound (LUS) is increasingly used in ICU.

AIM: The objectives of the study were to assess the accuracy of LUS in detecting parenchymal lung recovery following antibiotic administration in critically ill patients with pneumonia.

METHODS: Fifty patients with pneumonia were included in the study with time-dependent analysis for acute physiology and chronic health evaluation II, CURB-65 and modified clinical pulmonary infection score. LUS at day 0 described basal lung condition then according to changes in lung parenchyma, ultrasound (US) score could be first calculated at day 3. At day 5, US score was calculated again and changes in score (delta score) were calculated to assess ability of US to predict early good antibiotic response and finally LUS was repeated at day 7, score calculated to detect lung parenchyma recovery and compared with follow-up computed tomography (CT) for accuracy and agreement. Air bronchogram was reported whenever seen, described as static or dynamic, and assessed in follow-up examinations to be compared with CT follow-up.

RESULTS: LUS score ranged from -2 to 17 with mean value of 8.75 ± 3.88 for improving patients, while worsening patients showed LUS score of -11 to -20 with mean value of -10.08 ± 6.95 with high statistical significance ($p < 0.001$). The best cutoff value of LUS score changes for detecting good response to antibiotic was 2.5, detected using area under the curve ($p < 0.001$). US score on day 7 showed excellent sensitivity and specificity of 91.89–92.31%, respectively, when compared to CT with positive predictive value (PPV) of 97.14% and negative predictive value (NPV) 80% and accuracy 92% with strong statistical significance ($p < 0.001$). Air bronchogram showed sensitivity of 61.5% and specificity of 89.1% and with PPV of 66.67% and NPV of 86.84% and accuracy of 82% and moderate agreement (0.52) with CT while B-lines were significant for assessing lung re-aeration with sensitivity of 69.2% and specificity of 67.5% and accuracy of 68% but with fair (0.31) agreement with CT ($p < 0.027$) in detecting parenchymal lung recovery.

CONCLUSION: LUS is a reasonable bedside method for quantifying parenchymal lung recovery in patients with pneumonia who are successfully treated with antibiotics.

Introduction

Pneumonia is a common infection among intensive care unit (ICU) patients either as a primary cause or a complication following hospital admission [1]. Pneumonia is defined as an inflammation of lung parenchyma, in which the affected part is consolidated and the alveoli are filled with inflammatory exudate. Infection by bacteria or viruses is the most common cause [2].

Pneumonia is divided into community acquired, hospital acquired, and ventilator associated (CAP/HAP and VAP) according to the American Thoracic Society (ATS) guidelines [3], [4]. Diagnosis and follow-up require clinical assessment, radiographical examination, and microbiological tests [5].

Radiological assessment by bedside chest radiography (CXR) showed poor accuracy and multiple

limitations [6], [7] that made thoracic computed tomography (CT) the gold standard. Nowadays, bedside lung ultrasound (LUS) is increasingly used; being non-invasive, easily repeatable, with less radiation exposure and no risk of transfer compared to CT [6]. Our study aimed to detect the accuracy of LUS in predicting parenchymal lung recovery following antibiotic administration in critically ill patients with pneumonia.

Methods

The study population

Fifty patients were examined when presented to Critical Care Department, Cairo University, with pneumonia according to the ATS definitions [3], [4].

Inclusion criteria

1. CAP patients admitted to the ICU either due to CURB-65 >2 or other indication for ICU admission
2. HAP patients needed ICU admission due to either severe sepsis, hemodynamic instability, and need for ventilatory support or secondary to another indication apart from pneumonia
3. VAP patients.

Exclusion criteria

Patients <18 years of age, referred from another ICU and those who were suffering from acquired immunodeficiency syndrome-defining condition, or neutropenia (PNLs <1000/mm³), were excluded from the study.

Test methods**Study design**

This was a cross-sectional study.

Data collection and study setting

This study was conducted from October 2018 to October 2019 at the Critical Care Department, Cairo University, Cairo, Egypt.

All patients were subjected to demographic data collection, medical history, thorough clinical examination, ventilator support settings – if needed – and blood, sputum/endotracheal cultures. Patients were managed with antimicrobial therapy protocol according to the ATS guidelines.

Scoring systems were conducted for all patients as follows; (I) acute physiology and chronic health evaluation II score was calculated for all patients at day 0 and analyzed for final outcome. (II) CURB-65 score in patients with CAP (III) modified clinical pulmonary infection score (CPIS) score in HAP/VAP at day of diagnosis (day 0) then both were repeated on day 3, 5, and 7 and analyzed for antibiotic response. Final outcome was assessed at day 28 for death or survival.

LUS protocol

LUS was performed at days 0, 3, 5, and 7 using ultrasound (US) machine manufactured by Siemens electronics (Sonoline Adara) with a regular size convex probe (5 MH frequency).

With patient lying in the supine position, each hemithorax is divided into six areas; 1 and 2 refer to superior and basal anterior areas, respectively; extending between the parasternal line and the anterior

axillary line, 3 and 4 refer to superior and basal lateral areas extending between anterior and posterior axillary line; and 5 and 6 refer to superior and basal posterior areas extending between the posterior axillary and the paravertebral lines [8]. Intercostal spaces of upper and lower parts of the different regions of both lungs were examined, and videos were saved.

The transducer was held perpendicular to the skin surface with the transducer marker (groove) pointed cephalic and the scanning plane directed between adjacent ribs, each region was examined. All lung areas were examined at day 0 and described according to the presence and shape of B lines and consolidation as follows:

B1 for non-coalescent B lines with 7 mm apart; B2 for coalescent B lines; C for lung consolidation; and N for normal pattern (Table 1)[9]. At day 3, lung areas were examined and each lung area was given a score according to shift from previous pattern and then all lung areas scores were summed giving a final score. At day 5, findings were compared to those of day 3, US score was calculated then delta score is also calculated to detect best cutoff value for response and re-aeration. Finally, lung areas were examined at day 7 and lung score was calculated the same as day 5.

Table 1: LUS score for quantification of loss of aeration and re-aeration

Quantification of re-aeration			Quantification of loss of aeration		
1 point	3 points	5 points	-5 points	-3 points	-1 point
B1⇒N	B2⇒N	C⇒N	N⇒C	N⇒B2	N⇒B1
B2⇒B1	C⇒B1	-	-	B1⇒C	B1⇒B2
C⇒B2	-	-	-	-	B2⇒C

LUS: Lung ultrasound.

Air bronchogram is detected whenever seen, it refers to the phenomenon of air-filled bronchi that became visible by the opacification of surrounding alveoli. With lung hepatization, dynamic air bronchograms make pneumonia more likely, while static or no bronchograms make atelectasis more likely.

Culture technique

Sputum culture was obtained from non-ventilated patients and endotracheal aspirate (ETA) or mini-bronchoalveolar lavage (BAL) was performed in ventilated patients at day 0 and repeated at days 3, 5, and 7 as a part of modified CPIS score. Laboratory was informed in case of previous antibiotics use. Samples were processed within 2 h if kept at room temperature and within 24 h if kept at 4°C. Cultures were considered positive once thresholds to diagnose pneumonia were detected: a PSB of >10³ CFU/mL, a mini-BAL of >10⁴ CFU/mL, and ETA>10⁵ CFU/mL [10].

CT protocol

Lung scanning without administering intravenous contrast was performed from the apex to the diaphragm with a 15 s breath hold in spontaneously

breathing patients and induced apnea in ventilated patients. Adjacent axial CT sections 10 mm thick were reconstructed from the volumetric data [11] and recorded. On each CT section, lung parenchyma was manually delineated [12]. The total volume of gas was computed as $(-CT/1000)$ total volume (total number of voxels), where CT is the CT attenuation of voxels with a CT number 0 using the software Lung view [13].

Parenchymal lung recovery and lung reaeration resulting from antibiotics administration were defined as the additional volume of gas detected within both lungs following 5 days of antimicrobial therapy protocol.

To provide similar conditions of measurements at day 0 and day 7, LUS and CT were consecutively performed in the supine position at zero end-expiratory pressure. Each exam was separated by 2 h time interval to regain positive end-expiratory pressure and avoid atelectatic complications in mechanically ventilated patients.

Using this time scheduled follow-up of clinical and microbiological variables; pneumonia was considered as successfully treated by antimicrobial therapy if any of the following criteria were met: (1) Decrease in CPIS for VAP patients; (2) CT reaeration corresponding to partial or complete regression of consolidations and rounded CT attenuations; and (3) either extubation between day 4 and 7 or negative mini-BAL in patients remaining ventilated at day 7.

Statistical methods

Data were coded and entered using the Statistical Package for the Social Sciences version 25. Data were summarized using mean, standard deviation, median, minimum and maximum in quantitative data, and using frequency (count) and relative frequency (percentage) for categorical data. Comparisons between quantitative variables were done using the non-parametric Mann–Whitney U-test. For comparing categorical data, Chi-square (χ^2) test was performed. Exact test was used instead when the expected frequency is <5 . Standard diagnostic indices including sensitivity, specificity, positive predictive value (PPV), negative predictive value (NPV), and diagnostic efficacy were calculated. Receiver operating characteristic (ROC) curve was constructed with area under curve analysis performed to detect best cutoff value of LUS at day 5 and 7 for detection of improvement. $p < 0.05$ was considered as statistically significant. Kappa measure of agreement was used to test agreement between categorical variables.

Results

Participants

Fifty-seven patients were eligible for the study, 50 patients were finally enrolled and analyzed as shown

in patients flowchart (Figure 1), Twenty-one males (42%) and twenty-nine (58%) females were enrolled in the study, with mean age of 63 ± 18 years. About 40% of patients were smokers, 50% were hypertensive, and 52% were diabetic.

The studied population included 10 patients (20%) with CAP, 16 (32%) with early HAP, and 24 patients (48%) with VAP. Best pneumonia response and final outcome were detected among CAP patients with 100% success of treatment and 28 days survival, while patients with HAP and VAP showed 37.5% mortality. Six cases of HAP patients died, four of them with worsening pneumonia, one case due to surgical complications, and the second case secondary to MI and cardiogenic shock. VAP cases showed worsening and death of nine cases of the 15 studied patients.

Highest mortality was seen among patients infected with mixed Gram-negative bacteria (66%) followed by patients with *Acinetobacter* infection (50%) then those with *Klebsiella* (37.5%).

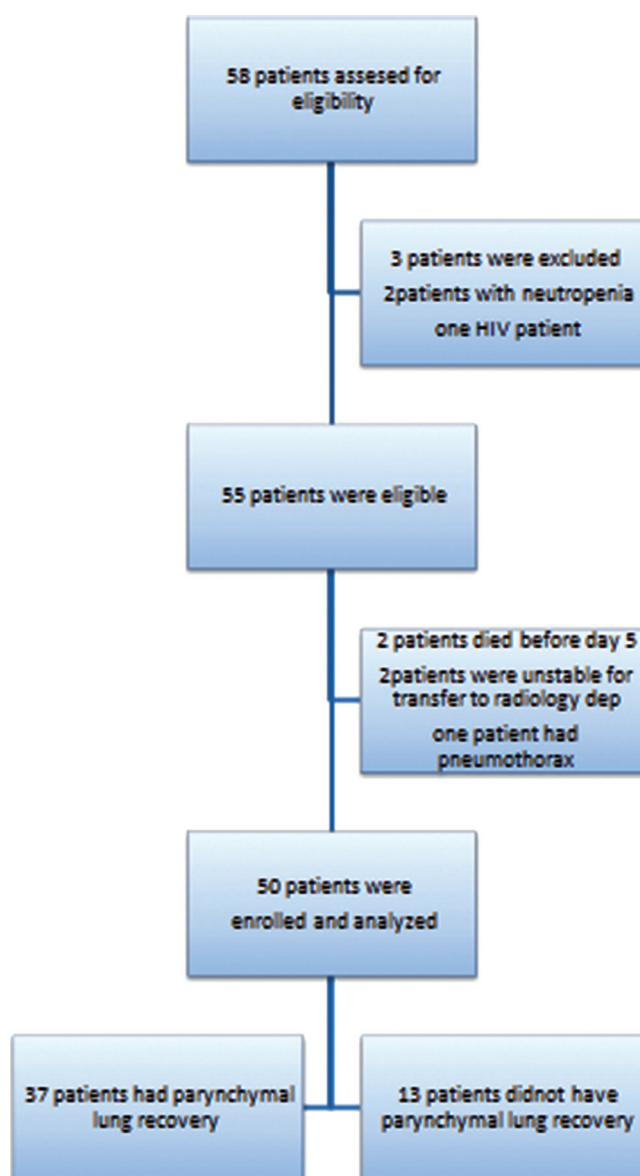


Figure 1: Flowchart of patients included in the study

Test results and estimates of diagnostic accuracy

In 37 patients, pneumonia was considered as successfully treated by antimicrobial therapy on the following arguments: (a) The mean CPIS for HAP and VAP patients had decreased to 4.3 at day 7, CURB 65 score for all CAP patients decreased at day 7 to mean of 1.5; (b) a significant CT reaeration was observed at day 7 together with a partial regression or a complete disappearance of consolidations and round CT attenuations that were present at day 0; (c) 15 patients were extubated between day 4 and 7; and (d) mini-BALs performed in the 15 patients who remained ventilated were negative at day 7.

In 13 patients, VAP and HAP were considered as unsuccessfully treated by antimicrobial therapy on the following arguments: (a) The mean CPIS remained at 6.8; (b) in eight patients, no significant CT reaeration was observed at day 7, corresponding to persisting consolidations and round CT attenuations present at day 1; (c) in five patients, no significant CT reaeration was observed at day 7, corresponding to new consolidations and round CT attenuations, whereas consolidations and round CT attenuations present at day 0 had partially disappeared; (d) the 13 patients were still on mechanical ventilation at day 7; and (e) mini-BALs performed in the 13 patients were all positive at day 7.

Therapeutic failure was related to lack of eradication of causative microorganism in four patients and to secondary lung infection by another microorganism resistive to the antimicrobial therapy in four patients. Lung morphology characterizing ventilator-associated pneumonia, in nine patients, VAP was exclusively characterized by intraparenchymal and subpleural rounded CT attenuations disseminated within upper and/or lower lobes. In five patients, VAP was exclusively characterized by consolidations of lower lobes associated or not with consolidation of upper lobes. In 36 patients, VAP was characterized by an association of consolidations affecting one or several lobes with intraparenchymal and subpleural rounded CT attenuations disseminated within upper and/or lower lobes. Rounded CT attenuations were either isolated or confluent, forming more or less extended ground glass areas. Their size ranged between 1 and 15 mm, and many of them were subpleural, surrounded by normally aerated lung parenchyma.

Comparing CT chest and LUS showed improvement of 34 patients and worsening of 12 patients in both. Disagreement was detected between the two tests in four cases, one case showed improvement in lung US score but not in CT chest and the other three cases showed improvement in CT chest only.

Lung US score ranged from -2 to 17 with mean value of 8.75 ± 3.88 for improving patients. Patients, while US score in patients with worsening pneumonia ranged from -20 to 2 with mean value of -10.08 ± 6.95 with high statistical significance (Table 2).

Table 2: LUS score at day 7 between the two groups

US score	Pneumonia response						p-value
	Improved			Worsened			
	Mean \pm SD	Min	Max	Mean \pm SD	Min	Max	
LUS score at day 7	8.57 ± 3.88	-2.00	17.00	-10.08 ± 6.95	-20.00	2.00	<0.001*

LUS: Lung ultrasound.

US score at day 7 showed excellent sensitivity and specificity of 91.89% and 92.31%, respectively, when compared to CT, with PPV of 97.14% and NPV of 80% and accuracy of 92% with strong statistical significance ($p < 0.001$).

Best cutoff value of LUS score for detecting good response to antibiotics was 2.5 ($p < 0.001$), with lower bound of 0.975, upper bound of 1.000, and area under the curve (AUC) of 0.992 and with 91.9% sensitivity and 100% specificity, with p value > 0.001 and confidence interval (CI) of 95% (Table 4).

US score showed high agreement with CT when running Kappa statistics between the two judgments (Table 3).

Table 3: Agreement between US score, air bronchogram, B lines, and CT at day 7

US variables	Value	Asymptomatic standard error	Approximate T	p-value
US score	Kappa 0.802	0.094	5.699	<0.001*
Air bronchogram	Kappa 0.520	0.139	3.684	0.001
B lines	Kappa 0.307	0.131	2.312	0.027

US: Ultrasound, CT: Computed tomography.

Sub-analysis of air bronchogram showed that 27 (54%) patients had a dynamic air bronchogram and 16 (32%) patients had a static air bronchogram. After treatment, in 24 (48%) patients, the air bronchogram disappeared and resolved (totally reaerated); in 6 (12%) patients, air bronchogram became dynamic after being static (partially reaerated); and in 7 (14%) patients, the air bronchogram was static: In the latter case, in 1 (2%) case, the dynamic air bronchogram became static, and in 6 (12%) patients, the static air bronchogram remained static with $p > 0.001$, sensitivity of 61.5% and specificity of 89.1% and with PPV of 66.67% and NPV of 86.84% and accuracy of 82% and with moderate agreement between the air bronchogram and CT when running Kappa statistics between two judgments (Table 4).

Table 4: B-lines and air bronchogram progression between day 0 and day 7

US variables analysis	Day 0		Day 7		p-value
	Count	%	Count	%	
Air bronchogram					
Resolved	7	14.0	33	66.0	<0.001
Dynamic	27	54.0	10	20.0	
Static	16	32.0	7	14.0	
B-lines					
Present	50	100.0	12	24.0	<0.001
absent/improved	0	0.0	38	76.0	

Studying B-lines before antibiotic administration (day 0) showed that 100% of patients had B-lines versus 24% at day 7 after antibiotic administration with $p < 0.001$ with sensitivity of 69.2% and specificity of 67.5% and accuracy of 68% but with fair (0.31) agreement with CT chest $p < 0.027$ (Table 3).

Discussion

Pneumonia is a common infection worldwide with increasing use of LUS among patients; especially those in ICUs. In our study, lung US score at day 7 showed excellent sensitivity and specificity when compared to pneumonia response (CT re-aeration at day 7) of 91.89% and 92.31%, respectively, with PPV of 97.14% and NPV of 80% and accuracy of 92%.

Similarly, Peris *et al.* reported the effectiveness of bedside US in the ICU setting with decline in the use of chest radiographs (26%) and CT scans (47%) [14]. Furthermore, Vitturi *et al.* reported good concordance between chest US when compared with chest CT in diagnosing different lung diseases [15].

Another study performed by Lichtenstein and Mezière compared bedside CXR diagnostic accuracy with that of LUS to report much higher accuracy for LUS in diagnosing pleural effusion, alveolar consolidation, and alveolar interstitial syndrome [16].

In our study, we detected that change of LUS score by 2.5 as a best cutoff value ($p < 0.001$) reflecting good antibiotic response with a sensitivity of 91.9 and specificity of 100%. When El-Moursi *et al.* studied accuracy of US score in the assessment of pulmonary re-aeration in VAP after antibiotic administration, the ROC curve for chest US reported 1.000 as best cutoff value for US assessment score ($p < 0.001$) with sensitivity of 100% and specificity of 100% [17].

They reported that 100% of patients had B-lines at day 0 versus 24% at day 5 after antibiotic administration with $p < 0.001$, which means that the B-lines were significant for assessing lung re-aeration and good antibiotic response. Furthermore, Cortellaro *et al.* and Lichtenstein have demonstrated that patients with VAP [16], [18] and with ground-glass opacification on CT would have B-lines in lung US and that B-line correlates with interstitial edema may be focal or diffuse. Also Bouhemad *et al.* described antibiotic response by lung US in VAP patients with disappearance of B-lines and comet tails or transformation of lung consolidation into comet tails [8].

Inversely, poor antibiotic response was associated with new appearance of lung comets (87%), consolidation (3%), or transformation comets into consolidation (7%) in LUS, With corresponding CT changes in the form of appearance of new rounded opacities disseminated within both lungs [19].

Bouhemad *et al.* reported poor accuracy of CXR in detecting changes in lung aeration after antimicrobial therapy in contrast to LUS that could detect antibiotic effectiveness in the follow-up of VAP when compared with CT scan. Whereas antibiotic failure corresponds to new subpleural consolidation appearance or coalescing in lobar consolidation. In this study on VAP patients, lung re-aeration after 7 days of

antimicrobial therapy was measured by CT scan and compared with LUS re-aeration score [8].

Conclusion

The chest US is reasonable tool for assessing parenchymal lung recovery in patients with pneumonia who are successfully treated with antibiotics with very good sensitivity and specificity in comparison with CT chest. It is reasonable bedside method, especially for unstable patients for whom transfer for CT chest carries considerable risk.

Future Research Implications

Conducting similar studies with larger number of patients to confirm results and study lung US ability to detect pneumonia complications and presence of underlying pathology in comparison with CT.

Study Limitations

All the ICU research teams were not gathered except for the time of their scheduled shifts and rounds, so patient examination was delivered individually not in groups.

Acknowledgment

The research team especially thanks each and everyone in the critical care department at Cairo University Hospital for their utmost help and welcome that was priceless for completion of this research.

References

1. Lichtenstein DA. Ultrasound in the management of thoracic disease. *Crit Care Med*. 2007;35(Suppl):S250-61.
2. Reissig A, Kroegel C. Sonographic diagnosis and follow-up of pneumonia: A prospective study. *Respiration*. 2007;74(5):537-47. <https://doi.org/10.1159/000100427> PMID:17337882
3. Govindan S, Hyzy RC (2016) The 2016 guidelines for hospital-acquired and ventilator-associated pneumonia. A selection correction? *Am J Respir Crit Care Med* 194:658–660. <https://doi.org/10.1164/rccm.201607-1447ED>

4. Mandell LA, Wunderink RG, Anzueto A, Bartlett JG, Campbell GD, Dean NC, Dowell SF, File TM Jr, Musher DM, Niederman MS, Torres A, Whitney CG; Infectious Diseases Society of America; American Thoracic Society. Infectious Diseases Society of America/American Thoracic Society consensus guidelines on the management of community-acquired pneumonia in adults. *Clin Infect Dis*. 2007 Mar 1;44 Suppl 2(Suppl 2):S27-72. doi: 10.1086/511159. PMID: 17278083; PMCID: PMC7107997.
5. Zilberberg MD, Shorr AF. Ventilator-associated pneumonia: the clinical pulmonary infection score as a surrogate for diagnostics and outcome. *Clin Infect Dis*. 2010;51(Suppl 1):S131-5. <https://doi.org/10.1086/653062> PMID:20597663
6. Rubinowitz AN, Siegel MD, Tocino I. Thoracic imaging in the ICU. *Crit Care Clin*. 2007;23(3):539-73. <https://doi.org/10.1016/j.ccc.2007.06.001> PMID:17900484
7. Henschke CI, Yankelevitz DF, Wand A, Davis SD, Shiau M. Accuracy and efficacy of chest radiography in the intensive care unit. *Radiol Clin North Am*. 1996;34(1):21-31. PMID:8539351
8. Bouhemad B, Zhang M, Lu Q, Rouby JJ. Clinical review: Bedside lung ultrasound in critical care practice. *Crit Care*. 2007;11(1):205. <https://doi.org/10.1186/cc5668> PMID:17316468
9. Bouhemad B, Liu ZH, Arbelot C, Zhang M, Ferarri F, Le-Guen M, et al. Ultrasound assessment of antibiotic-induced pulmonary reaeration in ventilator-associated pneumonia. *Crit Care Med*. 2009;38(1):84-92. <https://doi.org/10.1097/ccm.0b013e3181b08cdb> PMID:19633538
10. Raman K, Nailor MD, Nicolau DP, Aslanzadeh J, Nadeau M, Kuti JL. Early antibiotic discontinuation in patients with clinically suspected ventilator-associated pneumonia and negative quantitative bronchoscopy cultures. *Crit Care Med*. 2013;41(7):1656-63. <https://doi.org/10.1097/ccm.0b013e318287f713> PMID:23528805
11. Lu Q, Malbouisson M, Mourgeon E, Goldstein I, Coriat P, Rouby JJ. Assessment of PEEP-induced reopening of collapsed lung regions in acute lung injury: Are one or three CT sections representative of the entire lung? *Intensive Care Med*. 2001;27(9):1504-10. <https://doi.org/10.1007/s001340101049> PMID:11685344
12. Puybasset L, Cluzel P, Gusman P, Grenier P, Preteux F, Rouby JJ. Regional distribution of gas and tissue in acute respiratory distress syndrome, I: Consequences for lung morphology. CT Scan ARDS Study Group. *Intensive Care Med*. 2000;26(7):857-69. <https://doi.org/10.1007/s001340051274> PMID:10990099
13. Malbouisson LM, Preteux F, Puybasset L, Grenier P, Coriat P, Rouby JJ. Validation of a software designed for computed tomographic (CT) measurement of lung water. *Intensive Care Med*. 2001;27:602-8. <https://doi.org/10.1007/s001340100860>
14. Peris A, Tutino L, Zagli G, Batacchi S, Cianchi G, Spina R, et al. The use of point-of-care bedside lung ultrasound significantly reduces the number of radiographs and computed tomography scans in critically ill patients. *Anesth Analg*. 2010;111(3):687-92. <https://doi.org/10.1213/ane.0b013e3181e7cc42> PMID:20733164
15. Vitturi N, Dugo M, Soattin M, Simoni F, Maresca L, Zagatti R, et al. Lung ultrasound during hemodialysis: The role in the assessment of volume status. *Int Urol Nephrol*. 2014;46(1):169-74. <https://doi.org/10.1007/s11255-013-0500-5> PMID:23884727
16. Lichtenstein DA, Mezière GA. Relevance of lung ultrasound in the diagnosis of acute respiratory failure: The BLUE protocol. *Chest*. 2008;134(1):117-25. <https://doi.org/10.1378/chest.07-2800> PMID:18403664
17. El-Moursia AA, Besheya BN. Ultrasound assessment of antibiotic-induced pulmonary reaeration in ventilator-associated pneumonia. *Res Opin Anesth Intens Care*. 2017;4:7-16. <https://doi.org/10.4103/2356-9115.202699>
18. Cortellaro F, Colombo S, Coen D, Duca PG. Lung ultrasound is an accurate diagnostic tool for the diagnosis of pneumonia in the emergency department. *Emerg Med J*. 2012;29(1):19-23. <https://doi.org/10.1136/emj.2010.101584> PMID:21030550
19. Beckh S, Bölskei PL, Lessnau KD. Real-time chest ultrasonography: A comprehensive review for the pulmonologist. *Chest*. 2002;122(5):1759-73. <https://doi.org/10.1378/chest.122.5.1759> PMID:12426282