



Immunohistochemical Expression of “HE4” in Endometrial Hyperplasia versus Endometrial Endometrioid Carcinoma

Amany Talaat Abd El-Hamed*, Samira Abd-Allah Mahmoud, Ahmed A. Soliman, Dina F. El-Yasergy

Department of Pathology, Faculty of Medicine, Cairo University, Cairo, Egypt

Abstract

Edited by: Sinisa Stojanoski
Citation: Abd El-Hamed AT, Mahmoud SA, Soliman AA, El-Yasergy DF. Immunohistochemical Expression of “HE4” in Endometrial Hyperplasia versus Endometrial Endometrioid Carcinoma. Open Access Maced J Med Sci. 2021 Aug 07; 9(A):669-675. <https://doi.org/10.3889/oamjms.2021.6189>
Keywords: Endometrial carcinoma; Endometrial hyperplasia; HE4; Immunohistochemistry
***Correspondence:** Amany Talaat Abd El-Hamed, Department of Pathology, Faculty of Medicine, Cairo University, Cairo, Egypt. E-mail: amanytalaat_85@yahoo.com
Received: 13-Apr-2021
Revised: 25-Jul-2021
Accepted: 28-Jul-2021
Copyright: © 2021 Amany Talaat Abd El-Hamed, Samira Abd-Allah Mahmoud, Ahmed A. Soliman, Dina F. El-Yasergy
Funding: This research did not receive any financial support
Competing Interests: The authors have declared that no competing interests exist
Open Access: This is an open-access article distributed under the terms of the Creative Commons Attribution-NonCommercial 4.0 International License (CC BY-NC 4.0)

BACKGROUND: Endometrial cancer is the most common cancer of the female genital tract. No effective biomarkers currently exist to allow for an efficient risk classification of endometrial carcinoma. Human epididymis protein 4 (HE4) overexpression is first observed in ovarian cancer tissue and subsequent research has shown that the HE4 overexpression has also been observed in patients with endometrial carcinoma. To the best of our knowledge, this marker was evaluated in small number of research studies in cases of endometrial carcinoma versus hyperplasia.

AIM: This has inspired us to test for immunohistochemical expression of HE4 in endometrial endometrioid carcinoma and hyperplastic endometria and to correlate HE4 expression with various prognostic pathological parameters including the International Federation of Gynecology and Obstetrics (FIGO) grading and staging.

METHODS: Immunohistochemical staining for HE4 was performed on paraffin-embedded sections of forty cases of endometrial endometrioid carcinoma and thirty cases of endometrial hyperplasia: including 15 cases of non-atypical hyperplasia and 15 cases of atypical hyperplasia. A histochemical score was used to evaluate HE4 expression by the tumor cells.

RESULTS: In this study, HE4 overexpression level was significantly higher in endometrial endometrioid carcinoma than endometrial hyperplasia and significantly higher than non-atypical endometrial hyperplasia ($p < 0.05$). HE4 strong expression was detected in 20% of atypical endometrial hyperplasia, but no statistical significance was detected between atypical hyperplasia and endometrial carcinoma. HE4 overexpression showed statistically significant positive correlation with FIGO grading, FIGO staging, and depth of myometrial invasion.

CONCLUSION: During interpretation of endometrial biopsies of atypical hyperplasia, HE4 strong expression might raise the possibility of the presence of coexisting adenocarcinoma not biopsied or even warning of a near future malignant transformation. Furthermore, strong expression of HE4 by tissue biopsy of adenocarcinoma should be reported as this might predict higher grade and stage of the tumor, a point that should be considered by surgeons while performing hysterectomy. These results should be further confirmed by extending the study on a large scale, correlation of HE4 expression with the molecular classification of Tumor Cancer Genome Atlas and long-term follow-up are required to establish the prognostic significance of HE4 expression in endometrial carcinoma and atypical hyperplasia.

Introduction

Endometrial cancer is a malignant cancer arising from the endometrial epithelium, accounting for 20% to 30% of malignant tumors in the female reproductive system. Due to increased obesity, hypertension, diabetes, and prolonged life expectancy, the incidence and mortality of endometrial cancer have risen, with a tendency for onset at a younger age [1].

Approximately 90% of cases of endometrial cancer are sporadic, whereas the remaining 10% of cases are hereditary. Two major types are distinguished. Type I (estrogen-dependent) endometrial cancers represent the majority of sporadic cases, accounting for 80–85% of cases and these tumors are of endometrial histology. Type II is not estrogen-dependent, make up the remaining 10–15% of cases [2].

HE4, also known as whey acidic protein (WFDC2) was discovered in the human epididymal

epithelium. It is a protease inhibitor which is associated with innate immunity and sperm maturation. HE4 is mainly expressed in germinal epithelium, oviduct epithelium, Bartholin’s gland of females, and endometrial glands [3], [4]. Its overexpression is first observed in ovarian cancer tissue [5]. It has a better sensitivity, specificity than CA-125 in the diagnosis of ovarian cancer [6]. Subsequent research has shown that the overexpression of HE4 not only exists in patients with ovarian cancer but has also been observed in patients with endometrial carcinoma [7], [8].

CA125 is the major marker in the diagnosis and monitoring of endometrial cancer, but it is less sensitive and specific in diagnosing endometrial cancer compared to ovarian cancer; thus, it is only suitable for cases with advanced or recurrent endometrial cancer. Therefore, finding out other tumor markers is of great significant [9]. HE4 immunohistochemical expression in patients with endometrial carcinoma was significantly higher than that in patients with

hyperplasia and in those with normal endometrial tissue, which provides a preliminary theoretical reference for basic research on the role of HE4 in endometrial cancer development [10], [11], [12]. The exact function of the HE4 protein is unknown, but some studies have demonstrated that overexpression of HE4 enhances cell adhesion and migration while suppression of HE4 markedly inhibits the growth of tumor cell [13]. Overexpression of HE4 in endometrial carcinoma cell lines induced proliferation of cancer cells *in vitro* and *in vivo*, supporting a function for HE4 in tumor progression. HE4 may be beneficial as a useful prognostic biomarker for endometrial carcinoma. Overexpression of HE4 is associated with increases in the FIGO stage and grade [14].

Materials and Methods

Retrieval of cases

This study included forty cases of endometrial endometrioid carcinoma and thirty cases of endometrial hyperplasia obtained through collection of archived paraffin blocks during the period from January 2018 till February 2019, from the Pathology Department, Kasr AL-Ainy, Faculty of Medicine, Cairo University. The forty cases of endometrial carcinoma were obtained from total hysterectomy with bilateral salpingoophorectomy specimens and the thirty cases of endometrial hyperplasia were obtained from endometrial biopsies.

The data collected from the pathology reports of these cases included age at the time of diagnosis, the extent of myometrial invasion, presence of tumor involvement of the cervix, adnexa, and parametrium.

Cases received neoadjuvant therapy or cases with missed data were excluded from the study.

Histopathological examination

Each paraffin block was re-cut by rotatory microtome at 4 μ m thickness then mounted on glass slides and stained by hematoxylin and eosin (H and E) for routine histopathological examination which included:

- Histological classification according to the latest World Health Organization recommendations [15].
- Histological grading according to the FIGO grading system [16].
- Pathological staging according to the FIGO staging system [17] and the eighth edition (2017) of the American Joint Committee on Cancer's AJCC Cancer Staging Manual [18].

HE4 Immunohistochemical staining and evaluation

Paraffin sections were cut at 4 μ m thickness on positively charged slides. Immunostaining was done using BenchMark XT (Ventana) autostainer.

A section of epididymis was used as positive control according to the manufacturer recommendations.

HE4 Immunohistochemical staining results, brown-stained granules on the cell membrane and cytoplasm, were regarded as positive. Based on the intensity of color, uncolored, light yellow, yellowishbrown, and brown were scored as 0, 1, 2, and 3, respectively. The percentage of stained cells in the field of view was calculated as follows: five consecutive high-powered fields in each section were observed under a 400x optical microscope, and then the scores were averaged. The proportion of positive cells <5% was recorded as 0, 5%–25% as 1, 26%–50% as 2, 51%–75% as 3, and >75% as 4. The final score was equal to the multiplication of the two scores: 0–2 as negative (-), 3–4 as weakly positive (+), and 5–12 as strongly positive (2+/3+) expression [11].

Statistical analysis

The histopathological and immunohistochemical data were then transferred to the SPSS Software program, version 25 to be statistically analyzed. Simple descriptive statistics (arithmetic mean and standard deviation) were used for the summary of quantitative data and frequencies were used for qualitative data. Estimation of the association between categorical variables was performed using the chi-square test. $p < 0.05$ is considered as statistically significant.

Results

This study included forty cases of endometrial endometrioid carcinoma and thirty cases of endometrial hyperplasia. Fifty-seven percent (57%) of studied cases were endometrial endometrioid carcinoma, 21.5% of cases were endometrial hyperplasia without atypia and 21.5% were atypical endometrial hyperplasia. The age of endometrial malignancy cases ranged in age from 39 to 77 years with a mean of age 62 years. Concerning FIGO grade of carcinoma cases, 35% of the cases were Grade 1, 37.5% were Grade 2, and 27.5% were Grade 3. Regarding the FIGO stage, 55% of the cases were classified as FIGO Stage I, 27.5% of the cases were FIGO Stage II, and 17.5% of the cases were FIGO Stage III.

Less than half myometrial invasion was documented in 57.5% of the cases and more than half myometrial invasion was documented in 42.5%

of the cases. Cervical, serosal, and/or adnexal and parametrial involvement by the tumor was detected in 27.5%, 10%, and 7.5% of the cases, respectively. The pathological characteristics of the studied carcinoma cases are summarized in Table 1 [1].

Table 1: Pathological characteristics of the studied endometrial carcinoma cases

Pathological characteristics		Number (%)
Histopathological type	Endometrioid carcinoma	40 (100)
FIGO grade	Grade 1	14 (35)
	Grade 2	15 (37.5)
	Grade 3	11 (27.5)
FIGO Stage	I	22 (55)
	II	11 (27.5)
	III	7 (17.5)
Myometrial invasion	Less than half	23 (57.5)
	More than half	17 (42.5)
Cervical involvement	Present	11 (27.5)
	Absent	29 (72.5)
Serosal and/or adnexal involvement	Present	4 (10)
	Absent	36 (90)
Parametrial involvement	Present	3 (7.5)
	Absent	37 (92.5)

In the current study, 32 cases out of the 40 cases of endometrial endometrioid carcinoma (80%) showed positive HE4 immunohistochemical expression in tumor cells while only 17 out of the 30 cases of endometrial hyperplasia (57%) showed positive HE4 immunohistochemical expression. Seventeen cases of endometrial carcinoma (42.5%) showed weak positivity for HE4 immunohistochemical expression and 15 cases (37.5%) showed strong HE4 positivity, while the remaining 20% of the cases were negative for HE4 immunohistochemical expression. Seventeen cases of endometrial hyperplasia (47%) were weakly positive for HE4 immunohistochemical expression and only 3 cases (10%) were strongly HE4 positive, while the remaining 13 cases (43%) showed negative HE4 immunohistochemical expression (Table 2 and Figure 1).

Table 2: HE4 immunohistochemical expression in studied cases of endometrial endometrioid carcinoma and endometrial hyperplasia and its correlation with various pathological characteristics

Parameters	Negative (%)	Weak expression (%)	Strong expression (%)	Total (%)
Endometrial carcinoma	8 (20)	17 (42.5)	15 (37.5)	40 (100)
Endometrial hyperplasia	13 (43)	14 (57)	3 (10)	30 (100)
EH without atypia	10 (67)	5 (33)	0 (0)	15 (100)
Atypical EH	3 (20)	9 (60)	3 (20)	15 (100)
FIGO Grade				
Grade I	3 (21)	8 (58)	3 (21)	14 (100)
Grade II	3 (20)	7 (47)	5 (33)	15 (100)
Grade III	2 (18)	2 (18)	7 (64)	11 (100)
FIGO stage				
Stage I	4 (18)	12 (55)	6 (27)	22 (100)
Stage II	2 (18)	5 (46)	4 (36)	11 (100)
Stage III	2 (29)	0 (0)	5 (71)	7 (100)
Myometrial invasion				
Less than half myometrial thickness	5 (22)	13 (56)	5 (22)	23 (100)
More than half myometrial thickness	3 (18)	4(23)	10 (59)	17 (100)
Cx involvement				
Present	2 (18)	5 (46)	4 (36)	11 (100)
Absent	6 (21)	12 (41)	11 (38)	29 (100)
Parametrial involvement				
Present	1 (33)	0 (0)	2 (67)	3 (100)
Absent	7 (19)	17 (46)	13 (35)%	37 (100)
Serosal/adnexal involvement				
Present	1 (25)	0 (0)	3 (75)	4 (100)
Absent	7 (20)	17 (47)	12 (33)	36 (100)

Endometrial endometrioid carcinoma cases showed higher percentage (37%) of strongly positive

cases for HE4 immunohistochemical expression than endometrial hyperplasia (only 10%) with statistically significant relation ($p = 0.01$) (Table 2 and Figure 1).

Strong expression of HE4 was significantly higher in endometrioid carcinoma (37%) than in endometrial hyperplasia without atypia which showed no strongly positive cases ($p = 0.005$) (Table 2 and Figure 1). There was no statistically significant relation in HE4 expression between endometrioid carcinoma and endometrial atypical hyperplasia ($p = 0.06$) (Table 2).

There was statistically significant relationship between the grade and the level of HE4 expression as Grade 3 carcinoma cases showed the highest percentage of strongly positive cases (64%), followed by Grade 2 (33%) followed by Grade 1 (21%) ($p = 0.04$) (Table 2, Figure 1).

Stage III endometrioid carcinoma cases showed the highest percentage of strongly positive cases (71%), followed by stage II (36%) followed by stage I (27%) with statistically significant relation ($p = 0.03$) (Table 2, Figure 1).

Endometrial endometrioid carcinoma cases invading more than half myometrial thickness showed higher percentage of strongly positive cases (59%), than those with less than half myometrial thickness with statistically significant relation ($p = 0.02$) (Table 2).

There was no statistically significant relation was detected in HE4 immunohistochemical expression among the endometrioid carcinoma cases with and without cervical involvement ($p > 0.05$). Furthermore, there was no statistically significant relation was detected in HE4 immunohistochemical expression among the endometrioid carcinoma cases with and without parametrial, serosal/adnexal involvement ($p > 0.05$) (Table 2).

Discussion

Endometrial cancer is the most common gynecological malignancy. The available histopathological and clinical data do not allow for an efficient and well reproducible risk classification. This is especially true for an early-stage disease where few patients suffer fatal relapse in spite of the absence of the established high-risk criteria. Furthermore, no effective biomarkers currently exist to allow for an efficient risk classification of endometrial carcinoma, to direct treatment (chemotherapy and/or adjuvant radiation) in endometrial cancer, or to triage pelvic and para-aortic lymphadenectomy [19].

HE4 protein has gained a great degree of interest as a complementary biomarker to CA 125, or even as an independent one for monitoring, diagnosis, and prognostic evaluation of ovarian cancer. They have

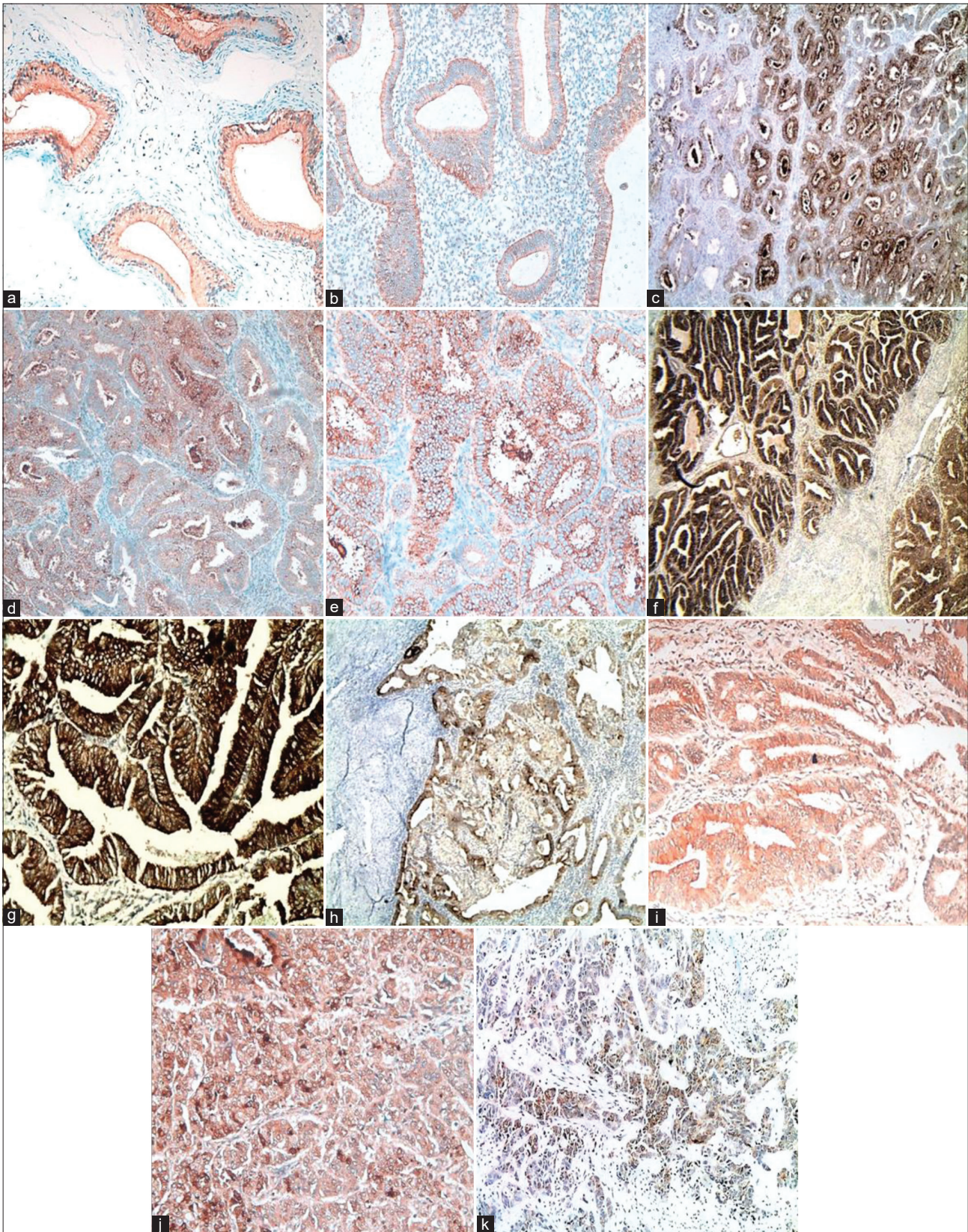


Figure 1: (a) Epididymis (positive control) showing positive immunohistochemical expression of HE4. (b) Simple endometrial hyperplasia without atypia showing weekly positive immunohistochemical expression of HE4. (c) Complex atypical endometrial hyperplasia showing strongly positive immunohistochemical expression of HE4. (d) Complex atypical endometrial hyperplasia showing strongly positive immunohistochemical expression of HE4. (e) Complex atypical endometrial hyperplasia showing strongly positive immunohistochemical expression of HE4. (f) Grade 1 endometrioid carcinoma showing strongly positive immunohistochemical expression of HE4. (g) Villoglandular endometrioid carcinoma grade 1 showing strongly positive immunohistochemical expression of HE4. (h) Grade 2 endometrioid carcinoma showing weekly positive immunohistochemical expression of HE4. (i) Grade 2 endometrioid carcinoma showing strongly positive immunohistochemical expression of HE4. (j) Grade 3 endometrioid carcinoma showing strongly positive immunohistochemical expression of HE4. (k) Grade 3 endometrioid carcinoma showing weekly positive immunohistochemical expression of HE4

suggested that it could also be used in other types of cancers [20].

This study included forty cases of endometrial endometrioid carcinoma obtained from total hysterectomy with bilateral salpingo-oophorectomy and thirty cases of endometrial hyperplasia obtained from endometrial biopsies. All were obtained through collection of archived paraffin blocks during the period from January 2018 till February 2019, from the Pathology Department, Kasr Al-Ainy, Faculty of Medicine, Cairo University.

The mean age of studied endometrial endometrioid carcinoma cases was 62 years (ranging between 39-77 years). This is consistent to surveillance, epidemiology, and end result program (SEER), where the mean age at presentation for EC was reported to be 62 years [21] and was 57.6 years according to the pathology-based cancer registry of Ain-Shams Faculty of Medicine [22].

HE4 was mainly expressed in the cell membrane, and the cytoplasm also showed slight expression. In this study, the positive expression rate of HE4 was 80% in the endometrial cancer group, higher than 67% in the endometrial hyperplasia group, this figure close to that reported by Li *et al.*, 2015 and Deng *et al.*, 2015 [10], [11]. The positive expression rate of HE4 was (84.62% and 85.7%) in the endometrial cancer group higher than (66.67% and 66.7%) in the endometrial hyperplasia group respectively. In accordance to our study, Yang *et al.* (2011) detected HE4 immunohistochemical expression in 31 cases of endometrial carcinoma, 19 cases of endometrial hyperplasia, they showed that the expression of HE4 in the malignant group was significantly higher than that in the hyperplasia group suggesting that HE4 may be involved in the tumor development [12].

In this work, the results showed that the strongly positive expression rate of HE4 in endometrioid carcinoma cases (37.5%) was significantly higher than that in endometrial hyperplasia cases (10%) and no cases of endometrial hyperplasia without atypia were strongly positive for HE4 (0.0%), the figures are close to study reported by Li *et al.*, 2015 which revealed that the strong expression of HE4 was significantly higher in endometrioid carcinoma (55.98%) than that in endometrial hyperplasia (20%) and also significantly higher than that in endometrial hyperplasia without atypia (0.0%) [11]. Similarly, Deng *et al.*, 2015 also reported that strong HE4 immunohistochemical expression is significantly higher in endometrial carcinoma cases (45.2%) than that detected in endometrial hyperplasia cases (23.3%) [12]. Zhang *et al.*, 2016 stated that HE4 expression was obviously higher in patients with endometrial carcinoma than in benign uterine diseases [23].

In our study, there was statistically significant relationship between the grade and the level of HE4

expression as Grade 3 carcinoma cases showed the highest percentage of strongly positive cases (64%), followed by Grade 2 (33%) followed by Grade 1 (21%) ($p = 0.04$). In agreement to our results, Li *et al.*, 2015 reported that as the degree of endometrial cancer differentiation decreased, the HE4 level increased, and the HE4 positive expression rate in the poorly differentiated group (92.3%) was significantly higher than that in the highly differentiated group (72.7%), which demonstrated that HE4 expression in endometrial cancer is related to the degree of differentiation of the tumor [11]. Furthermore, Mutz-Dehbalaiie *et al.*, 2012, Bignotti *et al.*, 2011; Moore *et al.*, 2011 and Moore *et al.*, 2008 reported positive correlation between FIGO grading and high expression of HE4 [9], [24], [25], [26].

In this work, FIGO Stage III cases showed the highest percentage of strongly positive cases (71%), followed by stage II (36%) followed by stage I (27%) with statistically significant relation ($p = 0.03$). Similarly, Li *et al.*, 2015 stated that the positive expression of HE4 in advanced endometrial cancer was significantly higher than that at earlier stages [11]. This is consistent with the findings in the literature of Li *et al.*, 2013, Moore *et al.*, 2011 and Bignotti *et al.*, 2011, which suggested that the expression level of HE4 is associated with myometrial invasion depth; the larger the area and greater the depth of invasion, the more malignant cells are present and the higher the HE4 expression in corresponding tissues [25], [26], [27]. Furthermore, Deng *et al.*, 2015 reported that the high expression rate of HE4 in Stage III-IV endometrial carcinoma was 66.7% (16/24), which was significantly higher than stage I-II 36.7% (22/60) [10].

In our study, endometrial endometrioid carcinoma cases invading more than half myometrial thickness showed higher percentage of strongly positive cases (59%), than those with less than half myometrial thickness with statistically significant relation. Similarly, Li *et al.* (2015), Li *et al.* (2013), Moore *et al.* (2011), and Bignotti *et al.* (2011) reported that the rate of HE4 positive expression increased with increasing the depth of myometrial invasion [9], [25], [26], [27]. In this study, there was no statistically significant relation was detected in HE4 immunohistochemical expression among the endometrioid carcinoma cases with and without cervical involvement. This correlation was not evaluated by other comparative studies. As well, no statistically significant relation was detected in HE4 immunohistochemical expression among the endometrioid carcinoma cases with and without serosal/adnexal or parametrial involvement. This might be explained because of the small number of cases within the groups of cervical, adnexal and parametrial involvement. These correlations were not evaluated by other comparative studies.

Finally, it is worth mentioning that one of the most important findings is that the positivity rate of HE4 expression was significantly higher in endometrial

carcinoma than that in endometrial hyperplasia and also significantly higher than that in endometrial hyperplasia without atypia. This is consistent with many of the reported studies which provide a preliminary theoretical reference for basic research on the role of HE4 in the development of endometrial cancer.

Therefore, during interpretation of endometrial biopsies of atypical hyperplasia, HE4 strong expression might raise the possibility of the presence of coexisting adenocarcinoma not biopsied or even warning of a near future malignant transformation. Also, strong expression of HE4 by tissue biopsy of adenocarcinoma should be reported as this might predict higher grade and stage of the tumor, a point that should be considered by surgeons while performing hysterectomy. These results should be further confirmed by extending the study on a large scale, correlation of HE4 expression with the molecular classification of Tumor Cancer Genome Atlas and with patient's prognosis, particularly occurrence of recurrence and survival to establish the prognostic significance of HE4 expression in endometrial carcinoma and atypical hyperplasia.

References

- Brennan DJ, Hackethal A, Metcalf AM, Coward J, Ferguson K, Oehler MK, *et al.* Serum HE4 as a prognostic marker in endometrial cancer-a population based study. *Gynecol Oncol.* 2014;132(1):159-65. <https://doi.org/10.1016/j.ygyno.2013.10.036>
PMid:24211402
- Doll A, Abal M, Rigau M, Monge M, Gonzalez M, Demajo S, *et al.* Novel molecular profiles of endometrial cancer-new light through old windows. *Mol Biol.* 2008;108(3-5):221-9. <https://doi.org/10.1016/j.jsbmb.2007.09.020>
PMid:18061438
- Jiang LN, Zhang HJ, Zhang HJ. The study of HE4, CA125 and CA72-4 for differential diagnosis between ovarian endometriosis and ovarian cancer. *Chin J Lab Diagn.* 2014;18(3):394-6.
- Sandri MT, Bottari F, Franchi D, Boveri S, Candiani M, Ronzoni S, *et al.* Comparison of HE4, CA125 and ROMA algorithm in women with a pelvic mass: Correlation with pathological outcome. *Gynecol Oncol.* 2013;128(2):233-8. <https://doi.org/10.1016/j.ygyno.2012.11.026>
PMid:23200911
- Schummer M, Ng WV, Bumgarner RE, Nelson PS, Schummer B, Bednarski DW, *et al.* Comparative hybridization of an array of 21, 500 ovarian cDNAs for the discovery of genes overexpressed in ovarian carcinomas. *Gene.* 1999;238(2):375-85. [https://doi.org/10.1016/s0378-1119\(99\)00342-x](https://doi.org/10.1016/s0378-1119(99)00342-x)
PMid:1057096
- Yu S, Yang HJ, Xie SQ, Bao YX. Diagnostic value of HE4 for ovarian cancer: A meta-analysis. *Clin Chem Lab Med.* 2012;50(8):1439-46.
PMid:22868811
- Karlsen NS, Karlsen MA, Hogdall CK, Hogdall EV. HE4 tissue expression and serum HE4 levels in healthy individuals and patients with benign or malignant tumors: A systematic review. *Cancer Epidemiol Biomarkers Prev.* 2014;23(11):2285-95. <https://doi.org/10.1158/1055-9965.epi-14-0447>
PMid:25169975
- Galgano MT, Hampton GT, Frierson HF Jr. Comprehensive analysis of HE4 expression in normal and malignant human tissues. *Mod Pathol.* 2006;19(6):847-53. <https://doi.org/10.1038/modpathol.3800612>
PMid:16607372
- Moore RG, Brown AK, Miller MC, Badgwell D, Lu Z, Allard WJ, *et al.* Utility of a novel serum tumor biomarker HE4 in patients with endometrioid adenocarcinoma of the uterus. *Gynecol Oncol.* 2008;110(2):196-201. <https://doi.org/10.1016/j.ygyno.2008.04.002>
PMid:18495222
- Deng L, Gao Y, Li X, Cai M, Wang H, Zhang H, *et al.* Expression and clinical significance of annexin A2 and human epididymis protein 4 in endometrial cancer. *J Exp Clin Cancer Res.* 2015;34(1):96. <https://doi.org/10.1186/s13046-015-0208-8>
PMid:26362938
- Li J, Lin J, Luo Y, Kuang M, Liu Y. A multivariate analysis of prognostic biomarkers in surgically treated endometrial cancer. *PLoS One.* 2015;10(6):e0130640. <https://doi.org/10.1371/journal.pone.0130640>
PMid:26107255
- Yang CH, Xu YH, Zhang XY. Expression and significance of human epididymis gene product 4 in tissue and serum of patients with endometrial cancer. *Chin J Clin Oncol.* 2011;38(9):516-9.
- Lu R, Sun X, Xiao R, Zhou L, Gao X, Guo L. Human epididymis protein 4 (HE4) plays a key role in ovarian cancer cell adhesion and motility. *Biochem Biophys Res Commun.* 2012;419(2):274-80. <https://doi.org/10.1016/j.bbrc.2012.02.008>
PMid:22342977
- Trudel D, Tetu B, Gregoire J, Plante M, Renaud MC, Bachvarov D, *et al.* Human epididymis protein 4 (HE4) and ovarian cancer prognosis. *Gynecol Oncol.* 2012;127(3):511-5. <https://doi.org/10.1016/j.ygyno.2012.09.003>
PMid:22967799
- Zaino R, Carinelli SG, Ellenson LH. Epithelial tumors and precursors. In: Kurman RJ, editor. *WHO Classification of Tumours of the Female Reproductive Organs.* Lyon, France: IARC; 2014. p. 125-35.
- Zhou Q, Singh SR, Yunzhe L, Mo Z, Huang J. Preoperative histopathological grading and clinical staging versus surgical-pathological grading and surgical staging in endometrial carcinoma patients: A single centre retrospective study. *Glob J Med Res.* 2018;18:18-28.
- FIGO Committee on Gynecologic Oncology. FIGO staging for carcinoma of the vulva, cervix, and corpus uteri. *Int J Gynaecol Obstet.* 2014;125(2):97-8. <https://doi.org/10.1016/j.ijgo.2014.02.003>
PMid:24630859
- Powell MA, Olawaiye AB, Bermudez A. Corpus uteri-carcinoma and carcinosarcoma. In: Amin MB, Edge SB, Greene FL, editors. *AJCC Cancer Staging Manual.* 8th ed. New York: Springer; 2017. p. 639-57.
- Kommos F, Grevenkamp F, Bunz AK, Taran FA, Fend F, Lax S. L1CAM: Amending the low-risk category in endometrial carcinoma. *J Cancer Res Clin Oncol.* 2017;143(2):255-62. <https://doi.org/10.1007/s00432-016-2276-3>
PMid:27695947
- Kumarasamy C, Madhav MR, Sabarimurugan S, Lakhotiya K, Pandey V, Priyadharshini T, *et al.* Diagnostic and prognostic role of HE4 expression in multiple carcinomas: A protocol for systematic review and meta-analysis. *Medicine (Baltimore).* 2019;98(28):e15336. <https://doi.org/10.1097/md.00000000000015336>

-
- PMid:31305389
21. Khatuja R, Rai S. Endometrial carcinoma: Epidemiology and risk factors. In: Preventive Oncology for the Gynecologist. Singapore: Springer; 2019. p. 3-12. https://doi.org/10.1007/978-981-13-3438-2_1
22. Helal EA, Salman MI, Ezz-Elarab SS. Malignant tumors of the body of uterus. In: Pathology-Based Cancer Registry 2002-2010. 1st ed. Cairo, Egypt: Ain-Shams Faculty of Medicine; 2015. p. 54-56.
23. Zhang Z, Chen HX, Xu XX. The values of the combined detection of serum human epididymis protein E4, CA125 and CA199 in diagnosis of endometrial cancer. J Pract Med. 2016;32(7):1108-12.
24. Mutz-Dehbalaie I, Egle D, Fessler S, Hubalek M, Fiegl H, Marth C, et al. HE4 is an independent prognostic marker in endometrial cancer patients. Gynecol Oncol. 2012;126(2):186-91. <https://doi.org/10.1016/j.ygyno.2012.04.022>
- PMid:22525819
25. Bignotti E, Ragnoli M, Zanotti L, Calza S, Falchetti M, Lonardi S, et al. Diagnostic and prognostic impact of serum HE4 detection in endometrial carcinoma patients. Br J Cancer. 2011;104(9):1418-25. <https://doi.org/10.1038/bjc.2011.109>
- PMid:21468050
26. Moore RG, Miller MC, Disilvestro P, Landrum LM, Gajewski W, Ball JJ, et al. Evaluation of the diagnostic accuracy of the risk of ovarian malignancy algorithm in women with a pelvic mass. Obstet Gynecol. 2011;118(2):280-8. <https://doi.org/10.1097/aog.0b013e318224fce2>
27. Li J, Chen H, Mariani A, Chen D, Klatt E, Podratz K, et al. HE4 (WFDC2) promotes tumor growth in endometrial cancer cell lines. Int J Mol Sci. 2013;14(3):6026-43. <https://doi.org/10.3390/ijms14036026>
- PMid:23502467