



Trabeculectomy in Staphyloma Eye with High Intraocular Pressure Following Ocular Trauma – A Case Report

Masitha Dewi Sari*

Department of Ophthalmology, Faculty of Medicine, Universitas Sumatera Utara, Medan, Indonesia

Abstract

Edited by: Ksenija Bogojeva-Kostovska

Citation: Sari MD. Trabeculectomy in Staphyloma Eye with High Intraocular Pressure Following Ocular Trauma – A Case Report. Open Access Maced J Med Sci. 2021 May 20; 9(T3):23-25.
<https://doi.org/10.3889/oamjms.2021.6313>

Keywords: Trabeculectomy; Traumatic glaucoma; Staphyloma

*Correspondence: Sari MD. Department of Ophthalmology, Faculty of Medicine, Universitas Sumatera Utara, Medan, Indonesia. E-mail: masitha@usu.ac.id

Received: 27-Apr-2021

Revised: 08-May-2021

Accepted: 10-May-2021

Copyright: © 2021 Masitha Dewi Sari

Funding: This research did not receive any financial support

Competing Interest: The authors have declared that no competing interest exists

Open Access: This is an open-access article distributed under the terms of the Creative Commons Attribution-NonCommercial 4.0 International License (CC BY-NC 4.0)

BACKGROUND: Ocular trauma may alter the anterior segment condition that may lead to secondary glaucomas such as inflammation, hyphema, angle recession, and lens subluxation. One of the most common procedures to decrease intraocular pressure (IOP) is trabeculectomy by creating pathways that allow aqueous humor to flow out of the anterior chamber. Scleral tissue destruction can cause damage in thin areas (such as posterior to the rectus muscle insertions) as in case of scleritis.

CASE REPORT: An 11-year-old boy presented to the Ophthalmology Department of Universitas Sumatera Utara Hospital with a bigger white grayish mass and blurry vision. There was a history of the left ocular trauma 6 years ago, followed by redness of the eye, but not treated properly. On the general examination, the patient's left eyes looked cloudy. On ocular examination, the left eye visual acuity was 1/300 and IOP was 28 mmHg. Segment anterior examination showed staphyloma from 9 to 12 o'clock, conjunctival injection, corneal scar, shallow anterior chamber, and cloudy lens. We could not assess the posterior segment due to cloudy media. We gave anti-glaucoma medication for 1 month, but the IOP did not decrease. We performed a trabeculectomy to control IOP and to prevent staphyloma from getting bigger.

CONCLUSION: Trabeculectomy was an effective procedure to control IOP in a staphyloma eye following ocular trauma.

Introduction

Staphyloma refers to a localized bulging of the weak and thin outer tunic of the eyeball (cornea or sclera), lined by uveal tissue which shines through the thinned out fibrous coat, then adds its color to the thinned sclera, giving an appearance of bluish to almost black color. Scleral staphylomas are scleral ectasia that is lined internally by uveal tissue. Scleral tissue destruction can cause damage in thin areas (such as posterior to the rectus muscle insertions) as in case of scleritis. In children, staphyloma may occur as a result of long-standing increased intraocular pressure (IOP) or axial myopia, due to the relative distensibility of the sclera in the young [1], [2], [3]. Staphyloma can be classified based on anatomy as anterior staphyloma, intercalary staphyloma, equatorial staphyloma, posterior staphyloma, and peripapillary staphyloma [1], [2], [4], [5].

Ocular trauma may result in secondary glaucoma either by open angle or angle closure. Ocular trauma may alter the anterior segment condition that may lead to secondary glaucomas such as inflammation, hyphema, angle recession, and lens subluxation. If this condition is founded together, it may lead to elevated IOP initially after trauma and if this condition happens for a long time, it may result in glaucomatous optic nerve damage [5], [6]. Moreover, following ocular

trauma, angle-closure glaucoma without a pupillary block may develop from the formation of peripheral anterior synechiae associated with angle recession or from contusion, hyphema, and inflammation.

The aim of all glaucoma treatments is lowering IOP to preserve visual function or to improve quality of life. But not effective to everyone, some of them have to take surgical treatment. One of the most common procedures is trabeculectomy. Trabeculectomy also called filtering surgery is a procedure to decrease IOP by surgical corneoscleral with creating pathways that allow aqueous humor to flow out of the anterior chamber.

Case Report

An 11-year-old boy presented to the Ophthalmology Department of Universitas Sumatera Utara Hospital with a bigger white greyish mass, blurry vision in his left eye (Figure 1). There was a history of the left ocular trauma 6 years ago, followed by redness of the eye, but not treated properly. He got traditional medicine for his left eye instead of proper medication. Then, his eye got worse and cloudier. He was born of

a full-term normal vaginal delivery, birth weight, and vaccine history was unclear.

On the general examination, VAS score was 4/10, patient's left eyes looked cloudy. On ocular examination, the left eye visual acuity was 1/300 (hand movement) while the right eye was 6/6. And IOP was 28 mmHg. Segment anterior examination showed staphyloma from 9 to 12 o'clock, conjunctival injection, corneal scar, shallow anterior chamber, and cloudy lens. We could not assess the posterior segment due to cloudy media. The patient was started on antiglaucoma medication for 1 month (pilocarpine 2% eye drop 4 times daily, brinzolamide eye drop 3 times daily, and acetazolamide 125 mg peroral 3 times daily) accompanied by antibiotics and steroid (levofloxacin eye drop 4 times daily, and dexamethasone, neomycin sulfate, polymyxin sulfate eye drop 4 times daily, and amoxicillin oral suspension 250 mg peroral 3 times daily).

After 1 month treatment with antiglaucoma, the IOP did not decrease. We performed trabeculectomy with general anesthesia to control IOP and to prevent staphyloma getting bigger (Figure 2). Post-operative patient was given combination steroid and antibiotic eye drop and ointment (tobramycin dexamethasone eye drop 4 times daily; dexamethasone neomycin polymyxin eye ointment twice daily), anticholinergic (homatropine eye drop twice daily), oral antibiotic (cefadroxil 250 mg oral suspension twice daily), and NSAID oral (ibuprofen syrup 3 × 100 mg).

One day after trabeculectomy, patient still feels pain in the left eyes, the visual acuity was 1/300, IOP within normal limits. Segment anterior examination showed staphyloma in 9–12 o'clock, close suture at 2

o'clock, subconjunctival bleeding, conjunctival injection, corneal leukoma, corneal pannus, normal anterior chamber, and cloudy media (Figure 3).

Routine follow-up on day 12th showed minimal pain in the left eye, the visual acuity was 1/300, IOP was 14 mmHg. Segment anterior examination showed minimal subconjunctival bleeding, bleb formed, white-grayish mass from 9 to 12 o'clock, corneal leukoma, corneal pannus, normal anterior chamber, and cloudy media.

Discussion

The most common ocular injuries in the pediatric population are ocular foreign body, sharp object injury, and trauma. All of the ocular traumas need urgent ophthalmology assessment and treatment to prevent morbidity. Cornea erosion most often happened in the ocular trauma and required prompt medication to prevent infection [7], [8].

The prevalence of corneal leukoma and staphyloma in children was 0.03%. More than 2.5 million eye injuries occur each year, often sufferers permanently lose part or all of their vision. Almost 30% of them are younger than 18 years. In this case, previous ocular trauma may affect the cornea. He got traditional medicine in spite of proper medical treatment and resulted in an unresolved corneal infection and corneal scar. The formation of corneal opacity or scar is caused by activation and transformation of corneal stromal cells, cytokines, destruction, and remodeling of collagen structure [9], [10].

The most common organisms involved in scleritis are *Pseudomonas aeruginosa*, *Staphylococcus* species, *Streptococcus* species, *Stenotrophomonas maltophilia*, *Serratia marcescens*, *Mycobacterium* species, *Haemophilus influenza*, *Nocardia*, virus, and fungus [11]. In this case, untreated corneal infection might spread into

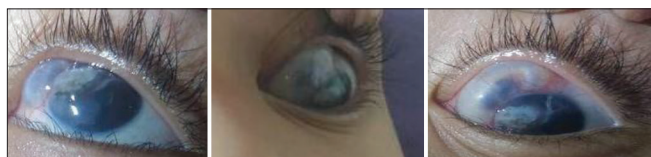

Figure 1: Pre-trabeculectomy

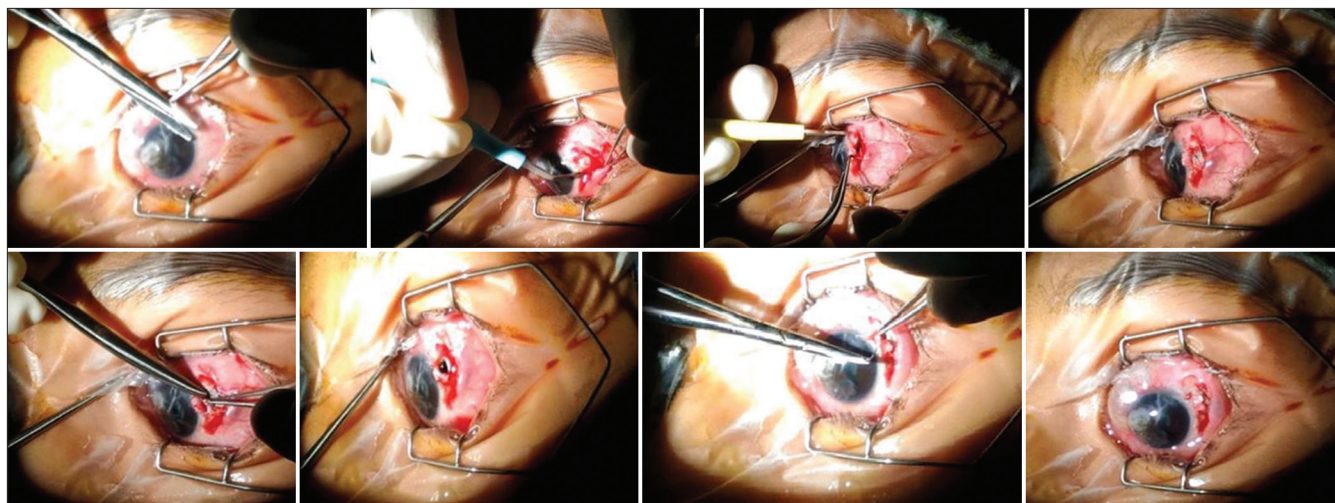


Figure 2: During trabeculectomy

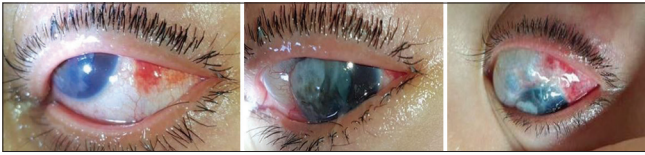


Figure 3: Post-trabeculectomy

adjacent sclera which might lead to necrotizing scleritis and anterior scleral staphyloma. Scleral staphylomas are scleral ectasia that is lined by uveal tissue. Scleral tissue destruction can cause damage in thin areas (such as posterior to the rectus muscle insertions) as in case of scleritis [1]. In this case, anterior scleral staphylomas occurred due to previous trauma and infection that is not treated properly. Then, the scleral wall became thin and weak.

About 4% of cases following ocular injury can elevate IOP. Post-traumatic glaucoma followed closed globe injuries has contributed as much 77% and 23% followed open globe injuries [12]. The aim of all glaucoma treatments is lowering IOP to preserve visual function or to improve quality of life. Medical management consists of prostaglandin analogue, β 2 adrenergic antagonist, α 2 adrenergic agonist, carbonic anhydrase inhibitor, parasympathomimetic agents, and hyperosmotic agents [6]. We treated this patient using pilocarpine eye drop (parasympathomimetic), brinzolamide eye drop (topical carbonic anhydrase inhibitor), and acetazolamide eye drop (oral carbonic anhydrase inhibitor) for 1½ months, but the IOP did not decrease to normal level.

Trabeculectomy also called filtering surgery is a procedure to decrease IOP by surgical corneoscleral with creating pathways that allow aqueous humor to flow out of the anterior chamber [6]. The indication of trabeculectomy in this case is uncontrolled IOP despite having maximal antiglaucoma medication.

The efficacy of trabeculectomy was as high as 65% [13], [14]. We performed trabeculectomy as usual except that we made a conjunctival incision at 12–3 o'clock. Usually, we made a conjunctival incision at 10–2 o'clock but we could not do it because of staphyloma [6]. Trabeculectomy modification such as using antifibrotic agent can improve trabeculectomy efficacy in decreasing IOP [6]. However, in this case, we did not use antifibrotic agent because the sclera was already thin and may impair the sclera. We were successful in lowering the IOP from 28 mmHg to 14 mmHg in this case. The bleb was seen on the 3rd day after the trabeculectomy, and the boy did not complain about the headache anymore.

Conclusion

Trabeculectomy is one of indications in case of uncontrolled IOP despite having maximal antiglaucoma therapy. In this patient, trabeculectomy is not only to control IOP but also to prevent staphyloma enlarging.

Hence, trabeculectomy was effective in controlling IOP in staphyloma eye following ocular trauma.

References

- Rosa RH. Ophthalmic Pathology and Intraocular Tumor. 4th ed. San Francisco: American Academy of Ophthalmology; 2019-2020. p. 145-6.
- Khurana AK, Khurana BP. Comprehensive Ophthalmology: Disease of Sclera. 7th ed. New Delhi: Jaypee Brothers Medical Publisher; 2018. p. 149-50.
- Eva-Riordan P, Ausburger JJ. Vaughan and Asbury's General Ophthalmology. Uveal Tract and Sclera. 19th ed. Glashütte, Germany: Lange; 2018. p. 383-4.
- Wiesenthal RW. External Diseases and Cornea. 8th ed. San Francisco: American Academy of Ophthalmology; 2019-2020. p. 372-4.
- Salmon JF. Clinical ophthalmology a systematic approach. In: Kanski's: Degenerative Myopia, Dome Shaped Macula, Congenital Optic Disc Anomaly, Trabeculectomy. 9th ed. Amsterdam, Netherlands: Elsevier; 2020. p. 412-9, 604, 612, 778-80.
- American Academy of Ophthalmology. Glaucoma. 10th ed. San Francisco: American Academy of Ophthalmology; 2019-2020. p. 131-7, 175.
- Pi LH, Chen L, Liu Q, Ke N, Fang J, Zhang S, *et al*. Prevalence of eye diseases and causes of visual impairment in school-aged children in Western China. J Epidemiol. 2012;22(1):37-44. <https://doi.org/10.2188/jea.je20110063> PMID:22123227
- Cohen N, Cohen E, Anafy A, Margalio A, Kaganov K, Gomel N, *et al*. Predictors of traumatic eye injuries at high-risk for ophthalmic complications in children. Eur J Pediatr. 2021;180(1):177-85. <https://doi.org/10.1007/s00431-020-03734-0> PMID:32642855
- Sitompul R, Kusumowidagdo G, Matur EB, Barliana JD, Sitorus RS, Sungkar S. Post-ocular trauma corneal staphyloma in a child living in an underdeveloped region of Eastern Indonesia. Case Rep Ophthalmol. 2018;9(1):24-9. <https://doi.org/10.1159/000485553> PMID:29681830
- Zhou Y, Chen Y, Wang S, Qin F, Wang L. MSCs helped reduce scarring in the cornea after fungal infection when combined with anti-fungal treatment. BMC Ophthalmol. 2019;19(1):226. <https://doi.org/10.1186/s12886-019-1235-6> PMID:31727008
- Reddy JC, Murthy SI, Reddy AK, Garg P. Risk factors and clinical outcomes of bacterial and fungal scleritis at a tertiary eye care hospital. Middle East Afr J Ophthalmol. 2015;22(2):203-11. <https://doi.org/10.4103/0974-9233.150634> PMID:25949079
- De Leon-Ortega JE, Girkin CA. Ocular trauma-related glaucoma. Ophthalmol Clin North Am. 2002;15(2):215-23. PMID:12229238
- Ranjan A, Rao A. Ahmed glaucoma valve surgery for necrotizing scleritis with secondary glaucoma. Int Ophthalmol. 2014;34(2):327-9. <https://doi.org/10.1007/s10792-013-9782-y> PMID:23636673
- Wagner FM, Schuster AK, Emmerich J, Chronopoulos P, Hoffmann EM. Efficacy and safety of XEN®-Implantation vs. trabeculectomy: Data of a "real-world" setting. PLoS One. 2020;15(4):e0231614. <https://doi.org/10.1371/journal.pone.0231614> PMID:32310972