



## Case Report: Acute Transverse Myelitis

Petrus Nilwan Ginting\*, Kiking Ritarwan<sup>1b</sup>

Department of Neurology, Faculty of Medicine, University of Sumatera Utara, Haji Adam Malik General Hospital, Medan, Indonesia

### Abstract

**Edited by:** Branislav Filipović  
**Citation:** Ginting PN, Ritarwan K. Case Report: Acute Transverse Myelitis. Open Access Maced J Med Sci. 2021 May 17; 9(T3):182-185.  
<https://doi.org/10.3889/oamjms.2021.6327>  
**Keywords:** Acute transverse myelitis; Acute myelopathy; Multiple sclerosis  
**\*Correspondence:** Petrus Nilwan Ginting, Department of Neurology, Faculty of Medicine, University of Sumatera Utara, Haji Adam Malik General Hospital, Medan, Indonesia. E-mail: [petrusginting42@gmail.com](mailto:petrusginting42@gmail.com)  
**Received:** 28-Apr-2021  
**Revised:** 04-May-2021  
**Accepted:** 07-May-2021  
**Copyright:** © 2021 Petrus Nilwan Ginting, Kiking Ritarwan  
**Funding:** This research did not receive any financial support  
**Competing Interests:** The authors have declared that no competing interests exist  
**Open Access:** This is an open-access article distributed under the terms of the Creative Commons Attribution-NonCommercial 4.0 International License (CC BY-NC 4.0)

**BACKGROUND:** Acute transverse myelitis (ATM) could be a pathogenetically heterogeneous inflammatory disorder affecting the spinal cord at one or more segments [1].

**CASE PRESENTATION:** We report a 69-year-old man presented with complaints of weakness of the arms and legs since 3 weeks before hospital admission. On physical and neurological examination was found Tetraparesis, lower motor neuron in the superior limb and upper motor neuron in the inferior limb, sensory disturbances at C6-C7 levels, and autonomic impairment retention of urine and bladder dysfunction. On magnetic resonance imaging examination of the whole spine vertebra, a diffuse process was found in the spinal cord along with the cervical 7 to Th12-L1. Differential diagnosis is with transverse myelitis, multiple sclerosis, and no picture of syringomyelia. The patient was treated with steroids. Acute transverse myelitis is an inflammatory disorder of the spinal cord with various causes.

**CONCLUSION:** Clinical examination and investigations are very important to establish the diagnosis and determine the right management so that the expected outcome is obtained.

### Introduction

Acute transverse myelitis (ATM) could be a pathogenetically heterogeneous inflammatory disorder affecting the spinal cord at one or more segments [1]. A range of disorders can cause ATM and includes infections, para- and post-infections, and vascular, neoplastic, paraneoplastic, collagen vascular, and iatrogenic irregularities [2]. ATM could be a rare syndrome with an incidence of between 1 and 8 new cases/million population each year. The characteristics of transverse myelitis are characterized by inflammation within the spinal cord and have clinical manifestations within the sort of neural dysfunction of motor, sensory, and autonomic pathways as a result of the pathway crossing the rostral border of inflammation. Often found complaints of sensory dysfunction and evidence of acute inflammation as evidenced by magnetic resonance imaging (MRI) and lumbar puncture [3].

Estimates of the annual incidence of idiopathic or post-infectious transverse myelitis range from 1.3 to 8 cases/million. Although the disorder can develop at any age, there is a bimodal peak within the incidence at 10–19 years old and 30–39 years. The incidence increases to 24.6 cases/million annually if acquired demyelinating causes, especially disseminated multiple sclerosis (MS), are included in the study. There's not any clear pattern among the cases of idiopathic transverse

myelitis concerning sex, geographic distribution, or familial susceptibility [4].

When the utmost level of neurologic deficit approaches 50%, patients have lost all limb movement, bladder dysfunction, and 80–94% of patients complain of numbness, paresthesia, and dysesthesia. Autonomic symptoms encompass increased urinary disorders and defecation, difficulty or inability to empty it or constipation of the digestive tract, and sexual disturbances [5]. ATM has many possible etiologies, but the bulk of cases are categorized as idiopathic despite a radical evaluation. Rapid recognition, even before a final diagnosis is reached. It is vital to initiate early therapeutic interventions to cut back the harmful effects of inflammation [4].

### Case Report

A man, 69 years old, married, works as a private employee, the address is Medan Marelan, Medan city, North Sumatra. Medical record number 00.81.35.09, entered RSUP H. Adam Malik Medan on July 9, 2020. Main Complaint: Weak all four limbs.

This was experienced since 3 weeks before admission to the hospital occurs suddenly during light activity. The patient feels the leg is not moving normally,

and the patient's arm is unable to grip firmly along with the weakness of all four limbs. Complaints were also accompanied by numbness in both legs and arms. The patient also had difficulty passing stools and difficulty urinating since 3 weeks ago along with weakness of all four limbs. A History of fever was denied. History of trauma was denied. History of the upper respiratory tract infection and history of indigestion was denied, a history of experiencing similar complaints was denied. Family history of having similar complaints was denied.

On neurological examination found tetraparesis type lower motor neuron (LMN) superior limb and upper motor neuron (UMN) type inferior limb with muscle strength in the right superior limb 44444 and left superior limb 44444, right inferior extremity 11111 and left inferior limb 11111, hypesthesia as high as the spinal cord C6-C7, and urine retention. On the physiological examination of the triceps biceps reflex, hyporeflexia was found, APR and KPR were found to be hyperreflexia and there was a Babinski pathological reflex.

On MRI examination, was found hyperintense lesions in the spinal cord with an irregular shape partly anterior – lateral and posterior (Figure 1). Lesions were seen ranging from C7 to Th12-L1. The most widespread are seen at the Th2-3 to Th4-5 levels. The process looks diffuse and shows minimal enhancement after intravenous (IV) contrast administration. Diffuse process in the spinal cord along with the cervical 7 to Th12-L1.

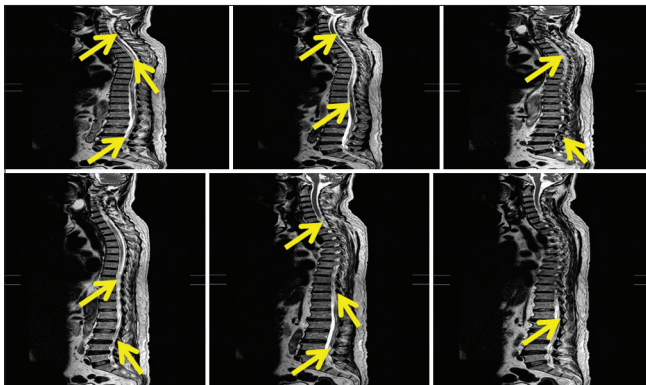


Figure 1: Magnetic resonance imaging whole spine with intravenous contrast patient acute transverse myelitis

The patient was diagnosed with Tetraparesis type LMN superior limb and UMN type inferior limb + Hypesthesia at the level of the spinal cord Cervical 6–7 and below + Urine retention and bladder dysfunction. Differential diagnosis is with a Guillain-bare syndrome (GBS), MS, intramedullary tumor. Management in this patient injection of methylprednisolone 125 mg/6 h loading dose/3 days. Prognostic of this patient, poor outcomes.

## Discussion

A man (S), 69 years old, married, work as a private employee, the address is Medan marelau,

Medan city, North Sumatra. RM 00.81.35.09, entered RSUP H. Adam Malik Medan on July 9, 2020, with complaints of weakness of the four members of the movement. The incidence of ATM is between 1.34 and 4.6 million/year with a bimodal peak between the ages of 10–19 and 30–39 years. There is no gender or family or an ethnic tendency for ATMs. There is no evidence of geographic variation in the incidence of ATM [6].

In this patient, complaints occur suddenly during light activity. The patient feels the leg is not moving normally, and the patient's arm is unable to grip firmly along with the weakness of all four limbs. Complaints were also accompanied by numbness in both legs and arms. The patient also had difficulty passing stools and difficulty urinating since 3 weeks ago along with weakness of all four limbs. The history of fever is refuted. The history of trauma is refuted. History of the upper respiratory tract infection and history of indigestion was denied, a history of experiencing similar complaints was denied. Family history of having similar complaints is refuted. ATM occurs acutely (occurs within a few hours to several days) or subacute (occurs within a week or two). Common symptoms that appear involve motor, sensory, and autonomic symptoms. Some sufferers also report experiencing muscle spasms, anxiety, headaches, fever, and loss of appetite. Of the several symptoms, there are four classic symptoms of ATM, namely muscle weakness or paralysis of both arms or legs, pain, loss of feeling in the feet and toes, bladder dysfunction, and defecation [7].

On neurological examination found tetraparesis type LMN superior limb and UMN type inferior limb with muscle strength in the right superior limb 44444 and left superior limb 44444, right inferior extremity 11111 and left inferior limb 11111, hypesthesia as high as the spinal cord C6-C7, urine retention, and bladder dysfunction. On the physiological examination of the triceps biceps reflex, hyporeflexia was found, APR and KPR were found to be hyperreflexia and there was a Babinski pathological reflex. After the acute onset of spinal cord injury, there is a sudden disturbance of reflex and muscle tone below the level of the lesion, which is called spinal shock sudden onset of muscle irritability and loss of reflexes with spinal paralysis. Loss of muscle tone and decreased reflexes may result from disruption of the fusiform,  $\gamma$ -efferent system, which regulates the sensitivity of muscle stretch receptors. The gamma-motor neurons regulating muscle spindle can potentially be released to sustain the stimulation of the muscle spindle. Gamma-motor neurons can lose descending tonic facilitation distal to the level of the spinal cord injury, resulting in decreased muscle spindle excitability and decreased segmental input to the motor neuron by an afferent reflex stretch. The impaired fusiform function is caused by loss of normal spinal cord activity, which is dependent on continuous tonic release from higher up from the center, including tonal discharge transmitted through the vestibulospinal and reticulospinal tracts [8].

MRI examination revealed hyperintense lesions within the medulla spinalis of irregular shape partly anterior – lateral and posterior. Lesions were seen starting from C7 to Th12-L1. The foremost widespread are seen at the Th2-3 to Th4-5 levels. The method appears diffuse and shows minimal enhancement after IV contrast administration. Diffuse process within the medulla spinalis together with the cervical 7 to Th12-L1. The typical MRI feature of transverse myelitis is a hyperintense central T2 medulla spinalis lesion extending over quite 2 segments, involving quite two-thirds of the cross-sectional area of the cord. Although each level cord is also affected, the classic description includes a preference for cords. Half of the cord segments involved are extensive and increase in 37–74% of cases. The pattern of lesion enhancement varies diffuse, heterogeneous, and peripheral enhancement. When diagnostic criteria have not been met because of an absence of elevation and normal cerebrospinal fluid (CSF) parameters, follow-up imaging could also be helpful, as improvement is reported more frequently within the subacute stage than within the early stages [9].

Based on the results of the history, neurological examination, and investigations, the patient was diagnosed with ATM. An idiopathic diagnosis of ATM must require that everyone inclusion criteria and none of the exclusion criteria be met. The diagnosis of ATM-related disease must require that everyone inclusion criteria are met and also the patient is identified as having the underlying condition listed within the specific disease excluded. Since the clinical ATM syndrome could also be because of inflammatory causes (i.e., vascular causes), ATM could be a subset of acute myelopathy. The diagnosis of ATM requires evidence of inflammation within the medulla spinalis, since spinal cord biopsy is not a practical option within the routine evaluation of ATM patients, MRI analysis and spinal cord CSF are the only highly available tools to see the presence of inflammation within the lesions involved [10].

This patient was diagnosed with GBS because GBS can appear just such as ATM, decreased reflex, weakness, bowel and bladder disorders, and autonomic disorders. Differentiating factors, GBS include less prominent sensory components and also the presence of cranial neuropathy; (excluding the optic nerve), MRI also can help differentiate these two conditions and show stagnation of the nervus spinalis roots in GBS and also the absence of intramedullary disease. Although ATM and GBS may have elevated CSF protein, GBS does not exhibit the pleocytosis often seen with ATM. In cases where it is not clear, nerve conduction tests are often wont to show the neuropathy. Rarely do ATM and GBS concurrently in patients [11].

This patient was differentially diagnosed with MS because although ATM can be a marker for MS incidence, MS usually presents with partial myelitis, meaning that sensory or motor symptoms

will appear and digestive and bladder function is not compromised in myelitis. MS patients are more likely to have asymmetric clinical findings with a particular predisposition to dorsal column disorders. The clinical patterns of spinal cord disorders commonly occurring in MS include Brown-Sequard syndrome and the sensory useless hand of Oppenheim [12].

This patient was diagnosed with an intramedullary tumor because intramedullary tumors, like glioma, could appear just like ATMs. Astrocytoma, the foremost common neoplasm of the cord in children, shows a mass infiltration of mass with a fusiform extension of the cord, usually extending but four vertebral segments. Symptoms resembling ATM are slower within the tumor. The syrinx above and below the lesion often result from obstruction of the central canal by the tumor. Occasionally, hyperintense protein CSF (Froin syndrome) can appear under the mass, sometimes related to bleeding. Pilocytic astrocytoma may have a cyst adjacent to the tumor ependymoma heart-bordered with an extension of the cord. These tumors could also be cystic or associated with the syrinx and bleeding frequently occurs. Sometimes, it is difficult to tell apart ATM from intramedullary mass on diffuse cord swelling with increased T2 signal, gadolinium streaking, and increased protein. Markers of inflammation such as CSF pleocytosis can differentiate the two [13], [14].

This patient received corticosteroid therapy. After the administration of corticosteroids on the 4<sup>th</sup> day, there were changes in the patient. There a motor improvement and loss of sensory complaints in the superior extremities. Standard first-line therapy of idiopathic ATM is IV high-dose corticosteroid prescribed 30 mg/kg/day (maximum 1 g/day) of methylprednisolone for 3–7 days. Patients treated with corticosteroids had better long-term and short-term outcomes and lower postmortem times. IV methylprednisolone should be followed by oral steroids starting at 1 mg/kg/day and reduced for 3–4 weeks [15].

The prognosis during this patient is a poor outcome. In general, the prognosis in adult cases of ATM suggests that one-third of patients had a good outcome, one-third had a fair outcome, and one-third had a poor outcome. The outcome was favorable that the patient had complete recovery or minimal sequela. The fair outcome implies that the patient is functional and outpatient but may have some urinary and digestive symptoms and/or sensory changes. The Poor outcome implies that patients are primarily not outpatient, have poor or absent sphincter control, and have severe sensory deficits. In general, patients with good motor recovery also appear to own better urinary control recovery. The explanation for this is often unclear but can be associated with acute complete transverse myelitis and longitudinally extensive transverse myelitis which are more common in younger age groups. Many previous studies reported slight improvement after 6 months, but several studies reported that longer time



to follow-up was related to better functional outcomes, suggesting that recovery can continue even over several years. Factors related to a worse prognosis are rapid onset of symptoms, severe motor weakness, need for a ventilator. ATM associated with acute disseminated encephalomyelitis or MS included a better prognosis for recovery than idiopathic ATM and neuromyelitis Optica-related ATM. The length of the lesion in the context of idiopathic ATM could be a major determinant of the prognosis of recurrence, as reflected within the classification terminology [11].

## Conclusion

Definition of ATM is a neurological disorder caused by inflammation along the spinal cord involving either one level or segment of the spinal cord. The term myelitis denotes inflammation of the spinal cord, transverse indicates the position of the inflammation along the spinal cord. History, neurological examination, and supporting examinations (MRI, CSF analysis, and serology) help make the diagnosis. Various factors determine the prognosis of ATM.

## References

1. Kwon SB, Hwang SH, Jung S, Kang SY. Clinica, laboratory, MRI, and electrophysiologic findings in acute transverse myelitis: Comparison between patients with and without multiple sclerosis. *Neurology Asia*. 2008;13:211-3.
2. Krishnan C, Kaplin AI, Deshpande DM, Pardo CA, Kerr DA. Transverse myelitis: Pathogenesis, diagnosis and treatment. *Front Biosci*. 2004;9:1483-99. PMID:14977560
3. Pandit L. Transverse myelitis spectrum disorders. *Neurol India*. 2009;57(2):126-33. <https://doi.org/10.4103/0028-3886.51278> PMID:19439840
4. Frohman EM, Wingerchuck DM. Transverse myelitis: Clinical practice. *N Engl J Med*. 2010;363(6):564-72. PMID:20818891
5. Kerr D. The History of Transverse Myelitis: The Origin of the Name and the Identification of Disease. *The Transverse Myelitis Association*; 2006. Available from: <http://www.myelitis.org/history.htm>. [Last accessed on 2021 April 12].
6. Bhat A, Naguwa S, Cheema G, Greshwin ME. The epidemiology of transverse myelitis. *Autoimmun Rev*. 2010;9(5):A395-9. <https://doi.org/10.1016/j.autrev.2009.12.007> PMID:20035902
7. Transverse Myelitis Fact Sheet. National Institute of Neurological Disorders and Stroke; 2006. Available from: <http://www.ninds.nih.gov>. [Last accessed on 2021 April 12].
8. Ko HY. Revisit spinal shock: Pattern of reflex evolution during spinal shock. *Korean J Neurotrauma*. 2018;14(2):47-54. <https://doi.org/10.13004/kjnt.2018.14.2.47> PMID:30402418
9. Goh C, Desmond PM, Phal PM. MRI in transverse myelitis. *J Magn Reson Imaging* 2014;40(6):1267-79. <https://doi.org/10.1002/jmri.24563>
10. Transverse Myelitis Consortium Working Group. Proposed diagnostic criteria and nosology of acute transverse myelitis. *Neurology*. 2002;59(4):499-505. <https://doi.org/10.1212/wnl.59.4.499> PMID:12236201
11. Wolf VL, Lupo PJ, Lotze TE. Pediatric acute transverse, myelitis overview and differential diagnosis. *J Child Neurol*. 2012;27(11):1426-36. <https://doi.org/10.1177/0883073812452916> PMID:22914370
12. West WW, Hess C, Cree BA. Acute transverse myelitis: Demyelinating inflammatory, and infectious myelopathies. *Semin Neurol*. 2012;32(2):92-113. <https://doi.org/10.1055/s-0032-1322586> PMID:22961185
13. Sheerin F, Collison K, Quaghebeur G. Magnetic resonance imaging of acute intramedullary myelopathy: Radiological differential diagnosis for the on-call radiologist. *Clin Radiol*. 2009;64(1):84-94. <https://doi.org/10.1016/j.crad.2008.07.004> PMID:19070702
14. Bakheet MF, Ahmed E. The differential diagnosis of acute inflammatory transverse myelitis. *J Teach Hosp Inst*. 2019;9:8-21.
15. Tavasoli A, Tabirizi A. Acute transverse myelitis in children. *Iran J Child Neurol*. 2018;12(2):7-16. PMID:29696041