



Penetrating Scrotal Injuries: A War Time Experience in a Civilian Setup

Ammar Fadil Abid^{1*}, Naimet Naoum²

¹Department of Uro-surgery, Medical College, Al-Mustansiriyah University, Al-Yarmouk Teaching Hospital, Baghdad, Iraq;

²Consultant Urologist, Medical College, Al-Mustansiriyah University, Al-Yarmouk Teaching Hospital, Baghdad, Iraq

Abstract

Edited by: Ksenija Bogoeva-Kostovska
Citation: Abid AF, Naoum N. Penetrating Scrotal Injuries: A War Time Experience in a Civilian Setup. Open Access Maced J Med Sci. 2021 Oct 14; 9(B):1198-1202. https://doi.org/10.3889/oamjms.2021.6888
Keywords: Testicle; External genitalia; Blast injury; Gunshot
***Correspondence:** Ammar Fadil Abid, Department of Uro-surgery, Medical College AL-Mustansiriyah University, Baghdad, Iraq. E-mail: amarfadil@yahoo.com
Received: 22-Jul-2021
Revised: 30-Sep-2021
Accepted: 04-Oct-2021
Copyright: © 2021 Ammar Fadil Abid, Naimet Naoum
Funding: This research did not receive any financial support
Competing Interests: The authors have declared that no competing interests exist
Open Access: This is an open-access article distributed under the terms of the Creative Commons Attribution-NonCommercial 4.0 International License (CC BY-NC 4.0)

AIM: To present our experience in managing testicular involvement in penetrating scrotal injuries, trying to highlight a possible role for conservative management of selected cases.

METHODS: We reviewed retrospectively all-penetrating scrotal injuries presented to Alyarmook teaching hospital for the period between January 2009 and November 2015, including only those injured victims who reached the hospital alive. Patients' charts reviewed regarding their demographic data including age, status being civilian or military, and married or single. We documented as well the cause of injury (bullets vs. explosive devices), laterality, associated injured organs, and type of management performed whether operative or non-operative conservative approach. Postoperative complications were recorded while in-patient and after a follow-up period of at least 1 month.

RESULTS: Thirty-one penetrating scrotal injuries were identified, resulted in 34 injured testicles. The patients' mean age was 34.35 years (± 12.89 standard deviation [SD]) (18–70 years). Most of the victims 24 (77.4%) were civilians. Explosive devices were the cause of injury in 23 patients (74.2%), while bullets were the cause in the remaining 8 patients (25.8%). Orchiectomy needed to be done in 17 (50%) testicles, while 11 (32.4%) injured testes were repaired by suturing. Six cases (17.6%) were treated conservatively without any surgical intervention. The overall testicular salvage rate was (50%). Twenty-one patients (68%) had associated injuries, mostly fractures. Complications occurred in 10 (32.2%) patients, including two mortalities.

CONCLUSIONS: Management of genitourinary injuries continues to be a challenging task. In our penetrating testicular injured series, we succeeded to salvage 50% of the injured testes. Non-surgical treatment is feasible in selected patients, an approach that needs further study and longer follow-up.

Introduction

Although injuries to the external genitalia are typically not in and of themselves life-threatening, yet they are commonly associated with other potentially life-threatening injuries. Severe injuries to the genital and/or urinary structures can result in sexual dysfunction, urinary symptoms, infertility, and mental health problems [1], [2].

The genitourinary (GU) tract is involved in approximately 10% of all traumas, and up to 40–60% of all penetrating GU injuries involve the external genitalia. In civilian life trauma, the incidence of scrotal or testicular injury remains low <1% [3], [4].

During the late 20th century, body armor modifications as well as a shift in weapon use from predominantly high-velocity rounds to explosive munitions, likely resulted in shift from internal GU injuries (renal and bladder) to genital injuries becoming more predominant [2], [5].

Most of the GU injury reports of the Iraqi conflict have been limited to records of the battlefield injuries amongst coalition troops [6], [7], [8], [9].

On the other hand, civil violence has been escalating throughout the country since the beginning of the war in March 2003, and Iraqi civilian victims were daily exposed to violent acts everywhere across the country. The reports on GU injuries from the Iraqi sources were very limited [10], [11], [12], [13].

We aimed in this study to present our experience with penetrating scrotal injuries involving the testes, trying to highlight a possible role for a non-operative management of selected cases.

Patients and Methods

We reviewed retrospectively all-penetrating scrotal injuries presented to Alyarmook teaching hospital for the period between January 2009 and November 2015, including only those injured victims who reached the hospital alive.

Patients were initially triaged and evaluated in the emergency department (ED), and urologists were

usually involved in managing the GU injuries. Unstable patients especially those with multi-organ injuries needed urgent operative treatment after preliminary resuscitation in the ED, while stable patients were admitted to complete their management in the hospital.

Patients' charts reviewed regarding their demographic data including age, status being civilian or military, and married or single. We documented as well the cause of injury (bullets vs. explosive devices), laterality, associated injured organs, and type of management performed whether operative or non-operative conservative approach. Operative management included either orchidectomy whether unilateral or bilateral, or suturing and repair to salvage the injured testis (es).

Conservative management was tried for scrotal injuries that were treated with no surgical intervention. Patients treated conservatively were selected after being clinically examined by the urologist, and evaluated by ultrasonic scrotal doppler. If the patient was stable, and the ultrasound did not show a significant Tunica Albugenia break nor a big hematoma was identified, then this patient would be admitted, and a serial clinical and ultrasonic examinations would be followed to make sure of the resolution of his injury, and absence of further complications.

Surgical care of polytrauma patients involving the genitalia, or those with confined scrotal and testicular injuries, was done according to the damage control surgical resuscitation protocols and the AUA Uro-trauma guidelines. Operations were done as an emergency or urgent procedure depending on the patient's triage status [14], [15].

Post-operative complications were recorded while in-patient and after a follow-up period of at least 1 month. Patients who had sustained bilateral testicular loss began testosterone replacement therapy as soon as possible after being discharged.

Categorical data were expressed as percentages, and continuous data as means and SD. Chi square and Fisher exact tests were used for statistical comparison of categorical groups, while one - way Anova and independent t-tests used for statistical comparison of continuous data. Level of significance was set at ($p < 0.05$).

Results

Thirty-one penetrating scrotal injuries were identified, including 34 injured testicles, 3 (9.6%) patients had bilateral testicular injuries. Fourteen (45.2%) injured testes were distributed equally on both right and left sides.

The patients' mean age was 34.35 years (± 12.89 SD) ranging (18–70 years). Majority of the

patients (61.3%) were younger than 30 years old. Most of the victims 24 (77.4%) were civilians, and 20 of them (64.5%) were unmarried.

Explosive devices were the cause of injury in 23 patients (74.2%) Figure 1, while bullets were the cause in the remaining 8 patients (25.8%) Figure 2.

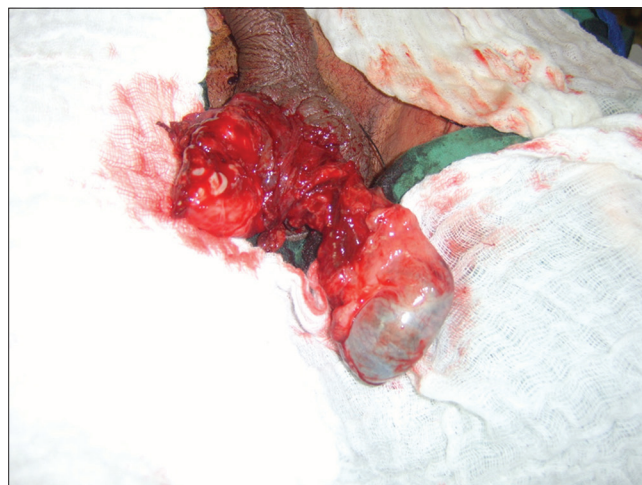

Figure 1: Blast injury of external genitalia after cleaning

Orchidectomy needed to be done in 17 (50%) testicles, while 11(32.4%) testes were explored and repaired by suturing. Bilateral orchidectomy was done in the three patients who had sustained bilateral injuries.

Six cases (17.6%) were treated conservatively without any surgical intervention, 4 (66.7%) of them were caused by bullet injuries. The overall testicular salvage rate was (50%).

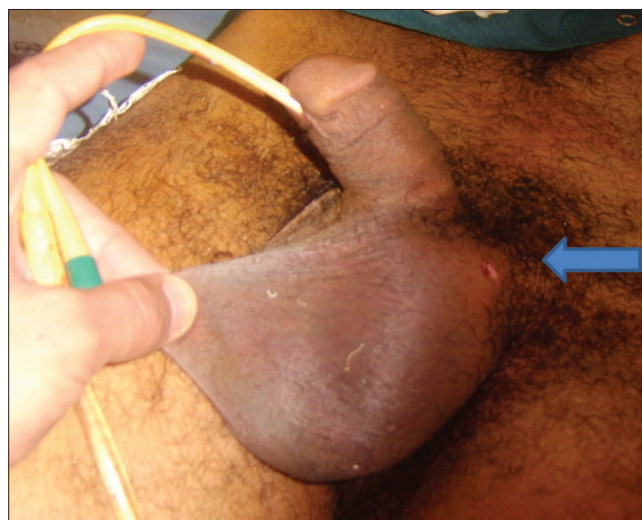

Figure 2: Bullet injury of external genitalia was managed conservatively

Twenty-one patients (68%) had associated injuries, mostly fractures in 15 patients (48.4%), followed by bowel injuries in 7 (22.6%), and associated GU injuries (Penile, urethral, and bladder) in 6 (19.3%) patients (Figure 3).

Complications occurred in 10 (32.2%) patients, with 2 mortalities, bleeding requiring blood transfusion

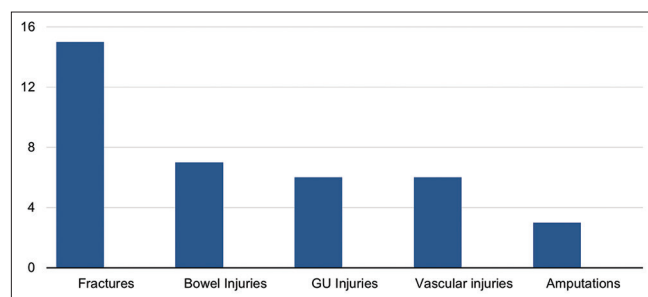


Figure 3: Concomitant injuries in 31 penetrating external genitalia injury

in five patients, and infection-causing sepsis with longer hospitalization in three patients. The 2 death incidents occurred on the surgical table due to severe multi-organ injuries.

We didn't find a statistical relationship between the age of the patients and the cause of their injuries, nor the type of management performed ($p = 0.551$ and $p = 0.255$). The age was not found as well statistically related to the presence of associated injuries ($p = 0.272$).

Trending towards more orchidectomies in blast injuries without statistical significance was found ($p = 0.069$). We could not find a significant relationship between the cause of the injury and laterality or the presence of associated injuries ($p = 0.723$, $p = 0.074$).

No statistical relation was found between the presence of associated injuries and type of management performed ($p = 0.316$).

Discussion

During U.S. troop involvement in Iraq and Afghanistan, a number of factors determined by the weapon energy level and the individual's protective equipment, converged and ultimately resulted in the frequency of genital injuries increasing to a level never before reported in the history of war. The majority of injuries sustained during these conflicts were caused by ground-based explosive mechanisms and frequently resulted in a unique injury pattern to dismounted troop known as dismounted complex blast injury, which involves multiple extremity amputations, pelvic fractures, and extensive genital/perineal wounds. Explosions now represent the most common mechanism of injury (78%) and death (63%) on the modern battlefield [16].

During the 3-year study at Balad, air force theatre hospital 2005–2008, (71.5%) of the operative procedures involved the external genitalia. Eighty percent of the scrotal trauma in UK forces in Iraq and Afghanistan 2003–2009, were caused by improvised explosive devices [9], [17].

In our study, most of the testicular injuries (74.2%), occurred as a result of explosive devices.

This coincides with other literatures which studied the military and civilian injuries during the Iraq invasion period [1], [2], [6], [9], [11], [16], [17].

Phonsombat *et al.*, reviewed retrospectively the records of 110 civilian patients with penetrating injuries to the external genitalia in San Francisco between 1977 and 2006 and found that half of the patients injured by gunshot wounds (GSW), which constituted only 25.8% of our cases [3].

Likely due to the demographic norms of military service, the majority (81.4–95.6%) of the penetrating GU injury victims, were young adults <30 years old. This is higher than the (61.3%) incidence in our study, as the majority were civilians [2].

Bilateral testicular injuries in (9.6%) of our patients, show less incidence than reported by others (14.8–26.5%) [1], [9].

Our salvage rate of the injured testes was 50%. This rate varies in different studies depending on the combat theatre setup, which will ultimately reflect the type of weapons used and the severity of the injuries.

In a civilian setup, testes injured by GSW were salvaged in 50–75% of cases, and in 86% of a single study cases, where the injuries occurred mainly by explosives [3], [11], [18].

Military testicular salvage rates varies from 10% to 52% in reports from the Vietnam era, when injuries are typically the result of high-velocity projectiles or landmine shrapnel. With improvements in military medical services, salvage rates increased in the US and UK military operations in Iraq and Afghanistan to reach (51.1–74.4%) in different literatures [1], [17].

The TOUGH project for epidemiology of GU Injuries among Male U.S. service members in Iraq and Afghanistan, reported 67.6% salvage rate, while Williams *et al.*, reported 59.3% testicular salvage rate among the UK troops injured by explosives in Iraq and Afghanistan [2], [9].

Significant atrophy may nevertheless occur Later on in repaired testes that may adversely affect future fertility. Future non-obstructive azoospermia and atrophy were noticed in blast pelvic injuries even without obvious testicular involvement. These findings may question the realistic concept of salvage rates [2], [16].

We managed to treat six injured testes conservatively depending on clinical and imaging judgment. Serial clinical and Doppler ultrasonic examinations were done to make sure that the initially limited testicular injury is stable and resolving.

The American and the European urology guidelines indicate that penetrating injuries to the scrotum require surgical exploration with debridement of

non-viable tissue, though the European guidelines also mentioned conservative management in hematoceles smaller than three times the size of the contralateral testes [14], [19].

Some literatures documented severe testicular injuries with only minimal scrotal wall lacerations, and GU surgeons did observe that the visible appearance of the scrotum was not a reliable predictor of the presence or absence of testicular injury. Therefore, scrotal exploration became a routine practice for many, to stage penetrating scrotal trauma [1], [17].

Nevertheless, other literatures did recommend non-surgical treatment in a selected group of penetrating penile and scrotal injuries, with the use of doppler ultrasonography to determine the extent of the vascular damage [3], [20].

We think that the conservatively treated patients in our study will definitely need a longer follow-up period, and the method itself needs more studies to be standardized.

Disfigured genital injuries in these young men, especially those unmarried, will, unfortunately, impact their future sexual and reproductive life. They need to be managed in a collaborative multi-disciplinary approach, with the involvement of a clinical psychologist well versed in sexual medicine to help for the long-term psychological rehabilitation. In this aspect, we may suggest as well, especially for those with bilateral testicular injuries, that sperm retrieval and cryopreservation for future *in vitro* fertilization, be part of their management plans. These techniques have been already in practice, and in their way to become the standard of care in treating such injuries [2], [15], [21].

This study has its inherited limitations being retrospective, together with the small sample size, and the short follow-up period. Trauma literatures traditionally have poor follow-up, limiting thus the outcome analysis. Most of the trauma studies pointed to these limitations [3].

Conclusions

Genital injuries are rarely life-threatening, but they often become the male patient's chief concern once the acute injury phase resolves. Management of GU injuries continues to be a challenging task. In our study, we managed to salvage 50% of the injured testes. Non-surgical treatment is feasible in selected patients, a method that needs further study and longer follow-up.

References

1. Waxman S, Beekley A, Morey A, Soderdahl D. Penetrating trauma to the external genitalia in operation Iraqi freedom. *Int J Impot Res.* 2009;21(2):145-8. <https://doi.org/10.1038/ijir.2008.59>
PMid:19020522
2. Janak JC, Orman JA, Soderdahl DW, Hudak SJ. Epidemiology of genitourinary injuries among male U.S. Service members deployed to Iraq and Afghanistan: Early findings from the trauma outcomes and urogenital health (TOUGH) project. *J Urol.* 2017;197(2):414-9.
PMid:27506692
3. Phonsombat S, Master VA, McAninch JW. Penetrating external genital trauma: A 30-year single institution experience. *J Urol.* 2008;180(1):192. <https://doi.org/10.1016/j.juro.2008.03.041>
PMid:18499189
4. Grigorian A, Livingston JK, Schubl SD, Hasjim BJ, Mayers D, Kuncir E, et al. National analysis of testicular and scrotal trauma in the USA. *Res Rep Urol.* 2018;10:51-6. <https://doi.org/10.2147/rru.s172848>
PMid:30128306
5. Hudak SJ, Morey AF, Rozanski TA, Fox CW Jr. Battlefield urogenital injuries: Changing patterns during the past century. *Urology.* 2005;65(6):1041-6. <https://doi.org/10.1016/j.urology.2004.11.031>
PMid:15913731
6. Edmond L. Paquette: Genitourinary trauma at a combat support hospital during operation Iraqi freedom: The impact of body armor. *J Urol.* 2007;177(6):2196-9. <https://doi.org/10.1016/j.juro.2007.01.132>
PMid:17509316
7. Owens BD, Kragh JF Jr., Wenke JC, Macaitis J, Wade CE, Holcomb JB. Combat wounds in operation Iraqi Freedom and operation Enduring Freedom. *J Trauma.* 2008;64(2):295-9. <https://doi.org/10.1097/ta.0b013e318163b875>
PMid:18301189
8. Serkin FB, Soderdahl DW, Hernandez J, Patterson M, Blackbourne L, Wade CE. Combat urologic trauma in US military overseas contingency operations. *J Trauma.* 2010;69(1):175-8.
PMid:20622614
9. Williams RJ, Fries CA, Midwinter M, Lambert AW. Battlefield scrotal trauma: How Should it be managed in a deployed military hospital? *Injury.* 2013;44(9):1246-9.
PMid:23587211
10. Petros FG, Santucci RA, Al-Saigh NK. The incidence, management, and outcome of penetrating bladder injuries in civilians resultant from armed conflict in Baghdad 2005-2006. *Adv Urol.* 2009;2009:275634. <https://doi.org/10.1155/2009/275634>
PMid:19360111
11. Al-Azzawi IS, Koraitim MM. Lower genitourinary trauma in modern warfare: The experience from civil violence in Iraq. *Injury.* 2014;45(5):885-9. <https://doi.org/10.1016/j.injury.2014.01.005>
PMid:24485550
12. Alsaigh NK, Alharoob IS. Renal injuries in penetrating abdominal trauma: Iraqi experience of Alyarmouk teaching hospital. *J Urol.* 2007;177(4):55. [https://doi.org/10.1016/s0022-5347\(18\)30427-0](https://doi.org/10.1016/s0022-5347(18)30427-0)
13. Ammar AF, Hussein HL. Ureteral injuries from gunshots and shells of explosive devices. *Urol Ann.* 2010;2(1):17-20. <https://doi.org/10.4103/0974-7796.62920>
PMid:20842252
14. Morey AF, Brandes S, Dugi DD, Armstrong JH, Breyer BN,

- Broghammer JA, *et al.* Urotauma: AUA guideline. *J Urol.* 2014;192(2):327-35. <https://doi.org/10.1016/j.juro.2014.05.004> PMID:24857651
15. Balzano FL, Balzano Steven J. Military genitourinary injuries: Past, present, and future. *Transl Androl Urol.* 2018;7(4):646-52. <https://doi.org/10.21037/tau.2018.04.05> PMID:30211054
16. Cannon JW, Hofmann LJ, Glasgow SC, *et al.* Dismounted complex blast injuries: A comprehensive review of the modern combat experience. *J Am Coll Surg.* 2016;223(4):652-64.e8. PMID:27481095
17. Hudac SJ, Hakim S. Operative management of wartime genitourinary injuries at Balad Air Force theater hospital, 2005 to 2008. *J Urol.* 2009;182(1):180-3. <https://doi.org/10.1016/j.juro.2009.02.150> PMID:19450817
18. Brandes SB, Buckman RF, Chelsky MJ, Hanno PM. External genitalia gunshot wounds: A ten-year experience with fifty-six cases. *J Trauma.* 1995;39(2):266. <https://doi.org/10.1097/00005373-199508000-00013> PMID:7674395
19. Kitrey ND, Djakovic N, Hallscheidt P, *et al.* EAU guidelines on urological trauma. In: *European Association of Urology Pocket Guidelines.* Arnhem, Netherlands: European Association of Urology EAU; 2020. p. 374-9.
20. Fackler ML. Civilian gunshot wounds and ballistics: Dispelling the myths. *Emerg Med Clin North Am.* 1998;16(1):17-28. [https://doi.org/10.1016/s0733-8627\(05\)70346-1](https://doi.org/10.1016/s0733-8627(05)70346-1) PMID:9496312
21. Sharma DM, Bowley DM. Immediate surgical management of combat-related injury to the external genitalia. *J R Army Med Corps.* 2013;159(1):118. <https://doi.org/10.1136/jramc-2013-000023> PMID:23631321