



# The Avocado (*Persea americana* Mill.) Leaf Extract on Streptozotocin-induced Pancreatic Cell Regeneration of White Rats (*Rattus norvegicus*)

Nurdin Rahman<sup>1\*</sup>, I. Made Tangkas<sup>1</sup>, Sri Mulyani Sabang<sup>2</sup>, Bohari Bohari<sup>3</sup> , Rukman Abdullah<sup>4</sup> 

<sup>1</sup>Department of Nutrition, Faculty of Public Health, Universitas Tadulako, City of Palu, Indonesia; <sup>2</sup>Department of Chemistry Education, Faculty of Teacher Training and Education, Universitas Tadulako, City of Palu, Indonesia; <sup>3</sup>Department of Nutrition, Universitas Sultan Ageng Tirtayasa, City of Serang, Indonesia; <sup>4</sup>Department of Medical Education, Universitas Sultan Ageng Tirtayasa, City of Serang, Indonesia

## Abstract

**Edited by:** Sinisa Stojanoski  
**Citation:** Rahman N, Tangkas IM, Sabang SM, Bohari B, Abdullah R. The Avocado (*Persea americana* Mill.) Leaf Extract on Streptozotocin-induced Pancreatic Cell Regeneration of White Rats (*Rattus norvegicus*). Open Access Maced J Med Sci. 2021 Oct 10; 9(A):849-853. https://doi.org/10.3889/oamjms.2021.7065  
**Keywords:** Avocado leaf extract; Histology; Pancreas; Diabetes mellitus  
**\*Correspondence:** Nurdin Rahman, The Avocado (*Persea americana* Mill.) Leaf Extract on Streptozotocin-induced Pancreatic Cell Regeneration of White Rats (*Rattus norvegicus*). E-mail: nurdinrahman.untad@gmail.com  
**Received:** 14-Aug-2021  
**Revised:** 05-Sep-2021  
**Accepted:** 30-Sep-2021  
**Copyright:** © 2021 Nurdin Rahman, I. Made Tangkas, Sri Mulyani Sabang, Bohari Bohari, Rukman Abdullah  
**Funding:** The authors are thankful to the Directorate General of Development and Research Enhancement of the Ministry of Research, Technology and Higher Education.  
**Competing Interests:** The authors declare that they have no competing interests.  
**Open Access:** This is an open-access article distributed under the terms of the Creative Commons Attribution-NonCommercial 4.0 International License (CC BY-NC 4.0)

**AIM:** The rate of pancreatic cell regeneration after avocado leaf extract intervention in a diabetic animal model induced by streptozotocin (STZ) was investigated in this study.

**METHODS:** Experimental study was conducted on 18 male white rats as subjects, which were divided into six groups, three animals of each. Preparing diabetic animal models: First, the animals had been fasting a whole night; they were induced with STZ and 10% sucrose. The primary data included the histopathology of the pancreas of white male rats in the form of histopathological scoring: Score 0: Normal, Score 1: 1–25% pancreatic damage, Score 2: 25–50% pancreatic damage, Score 3: 50–75% pancreatic damage, and Score 4: 70–100% pancreatic damage.

**RESULTS:** A dosage of 100 mg/kg b.w. of the ethanolic avocado leaf extract impacted pancreatic cells regeneration in white male rats, with a score of 1.67. However, improvement in pancreatic cell regeneration appears to increase align with the dose, score 1.00 in dosage of 150 mg/kg b.w. and score 0.33 in dosage of 200 mg/kg. The score of 0.33 was also seen in G5 (obtained glibenclamide) and G6 (normal healthy animal). However, the most damage was in G4 who obtained only 0.5% Na-CMC.

**CONCLUSION:** The dose of 200 mg/kg b.w. of the avocado leaf extract contributed the most significant recovery of pancreatic cell of diabetic animal induced with STZ, equivalent to glibenclamide.

## Introduction

Diabetes mellitus (DM) is a metabolic syndrome of failure in carbohydrate, fat, and protein metabolism caused by insulin deficiency or decreased tissue sensitivity to insulin [1]. This metabolic disease is characterized by hyperglycemia and disorders of carbohydrate, fat, and protein metabolism caused by abnormal insulin secretion and action results in blood glucose levels exceeding normal. DM is classified into two, type 1 diabetes that is dependent on insulin, and type 2 diabetes that is not dependent on insulin [2].

According to the International Diabetes Federation, DM prevalence globally is 1.9% and become the seventh cause of death. In 2012, the incidence of DM in the world was 371 million people, where the proportion of the incidence of type 2 DM 95% of the world's population suffers from DM. The Indonesian Basic Health Research (In Indonesian:

Riset Kesehatan Dasar) in 2008 showed that the prevalence of DM in Indonesia had grown to 57% [3]. The high prevalence of type 2 DM is caused by several unchangeable risk factors, such as gender, age, genetic factors, body, waist circumference, and age [4], [5], [6]. This silent killer disease affects all organs and cause several complaints, including kidney disease, cataracts, impaired vision, heart disease, sexual impotence, gangrene, stroke, and others [7].

The state of diabetes or hyperglycemia will worsen and exacerbate ROS formation through several mechanisms in oxidative stress due to free radicals [8]. Oxidative stress and oxidative damage to tissues usually end up with chronic diseases including atherosclerosis, diabetes, and rheumatoid arthritis. It may increase glycosidation and lipoxidation in plasma and protein tissue due to the elevation of oxidative stress in DM [9], [10]. Diabetic ingredients such as alloxan can cause oxidative stress on cells and diabetic patients often experience oxidative stress. Complications of

diabetes are related to oxidative stress, especially the formation of superoxide free radicals [11]. Sources of oxidative stress in diabetes include shifting the balance of redox reactions due to changes in carbohydrate and lipid metabolism which will increase the formation of ROS from glycation reactions and lipid oxidation, thereby reducing antioxidant defense systems including GSH [12]. Reducing oxidative stress is the most appropriate step by suppressing free radicals along with optimizing antioxidant intake [13]. Research shows that the use of dolichandrone atrovirens leaf and bark extract has blood glucose lowering potential action in diabetic conditions [2].

Antioxidants agents are needed in protecting and preventing cells against oxidative stress [14]. Medicinal plants are considered a source of various oxidative stress-related diseases [15], consisting of phenolic compounds, mainly in phenolic acids, flavonoids, and tannins. These compounds have a wide range of antioxidant activities [16]. Avocado leaves showed a potent in chelating free radicals related to antioxidant activities.

This study aims to analyze the effects of avocado leaf extracts on the pancreatic cell regeneration of people with diabetes.

## Methods

### Material

It was an *in vivo* experimental study through 18 white male rats (*Rattus norvegicus*) as subjects, conducted in the Pharmacology Laboratory of Pelita Mas Palu (STIFA) and Balai Besar Veteriner Maros. This study used avocado (*Persea americana Mill.*) leaves as the main materials.

### Extraction

The collected avocado leaves were cleaned and sorted. The avocado leaves were then dried and crushed. The extract was prepared by maceration of crushed dried avocado leaves in 70% ethanol for 7 days. The extract obtained was concentrated by a rotary vacuum evaporator at 45°C and dried.

### Intervention

There were six groups of animal experiments which consisted of three white rats in each group. The five rat's group rats had been diabetic animal models using (STZ), while one group was left as healthy normal rats. Preparing diabetic animal models: First, the animals had been fasting a whole night; they were induced with STZ and 10% sucrose. After considering

diabetes, they were ready to be diabetic animal models. Each intervention of those groups was as follows:

1. G1: Feed + STZ + 10% Sucrose + 100 mg/kg b.w of extract + 0.5% NaCMC
2. G2: Feed + STZ + 10% Sucrose + 150 mg/kg b.w of extract + 0.5% NaCMC
3. G3: Feed + STZ + 10% Sucrose + 200 mg/kg b.w of extract + 0.5% NaCMC
4. G4: Feed + STZ + 10% sucrose + 0.5% Na-CMC
5. G5: Feed + STZ + 10% sucrose + Glibenclamid + 0.5% Na-CMC
6. G6: Normal healthy animal + regular feed.

The surgical process was performed on the abdominothoracal part, followed by necropsy of the pancreas. The pancreas was then rinsed with 0.9% of physiological liquid of NaCl to separate it from the blood or fats attached to the organ.

### Data analysis

The primary data included the histopathology of the pancreas of white male rats in the form of histopathological scoring: Score 0: Normal, Score 1: 1–25% pancreatic damage, Score 2: 25–50% pancreatic damage, Score 3: 50–75% pancreatic damage, and Score 4: 70–100% pancreatic damage.

### Ethical agreement

The study approved by Health Research Ethics Committee of the Faculty of Medicine, Hasanuddin University Hospital, and Pulmonary General Hospital Dr. Wahidin Sudirohusodo, Makassar, with an ethical agreement Number: 546/H4.8.4.31/PP36-KOMETIK/2018.

## Results

The results showed that the pancreatic sell damage in animal experimental was G1 = 1.67 (moderate cell damage); G2 = 1.00 (mild cell damage); G3 = 0.33 (no damage); G4 = 3.00 (severe cell damage); G5 = 0.33 (no damage); and G6 = 0.33 (no damage) (Table 1 and Figure 1).

A dosage of 100 mg/kg b.w. of the ethanolic extract of avocado impacted pancreatic cells

**Table 1: Scoring pancreas histology damage**

Treatment groups	The score of pancreatic cell damage*			
	Animal 1	Animal 2	Animal 3	Average
G1	2	2	1	1.67
G2	1	1	1	1.00
G3	0	0	1	0.33
G4	4	2	3	3.00
G5	0	0	1	0.33
G6	0	1	0	0.33

\*=0: No damage, 1: Mild pancreatic cell damage (1/3 cell part), 2: Moderate pancreatic cell damage (2/3 cell parts), 3: Severe pancreatic cell damage (>2/3 cell parts).

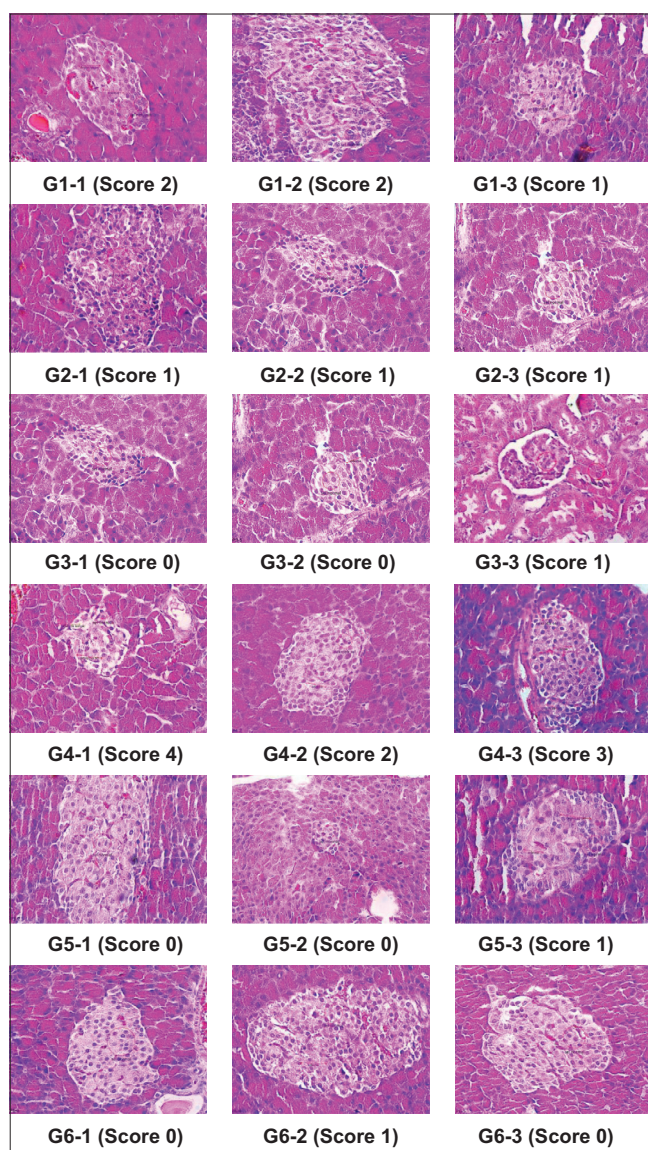


Figure 1: The level of damage of pancreatic cells

regeneration in white male rats, with a score of 1.67. However, improvement in pancreatic cell regeneration appears to increase align with the dose, score 1.00 in dosage of 150 mg/kg b.w. and score 0.33 in dosage of 200 mg/kg. The score of 0.33 was also seen in G5 (obtained glibenclamide) and G6 (normal healthy animal). However, the most damage was in G4 who obtained only 0.5% Na-CMC.

## Discussion

The results of pancreatic histology proven that multilevel dosages of avocado leaf extract effectively regenerate the kidney tissue of white male rats whose pancreas has been damaged by STZ induction, resulting in diabetes. It was seen that the higher dosage contributed more quickly to the regeneration of pancreatic cells in the STZ-induced DM animal model.

This recovery was seen to be most significant at a dose of 200 mg/kg b.w. (score 0.33) compared to the other two lower doses and had an effect equivalent to glibenclamide (0.33). However, cell regeneration was shown at doses of 100 mg/kg b.w. and 150 mg/kg b.w. (scores 1.67 and 1.00, respectively) compared to diabetic animal models receiving only NaCMC (3.00), the results did not match the effectiveness of glibenclamide.

Based on the observation of histopathological slides of the pancreas, there were cell degeneration and inflammation in pancreatic cells. The degeneration was occurred in the cytoplasm but did not harm the nucleus so that it may be recovered. The prolonged cell degeneration causes the cell inability to lead to improper metabolism, an initial reaction to acute cell damage caused by ischemia or toxin. The cell can regenerate and return its proper function when the toxic is neutralized or removed in a degenerative state. Cell degeneration is caused by the accumulation of toxic substances and other metabolites [17], [18].

The normal group (G6) of Langerhans islets did not show significant damage, and the shape was normal. Cell damage was seen in the negative control group (G4), which was indicated by the islets of Langerhans cells that looked empty, the small size of the Langerhans islets. The damage was caused by STZ induction, resulting in cell degeneration and pancreatic cell damage [19], [20].

Islets of Langerhans dominated by  $\alpha$  cell compared to  $\beta$  cell are caused by chronic hyperglycemic conditions that result in a decrease in insulin-producing cells and an increase in the activity of glucagon-producing cells [21]. The increase in insulin secretion previously described stated that the administration of glibenclamide in the positive control group could increase insulin secretion. This correlates with histopathological results that show the large Langerhans islets that can induce insulin secretion, although cell regeneration has not occurred in its entirety, and islet conditions are dominated by cells. The use of glibenclamide can inhibit oxidative stress and cell damage in the pancreas [22].

Administration of glibenclamide in experimental animals with diabetes can also prevent a decrease in insulin secretion and maintain or increase the number of glucagon-producing cells. In addition, the effectiveness of using glibenclamide is higher in stabilizing blood glucose levels than insulin therapy and can normalize cell damage that occurs in pancreatic islets [21].

The G3 group did not show any significant abnormalities and almost resembled the normal group. It indicated that the administration of water extract of Surian leaf at a dose of 200 mg/kg b.w. is more effective in inducing cell regeneration and inhibiting oxidative stress and pancreatic cell damage. Phytochemical compounds contained in avocado leaf extract have a role as a protective agent for pancreatic cells. The phytochemical screening test

shows these compounds in avocado leaf extract [23]. Flavonoid is a phytochemical compound that effectively repairs and protects cell structures and is an anti-inflammatory [24], [25]. Dembinska-Kiec *et al.* stated that flavonoid compounds' antioxidant activity in various plants could act as protective agents by reducing lipid peroxidation activity, increasing insulin secretion, and increasing glutathione and beta-carotene levels in the plasma of diabetic rats [26], [27]. The results of the study are in line with the previous studies which showed that the treatment of G3 with a dose of 200 mg/kg body weight avocado leaf extract gives a relatively effective influence on regenerating STZ induced renal cell rats, compared to other doses [28].

Other research shows that among the two phytoisolates of *Swertia alata*, the compound SA-4 has high anti-inflammatory potential and offers less ulcerogenic and less gastric irritant effect [29]. The results of this study imply that avocado leaf extract can be used and developed as a source of antioxidants that play a role in the regeneration of pancreas cells that degenerate due to high blood glucose levels.

## Conclusion

The dose of 200 mg/kg body weight of the ethanolic avocado leaf extract contributed the most significant recovery of the pancreatic cell of diabetic white rats induced with STZ, which was equivalent to glibenclamide.

## References

- Chawla A, Chawla R, Jaggi S. Microvascular and macrovascular complications in diabetes mellitus: Distinct or continuum? *Indian J Endocrinol Metab.* 2016;20(4):546-51. <https://doi.org/10.4103/2230-8210.183480>  
PMid:27366724
- Kayarahanam S, Subramaniyan V, Janakiraman AK, Kumar SJ. Antioxidant, antidiabetic, and antihyperlipidemic activities of *dolichandrone atrovirens* in albino wistar rats. *Res J Pharm Technol.* 2019;12(7):3511-6. <https://doi.org/10.5958/0974-360x.2019.00597.3>
- Kementerian Kemenkes RI. Main Results of Riskesdas 2018. Indonesia: Kementerian Kesehatan RI; 2018.
- Harding AH, Day NE, Khaw KT, Bingham S, Luben R, Welsh A. Dietary fat and the risk of clinical type 2 diabetes: The European prospective investigation of Cancer-Norfolk study. *Am J Epidemiol.* 2004;159(1):73-82. <https://doi.org/10.1093/aje/kwh004>  
PMid:14693662
- Hastuti RT. Faktor-faktor Risiko Ulkus Diabetika Pada Penderita Diabetes Melitus Studi Kasus di RSUD Dr. Moewardi Surakarta. Semarang: Universitas Diponegoro; 2008. <https://doi.org/10.32382/jmk.v11i1.1072>
- Teixeira-Lemos E, Nunes S, Teixeira F, Reis F. Regular physical exercise training assists in preventing type 2 diabetes development: Focus on its antioxidant and anti-inflammatory properties. *Cardiovasc Diabetol.* 2011;10:12. <https://doi.org/10.1186/1475-2840-10-12>  
PMid:21276212
- Venkateshan S, Subramaniyan V, Chinnasamy V, Chandiran S. Anti-oxidant and anti-hyperlipidemic activity of *Hemidesmus indicus* in rats fed with high-fat diet. *Avicenna J Phytomed.* 2016;6(5):516-25.  
PMid:27761421
- Matough FA, Budin SB, Hamid ZA, Alwahaibi N, Mohamed J. The role of oxidative stress and antioxidants in diabetic complications. *Sultan Qaboos Univ Med J.* 2012;12(1):5-18. <https://doi.org/10.12816/0003082>  
PMid:22375253
- Phaniendra A, Jestadi DB, Periyasamy L. Free radicals: Properties, sources, targets, and their implication in various diseases. *Indian J Clin Biochem.* 2015;30(1):11-26. <https://doi.org/10.1007/s12291-014-0446-0>  
PMid:25646037
- Fuloria S, Subramaniyan V, Karupiah S, Kumari U, Sathasivam K, Meenakshi DU. Comprehensive review of methodology to detect reactive oxygen species (ROS) in *Mammalian* species and establish its relationship with antioxidants and cancer. *Antioxid Basel Switz.* 2021;10(1):128. <https://doi.org/10.3390/antiox10010128>
- Pham-Huy LA, He H, Pham-Huy C. Free radicals, antioxidants in disease and health. *Int J Biomed Sci.* 2008;4(2):89-96.  
PMid:23675073
- Asmat U, Abad K, Ismail K. Diabetes mellitus and oxidative stress-a concise review. *Saudi Pharm J.* 2016;24(5):547-53. <https://doi.org/10.1016/j.jsps.2015.03.013>  
PMid:27752226
- Fuloria S, Subramaniyan V, Karupiah S, Kumari U, Sathasivam K, Meenakshi DU. A comprehensive review on source, types, effects, nanotechnology, detection, and therapeutic management of reactive carbonyl species associated with various chronic diseases. *Antioxidants.* 2020;9(11):1075. <https://doi.org/10.3390/antiox9111075>  
PMid:33147856
- Shahreza FD. Oxidative stress, free radicals, kidney disease, and plant antioxidants. *Immunopathol Persa.* 2016;3(2):1-6. <https://doi.org/10.15171/ipp.2017.03>
- Rafeian-Kopaei M, Baradaran A, Rafeian M. Plants antioxidants: From laboratory to clinic. *J Nephropathol.* 2013;2(2):152-3. <https://doi.org/10.5812/nephropathol.12116>  
PMid:24475444
- Martins S, Mussatto SI, Martínez-Avila G, Montañez-Saenz J, Aguilar CN, Teixeira JA. Bioactive phenolic compounds: Production and extraction by solid-state fermentation. A review. *Biotechnol Adv.* 2011;29(3):365-73. <https://doi.org/10.1016/j.biotechadv.2011.01.008>
- Llorens J. Toxic neurofilamentous axonopathies-accumulation of neurofilaments and axonal degeneration. *J Intern Med.* 2013;273(5):478-89. <https://doi.org/10.1111/joim.12030>  
PMid:23331301
- Subramaniyan V, Kayarahanam S, Kumar A, Kumarasamy V. Impact of herbal drugs and its clinical application. *Int J Res Pharm Sci.* 2019;10(2):1340-5. <https://doi.org/10.26452/ijrps.v10i2.537>
- Akbarzadeh A, Norouzian D, Mehrabi MR, Jamshidi Sh, Farhangi A, Verdi AA. Induction of diabetes by Streptozotocin in rats. *Indian J Clin Biochem.* 2007;22(2):60-4. <https://doi.org/10.32382/jmk.v11i1.1072>

- org/10.1007/bf02913315  
PMid:23105684
20. Ikebukuro K, Adachi Y, Yamada Y, Fujimoto S, Seino Y, Oyaizu H. Treatment of streptozotocin-induced diabetes mellitus by transplantation of islet cells plus bone marrow cells via portal vein in rats. Transplantation. 2002;73(4):512-8. <https://doi.org/10.1097/00007890-200202270-00004>  
PMid:11889421
21. Brereton MF, Iberl M, Shimomura K, Zhang Q, Adriaenssens AE, Proks P. Reversible changes in pancreatic islet structure and function produced by elevated blood glucose. Nat Commun. 2014;5:4639. <https://doi.org/10.1038/ncomms5639>  
PMid:25145789
22. Erejuwa OO, Sulaiman SA, Wahab MS, Salam SK, Salleh MS, Gurtu S. Antioxidant protective effect of glibenclamide and metformin in combination with honey in pancreas of streptozotocin-induced diabetic rats. Int J Mol Sci. 2010;11(5):2056-66. <https://doi.org/10.3390/ijms11052056>  
PMid:20559501
23. Rahman N, Utami Dewi N, Bohari B. Phytochemical and antioxidant activity of avocado leaf extract (*Persea americana* mill.). Asian J Sci Res. 2018;11(3):357-63. <https://doi.org/10.3923/ajsr.2018.357.363>
24. Panche AN, Diwan AD, Chandra SR. Flavonoids: An overview. J Nutr Sci. 2016;5:e47.  
PMid:28620474
25. Kumar S, Pandey AK. Chemistry and biological activities of flavonoids: An overview. ScientificWorldJournal. 2013;2013:162750.  
PMid:24470791
26. Dembinska-Kiec A, Mykkänen O, Kiec-Wilk B, Mykkänen H. Antioxidant phytochemicals against Type 2 diabetes. Br J Nutr. 2008;99(1):ES109-17. <https://doi.org/10.1017/s000711450896579x>  
PMid:18503731
27. Subramaniyan V, Shaik S, Bag A, Manavalan G, Chandiran S. Potential action of *Rumex vesicarius* (L.) against potassium dichromate and gentamicin induced nephrotoxicity in experimental rats. Pak J Pharm Sci. 2018;31(2):509-16.  
PMid:29618442
28. Rahman N, Sabang SM, Dewi NU, Bohari B, Fitriyah SI. The dosage of the avocado leaf extract (*Persea americana* Mill.) on regeneration of diabetic white rats (*Rattus norvegicus*) renal cell. Int J Nutr Pharmacol Neurol Dis. 2020;10(3):149.
29. Bajaj S, Fuloria S, Subramaniyan V, Meenakshi DU, Wakode S, Kaur A. Chemical characterization and anti-inflammatory activity of phytoconstituents from *Swertia alata*. Plants. 2021;10(6):1109. <https://doi.org/10.3390/plants10061109>  
PMid:34072717