



# The Effectiveness of *Sechium edule* Jacq. Swartz Extract Changes in the Histopathology of Aspirin-Induced Rat Gastritis Model

Hendrika Andriana Silitonga<sup>1,2</sup>, Gontar A. Siregar<sup>3\*</sup>, Rosita Juwita Sembiring<sup>4</sup>, Marline Nainggolan<sup>5</sup>

<sup>1</sup>Doctoral Program, Faculty of Medicine, Universitas Sumatera Utara, Kota Medan, Indonesia; <sup>2</sup>Department of Histology, Faculty of Medicine, Universitas Methodist Indonesia, Kota Medan, Indonesia; <sup>3</sup>Department of Internal Medicine, Faculty of Medicine, Universitas Sumatera Utara, Kota Medan, Indonesia; <sup>4</sup>Department of Clinical Pathology, Faculty of Medicine, Universitas Sumatera Utara, Kota Medan, Indonesia; <sup>5</sup>Department of Pharmaceutical Biology, Faculty of Pharmacy, Universitas Sumatera Utara, Kota Medan, Indonesia

## Abstract

**BACKGROUND:** Gastritis is one of the most common diseases found in internal medicine clinics and daily life.

**AIM:** The purpose of this study was to determine the histopathological changes of gastric rat model of aspirin-induced gastritis.

**MATERIALS AND METHODS:** Group K(-) is a negative control (normal) not given any treatment, Group K(+) is a positive control induced by aspirin 200 mg/kgBW, Group 1 (P1) is a treatment group induced by aspirin 200 mg/kgBW with ethanol extract of chayote 100 mg/kgBW, po, Group 2 (P2) was the treatment group induced by aspirin 200 mg/kgBW with ethanol extract of chayote 200 mg/kgBW, po, Group 3 (P3) was the treatment group induced by aspirin 200 mg/kgBW with ethyl acetate fraction chayote 100 mg/kgBW, PO, Group 4 (P4) was the treatment group induced by aspirin 200 mg/kgBW with ethyl acetate fraction chayote 200 mg/kgBW, PO, and Group 5 (P5) was the treatment group induced by aspirin 200 mg/kgBW with omeprazole 20 mg.

**RESULTS:** Analysis of the results of inflammatory infiltration in gastric histopathology in Groups P1, P2, P3, and P4 showed mild inflammatory infiltration compared to Groups P(5) and K(+). The description of the acinar glands on gastric histopathology showed that the P2 group gave a better picture of the acinar gland repair than the K(+), P2, P3, P4, and P5 groups.

**CONCLUSION:** This study showed that ethanol extracts of squash 200 mg/KgBW own effectiveness as an anti-inflammatory on the improvement of infiltration of inflammatory and picture histopathological gastric mice compared with the ethanol extract of squash 100 mg/kg, the fraction of ethyl acetate chayote 100 mg/KgBW and 200 mg/KgBW and omeprazole 20 mg.

**Edited by:** Branislav Filipović  
**Citation:** Silitonga HA, Siregar GA, Sembiring RJ, Nainggolan M. The Effectiveness of *Sechium edule* Jacq. Swartz Extract Changes in The Histopathology of Aspirin-Induced Rat Gastritis Model. Open Access Maced J Med Sci. 2021 Nov 22; 9(A):1252-1257. https://doi.org/10.3889/oamjms.2021.7072  
**Keywords:** Aspirin; Gastritis; *Sechium edule* Jacq. Swartz  
**\*Correspondence:** Gontar A. Siregar, Department of Internal Medicine, Faculty of Medicine, Universitas Sumatera Utara, Kota Medan, Indonesia. E-mail: gontarsiregar@gmail.com  
**Received:** 16-Aug-2021  
**Revised:** 09-Nov-2021  
**Accepted:** 12-Nov-2021  
**Copyright:** © 2021 Hendrika Andriana Silitonga, Gontar A. Siregar, Rosita Juwita Sembiring, Marline Nainggolan  
**Funding:** This research did not receive any financial support  
**Competing Interest:** The authors have declared that no competing interest exists  
**Open Access:** This is an open-access article distributed under the terms of the Creative Commons Attribution-NonCommercial 4.0 International License (CC BY-NC 4.0)

## Introduction

Gastritis is a common health problem, due to the fact that it is frequently diagnosed solely on the basis of clinical symptoms, rather than histological evaluation. Gastritis is an inflammatory condition of the gastric mucosa that can be transient or chronic, widespread, or localized. Gastritis is the gastric mucosa's response to irritants. The gastric epithelium is irritated by a variety of stimuli, both endogenous and exogenous, including HCl, pepsinogen/pepsin, bile salts, and medications, alcohol, and germs [1], [2], [3].

Inflammation is defined by an increase in the number of inflammatory cells in stomach biopsy specimens. There are numerous types of inflammatory cells, including macrophages, neutrophils, lymphocytes, and plasma cells. Gastritis can be classified according to the major inflammatory cell type. If there are numerous neutrophil cells, the condition is acute, but the presence of lymphocytes or plasma cells indicates

chronic gastritis. This difference in inflammatory cells is also seen in gastritis caused by *Helicobacter pylori*, nonsteroidal anti-inflammatory drugs, and chemicals. As a result, inflammatory cells become a critical indicator for diagnosing gastritis [4], [5].

Improving stomach mucosal defenses and reducing inflammation are critical components in treating gastritis. As a result, in the case of gastritis, treatment with medications generated from chemicals may increase inflammatory conditions, necessitating the use of an anti-inflammatory agent derived from nature, namely, chayote (*Sechium edule* Jacq. Swartz) [6].

*Sechium edule* (Jacq.) Swartz preliminary phytochemical screening revealed the presence of primary metabolites such as carbohydrates and proteins, as well as secondary metabolites such as saponins, phenols, flavonoids, steroids, tannins, terpenoids, and coumarins [7]. Flavonoids have also been found to have antispasmodic, antisecretory, antidiarrheal, and antiulcer actions in the gastrointestinal system [8], [9]. Due to their antioxidant characteristics,

flavonoids can help preserve the stomach mucosa, making them useful in the treatment of gastritis. One of the flavonoid compounds is quercetin, which inhibits the histidine decarboxylase enzyme, hence inhibiting histamine generation. Because histamine is a key mediator in inflammatory illnesses, meniran inhibits the inflammatory response caused by histamine in gastritis [10].

Chayote (*Sechium edule* Jacq. Swartz) may be used to treat gastritis. *Sechium edule* Jacq. Swartz contains flavonoids that have anti-inflammatory and antioxidant properties, as well as alkaloids that promote in cell regeneration [11], [12]. Thus, it is envisaged that the juice content of chayote (*Sechium edule* Jacq. Swartz) can be employed to restore the stomach mucosa in rats with aspirin-induced gastritis.

## Methods

### Materials

Aspirin (Kimia Farma), ethanol (Bratachem), ethyl acetate (Bratachem), pellet, methanol (Bratachem), hematoxylin (Sigma-Aldrich), eosin (Bratachem), toluene (Bratachem), Aquasterile (Bratachem), and ketamine (Kimia Farma) were used.

### Animal

The experimental study used 30 rats (*Rattus norvegicus*) in good health and weighing between 150 and 200 g. Rats are housed in plastic cages with a humidity level of 40–60% and a 12 h dark/light cycle. In addition, rats were given cratachem producing pellet diet and water *ad libitum*. The University of North Sumatra had granted ethics clearance for this project.

### Plant

*Sechium edule* Jacq. Swartz was collected in Berastagi, Sumatera Utara, Indonesia, cleaned, dried, and then blended till a dry powder was formed. In addition, the powder obtained was stored at room temperature and opened as needed.

### Ethyl acetate extract preparation

To begin the maceration process, dissolve the Siamese pumpkin (*Sechium edule* Jacq. Swartz) in a solvent, particularly ethyl acetate in a 1:10 (w/v) ratio, dissolved in 10 parts ethyl acetate, then poured with 75 parts 96% ethyl acetate. Covered and kept in a dark place for 5 days, stirring occasionally. After 5 days, the solution was filtered, the dregs were squeezed out, and the solution was rinsed with sufficient water

to get 100 parts. The juice (Maserati) was transferred to a closed vessel and stored in a cool, shaded area for 2 days. The resulting extract was then evaporated at a temperature of 500° in an evaporator, dried, and weighed [13].

### Ethanol extract preparation

The maceration procedure begins with dissolving the dregs of Siamese pumpkin (*Sechium edule* Jacq. Swartz) in ethanol using a solvent, specifically ethanol in a 1:10 (w/v) ratio, dissolved in 10 parts ethanol and then poured with 75 parts 96% ethanol. Covered and kept in a dark place for 5 days, stirring occasionally. After 5 days, the solution was filtered, the dregs were squeezed out, and the solution was rinsed with sufficient water to get 100 parts. The juice (Maserati) was transferred to a closed vessel and stored in a cool, shaded area for 2 days. The resulting extract was then evaporated at a temperature of 500° in an evaporator, dried, and weighed [13].

### Experimental design

This study used a sample of 35 male white rats divided into seven groups. Group K(-) is a negative control group (normal) that received no treatment, Group K(+) is a positive control group that received aspirin 200 mg/kg for 3 consecutive days, and Group 1 (P1) is a treatment group that received aspirin 200 mg/kgBW with chayote ethanol extract 100 mg/kgBW, po, Group 2 (P2) is the treatment group induced by aspirin 200 mg/kgBW with chayote ethanol extract 200 mg/kgBW, po, Group 3 (P3) is the treatment group induced by aspirin 200 mg/kgBW with chayote ethyl acetate fraction 100 mg/kgBW, po, and Group 4 (P4) for 28 days, chayote extract and omeprazole were administered. The rats were slaughtered on day 32 using stomach tissue obtained from the antrum-pylorus.

### Histopathology preparation

Antrum-pylorus was taken and the samples were soaked with liquid paraffin at 60–70°C for 2 h. It was molded and allowed to freeze, then the paraffin blocks were cut using a microtome with a thickness of 5–7 µm and were attached to slides. The organ incision that has been attached to the slide was immediately placed on a heating surface at a temperature of 56–58°C for approximately 10 s so that the organ stretches and sticks to the slide; adjustments were made to avoid wrinkled or folded organs. Further, hematoxylin-eosin staining was carried out. First, the preparations were soaked in xylene solution for the deparaffinization process for 12 min. Next, the dehydration process was carried out by soaking the

preparations in 70%, 80%, and 90%, and absolute ethanol for 5 min, and followed by washing using running water. Subsequently, the preparations were soaked with hematoxylin solution for 5 min, washed with running water, stained with eosin, and then dipped in ethanol 70%, 80%, and 90%, and absolute ethanol for 10 min. Finally, the preparations were put in xylene for 12 min. A microscope (Thermo, German) at  $\times 100$  was used to observe the preparations.

## Results

### ***Analysis of inflammatory infiltration in gastric histopathology***

The results of the analysis of inflammatory infiltration in gastric histopathology are shown in Table 1.

**Table 1: Data inflammatory infiltration in gastric histopathology**

Group	Inflammatory infiltration		
	None (%)	Mild (%)	Strong (%)
K(-)	4 (80)	1 (20)	-
K(+)	-	2 (40)	3 (60)
P1	-	5 (100)	-
P2	-	5 (100)	-
P3	-	5 (100)	-
P4	-	5 (100)	-
P5	-	-	5 (100)

Table 1 shows inflammatory infiltration in the tip of the group where in Group K(+) showed moderate inflammatory infiltration as many as 3 mice (60%) and 2 mice (40%) showed mild infiltration in gastric histopathology. Groups P1, P2, P3, and P4 showed mild infiltration (100%) while in Group P5 as many as 5 mice (100%) showed moderate infiltration.

### ***Analysis of acinar glands in gastric histopathology***

The results of the analysis of acinar glands in gastric histopathology in white male rats are shown in Table 2.

**Table 2: Data acinar glands in gastric histopathology**

Groups	Acinar glands						
	Not good (%)	Partially improved (%)	Well (%)	Atrophy <25% n (%)	Atrophy 25-50%	Atrophy 50%	Atrophy >75%
K(-)	-	-	5 (100)	-	-	-	-
K(+)	-	-	-	-	1 (20)	2 (40)	2 (40)
P1	1 (20)	1 (20)	3 (60)	-	-	-	-
P2	-	2 (40)	3 (60)	-	-	-	-
P3	1 (20)	-	-	-	1 (20)	3 (60)	-
P4	-	-	-	1 (20)	4 (80)	-	-
P5	-	-	-	-	4 (80)	1 (20)	-

Table 2 shows the description of the acinar glands on the gastric histopathological picture between the treatment groups.

## Discussion

Gastritis is a common ailment seen in internal medicine clinics and in everyday life. Gastritis is an inflammatory disorder affecting the mucosa and submucosa of the stomach, as well as health problems caused by irritation and infection. Histopathological evidence for this is the presence of inflammatory cells in the area [14].

Gastric biopsy can be used to confirm the diagnosis of gastritis. The purpose of this procedure is to assess the status of the gastric mucosa and to collect information about the diagnosis or prognosis that can be utilized to manage the patient's therapy later on. Erythema, exudative, flat erosion, elevated erosion, hemorrhages, and edematous rugae are all endoscopic characteristics of gastritis. Along with morphological changes, histopathological changes frequently describe the processes underlying the stomach mucosa's adaptive response [15], [16].

Aspirin is an acetylsalicylic acid that may irritate the stomach mucosa and alter the gastric epithelial barrier's permeability [17]. Gastritis and gastropathy are two types of gastric illnesses that can occur as a result of aspirin use [10], [18]. Gastritis caused by aspirin produces irritation of the gastric mucosa due to incomplete dissolution of aspirin pills, stomach absorption, or the presence of prostaglandin inhibition [19].

According to Nanlohy, where aspirin gives a picture of acute inflammation (acute gastritis) in the form of inflammatory cells in the mucous to serous layer, mucosal edema, and capillary dilation. Inflammation is a side effect of aspirin use, namely, irritation of the stomach caused by impaired prostaglandin synthesis. Disruption of prostaglandin synthesis causes impaired blood flow to the mucosal area and loss of the mucus layer that protects the gastric mucosa [20].

Preliminary phytochemical screening of *Sechium edule* (Jacq.) Swartz consists of primary metabolites, carbohydrates, and proteins and secondary metabolites, saponins, phenols, flavonoids, steroids, tannins, terpenoids, and coumarins [12].

Results of the analysis: The results of the inflammatory infiltration in gastric histopathology in Groups P1, P2, P3, and P4 showed mild inflammatory infiltration compared to Groups P(5) and K(+) (Table 2). The mechanism of action of flavonoids as natural antioxidants is to reduce or neutralize free radicals such as ROS and RNS through inhibition of enzymes that produce superoxide anion radicals such as xanthine oxidase and protein kinase. Flavonoids also inhibit cyclo-oxygenase, lipoxygenase, microsomal monooxygenase, glutathione S-transferase, mitochondrial succinate oxidase, and NADH oxidase which are all involved in the formation of ROS so that they can repair damaged tissue [8], [21].



Alkaloids reduce gastric acid secretion, increase mucus and alkali secretion, and improve gastric mucosal blood flow so as to help heal and prevent gastric ulcers against irritant agents/factors [9]. Alkaloid compounds reduce gastric acid secretion, increase mucus and alkali secretion, and improve gastric mucosal blood flow so as to help heal and prevent gastric ulcers against irritant agents/factors [22].

The mechanism of the action of saponins as gastroprotective is that saponins work by activating protective factors from the gastric mucous membrane [23]. Saponins have an inhibitory effect

on gastric mucosal lesions as a protective mucous membrane.

The results of the analysis of acinar gland images on gastric histopathology showed that the P2 group gave a better picture of acinar gland repair than the K(+), P2, P3, P4, and P5 groups (Table 2). The content of flavonoids in chayote is a compound that has pharmacological activity as an anti-inflammatory. The mechanism of flavonoids as anti-inflammatory can be through several pathways, namely, by inhibiting the activity of cyclooxygenase (COX) and lipoxygenase enzymes, inhibiting leukocyte accumulation, inhibiting neutrophil degranulation, and inhibiting histamine release. Inhibition of leukocyte accumulation during the

### Histopathology of gastric (Figure 1)

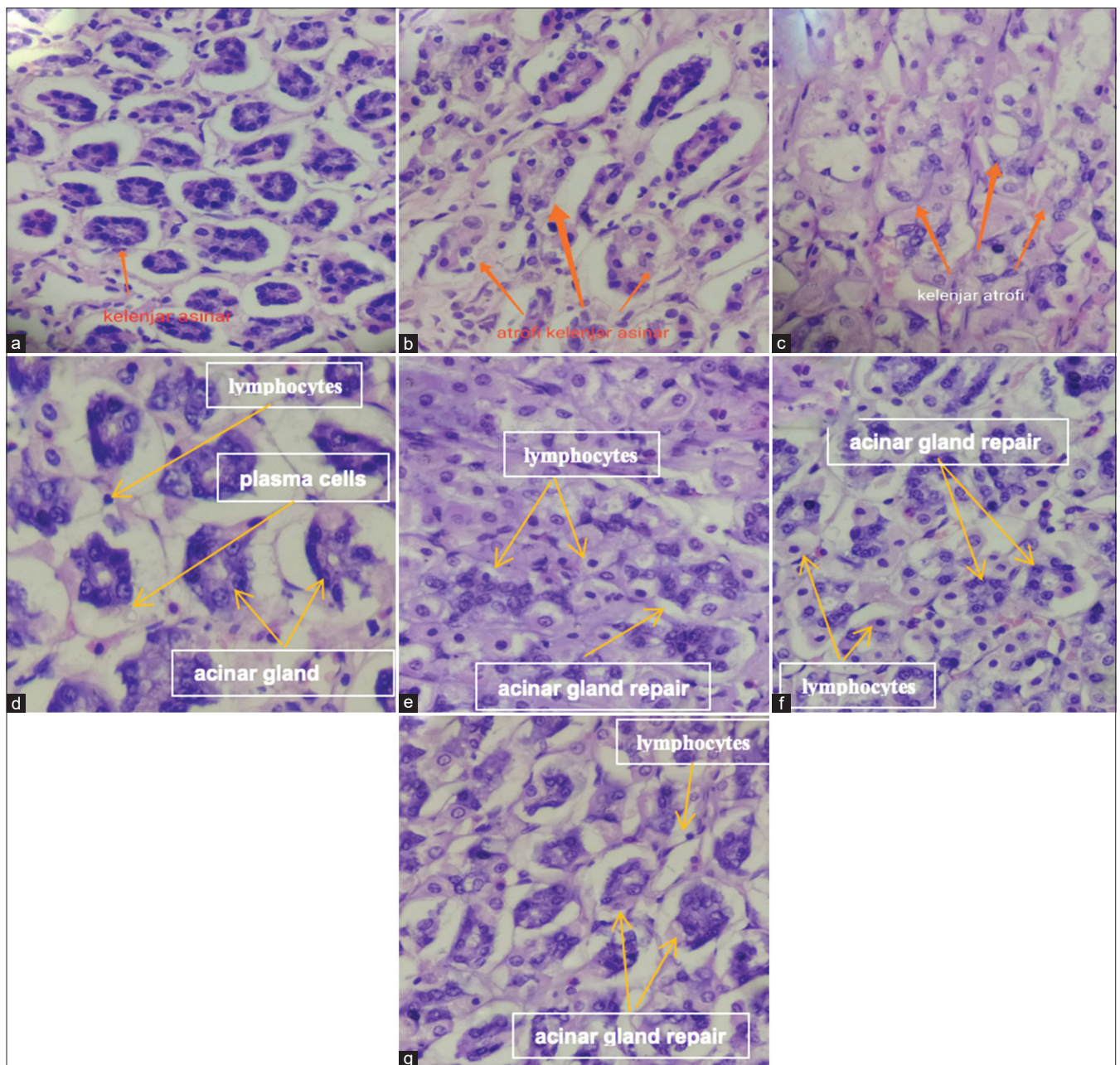


Figure 1: (a) Negative control: Gland appears good, inflammatory cells lymphocytes (-) neutrophils (-); (b) positive control: The acinar glands are mostly atrophic; (c) P1: Minimal aneurysm repair; (d) P2: Gland repair (+) with mild inflammation. Inflammatory cells of lymphocytes and plasma cells; (e) P3: Minimal acinar gland repair, atrophy, with mild lymphocytic cell invasion; (f) P4: Acinar gland repair (+), atrophy, with mild lymphocyte inflammatory cell invasion; (g) P5: Acinar gland repair (+), atrophy, with mild lymphocyte inflammatory cell infiltration (H&E ×400)

inflammatory process will cause a decrease in the body's response to inflammation, this inhibition of leukocyte accumulation is due to the inhibition of COX so that thromboxane will be inhibited where this thromboxane will cause leukocyte modulation. Inhibition of neutrophil degranulation will reduce the release of arachidonic acid by neutrophils. Inhibition of histamine release occurs because flavonoids can inhibit the release of histamine from mast cells [24].

In addition, the phenolic content in the chayote fruit is a compound that has potential as an antioxidant by counteracting free radicals in biological systems [5]. Mangiferin, which is a phenolic compound, has been reported to have gastroprotective activity with anti-secretion and antioxidant mechanisms [18].

Tannins are used as traditional medicine due to their astringent effect. This effect can cause tannins to react with tissue proteins. In peptic ulcer disease, it is this layer of tannin-protein complex that protects the stomach by increasing greater defense against irritating factors, tannins can function as antioxidants and increase tissue repair activity due to their anti-inflammatory activity [25].

Microscopic appearance of inflammatory infiltration and acinar glands on gastric mucosa with  $\times 400$  with (A) negative control; (B) positive control; (C) ethanol extract 100 mg/kgBW; (D) ethanol extract 200 mg/kgBW; (E) ethyl acetate fraction 100 mg/kgBW; (F) ethyl acetate fraction 200 mg/kgBW; and (G) omeprazole 20 mg/kgBW showed that the P2 group had a gastroprotective effect for further and chronic gastritis (Figure 1).

## Conclusion

This study shows that ethanol extract of 200 mg/kg weight of *Sechium edule* Jacq. Swartz can reduce inflammatory infiltration and repair of acinar glands in gastric mucosa of aspirin-induced rats compared to 100 mg/kg weight, ethyl acetate fraction of 100 mg/kg weight and 200 mg/kg weight of *Sechium edule* (Jacq.) Swartz Extract, and omeprazole 20 mg.

## Acknowledgments

The authors express their profound gratitude and appreciations to the Universitas Sumatera Utara and Universitas Methodist Indonesia for supporting this research.

## References

- Xuan J, Deguchi R, Yanagi H, Ozawa H, Urano T, Ogawa Y, *et al.* Relationship between gastric mucosal IL-8 levels and histological gastritis in patients with *Helicobacter pylori* infection. Tokai J Exp Clin Med. 2005;30(2):83-8. <https://doi.org/10.1007/s00535-005-1630-z>  
PMid:16146197
- Zhaoshen L, Duowu Z, Xiuqiang M, Jie C, Xingang S, Yanfang G, *et al.* Epidemiology of peptic ulcer disease: Endoscopic results of the systematic investigation of gastrointestinal disease in China. Am J Gastroenterol. 2010;105(12):2570-7.  
PMid:20736940
- Matsui H, Shimokawa O, Kaneko T, Nagano Y, Rai K, Hyodo I. The pathophysiology of non-steroidal anti-inflammatory drug (NSAID)-induced mucosal injuries in stomach and small intestine. J Clin Biochem Nutr. 2011;48(2):107-11. <https://doi.org/10.3164/jcbn.10-79>  
PMid:21373261
- Campbell KJ, Perkins ND. Regulation of NF-kappa $\beta$  function. Biochem Soc Symp. 2006;73(1):165-80.  
PMid:16626297
- Crabtree JE, Covacci A, Farmery SM. *Helicobacter pylori* induced interleukin-8 expression in gastric epithelial cells is associated with CagA positive phenotype. J Clin Pathol. 1995;48(1):41-5. <https://doi.org/10.1136/jcp.48.1.41>  
PMid:7706517
- Tanigawa T, Watanabe T, Higuchi K, Machida H, Yagami H, Watanabe K, *et al.* Lansoprazole, a proton pump inhibitor, suppresses production of tumor necrosis factor- $\alpha$  and interleukin-1 $\beta$  induced by lipopolysaccharide and *Helicobacter pylori* bacterial components in human monocytic cells via inhibition of activation of nuclear factor-kappaB and extracellular signal-regulated kinase. J Clin Biochem Nutr. 2009;45(1):86-92. <https://doi.org/10.3164/jcbn.08-267>  
PMid:19590712
- Zhao X, Wang Q, Qian Y, Song JL. Ilex kudingcha C.J. Tseng (Kudingcha) prevents HCl/ethanol-induced gastric injury in Sprague-Dawley rats. Mol Med Rep. 2013;7(10):1613-6. <https://doi.org/10.3892/mmr.2013.1402>  
PMid:23546392
- Gupta M, Neera S. Regeneration of beta cells in islet of Langerhans of pancreas of alloxan diabetic rats by acetone extract of *Momordica charantia* (Linn) (bitter melon) fruits. Indian J Exp Biol. 2006;45(1):1055-62.  
PMid:18254212
- Fenoglio-Preiser CM, Noffdinger AE, Stemmermann GN, Lantz PE, Isaacson PG. Gastrointestinal Pathology An Atlas and Text. 3<sup>rd</sup> ed. Philadelphia, PA: Lippincott Williams & Wilkins Wolter Kluwer; 2008. p. 155-61.
- Premkumar G. Preliminary phytochemical and nutritional profiles of an underutilized vegetable *Sechium edule* (Jacq.) Swartz. South Indian J Biol Sci. 2016;2(1):207-12. <https://doi.org/10.22205/sijbs/2016/v2/i1/100399>
- Eamlamnam K, Patumraj S, Visedopas N, Thong-Ngam D. Effects of Aloe vera and sucralfate on gastric microcirculatory changes, cytokine levels and gastric ulcer healing in rats. World J Gastroenterol. 2006;12(13):2034-9. <https://doi.org/10.3748/wjg.v12.i13.2034>  
PMid:16610053
- Oluwole FS, Maduabuchi NO, Odetola AA. Antiulcerogenic effects of *Phyllanthus amarus* in rats. Niger J Physiol Sci. 2002;17(2):52-6.

13. Nijveldt RJ, Nood EV, Hoorn DE, Boelens PG, Norren KV, Leeuwen PA. Flavonoids: A review of probable mechanisms of action and potential applications. *Am J Clin Nutr.* 2001;74(4):418-25. PMID:11566638
14. Ebadi MS. Pharmacodynamic Basis of Herbal Medicine. 2<sup>nd</sup> ed. United States: Taylor and Francis Group; 2007.
15. Falcao HD, de Jesus NZ, Gomes IF. Tannins, peptic ulcers and related mechanisms. *Int J Mol Sci.* 2012;13(3):3203-28. PMID:22489149
16. Nisa S. Gastritis (Warm-e-meda): A review with unani approach. *Int J Adv Sci Res.* 2018;3(3):43-5.
17. Wahyuni SD, Rumpati R, Lestarningsih RE. Hubungan pola makan dengan kejadian gastritis pada remaja. *Glob Health Sci.* 2017;2(2):149-54.
18. Sepulveda RA, Patil M. Practical approach to the pathologic diagnosis of gastritis. *Arch Pathol Lab Med.* 2008;132(10):1586-93. <https://doi.org/10.5858/2008-132-1586-pattpd> PMID:18834216
19. La Casa C, Villegas I, De La Lastra CA, Motilva V, Martin Calero MJ. Evidence for protective and antioxidant properties of rutin, a natural flavone, against ethanol induced gastric lesions. *J. Ethnopharmacol.* 2000;71(1):45-53. [https://doi.org/10.1016/S0378-8741\(99\)00174-9](https://doi.org/10.1016/S0378-8741(99)00174-9) PMID:10904145
20. Lima JT, Almeida JR, Barbosa-Filho JM, Assis TS, Silva MS, Dacunha EV, et al. Spasmolytic action of diplotropin, a furanoflavan from *Diplotropis ferruginea* Benth., involves calcium blockade in ginea-pig ileum. *Z Naturforsch B.* 2005;60:1-8.
21. Dyatmiko W, Maat S, Kusumawati I, Eko AT. *Sechium edule* (Jacq.) Swartz juice on total cholesterol and triglyceride levels in quekerbus mice. *J Penel Hayati.* 2004;9:139-42.
22. Mills SA, Contos MJ, Goel R. The stomach. In: Silverberg SG, editor. *Silverberg's Principles and Practice of Surgical Pathology and Cytopathology.* 4<sup>th</sup> ed., Vol. 2. New York: Churchill Livingstone, Elsevier; 2006. p. 1321-38.
23. Genta RM. Inflammatory disorders of the stomach. In: Odze RD, Goldblum JR, Crawford JW, editors. *Surgical Pathology of the GI Tract, Liver, Biliary Tract, Pancreas.* Philadelphia, PA: Saunders, Elsevier; 2004. p. 143-76.
24. HirLan. In: Sudoyo AW, editor. *Gastritis Dalam Ilmu Penyakit.* 5<sup>th</sup> ed., Vol. 1. Jakarta: Interna Publishing; 2009.
25. Rugge M, Robert MG, OLGA Group. Staging gastritis: An international proposal. *Gastroenterology.* 2005;129(5):1807-8. <https://doi.org/10.1053/j.gastro.2005.09.056> PMID:16285989