



The Effect of Topical and Oral Phenytoin on Increasing Wound Healing of Enterocutaneous Fistula in Wistar Rat

Victor Kurniawan^{1*}, Hardian Hardian², Ignatius Riwanto³

¹Biomedical Master Program, Diponegoro University, Semarang, Indonesia; ²Department of Physiology, Faculty of Medicine, Diponegoro University, Semarang, Indonesia; ³Department of Digestive Surgery, Faculty of Medicine, Diponegoro University, Semarang, Indonesia

Abstract

Edited by: Sasho Stoleski
Citation: Kurniawan V, Hardian H, Riwanto I. The Effect of Topical and Oral Phenytoin on Increasing Wound Healing of Enterocutaneous Fistula in Wistar Rat. Open Access Maced J Med Sci. 2022 Jan 25; 10(A):997-1000. <https://doi.org/10.3889/oamjms.2022.7885>
Keywords: Enterocutaneous fistula; Phenytoin; Wound healing
***Correspondence:** Victor Kurniawan, Diponegoro University Biomedical Master's Student, Indonesia, E-mail: vic.89.wan@gmail.com
Received: 07-Nov-2021
Revised: 27-Dec-2021
Accepted: 15-Jan-2022
Copyright: © 2022 Victor Kurniawan, Hardian Hardian, Ignatius Riwanto
Funding: This research did not receive any financial support
Competing Interests: The authors have declared that no competing interests exist
Open Access: This is an open-access article distributed under the terms of the Creative Commons Attribution-NonCommercial 4.0 International License (CC BY-NC 4.0)

BACKGROUND: Enterocutaneous fistula is an abnormal connection between gastrointestinal tract with skin or wound and studies showed low numbers of spontaneous fistula closure (20–30%) despite proper wound treatment and nutrition with high morbidity and mortality rate in fistula repair operation. Phenytoin, commonly used as an anticonvulsant, has shown its effects on wound healing process such as promoting fibroblast activities, formation of granulation tissue, reduction of collagenase activities, increasing collagen production, and other connective tissue components, reducing bacterial colonization, and reducing wound exudate.

AIM: To assess the effects of phenytoin in enterocutaneous fistula wound healing in Wistar rats (*Ratus norvegicus*).

MATERIALS AND METHODS: This is an experimental study with randomized post-test only design on 20 Wistar rats. A 5 mm enterocutaneous fistula was made on the rat's stomach and the rats were assigned randomly into three groups: K (control), P1 (10% phenytoin ointment), and P2 (0.03 mg/g oral phenytoin). The groups were terminated on day 7 and wound histological slides were made. The data were analyzed using SPSS software.

RESULTS: The delta diameter is highest in P1 group (mean + SD 0.928 + 0.078), followed by P2 (mean + SD 0.770 + 0.145), and control (mean + SD 0.411 + 0.120). There is a significant difference, $p < 0.05$ (0.000), between P1 and P2, indicating that oral phenytoin is more effective in collagen formation than topical phenytoin. There is no significant difference between P1 and P2, $p < 0.05$ (0.269), indicating that oral phenytoin is not more effective than topical phenytoin in granulation tissue in enterocutaneous fistula in Wistar rats.

CONCLUSION: Administration of topical and oral phenytoin was effective in increasing granulation tissue thickness, increasing collagen amount in wound tissue, and reducing the diameter of enterocutaneous fistulas in Wistar rats compared with control on the seventh day.

Introduction

Enterocutaneous fistula is an abnormal connection between the gastrointestinal tract with skin or wound [1]. The incidence of this fistula is high in inflammatory bowel disease, post-cancer surgery, adhesion removal, and trauma patients [2], [3], [4].

Enterocutaneous fistula treatment includes wound treatment, adequate nutrition, infection control, and fluid and electrolyte balance [5]. Some studies showed low numbers of spontaneous fistula closure (20–30%) despite proper wound treatment and nutrition with high morbidity and mortality rate in fistula repair operation [1], [4], [6], [7]. The understanding of basic principles of wound treatment, technique, and available materials is crucial to reduce the morbidity and mortality rate of patients with enterocutaneous fistula. Therefore, a study of new modality with higher efficacy for enterocutaneous fistula wound treatment is needed [5].

Phenytoin or diphenylhydantoin is commonly used as an anti-convulsant but recently it is studied for its effects on wound healing. Several studies have revealed the role of phenytoin in wound healing process such as promoting fibroblast activities, formation of granulation tissue, reduction of collagenase activities, increasing collagen production and other connective tissue component, reducing bacterial colonization and reducing wound exudate [8], [9], [10], [11], [12], [13], [14], [15]. Therefore, this study aims to assess the effect of phenytoin in the fistula wound healing process in Wistar rats. The results of this study are hoped to support the use of phenytoin as an option in the management of enterocutaneous fistulas.

Materials and Methods

This is an experimental study with randomized post-test only design. This study used 20 Wistar

rats (age 8–10 weeks, weight 100–150 g). A 5 mm enterocutaneous fistula was made on the rat's stomach. The rats were assigned randomly into three groups: K (control, wound treated with damp-dry sterile gauze dressing), P1 (10% phenytoin ointment and dry sterile gauze dressing), and P2 (0.03 mg/g oral phenytoin with dry sterile gauze dressing). The groups were terminated on day 7. All samples were treated in the same environment and diet. After termination, wound tissue was sampled up to the intestines and was prepared into histological slides. The histological slides were assessed by a pathological anatomist and the data was analyzed using SPSS version 25 for Windows. All experiments were conducted in *Laboratorium Institut Biosains Universitas Brawijaya, Malang* and *Laboratorium Patologi Anatomi Fakultas Kedokteran Universitas Brawijaya, Malang*.

Results

The delta diameter (day 7 treatment fistula diameter minus day 1 before treatment) is highest in P1 group (mean + SD 0.928 + 0.078), followed by P2 (mean + SD 0.770 + 0.145), and control (mean + SD 0.411 + 0.120). The amount of collagen increased in early phase of wound healing from the inflammation phase to the proliferation phase. There is a significant difference, $p < 0.05$ (0.000), between P1 and P2, indicating that oral phenytoin is more effective in collagen formation than topical phenytoin. Granulation tissue is thickest in P2, followed by P1, and control. There is no significant difference

Table 1: Delta diameter of enterocutaneous fistula (day 7 after treatment minus day 1 before treatment) in millimeters

Group	n	Mean ± SD
Control	6	0.411 ± 0.120
Topical	6	0.928 ± 0.078
Oral	6	0.770 ± 0.145

between P1 and P2, $p < 0.05$ (0.269), indicating that oral phenytoin is not more effective than topical phenytoin in granulation tissue in enterocutaneous fistula in Wistar rats (Figures 1-3 and Tables 1-3).

Table 2: The amount of collagen in the tissue between three treatment groups

Group	n	Mean + SD
Control	6	44.333 ± 9.048
Topical	6	126.167 ± 13.287
Oral	6	155.500 ± 10.709

Discussion

Similar results were seen in study done by Motawea *et al.* whose study found that administration of phenytoin powder resulted in reduction of ulcer diameter compared to treatment with only sterile gauze with normal saline [15]. Gupta *et al.* also yielded similar results using topical phenytoin [14].

Table 3: Granulation tissue thickness between three treatment groups

Group	n	Mean ± SD
Control	6	574.905 ± 9.183
Topical	6	845.351 ± 3.241
Oral	6	896.587 ± 81.295

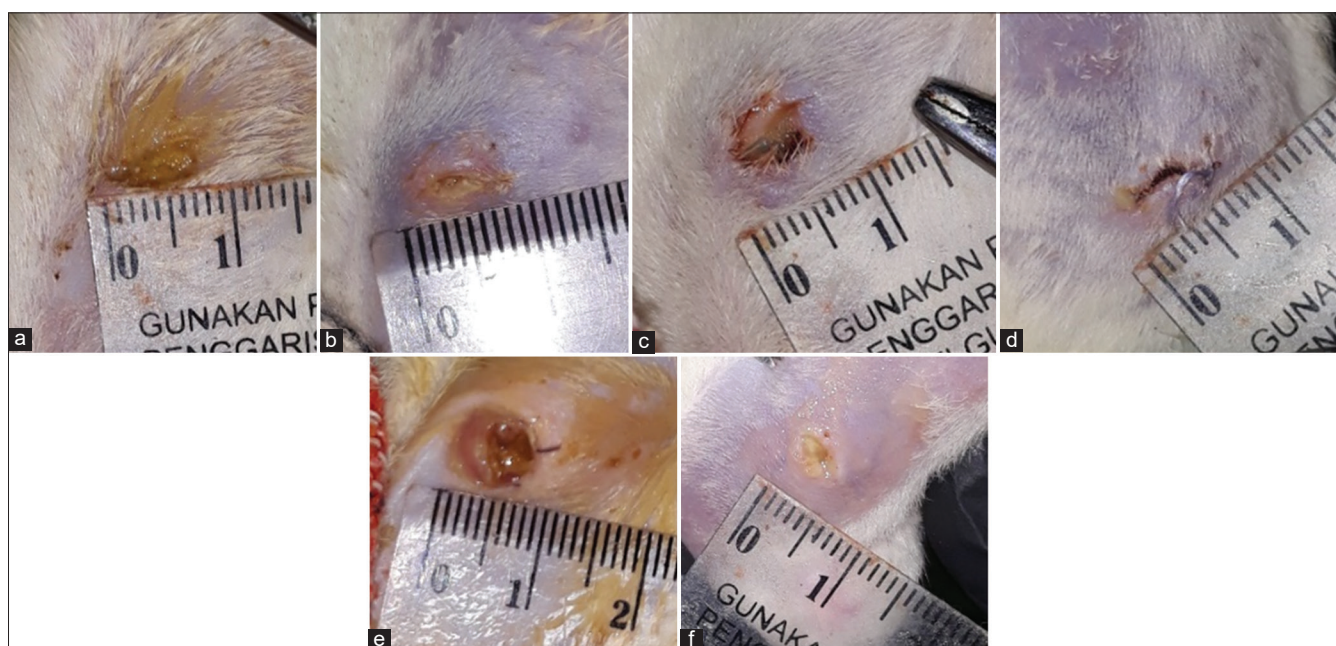


Figure 1: Macroscopic view of enterocutaneous fistula on day 1 and day 7 (termination) in control (K), topical treatment (P1), and oral treatment (P2) of phenytoin. (a) K-D1, (b) K-D7, (c) P1-D1, (d) P1-D7, (e) P2-D1, (f) P2-D7

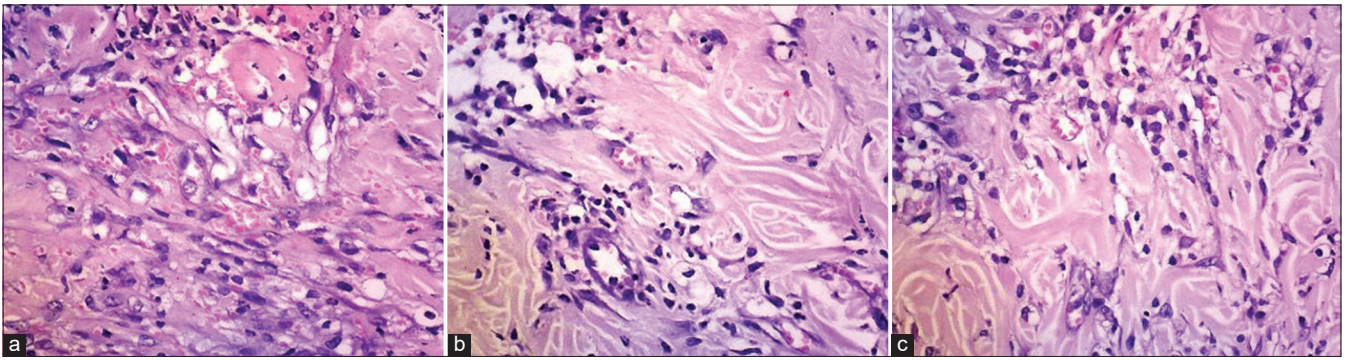


Figure 2: The amount of collagen in the tissue between three treatment groups (a) Control (b) Topical (c) Oral

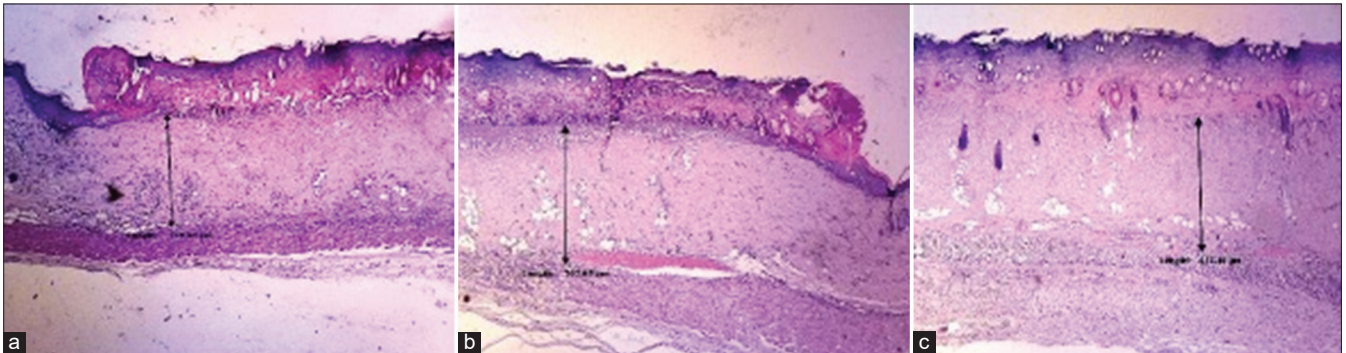


Figure 3: Granulation tissue thickness between three treatment groups (a) Control (b) Topical (c) Oral

Topical phenytoin had more effect on skin epithelization above the fistula tissue and thus skin closure was better compared to treatment using oral phenytoin. This aligns with the results from a study by Jain *et al.* who reported significant increase in epithelization, neovascularization, and tissue tensile strength in mice administered with topical phenytoin [12].

Systemic levels of phenytoin affect the formation of granulation tissue and other extracellular protein matrices [16]. A study of the effects of intravenous phenytoin on gastrointestinal fistula healing in mice revealed a faster healing process compared to conventional treatment [17]. This study also compared the doses of intravenous administration. The higher the level of phenytoin in blood resulted in more granulation tissue

Conclusion

Administration of topical and oral phenytoin was effective in increasing granulation tissue thickness, increasing collagen amount in wound tissue, and reducing the diameter of enterocutaneous fistulas in Wistar rats compared with control on the 7th day.

References

1. Sjamsuhidajat R, Dejong W. Buku Ajar Ilmu Bedah. 2nd ed. Jakarta: EGC; 2005. p. 636.
2. Enterocutaneous Fistula; 2013. Available from: <http://www.emedicine.medscape.com/article/1372132-overview> [Last accessed on 2013 Dec 15].
3. Parrish CR. Ostomies and fistula: A collaboration approach. *Pract Gastroenterol.* 2005;33:63-79.
4. Management of Enterocutaneous Fistula; 2001. Available from: <http://www.downstatesurgery.org/files/cases/enterocutaneousfistula.pdf> [Last accessed on 2013 Dec 15].
5. Schecter WP, Hirshberg A, Chang DS, Harris HW, Napolitano LM, Wexner SD, *et al.* Enteric fistulas: Principles of management. *J Am Coll Surg.* 2009;209(4):484-91. <https://doi.org/10.1016/j.jamcollsurg.2009.05.025> PMID:19801322
6. Lloyd DA, Gabe SM, Windsor AC. Nutrition and management of enterocutaneous fistula. *Br J Surg.* 2006;93(9):1045-55. <https://doi.org/10.1002/bjs.5396> PMID:16804873
7. Sheikh AR, Malik AM, Sheikh GA. Feasibility of early surgical intervention in postoperative entero-cutaneous fistulae. *J Ayub Med Coll Abbottabad.* 2010;22(4):37-40. PMID:22455257
8. Pratin C, Siriluck S. The management of patient with enterocutaneous fistula: A complex case study. *Wound Pract Res.* 2011;19:122-5.
9. Nordgren S, Fasth S, Hulten L. Anal fistulas in Crohn's disease: Incidence and outcome of surgical treatment. *Int J Colorectal Dis.* 1992;7(4):214-8. <https://doi.org/10.1007/BF00341224> PMID:1293243

10. Stewart DB Sr., Gaertner W, Glasgow S, Migaly J, Feingold D, Steele SR. Clinical practice guideline for the management of anal fissures. *Dis Colon Rectum*. 2017;60(1):7-14. <https://doi.org/10.1097/DCR.0000000000000735>
PMid:27926552
11. Jorge JM, Wexner SD. Etiology and management of fecal incontinence. *Dis Colon Rectum*. 1993;36(1):77-97. <https://doi.org/10.1007/BF02050307>
PMid:8416784
12. Jain BK, Vaibhaw K, Garg PK, Gupta S, Mohanty D. Comparison of a fistulectomy and a fistulotomy with marsupialization in the management of a simple anal fistula: A randomized, controlled pilot trial. *J Korean Soc Coloproctol*. 2012;28(2):78-82. <https://doi.org/10.3393/jksc.2012.28.2.67>
PMid:22606642
13. Xu Y, Liang S, Tang W. Meta-analysis of randomized clinical trials comparing fistulectomy versus fistulotomy for low anal fistula. *Springerplus*. 2016;5(1):1722. <https://doi.org/10.1186/s40064-016-3406-8>.
PMid:27777858
14. Gupta PJ, Heda PS, Shirrao SA, Kalaskar SS. Topical sucralfate treatment of anal fistulotomy wounds: A randomized placebo-controlled trial. *Dis Colon Rectum*. 2011;54(6):699-704. <https://doi.org/10.1007/DCR.0b013e31820fcd89>
PMid:21552054
15. Motawea A, Abd El-Gawad AE, Borg T, Motawea M, Tarshoby M. The impact of topical phenytoin loaded nanostructured lipid carriers in diabetic foot ulceration. *Foot (Edinb)*. 2019;40:14-21. <https://doi.org/10.1016/j.foot.2019.03.007>
PMid:30999080
16. Sayar H, Gergerlioglu N, Seringec N, Ozturk P, Bulbuloglu E, Karabay G. Comparison of efficacy of topical phenytoin with hypericin in second-degree burn wound healing: An experimental study in rats. *Med Sci Monit Basic Res*. 2014;20:36-46. <https://doi.org/10.12659/MSMBR.890337>
PMid:24694757
17. Iqbal MK, Saleem S, Iqbal A, Chaudhuri A, Pottoo FH, Ali J, *et al*. Natural, synthetic and their combinatorial nanocarriers based drug delivery system in the treatment paradigm for wound healing via dermal targeting. *Curr Pharm Des*. 2020;26(36):4551-68. <https://doi.org/10.2174/1381612826666200612164511>
PMid:32532188