



# Utilization of “Perineal Wound Image Application” In Perineal Wound Digital Image Screening

Bina Melvia Girsang<sup>1\*</sup>, Eqlima Elfira<sup>2</sup>

<sup>1</sup>Department of Maternity and Child, Faculty of Nursing, Universitas Sumatera Utara, Medan, Indonesia; <sup>2</sup>Department of Surgical Nursing, Faculty of Nursing, Universitas Sumatera Utara, Medan, Indonesia

## Abstract

**Edited by:** Ana Vucurevic  
**Citation:** Girsang BM, Elfira E. Utilization of “Perineal Wound Image Application” In Perineal Wound Digital Image Screening. Open Access Maced J Med Sci. 2022 Jan 16; 10(G):467-471. <https://doi.org/10.3889/oamjms.2022.7945>  
**Keywords:** Healing; Logic; Perineum  
**\*Correspondence:** Bina Melvia Girsang, Department of Maternity and Child, Faculty of Nursing, Universitas Sumatera Utara, Indonesia. E-mail: [binamelvia@usu.ac.id](mailto:binamelvia@usu.ac.id)  
**Received:** 13-Nov-2021  
**Revised:** 30-Dec-2021  
**Accepted:** 06-Jan-2022  
**Copyright:** © 2022 Bina Melvia Girsang, Eqlima Elfira  
**Funding:** This study was supported by Indonesian Ministry of Education and Culture  
**Competing Interests:** The authors have declared that no competing interests  
**Open Access:** This is an open-access article distributed under the terms of the Creative Commons Attribution-NonCommercial 4.0 International License (CC BY-NC 4.0)

**BACKGROUND:** A variety of serious conditions can affect the perineum, from infections that clear up on their own to conditions that are dangerous or add to the patient's discomfort. Data at the level of each zone are an important factor for determining the area of wound healing. Injury investigations should include the identification of the injury, the calculation of the area of the injury which is generally important in determining treatment.

**AIM:** This study aims to present the findings of determining the characteristics of the perineal wound category and determining the area of the wound using MATLAB programming.

**MATERIALS AND METHODS:** The trial data in this study used 10 digital images with the development of 1000 trials and resulted in an accuracy rate of 86%. Digital image application is designed with 11 categories of perineal wounds that include assessment of wound color and characteristics.

**RESULTS:** The use of the application was carried out by 21 midwife health workers with the results of 81% of applications making it easier for officers to classify wounds, and 85.7% stated that the application could be a guide in making decisions about perineal wound care. Determination of wound categories and perineal wound area in this program proves the ease for health workers in planning appropriate care and treatment. This makes it very easy for users to do programming so that users are not too bothered by programming logic and focus more on the logic of solving problems on a hand.

**CONCLUSION:** The development of innovative perineal wound screening applications will provide convenience in practicality and efficiency of use in the future.

## Introduction

Various factors play a role in the type and severity of trauma experienced, parity, delivery technique, and delivery assistance practices. There is currently a discussion about the best obstetric observations to reduce perineal trauma [1]. A wide variety of serious conditions can affect the perineum, ranging from self-limiting infections to conditions that may be dangerous or add significant patient discomfort if not analyzed and treated appropriately [2]. Delayed perineal wound repair is a difficulty encountered during perineal injury [3], [4], and different risk factors have been illustrated to identify with planned perineal injury repair. Injury to the sphincter is also a common complaint [5]. In addition, the choice of preoperative radiotherapy can also cause tissue damage [4]. These reasons can interfere with wound healing and lead to delayed wound healing. It should also be borne in mind that patients with vulvar or vaginal injuries in some cases present with abdominal or lower back pain as their chief complaint.

External wounds can be distinguished effectively, but must be carefully assessed for deeper extensions. Internal injuries are more difficult to

evaluate [6]. Assess for less common indications, e.g., serious pain, lump or mass, or odd discharge, including spilled stool [7]. Imaging is important in the clinical administration record of perineal disease because it allows precise anatomical delimitation of the source and extent of disease.

Complex perineal experience, use of concurrent imaging modalities, and multiple imaging findings found in intense perineal conditions are essential for rapid and precise analysis. Different imaging modalities are accessible to assess intense perineal conditions, each with its own focal point and lack of condition. Figured tomography is used to a large extent in settings of intense consideration given its long range accessibility, and fast image security [2]. This is a difficult task due to the complexity of the injuries, varying lighting conditions, and time constraints at the clinical research center. Wounds have several qualities that are identified with shadow and surface, but these qualities are not the same across all injury and individual images. Thus, research is not yet complete and future exploration may improve the picture of the injury [8].

Injury investigations should include identification of the margins of the injury, calculation of

the area of injury, and generally important, examination of the shading of the injury. Most wounds have a non-uniform combination of yellow necrotic tissue and red granulation tissue. Data at the level of each zone are an important factor in determining the area of wound healing, so assessment of treatment proficiency and further treatment options objective, compact, reproducible, subjective and quantitative examination of the wound is essential in achieving treatment agreement [9]. Injury Image Investigation Classifier has been actualized using MATLAB. This classifier classifies wounds by considering the healing status of the wound taking into account the different colors associated with wound progression and the different stages the injury goes through in the repair cycle. To improve wound healing outcomes, it is important that injuries are surveyed and monitored in an appropriate and appropriate manner. Perineal injuries can cause critical physical and mental effects in the short- or long-term, but there is little available evidence on this issue [1].

## Materials and Methods

This wound imaging uses MATLAB to identify the image of perineal wounds. The test results show that this method is able to detect the presence of wound images in perineal conditions with a percentage of success reaching 85% and for non-ideal image conditions able to achieve 37% accuracy [10].

In this study, a series of programming processes were carried out starting with the extraction of the red, green, and blue (RGB) pixel values, which separated the three colors of the wound image test. RGB images are converted into grayscale images and create a histogram image on a 1-dimensional image matrix, so that when implemented in an image matrix, only red, green, only blue, or grayscale matrices appear. In the process of determining the area of the perineal wound, the wound image is converted to a binary image. Next is processing the shape and structure of an object, and image filters to calculate the local representation of several pixels in the image. The selection of the wound area to be measured is carried out with an edge detection program, and followed by image reconstruction to get the right image analysis area.

## Results

In this study, we will explain the basics of digital image processing of perineal wounds using MATLAB. As it is known that MATLAB is a computational language that has a lot of built-in functions related to matrices and

equations commonly used in certain fields, making it very easy for users to do programming so that users don't get too confused with programming logic and focus more on solving logic problems encountered.

The assessment of wound categories based on the color and characteristics of the wound in this study contained 11 categories with the determination of categories referring to Kumar's research (2014). Wound assessment categories are divided based on the color and characteristics of the perineal wound, as shown in Table 1:

**Table 1: Category grouping based on perineal wound base color**

Wound base color	Wound category
Dark red	Healthy tissue, Good blood flow
Red oxide	Healthy tissue, Good blood flow
Pink	Poor blood flow, Anemia
Violet	Poor blood flow, Anemia
Gray Blue	Swelling, trauma
Purple	Enlarged, swollen, high bacteria level, trauma
Black	Necrotic tissue (Non Viable)
Chocolate	Non-viable tissue
Yellow	Non-regenerating (Non Viable), moist, exfoliated
Green	Tissue can't regenerate
White	Maceration, poor blood flow

The test of application utilization was carried out on health service midwives who monitored the postpartum period in their working area. In Table 1, and it can be seen the appearance of wound categories based on the color of the perineal wound surface. The determination of the number of digital images as a trial was based on the number of previous studies that used 10 wound image objects in the process of programming wound analysis, as a tool for health workers to intervene in perineal wounds with 86% accuracy [11].

In Figure 1 is a display of application use in determining wound categories based on the color

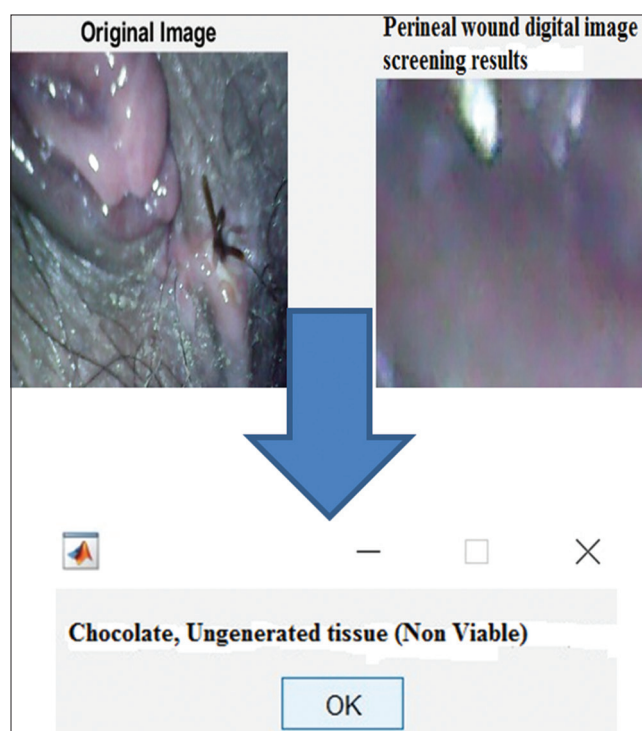


Figure 1: Perineal wound screening categorization

of the wound surface. The algorithm used in the implementation of perineal wound image recognition using MATLAB from 10 testing images with a testing accuracy of 82%, and developed into 1000 image exercises to increase application accuracy, with the development of 1000 trials on each perineal image with 86% accuracy results.

The results of digital image filtering are implemented in the `imfilter` function for RGB (3-D) images and filters for grayscale or 2-D images. The filter used is a gaussian filter with a  $12 \times 12$  matrix, then the reconstruction process is carried out using the `imfill` function to produce a clear image.

In the next stage, digital image processing is carried out by measuring the circumference of the perineal wound. This function aims to show an overview of perineal wound repair based on the reduction of the perineal wound area. Object selection is done by edge detection step in the image processing process, in MATLAB edge detection process is done by edge command/function. In Figure 2, the measurement of the wound is not the actual size of the wound but is a digital image that can be measured in millimeters.

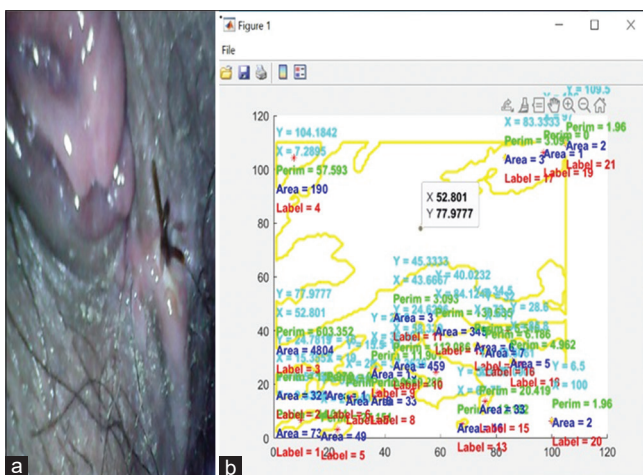


Figure 2: Calculation of wound area on digital image. (a) perineal wound digital image; (b) analysis of wound area assessment

The results of the analysis of the perineal wound screening program were given to a number of 21 midwives. In Figure 3, it can be seen that the results of the analysis show that 85.7% of this application serves as a guide in planning perineal wound care, and 81% makes it easy to categorize perineal wounds. The results obtained are quite satisfactory that the use of perineal wound image analysis applications can help midwives in making decisions about perineal wound care.

## Discussion

The type and severity of trauma experienced is associated with multiple factors, including birth

history, delivery methods, and local practices. The best midwifery practices to reduce perineal trauma are still under debate. When perineal trauma occurs, treatment varies greatly depending on its severity and severity, local customs and customs, and personal preferences. Proper and timely assessment and management of wounds is important to optimize wound healing outcomes. Perineal wounds can cause significant physical and/or psychological effects in the short- or long-term, but there is little evidence on this subject [1]. The use of digital images in wound care is a recent innovation and an advancement in obstetrics. The ability to refer to previous digital images and assess progress is important in deciding treatment strategies.

Patients and nursing staff no longer need to make subjective judgments comparing the current condition of the wound with the previous condition, the appearance of the wound category based on the analysis of digital image applications is designed to make it easier for health workers to screen perineal wounds. Digital image analyzers can be easily used in screening perineal wound changes in postpartum care settings or at home. The use of digital image analysis should be a reliable measure using technology, which is common today, rather than an ideal measure for changes in the wound area. Our data don't tell us the true size of the wound, but it does show that we can reliably measure change over time. The degree of change in the area over time is an important prognostic indicator of complete wound healing [12].

The results of repeated examinations of 10 digital images refer to the research of Rogers, 2010 with 10 different analytical objects with good wound documentation capabilities, and can be referred by other health examiners [13]. The proportion of black, yellow, and red in the wound depends on the healing time. For example, in the case of red color classification, granulation tissue has a distinct red color. It should also be noted that not all red sores are healthy. This study refers to the classification of color and characteristics of the wound from the research of Kumar (2014), with a total of 11 types of perineal wound categories [14]. The digital image analysis capability of this application makes it easier to examine postpartum mothers' perineal wounds during recovery at home or at midwifery services. The application of wound assessment or monitoring methods is divided into (a) wound assessment or monitoring and (b) data acquisition and information storage, 16 studies reported wound assessment or monitoring [15], [16], [17].

Yellow wound color wounds indicate the presence of plaque [14], [15]. The occurrence of venous ulcers is associated with biological stress [15]. While the color of necrotic tissue varies from white to yellow, greenish to black and includes all colors. The fourth color classification (pink) stated in the research of Hellgren and Vincent (1990), is the wound re-epithelialization stage, more sophisticated color classification models such as



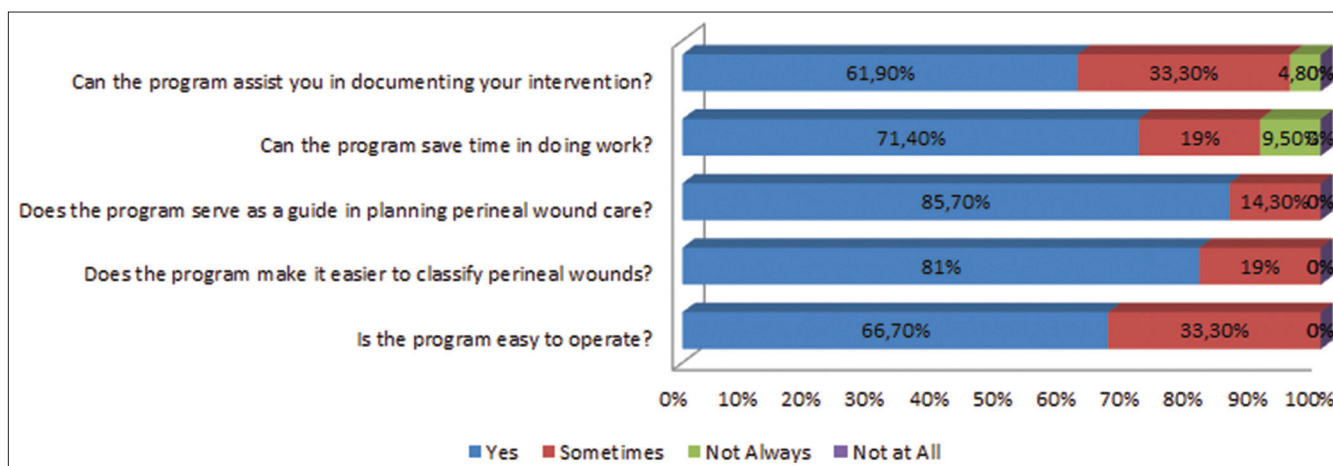


Figure 3: Assessment of health workers midwives in the use of digital image applications in wound screening

black, brown, yellow-red, and red are used to overcome this problem [16]. Ratings with this category apply in the assessment of wounds and skin lesions [17]. The classification for ulcers was described by Arnqvist, *et al.* (1988), as the fourth classification besides the black-yellow-red classification [18]. The previously designed method tracks the wound boundaries using a computer mouse and determines the region of interest which is also carried out in this study. Arnqvist and colleagues created 16 wound classifiers for arteries, veins, and surgery from thousands of different color photographs [18]. In this study, the perineal wound examiner operator selects a wound classifier and algorithm, classifies wound images into eleven tissue types, and calculates each wound area in millimeters. In the study by Herbin *et al.* [2] examined, color images of artificially created wounds to quantitatively assess healing rates. They automatically delineate the wound area based on the wound color (redness) information. The wound area and wound color index were then used to assess skin healing. However, while these sores are uniform in color, wounds in patients such as venous ulcers can have a distinct red color. An automated method for measuring pressure wound healing using a RGB histogram of the wound [19], [20], [21], [22], [23]. A total of 21 midwife health workers analyzed the application by analyzing the color of the wound, and the area of the wound.

## Conclusion

The development of innovative perineal wound screening applications will provide convenience in practicality and efficiency of use in the future. the use of digital image applications is recommended for health workers who often work outside the building or home visits in conducting postpartum monitoring of the dangers of infection in the perineal wound which can also be used as monitoring and documentation of wounds as data for further investigation.

## Acknowledgment

This research was funded by the Indonesian Ministry of Education and Culture, through the director general of higher education, and Universitas Sumatera Utara research institute. It is hoped that this research can be further developed into innovations in health services, especially postpartum wound monitoring services.

## Ethical Clearance

Ethical permission is approval from the Research Ethics Committee of the University of North Sumatra, Medan, Number: 520/KEP/USU/2021.

## References

- O'Kelly SM, Moore ZE. Antenatal maternal education for improving postnatal perineal healing for women who have birthed in a hospital setting. *Cochrane Database Syst Rev.* 2017;12(12):CD012258. <https://doi.org/10.1002/14651858.CD012258.pub2>  
PMid:29205275
- Choe J, Wortman JR, Sodickson AD, Khurana B, Uyeda JW. Imaging of acute conditions of the perineum. *Radiographics.* 2018;38(4):1111-30. <https://doi.org/10.1148/rg.2018170151>  
PMid:29906202
- Althumairi AA, Canner JK, Gearhart SL, Safar B, Sacks J, Efron JE. Predictors of perineal wound complications and prolonged time to perineal wound healing after abdominoperineal resection. *World J Surg.* 2016;40(7):1755-62. <https://doi.org/10.1007/s00268-016-3450-0>  
PMid:26908238
- Bullard KM, Trudel JL, Baxter NN, Rothenberger DA. Primary perineal wound closure after preoperative radiotherapy and

- abdominoperineal resection has a high incidence of wound failure. *Dis Colon Rectum*. 2005;48(3):438-43. <https://doi.org/10.1007/s10350-004-0827-1>  
PMid:15719190
5. Holm T, Ljung A, Häggmark T, Jurell G, Lagergren J. Extended abdominoperineal resection with gluteus maximus flap reconstruction of the pelvic floor for rectal cancer. *Br J Surg*. 2007;94(2):232-8. <https://doi.org/10.1002/bjs.5489>  
PMid:17143848
  6. Evaluation and Management of Female Lower Genital Tract Trauma-UpToDate; 2020. Available from: [https://www.uptodate.com/contents/evaluation-and-management-of-female-lower-genital-tract-trauma?sectionname=vagina&topicref=5399&anchor=h15&source=see\\_link#h15](https://www.uptodate.com/contents/evaluation-and-management-of-female-lower-genital-tract-trauma?sectionname=vagina&topicref=5399&anchor=h15&source=see_link#h15) [Last accessed on 2020 Oct 26].
  7. Postpartum Perineal Care and Management of Complications-UpToDate; 2020. Available from: [https://www.uptodate.com/contents/postpartum-perineal-care-and-management-of-complications?topicRef=5399&source=see\\_link](https://www.uptodate.com/contents/postpartum-perineal-care-and-management-of-complications?topicRef=5399&source=see_link) [Last accessed on 2020 Oct 23].
  8. Pires IM, Garcia NM. Wound area assessment using mobile application. *Biodevices*. 2015;1:271-82.
  9. Ama F. Non-invasive evaluation using image analysis to accelerate wound healing with the help of electrical stimulation. *J Ilm Pendidik Eksakta*. 2017;3(2):208-14.
  10. Christianto M. Identifikasi Citra Luka Abalon (Haliotis Asinina) Menggunakan Gray Level Co-Occurrence Matrix dan Klasifikasi Probabilistic Neural Network; 2014.
  11. Rogers LC, Bevilacqua NJ, Armstrong DG, Andros G. Digital Planimetry Results in More Accurate Wound Measurements: A Comparison to Standard Ruler Measurements; 2010. <https://doi.org/10.1177/193229681000400405>
  12. Margolis DJ, Allen-Taylor L, Hoffstad O, Berlin JA. The accuracy of venous leg ulcer prognostic models in a wound care system. *Wound Repair Regen*. 2004;12(2):163-8. <https://doi.org/10.1111/j.1067-1927.2004.012207.x>  
PMid:15086767
  13. Baxes G. *Digital Image Processing: Principles and Applications*; 1994. Available from: [https://www.keov.in.net/index\\_loh.pdf](https://www.keov.in.net/index_loh.pdf) [Last accessed on 2020 Feb 04].
  14. Kumar SK, Reddy BE. Wound image analysis classifier for efficient tracking of wound healing status. *Signal Image Process Int J*. 2014;5(2):15-27.
  15. Goyal M, Reeves ND, Rajbhandari S, Ahmad N, Wang C, Yap MH. Recognition of ischaemia and infection in diabetic foot ulcers: Dataset and techniques. *Comput Biol Med*. 2020;117:103616. <https://doi.org/10.1016/j.compbiomed.2020.103616>  
PMid:32072964
  16. Nouvong A, Hoogwerf B, Mohler E, Davis B, Tajaddini A, Medenilla E. Evaluation of diabetic foot ulcer healing with hyperspectral imaging of oxyhemoglobin and deoxyhemoglobin. *Am Diabetes Assoc*. 2009;32(11):2056-61. <https://doi.org/10.2337/dc08-2246>  
PMid:19641161
  17. Rajbhandari SM, Harris ND, Sutton M, Lockett C, Eaton S, Gadour M, *et al*. Digital imaging: An accurate and easy method of measuring foot ulcers. *Diabet Med*. 1999;16(4):339-42. <https://doi.org/10.1046/j.1464-5491.1999.00053.x>  
PMid:10220209
  18. Boardman M, Melhuish JM, Palmer K, Harding KG. Hue, saturation and intensity in the healing wound image. *J Wound Care*. 1994;3(7):314-9. <https://doi.org/10.12968/jowc.1994.3.7.314>  
PMid:27922367
  19. Harding KG. Wound care: Putting theory into clinical practice. *Wounds*. 1990;2(1):21-32.
  20. Engström N, Hansson F, Hellgren L, Johansson T, Nordin B, Vincent J, *et al*. Computerized wound image analysis. *Pathog Wound Biomater Infect*. 1990:189-92. [https://doi.org/10.1007/978-1-4471-3454-1\\_24](https://doi.org/10.1007/978-1-4471-3454-1_24)
  21. Berriss W, Wounds SJ. Automatic Quantitative Analysis of Healing Skin Wounds Using Colour Digital Image Processing; 1997. Available from: <http://www.worldwidewounds.com/1997/july/berriss/berriss.html> [Last accessed on 2021 Nov 13].
  22. Arnqvist J, Hellgren J. Semiautomatic Classification of Secondary Healing Ulcers in Multispectral Images; 1988. Available from: <https://www.computer.org/csdl/proceedings-article/icpr/1988/00028266/12omnylbofm> [Last accessed on 2021 Nov 13].
  23. Berriss W, Sangwine S. A Colour Histogram Clustering Technique for Tissue Analysis of Healing Skin Wounds; 1997. [https://doi.org/10.1049/cp\\_19970984](https://doi.org/10.1049/cp_19970984)