



# Pleomorphic Rhabdomyosarcoma on the Lumbal in Adult Patient: A Case Report

Otman Siregar<sup>1</sup> , Edwin Yosua Silitonga<sup>2\*</sup>, Pranajaya Dharma Kadar<sup>1</sup>, Heru Rahmadhany<sup>1</sup>, Benny Benny<sup>1</sup>

<sup>1</sup>Department of Orthopedic and Traumatology, Spine Division, Faculty of Medicine, University of Sumatera Utara, Haji Adam Malik Hospital, Medan, Indonesia; <sup>2</sup>Department of Orthopedic and Traumatology, Faculty of Medicine, University of Sumatera Utara, Haji Adam Malik Hospital, Medan, Indonesia

## Abstract

**Edited by:** Igor Spiroski

**Citation:** Siregar O, Silitonga EY, Kadar PD, Rahmadhany H, Benny B. Pleomorphic Rhabdomyosarcoma on the Lumbal in Adult Patient: A Case Report. Open Access Maced J Med Sci. 2022 Jan 18; 10(C):179-181.  
<https://doi.org/10.3889/oamjms.2022.8098>

**Keywords:** Pleomorphic rhabdomyosarcoma; Lumbal; Histology; Immunohistochemical

**\*Correspondence:** Edwin Yosua Silitonga, Department of Orthopedic and Traumatology, Faculty of Medicine University of Sumatera Utara Haji Adam Malik Hospital, Medan, Indonesia

E-mail: [dr.pranajaya.dharma.kadar.spot@gmail.com](mailto:dr.pranajaya.dharma.kadar.spot@gmail.com)

**Received:** 27-Nov-2021

**Revised:** 06-Jan-2022

**Accepted:** 08-Jan-2022

**Copyright:** © 2022 Otman Siregar, Edwin Yosua Silitonga, Pranajaya Dharma Kadar, Heru Rahmadhany, Benny Benny

**Funding:** This research did not receive any financial support

**Competing Interests:** The authors have declared that no competing interests exist

**Open Access:** This is an open-access article distributed under the terms of the Creative Commons Attribution-NonCommercial 4.0 International License (CC BY-NC 4.0)

**BACKGROUND:** The incidence of rhabdomyosarcoma in children found at the top of age 5–15 years, with median age about 10 years. In adult, the tumor occurs about 10% of all cases. PRMS is a very rare subtype of RMS and almost exclusively in male patient older than 45 years. Approximately 40% of RMS occur in the head and neck region, RMS in the trunk is rare. RMS arising from the paraspinal area only comprises 3.3% of all cases.

**CASE REPORT:** This case report described a 38-year-old male with lump on his back, since 1 year ago and enlarge slowly until bigger than a tennis ball, with no neurological deficit. Based on MRI with contrast, there is a solid mass on the subcutis on the level L4-5 with size 7.5 × 3 × 7.2 cm. The patient was underwent wide excision and the histopathology examination was referred to pleomorphic rhabdomyosarcoma. The patient underwent radiotherapy procedure for 1 month in outpatient clinic, with maximum dose radiotherapy 60 Gy, and the patient underwent 30 times session of radiotherapy with dose 2 Gy for each session. After 1.5 years of control, there is no sign of recurrences. Based on clinical, radiologic, and histological examination, the diagnosis of pleomorphic rhabdomyosarcoma confirmed by an expert pathology consultant. Immunohistochemical examination was performed, and the patient underwent wide excision and definitive radiotherapy.

**CONCLUSION:** Pleomorphic rhabdomyosarcoma on the back is extremely rare and difficult to distinguish histologically. This is a very valuable case, which highlights the need for orthopedic surgeons to re-evaluate clinical and histologic finding carefully when diagnosing patients with soft-tissue tumor on the lumbal region.

## Introduction

Rhabdomyosarcoma (RMS) is a malignant soft-tissue sarcoma of the skeletal muscle which originates from mesenchymal tumor. In adult, the tumor occurs about 10 % of all cases. RMS is divided into four major subtypes, embryonal RMS (ERMS), alveolar RMS (ARMS), pleomorphic RMS (PRMS), and spindle cell/sclerosing RMS (SRMS) [1]. ERMS and SRMS occur often in young children; meanwhile, PRMS is very rare, almost exclusively in male patient older than 45 years. Twelve PRMS have been reported of all time, arising on the dermis and/or subcutis. Overall, approximately 40% of RMS occurs in the head and neck region, RMS in the trunk is rare. Truncal sites include the chest wall, paraspinal area, and abdominal wall. Of these subsites, the most common location is the chest wall, RMS arising from the paraspinal area only comprises 3.3% of all cases [1].

## Objective

The purpose of this case series was to show a rare case of pleomorphic rhabdomyosarcoma on the back in adult patients.

## Case Report

A 38-year-old male patient presented with a chief complaint of a lump on his back one year ago. Previously, the lump was in coin size but now the size as big as a tennis ball, as shown in Figure 1. There was not any trauma recently. The patient was in normal condition with no significant weight loss, prolong cough, and night sweat. Bladder was normal and had no history in family with same complaint. Physical examination found palpable mass on the lumbal region with old scar and size 7 × 10 cm, well defined border, soft consistency, smooth surface, and mobile. MRI showed a solid mass on the subcutis on the level L4-5 with size 7,5 × 3 × 7,2 cm, as shown in Figure 2. Wide excision surgery was done in Adam Malik Hospital. The extraction tumor (8,5 × 8,2 cm) involves the dermis and subcutis. Histopathological studies showed neoplastic pleomorphic nuclei with considerable pleomorphism. Bizarre multinucleated giant cells with abundant eosinophilic cytoplasm were also presented and referred to pleomorphic rhabdomyosarcoma, as shown in Figure 3. Immunohistochemical studies such

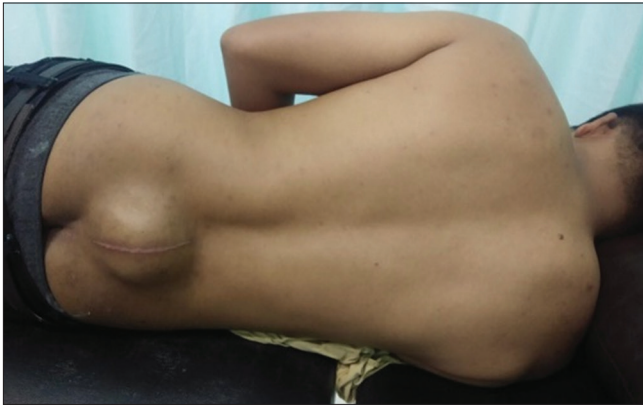

Figure 1: Lump on the back as big as tennis ball

as MyoD1, Desmin, and Vimentin were needed. The sample has intensity for vimentin. The patient was discharge 3 days after operation and follow-up with radiation therapy. The procedure was performed for 1 month, with 30 times sessions of radiation therapy, with 2 Gy doses for each session. After 1.5 years of control, from physical examination, laboratory, and radiographic examination were normal and there was not any sign of recurrences.

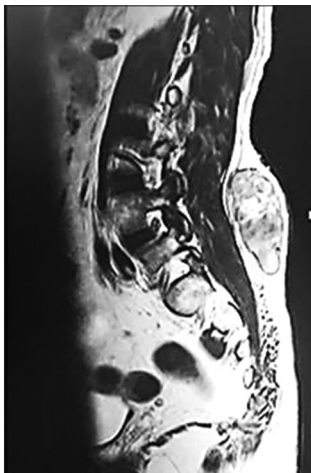


Figure 2: Lumbar MRI shows solid mass on L4–L5

## Discussion

Rhabdomyosarcoma (RMS) is a malignant mesenchymal tumor with skeletal muscle differentiation, typically observed at young age [2]. PRMS is very rare and occurring 40% in the head and neck, in the genitourinary tract, or in the deep soft tissues of the extremities, almost exclusively in a male patient older than 45 years [3]. The most common location is the chest wall, RMS arising from the paraspinal area only comprises 3.3% of all cases [4].

PRMS is composed of large, atypical, spindle-shaped, or polygonal pleomorphic rhabdomyoblasts with eccentric nuclei and abundant eosinophilic

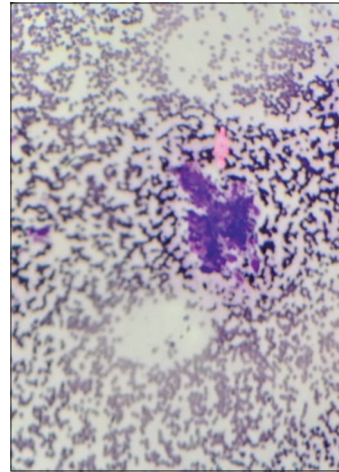


Figure 3: Pleomorphic rhabdomyosarcome on histopathologic examination

cytoplasm. Some other tumor cells have a high nucleocytoplasmic ratio and prominent nucleoli [4]. Based on histopathological findings of both initial incisional biopsy and surgical specimen, differential diagnoses included desmoplastic melanoma and other pleomorphic sarcomas such as undifferentiated pleomorphic sarcoma, epithelioid sarcoma, pleomorphic leiomyosarcoma, and cutaneous angiosarcoma. Undifferentiated pleomorphic sarcoma has highly pleomorphic spindle and epithelioid cells with a small number of multinucleated cells, which are immunohistochemically positive for vimentin, CD68 and lysozyme, and negative for CD34 and desmin [1].

The Intergroup Rhabdomyosarcoma Studies defined the treatment protocols for rhabdomyosarcoma in children and led to dramatically improved survival rates, up to more than 70% for all patients and over 85% for those with non-metastatic disease. This is largely achieved by a high chemotherapeutic response, it is less effective if applied to adults. Retrospective series report a 5-year overall survival as low as 31%–44% for adult patients, even with the use of combined therapy. As a result, some experts regard childhood and adult rhabdomyosarcomas as in need of specialized treatments [3].

It is difficult to determine the optimal treatment in adults and large studies use a variety of chemotherapeutic agents in their series [3]. Rhabdomyosarcoma tends to be more aggressive and more resistant to chemotherapy, the current guidelines for adult rhabdomyosarcoma are nonetheless based on the variety approach conceived by the Intergroup Rhabdomyosarcoma Studies.

This approach includes wide resection for the primary tumor, radiation therapy and multi-agent chemotherapy for microscopic or residual tumor. Aggressive treatment carries its own risks, and immediate complications along with surgery, radiation therapy, and chemotherapy, long-term survivors can suffer from complications of the treatment [5].

There was not any metastases after full examination of the patient. Combination therapy was given, wide resection of tumor and adequate radiation therapy procedure. 2 Gy dose therapy for 30 sessions in 6 months, the total dose was 50–60 Gy. Complete 6 months follow-up was done for every radiation therapy. 1.5 years later, there was not any sign of metastases from the patient. The prognostic of this case is excellent with no sign of metastase [5].

## References

1. Fletcher CD, World Health Organization. WHO Classification of Tumours of Soft Tissue and Bone. Amsterdam: Amsterdam University Press; 2013.
2. Ruiz MC, Goldberg JM, Coronado MA, Dumont SN, Trent JC. Rhabdomyosarcoma in adults: New perspectives on therapy. *Curr Treat Options Oncol.* 2015;16(6):27. <https://doi.org/10.1007/s11864-015-0342-8>  
PMid:25975442
3. Sultan I, Qaddoumi I, Yaser S, Galindo CR, Ferrari A. Comparing adult and pediatric rhabdomyosarcoma in the surveillance, epidemiology, and end results program 1973 to 2005: An analysis of 2,600 patients. *J Clin Oncol.* 2009;27:3391-7. <https://doi.org/10.1200/JCO.2008.19.7483>  
PMid:19398574
4. Parham DM, Ellison DA. Rhabdomyosarcomas in adults and children: An update. *Arch Pathol Lab Med.* 2006;130:1454-65. <https://doi.org/10.5858/2006-130-1454-RIAACA>  
PMid:17090187
5. Watanabe M, Ansai SI, Iwakiri I, Fukumoto T, Murakami M. Case of pleomorphic rhabdomyosarcoma arising on sub cutaneous tissue in an adult patient: Review of the published works of 13 cases arising on cutaneous or subcutaneous tissue. *J Dermatol* 2016;44(1):59-63. <https://doi.org/10.1111/1346-8138.13549>  
PMid:27569112