



# Identification of *NPHS1* Genetic Variations in Cohort of Egyptian Patients with Congenital Nephrotic Syndrome

Amira Samy<sup>1\*</sup> , Rasha Elkaffas<sup>1</sup> , F. Fadel<sup>2</sup>, Nehad Mosaad<sup>1</sup> , Hanan Madani<sup>1</sup>

<sup>1</sup>Department of Clinical and Chemical Pathology, Faculty of Medicine, Cairo University, Giza, Egypt; <sup>2</sup>Department of Pediatrics, Faculty of Medicine, Cairo University, Giza, Egypt

## Abstract

**Edited by:** Slavica Hristomanova-Mitkovska  
**Citation:** Samy A, Elkaffas R, Fadel F, Mosaad N, Madani H. Identification of *NPHS1* Genetic Variations in Cohort of Egyptian Patients with Congenital Nephrotic Syndrome. Open Access Maced J Med Sci. 2022 Jan 14; 10(A):84-89. https://doi.org/10.3889/oamjms.2022.8214  
**Keywords:** Congenital nephrotic disease; *NPHS1*; Nephrin; Molecular findings; Diagnosis  
**\*Correspondence:** Amira Samy, Department of Clinical and Chemical Pathology, Faculty of Medicine, Cairo University, Giza, Egypt. E-mail: dr\_amira\_samy@yahoo.com  
**Received:** 09-Dec-2021  
**Revised:** 12-Dec-2021  
**Accepted:** 04-Jan-2022  
**Copyright:** © 2022 Amira Samy, Rasha Elkaffas, F. Fadel, Nehad Mosaad, Hanan Madani  
**Funding:** This research did not receive any financial support  
**Competing Interest:** The authors have declared that no competing interest exists  
**Open Access:** This is an open-access article distributed under the terms of the Creative Commons Attribution-NonCommercial 4.0 International License (CC BY-NC 4.0)

**BACKGROUND:** Autosomal recessive variations in *NPHS1* gene represent common cause of congenital nephrotic syndrome (CNS). The disease is characterized by considerable proteinuria presenting in the first 90 days of life. CNS has a poor outcome and usually leads to end stage renal disease by 2–3 years of life. *NPHS1* encodes the protein nephrin, expressed in interpodocyte slit diaphragm.

**AIM:** The main objective of this cross-sectional study was to perform the analysis of the *NPHS1* gene in 24 Egyptian patients with CNS aiming to determine the molecular cause of the disease and to detect their phenotype/genotype correlations.

**MATERIALS AND METHODS:** Polymerase chain reaction followed by direct sequencing of exons (3, 4, 6, 7, 18, and 19) of *NPHS1* gene was performed in 24 neonates with CNS with a median age of 25 days (1–90 days).

**RESULTS:** Three pathogenic variants were detected in five patients. They were one frame shift variant in exon 19, one missense *de novo* variant in exon 6, and one in-frame deletion variant in exon 4. Three benign variants were seen in seven patients in exon and intron 3.

**CONCLUSION:** Although the number of patient included in the study is small, the results of the study presented *de novo* likely pathogenic mutation in exon 6 not reported before in two patients and two reported pathogenic variants. Molecular diagnosis is advised to be performed early in the diagnosis of CNS to avoid unnecessary immune suppression and start early suitable treatment.

## Introduction

Congenital nephrotic syndrome (CNS) manifests within the first 90 days of life. CNS is a rare inherited defect in glomerular filtration encompassing many gene variations [1]. CNS has a bad prognosis and usually leads to end-stage renal disease (ESRD) by 2–3 years of life. The most common type of CNS is the Finnish type, with known mutations and early genetic presentation, and typically has a severe phenotype clinically presenting by intra-uterine growth retardation, polyhydramnios, massive *in utero* proteinuria, a large placenta, albuminuria, hypoalbuminemia, severe edema in the first few days of life, and rapid progression to ESRD [2]. The majority of *NPHS1* mutations are autosomal recessive mutations; when both parents are carriers of CNS. It's not always possible to identify a gene mutation in CNS, as there are other non-genetic causes. These include infections such as cytomegalovirus infection, congenital syphilis, and congenital toxoplasmosis [3]. However, Sadowski *et al.* [4] suggested that 75% of CNS patients can be explained by monogenic mutations.

More than 80% of CNS cases are caused by four known mutations [5]. The most common is *NPHS1* (nephrin) gene mutation which is characteristic of the Finnish type of nephrosis, typically seen in people of Finnish ancestry, but may be present in non-Finnish individuals. Less common mutations are *WT1*, *NPHS2*, and *LAMB2* gene mutations [1]. CNS is a severe disease, it has a very high rate of morbidity and mortality, and aggressive treatment is aiming to save patient's kidney and patient's life too. Screening for *NPHS1* gene variations supports definitive diagnosis; it is superior to histopathology and less invasive. Patients who have pathogenic *NPHS1* variations are resistant to steroids, so they should be spared exposure to side effects of immunosuppression. Furthermore, those patients carry a very low risk of recurrence so they are encouraged to plan for renal transplantation as it is the only curative treatment for this condition. Molecular analysis is also needed for accurate genetic counseling and family planning [6].

This study aimed to determine the *NPHS1* gene variations as a genetic cause of CNS and to detect their phenotype/genotype correlations.

## Patients and Methods

This is a cross-sectional retrospective study that was conducted in the period from April 2018 to February 2020 on 24 patients presenting to nephrology and renal transplantation pediatric unit at Cairo University Children Hospital. The study was performed in the molecular biology unit of the Chemical Pathology Department-Faculty of Medicine-Cairo University. The patients were diagnosed as CNS on basis of presence of the triad of nephrotic range proteinuria ( $>40$  mg/m<sup>2</sup>/h), low serum albumin ( $<2.5$  g/dL), and edema [6]. Inclusion criteria included: Both sexes, patient age at onset of the disease: 0–3 months with diagnosis of CNS with steroid resistance which is defined by absent remission after 6–8 weeks of daily steroid therapy (prednisone 2 mg/kg/day). Exclusion criteria included; patients with nephrotic syndrome presenting after the age of 3 months, patients in remission (who respond to steroid therapy), secondary nephrotic syndrome (secondary to congenital infections such as syphilis, toxoplasmosis, cytomegalovirus, HIV, or hepatitis), and patients with known genetic mutations (already screened). All patients were subjected to detailed history taking and meticulous clinical examination. Laboratory investigations: Routine laboratory tests including: CBC, renal functions (urea, creatinine, albumin, albumin/creatinine ratio, glomerular filtration rate, and urine analysis), liver functions (alanine transaminase and aspartate transaminase), cholesterol, and thyroid profile were collected from patients' files. Renal biopsy showing focal segmental glomerulosclerosis (FSGS) or diffuse pathology was collected from patient's files. Genetic analysis: DNA extraction was done using QIAamp DNA Blood Mini kit (Qiagen, Valencia, CA). Amplification of coding regions as well as flanking intronic regions of exons 3 and 4, 6 and 7, and 18 and 19 of the *NPHS1* gene (NM\_004646.3) was done with primers according to the protocol proposed by Lenkerri *et al.* [7] then sequenced by Sanger sequencing which was done on Applied Biosystems 3500 Genetic Analyzer [8]. Analysis was done by Basic Local Alignment Search Tool ([www.ncbi.nlm.nih.gov](http://www.ncbi.nlm.nih.gov)). The nomenclature was according to Human Genome Variation Society [9]. For predicting the damaging effect of novel missense variants, *in silico* prediction tools were used as SIFT, PolyPhen-2, and Mutation Taster. Pathogenicity classification was done according to the American College of Medical Genetics and Genomics guidelines [10]. The study was approved by the Local Ethical Committee after informed verbal consents were obtained from parents of all patients.

### Statistical analysis

Data were analyzed using IBM SPSS advanced statistics version 19.0 (SPSS Inc., Chicago, IL). Quantitative data were expressed as mean  $\pm$  SD when

normally distributed and as median and range when not normally distributed. Qualitative data were represented as frequency and percentage.  $p < 0.05$  is considered statistically significant.

## Results

This cross-sectional study included 14 males (58.4%) and 10 females (41.6%). The demographic and clinical characteristics of the studied group are presented in Table 1. Positive consanguinity was represented in 46% of patients. Four pathogenic variants were found in 5 patients (20.8% of study population), as shown in Table 2.

**Table 1: Demographic and phenotypic data of the studied congenital nephrotic syndrome group**

| Parameter                                     | Study group (%)    |
|---|--------------------|
| Age of onset (days)                           | 25 (1–90)*         |
| Gender: Males                                 | 14 (58.4)          |
| Females                                       | 10 (41.6)          |
| Presentation: Facial edema                    | 13                 |
| Scrotal edema                                 | 13                 |
| Generalized                                   | 74                 |
| Albumin (g/dl)                                | 1.7 (0.7–3.5)*     |
| BUN (mg/dl)                                   | 77 (12–450)*       |
| Creatinine (mg/dl)                            | 1.38 (0.2–5.4)*    |
| ALT (U/L)                                     | 16.5 (10–58)*      |
| AST (U/L)                                     | 34.5 (17–88)*      |
| CHOL (mg/dl)                                  | 260 (165–479)*     |
| EGFR (ml/min)                                 | 10.4 $\pm$ 3.4**   |
| A/C ratio (g/mg)                              | 1 $\pm$ 0.1**      |
| Free T4 pg/ml                                 | 0.4 $\pm$ 0.1**    |
| Complication: ESRD                            | 10 patients (41.7) |
| Death   | 4 patients (16.7)  |
| Consanguinity: Positive                       | 11 patient (46)    |
| Negative                                      | 13 patients (54)   |
| Family history of sibling death               | 8 cases (33.3)     |
| Treatment modality Renal transplantation      | 1 Patient (4.2)    |
| Regular dialysis                              | 6 Patients (25)    |
| Renal support therapy                         | 17 Patients (70.8) |
| Renal biopsy (available for 21 patients only) |                    |
| Focal segmental glomerulosclerosis            | 18 (75)            |
| Diffuse mesangial sclerosis                   | 3 (12.5)           |

Data are expressed as \*median (range) and \*\*mean  $\pm$  standard deviation (SD). Qualitative data expressed as frequency and percentage. BUN: Blood urea nitrogen, AST: Aspartate transaminase, ALT: Alanine transaminase, ESRD: End-stage renal disease.

The first two cases with pathogenic variant Del C rs386833918 in exon 19 were born to consanguineous parents. Renal biopsy showed FSGS pattern for both of them. The elder one was a 3-year-old male child who was presented for the 1<sup>st</sup> time at the age of 4 days old with generalized edema, and he deteriorated until he lost kidney functions and progressed to ESRD by the end of his 1<sup>st</sup> year. He is candidate for renal transplantation and receives renal supportive treatment besides dialysis. The younger brother was 12 months, he presented with generalized edema at the age of 30 days and received regular albumin infusions and in a relatively better general condition.

Patients 3 and 4 had pathogenic variant G>Crs961890817 in exon 6. Patient number 3 was a 2-year-old female child who presented at the day 27 after birth by puffiness of face, with no family history and no consanguinity. Her renal biopsy showed FSGS

**Table 2: The *NPHS1* pathogenic variants identified in the study group and phenotype-genotype correlations**

| Patient No. | Gender | Current Age | Onset   | Variant coordinate  | Zygosity       | Exon/Intron | Variant Type         | Pathogenicity of the variant | Evidences                 | Extra renal manifestations |
|-------------|--------|-------------|---------|---|----------------|-------------|----------------------|------------------------------|---------------------------|----------------------------|
| 1           | Male   | 36 m        | 4 days  | DelC rs386833918  | Homo           | 19          | Frameshift           | Pathogenic                   | PVS1, PM1, PM2.           |                            |
| 2           | Male   | 12 m        | 30 days | NG_013356.2:g.32016delC<br>NM_004646.3:c.2515delC,<br>NP_004637.1:p.Gln839Arg<br>They are 2 siblings              | zygous         |             |                      |                              |                           |                            |
| 3           | Female | 24 m        | 27 days | C>G rs961890817   | Homo           | 6           | Missense             | Likely-Pathogenic            | PM1, PM2, PM3,<br>PP3.    |                            |
| 4           | Female | 48 m        | 2 days  | NG_013356.2:g.24654G>A<br>NM_004646.3:c.628G>T<br>NP_004637.1:p.Asp210His   | zygous         |             | Variant              |                              |                           |                            |
| 5           | Female | 60 m        | 2 days  | delCCA rs386833947<br>NG_051206.1:g.<br>4336_4338delTGG<br>NM_004646.3:c.515_517delCCA<br>NP_004637.1:p.Thr172del | Homo<br>zygous | 4           | In-frame<br>Deletion | Likely-Pathogenic            | PM1PM2PM4PP4,<br>PP5, BP4 |                            |

and she was relatively in a good general condition. Patient number 4 was a 4-year-old girl with a history of sibling death and positive consanguinity, presented at day 6 of life with edema. Her renal biopsy showed FSGS. She was hypertensive and progressed to ESRD at the age of 2 years old.

The last pathogenic variant detected was delCCArS386833947 in exon 4. It was detected in a 5-year-old female child of positive consanguinity and positive family history. She was presented with abdominal edema on the 2<sup>nd</sup> day of life, she received regular albumin infusions and renal supportive treatment. Her renal biopsy shows DMS.

Three benign variants were detected in five patients, as shown in Table 3. Benign variant rs2285450 in exon 3 was represented in patients 6 and 7. Patient number 6 was a 9-month-old boy who presented in the 1<sup>st</sup> time at the age of 40 days with scrotal edema and received albumin infusion. Renal biopsy showed DMS and renal supportive treatment started. While patient number 7 was a 2-year-old male child who presented at the end of the 3<sup>rd</sup> week of life (20 days) with puffiness of face, which later become generalized edema, and his kidney functions deteriorated rapidly until diagnosed as ESRD at age of 6 months. His renal biopsy showed FSGS. He was on regular hemodialysis and candidate for renal transplantation.

The second benign variant A>G rs412175 was detected in four patients; patients number 5, 6, 7, and 8 who was a female child of 6 years old, with

positive consanguinity, presented at the age of 40 days with edema and ascites. She was on regular albumin infusions. Her renal biopsy shows FSGS.

G>A rs3814995 is the last benign variant detected in our study. It was detected in a 1 month old baby girl who was admitted to neonatal intensive care unit at the age of 8 days due to anuria since birth, with positive consanguinity and no family history.

## Discussion

This study included 24 children who were diagnosed as CNS in the first 90 days of life according to the presence of the triad of massive proteinuria, low serum albumin, and edema [1]. In this study, a number of pathogenic, benign and likely benign variants were detected.

Three pathogenic variants were identified in five patients in this study. They were one frame shift deletion DelC rs386833918 in exon 19, one missense variants C>G rs961890817 in exon 6, and one in-frame deletion delCCA rs386833947 variant in exon 4. Of these five patients, three patients had a family history of sibling death and two of them were of consanguineous marriage.

The first pathogenic frameshift variant found in our study is homozygous c.2515delC (p.Gln839Argfs)

**Table 3: The *NPHS1* benign variants identified in the study group and phenotype-genotype correlations**

| Patient No. | Gender | Current age (months) | Onset (days) | Variant coordinate   | Zygosity       | Exon/intron | Variant type        | Pathogenicity of the variant | Evidences          |
|-------------|--------|----------------------|--------------|--|----------------|-------------|---------------------|------------------------------|--------------------|
| 6           | Male   | 9 m                  | 40 days      | A>G rs2285450  | Hetero         | 3           | Synonymous          | Benign                       | PM1, BA1, BP6, BP7 |
| 7           | Male   | 24 m                 | 20 days,     | NG_013356.2:g.<br>22923C>T<br>NM_004646.3:c.294C>T<br>NP_004637.1:p.Ile98=                         | zygous         |             | variant             |                              |                    |
| 5           | Female | 60                   | 2            | A>G rs412175   | Homo           | 3           | Intron variant      | Benign                       | BA1, BP4           |
| 6           | Male   | 9                    | 40           | NG_013356.2:g.   | zygous         |             |                     |                              |                    |
| 7           | Male   | 24                   | 20           | 23087A>G   |                |             |                     |                              |                    |
| 8           | Male   | 72                   | 40           |  |                |             |                     |                              |                    |
| 9           | Female | 1 m                  | 8 days       | G>A rs3814995<br>NG_013356.2:g.<br>22978G>A<br>NM_004646.3:c.349G>A<br>NP_004637.1:p.<br>Glu117Lys | Homo<br>zygous | 3           | Missense<br>variant | Likely-Benign                | PM1, PM2, PP3, PP4 |

which was identified on exon 19 in two siblings from one family. The variant was previously reported as rs386833918 in a study by Aya *et al.* [11] done on five Japanese patients where the variant was detected as a heterogeneous single-nucleotide deletion in three out of the five patients. In Aya *et al.* study, the three affected patients showed compound heterozygosity for this variant. It's known that compound heterozygosity of pathogenic variants is the most observed mode of inheritance in patients with rare recessive diseases if the parents are non-consanguineous [12].

In our study, the variant was homozygously inherited from consanguineous parents. In concordance with the Japanese study, onset of the disease for this variant was in the 1<sup>st</sup> month of age, its prognosis varied between ESRD (one patient in our cohort and three patients in the Japanese cohort) and death from infections (sepsis case in our cohort and pneumonia case in the Japanese cohort).

This variant was also reported in a functional study by Miyai *et al.*, using Western blot with anti-nephrin antibody. It was reported that the "wild-type" nephrin showed bands around 185 kD, while the truncated mutants carrying this variant had molecular weight of around 120 kD. They also reported that these truncated proteins had defects of trafficking into the cell surface [13]. This variation is an indel leading to a frame shift. The coding impact of such variations leads to the gain of a premature stop codon. The addition of an unwanted stop codon cuts ribosomal protein synthesis resulting in fragmented incomplete poly peptide chains.

The second pathogenic missense variant rs961890817 p.Asp210His was homozygous variant found on exon 6 in two patients from consanguineous marriage. No publications were found regarding this variant, *in silico* tools were used to classify the variant as likely pathogenic. The main barrier to determine the pathogenicity of this variant is absence or limited functional testing that highlights dysfunction of the encoded protein. In view of the clinical findings and biopsy features in both patients, it is obvious that this culprit variant may be causative of the disease development in these two children. However, due to lack of segregation data of alleles and absence of functional study, we could not classify this variant as pathogenic. It was instead classified as likely pathogenic.

The third likely pathogenic in-frame deletion variant rs386833947 c.515delACC (p.Thr 172del) was found on exon 4 in one patient of consanguineous parents with renal biopsy result showed DMS. This variant was studied by Schoeib *et al.* who found biallelic mutations in 36 of 62 families (58%) supporting the data that nearly one-half of CNS is caused by *NPHS1* mutations. His cohort represented 21 different ethnicities; the largest groups were of Arabic (15%) and Turkish (15%), then European (13%) and 9% of Caucasian race. One Arab patient was homozygous for the variant c.515delACC (p.Thr 172del), his biopsy showed FSGS of Finnish type

[14]. This pathogenic variant was also reported by Santin *et al.* in a Spanish cohort including 15 CNS patients with median age of onset 30 days [15].

Furthermore, the variant was reported in Saudi Arabia by Al-Hamed *et al.* who studied 62 Saudi families and found *NPHS1* variations in six patients of them (12%), including two unrelated patients with the same homozygous variant c.515\_517del CCA. One patient had a heterozygous *NPHS2* variant combined with this *NPHS1* variant. Both patients were consanguineous of first cousin marriage [16].

In this study, we detected one missense variant G>A rs3814995 p. Glu117Lys at exon 3 in homozygous pattern in one patient and according to *in silico* tools, it were used to be classified as likely benign variant. It was reported before by Lenkerri *et al.*, 1999, who reported that this was found as a homozygous change in five control subjects and is, therefore, most likely a common polymorphism. Furthermore, Nguyen *et al.*, 2017, reported this variant in three Vietnam patients [17].

Furthermore, in this study, we detected a benign variant A>G rs412175 in intron 3 in four patients and one synonymous variant A>G rs2285450 in two patients.

The previous studies revealed that the most mutations of *NPHS1* were observed in immunoglobulin (Ig)-2, Ig-4, and Ig-7 domains, which represent mutational "hotspots." It was also consistent with the concept that severe frame shift mutations lead to severe defect, while mild missense mutations have partial function preserved, as reported by Machuca *et al.* who found that some patients with mutations affecting the Ig-like part of intracellular domain of nephrin had a good clinical course [18]. Considering this, in our study, it would be expected that the two sibling patients who presented the frame shift at exon 19 would have experienced the worst disease progression. However, three of the patients included in the study died from sepsis, although having "milder" missense mutations, Figure 1. Therefore, association between the mutation type and the survival or prognosis was not established.

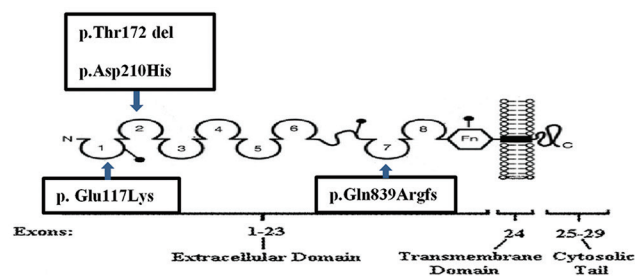


Figure 1: Localization of the detected variants in nephrin protein

Molecular diagnosis is crucial for family counseling. It may enable identification of recurrence risk in future children and potential diagnosis of pre-symptomatic individuals at risk. Genetic screening in apparently healthy family members may be of

additional importance in case of planning for a living related donor renal transplant.

The study had few limitations such as the selection of small number of patients from a single hospital. Furthermore, parental DNA was not available, segregation studies were not performed. Due to limited fund resources, we could only perform certain exons and not all 29 exons.

Based on the results of this study, we recommend that *NPHS1* gene sequencing test should be done to every patient diagnosed with nephrotic syndrome before 3 months of age, patients with known pathogenic mutations do not benefit from renal biopsy, and they should be spared the side effects of immunosuppression. Patients with pathogenic *NPHS1* mutations should follow a plan of conservative treatment and kidney transplantation from a living related donor. Genetic analysis may guide the choice of the donor as heterozygous individuals may be affected by kidney donation. Screening of *NPHS1* mutations should be done antenatal to the families with strong family history of the disease, for example, sibling death.

## Conclusion

Molecular study shows that *NPHS1* mutations are an important cause of CNS in Egypt; screening for mutations in the *NPHS1* gene aids in definitive diagnosis, which helps clinical management of such patients in addition to family counseling. It's evident that integrating the data from this study with large phenotype and genotype data may support and ascertain the role of multiple variants in disease progression, leading to variable phenotypes. Hopefully future studies will elucidate further genotype-phenotype correlations and disease mechanisms, which would pave the way for providing personalized medicine according to each patient.

## Acknowledgments

Authors are grateful to the patients who shared in the study.

## Compliance with Ethical Standards

### *Ethical approval*

All procedures performed in studies involving human participants were in accordance with the ethical

standards of the institutional and/or national research committee and with the 1964 Helsinki Declaration and its later amendments or comparable ethical standards.

### *Informed consent*

Informed consent was obtained from parents of all patients included in the study.

## Authors' Contributions

All authors have contributed to the research work all through. They all read and approved the final manuscript.

## References

1. Bérody S, Heidet L, Gribouval O, Harambat J, Niaudet P, Baudouin V, *et al.* Treatment and outcome of congenital nephrotic syndrome. *Nephrol Dial Transpl.* 2018(3):458-67. <https://doi.org/10.1093/ndt/gfy015>  
PMid:29474669
2. Sharief SN, Hefni NA, Alzahrani WA, Nazer II, Bayazeed MA, Alhasan KA, *et al.* Genetics of congenital and infantile nephrotic syndrome. *World J Pediatr.* 2019;15(2):198-203. <https://doi.org/10.1007/s12519-018-00224-0>  
PMid:30721404
3. Wang JJ, Mao JH. The etiology of congenital nephrotic syndrome: Current status and challenges. *World J Pediatr.* 2016;12(2):149-58. <https://doi.org/10.1007/s12519-016-0009-y>  
PMid:26961288
4. Sadowski CE, Lovric S, Ashraf S, Pabst WL, Gee HY, Kohl S, *et al.* A single gene cause in 29.5% of cases of steroid-resistant nephrotic syndrome. *J Am Soc Nephrol.* 2015;26(6):1279-89. <https://doi.org/10.1681/ASN.2014050489>  
PMid:25349199
5. Mann N, Braun D, Amann K, Tan W, Shril S, Connaughton DM, *et al.* Whole-exome sequencing enables a precision medicine approach for kidney transplant recipients. *J Am Soc Nephrol.* 2019;30(2):201-15. <https://doi.org/10.1681/ASN.2018060575>  
PMid:30655312
6. Ha TS. Genetics of hereditary nephrotic syndrome: A clinical review. *Korean J Pediatr.* 2017;60(3):55-63. <https://doi.org/10.3345/kjp.2017.60.3.55>  
PMid:28392820
7. Lenkerri U, Manniko M, McCreedy P, Lamerdin J, Gribouval O, Niaudet P, *et al.* Structure of the gene for congenital nephrotic syndrome of the Finnish type (*NPHS1*) and characterization of mutations. *Am J Hum Genet.* 1999;64(1):51-61. <https://doi.org/10.1086/302182>  
PMid:9915943
8. Sanger F, Nicklen S, Coulson AR. DNA sequencing with chain-terminating inhibitors. *Proc Natl Acad Sci U S A.* 1977;74(12):5463-7. <https://doi.org/10.1073/pnas.74.12.5463>  
PMid:271968

9. Dunnen JT, Antonarakis SE, Dalgeish R, Maglott DR, Hart RK, Greenblatt MS, *et al.* HGVS recommendations for the description of sequence variants: 2016 update. *Hum Mutat.* 2016;37(6):564-9. <https://doi.org/10.1002/humu.22981>  
PMid:26931183
10. Richards S, Aziz N, Bale S, Bick D, Das S, Gastier-Foster J, *et al.* Standards and guidelines for the interpretation of sequence variants: A joint consensus recommendation of the American college of medical genetics and genomics and the association for molecular pathology. *Genet Med.* 2015;17(5):405-24. <https://doi.org/10.1038/gim.2015.30>  
PMid:25741868
11. Aya K, Shimizu J, Ohtomo Y, Satomura K, Suzuki H, Yan K, *et al.* *NPHS1* gene mutation in Japanese patients with congenital nephrotic syndrome. *Nephrol Dial Transplant.* 2009;24(8):2411-4. <https://doi.org/10.1093/ndt/gfp122>  
PMid:19321760
12. Kamphans T, Sabri P, Zhu N, Heinrich V, Mundlos S, Robinson PN, *et al.* Filtering for compound heterozygous sequence variants in non-consanguineous pedigrees. *PLoS One.* 2013;8(8):e70151. <https://doi.org/10.1371/journal.pone.0070151>  
PMid:23940540
13. Miyai T, Aya K, Takaiwa M. Functional analysis of *NPHS1* mutations in Japanese patients. *Histol Histopathol.* 2014;29(2):279-84. <https://doi.org/10.14670/HH-29.279>  
PMid:24142548
14. Schoeb DS, Chernin G, Heeringa SF, Matejas V, Held S, Vega-Warner V, *et al.* Nineteen novel *NPHS1* mutations in a worldwide cohort of patients with congenital nephrotic syndrome (CNS). *Nephrol Dial Transplant.* 2010;25(9):2970-6. <https://doi.org/10.1093/ndt/gfq088>  
PMid:20172850
15. Santin S, Bullich G, Tazon-Vega B, García-Maset R, Giménez I, Silva I, *et al.* Clinical utility of genetic testing in children and adults with steroid-resistant nephrotic syndrome. *Clin J Am Soc Nephrol.* 2011;6(5):1139-48. <https://doi.org/10.2215/CJN.05260610>  
PMid:21415313
16. Al-Hamed M, Al-Sabban E, Al-Mojalli H, Al-Harbi N, Faqeih E, Al Shaya H, *et al.* A molecular genetic analysis of childhood nephrotic syndrome in a cohort of Saudi Arabian families. *J Hum Genet.* 2013;58(7):480-9. <https://doi.org/10.1038/jhg.2013.27>  
PMid:23595123
17. Nguyen TK, Pham VD, Nguyen TH, Pham TK, Nguyen TQ, Nguyen HH. Three novel mutations in the *NPHS1* gene in Vietnamese patients with congenital nephrotic syndrome. *Case Rep Genet* 2017;2017:2357282. <https://doi.org/10.1155/2017/2357282>  
PMid:28392951
18. Machuca E, Benoit G, Nevo F, Tête MJ, Gribouval O, Pawtowski A, *et al.* Genotype-phenotype correlations in non-Finnish congenital nephrotic syndrome. *J Am Soc Nephrol.* 2010;21(7):1209-17.