



Management of Nasal Bone Osteoma with Columella Approach: A Case Report

Al Hafiz^{1*}, Yunita Wulandari¹, Aswiyanti Asri²

¹Department of Otorhinolaryngology Head and Neck Surgery, Faculty of Medicine, Andalas University, Dr. M. Djamil Hospital, Padang, Indonesia; ²Department of Anatomic Pathology, Faculty of Medicine, Andalas University, Dr. M. Djamil Hospital, Padang, Indonesia

Abstract

Edited by: Ksenija Bogoeva-Kostovska
Citation: Al Hafiz, Wulandari Y, Asri A. Management of Nasal Bone Osteoma with Columella Approach: A Case Report. Open Access Maced J Med Sci. 2022 Nov 26; 10(C):306-311.
<https://doi.org/10.3889/oamjms.2022.8368>
Keywords: Osteoma; Osteoma nasal bone; Tumor resection
***Correspondence:** Al Hafiz, Department of Otorhinolaryngology Head and Neck Surgery, Faculty of Medicine Andalas University, Dr. M. Djamil Hospital, Padang. E-mail: alhafiz@med.unand.ac.id;
Received: 22-Dec-2021
Revised: 12-Nov-2022
Accepted: 16-Nov-2022
Copyright: © 2022 Al Hafiz, Yunita Wulandari, Aswiyanti Asri
Funding: This research did not receive any financial support
Competing Interests: The authors have declared that no competing interests exist
Open Access: This is an open-access article distributed under the terms of the Creative Commons Attribution-NonCommercial 4.0 International License (CC BY-NC 4.0)

BACKGROUND: Osteoma is a benign bone tumor with an incidence rate of about 1% of primary bone tumors. Osteoma of the nasal bone is a rare case and the rate of recurrence reported in the literature after surgery is about 10%. Osteoma most often occurs in young people in the second and third decades, mostly in men. Osteoma can be treated surgically with an external approach or with an endoscopic approach. The surgical technique with an incision technique open rhinoplasty with transcolumella incision extensions is effective, because it can minimize surgical scars post-operative and correct the esthetic problems.

CASE REPORT: Reported a case of a 11-year-old boy with chief complaint a lump on the right side of the nose that enlarged slowly in the last 2 months and diagnosed with suspected as nasal bone osteoma based on physical examination and CT Scan. Patient was performed management with tumor resection with columella approach technique and give the good result because can minimize surgical scars postoperative. On the results of histopathological examination after operation were nasal bone osteoma.

CONCLUSION: Osteoma of the nasal bone is a very rare benign bone tumor. One of the surgical techniques that can be performed in cases of nasal bone osteoma is tumor resection with columella approach. Although the case of nasal bone osteoma has a very rare recurrence; in this case, the recurrence occurred 4 months after tumor resection.

Introduction

Osteoma is a benign bone tumor with an incidence rate of about 1% of primary bone tumors. Osteoma is a benign bone tumor that is most often found in the paranasal sinuses, usually found in the frontal sinus and rarely in the ethmoid sinus [1]. Osteoma can also be found in the craniofacial area, which is often in the maxilla and mandible, where osteoma on the nasal bone is a rare case [2].

Osteoma can be divided into three types: Central osteoma, peripheral osteoma, and extraskeletal osteoma. Peripheral osteoma occurs in the periosteum and its etiology is still unclear. Neoplasia, the mechanism of reaction of the hamartoma, trauma, or infection can be considered as the etiologic of this osteoma. Osteoma of the nasal bone is categorized as peripheral osteoma [2]. In the case of asymptomatic osteoma, It may not require surgery intervention [3].

Surgical resection of the tumor is performed in symptomatic cases. Osteoma of the nasal bone with a

large diameter can cause cosmetic problems and complete surgical resection of the tumor has been reported to be successful [3]. There is no standard surgical procedure in cases of osteoma that occurs in the nasal bone, because it is a rare case. Surgery can be divided into external approach, endoscopy approach, or a combination of both [4]. However, excision of the tumor can be done through excision or direct incision right on the tumor lesion or using the incision technique columella approach [2].

Case Report

A boy, 11 years old, came to the ENT-HNS outpatient clinic, Facial Plastic and Reconstructive Surgery subdivision, Dr. M. Djamil Hospital Padang on January 28, 2021 with chief complaints of lumps on the right side of the nose that getting bigger since 2 months ago (Figure 1). Previously, the lump had been complained of since 3 months ago, it appeared like a

pimple, but the lump was not painful and the lump had been getting bigger since the past 2 months.

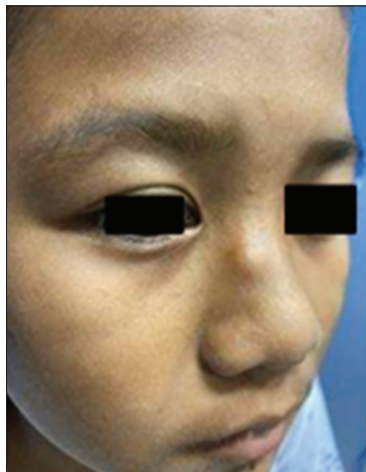

Figure 1: Picture of patient before surgery

There were no nasal congestion, runny nose or blood came out from the nose. There was no history of discharge or blood from the nose. There was no decreased sense of smell. There were no epiphora, decreased vision, double vision, and protrusion of the eye. There was no numbness in the nose or face, and headache. There was no history of trauma to the face and nose. There were no lumps in other body parts. There was no history of family malignancy.

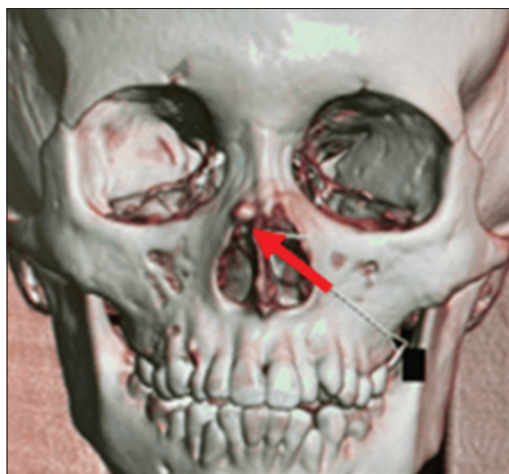


Figure 2: CT scan of paranasal sinuses and CT scan 3D

On physical examination, the general condition was good with vital signs within normal limits and the patient's weight was 47 kg. Based on ENT examinations, the nose, there was a mass on the right lateral nasal dorsum with a size of 10 × 10 × 5 mm, with hard palpation, fixed, flat surface, not hyperemic, and no tenderness. On nasoendoscopy, ear and throat examination revealed no abnormalities.

Peak nasal inspiratory flow was examined and the final result was 110. The result of laboratory findings was in normal limits. CT scan of paranasal sinuses and (Figure 2) CT scan 3D was performed with result nasal bone osteoma.

Based on anamnesis, physical examination and CT scan examination, the patient diagnosed with

tumor et nasal region and nasal bone osteoma as a differential diagnosis. The patient was planned to undergo tumor resection with a columella approach under general anesthesia.

On February 8, 2021, a tumor resection operation using the columella approach technique was performed on the patient. The operation begins with the patient lying supine on the operating table under general anesthesia. Asepsis and antisepsis were performed in the operating field. Nasal tampons were placed on the right and left nasal cavities with lidocaine: Epinephrine (4:1) and waited for 10 min. Then, the tampon was removed and evaluated on the right and left nasal cavities (Figure 3). Performed infiltration with 1:200,000 epinephrine solution in the supratochlear, angular and bilateral nasolabial areas before incision.

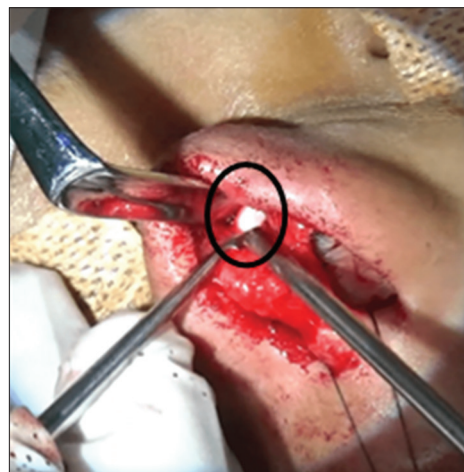


Figure 3: Durante operation, bone-like tumor mass appeared on the right lateral nasal bone

Followed by a "V-inverted" incision in the columella, the tissue was freed followed by undermining until a bone-like tumor mass appeared on the right lateral nasal bone. The tumor was chiseled to detach, followed by curettage at the base of the attached tumor until no residual tumor was seen in the nasal bone. The incision wound was then sutured using vicryl 4.0 suture and continued with prolene 5.0 suture, bleeding was evaluated. Operation was finished (Figure 4).

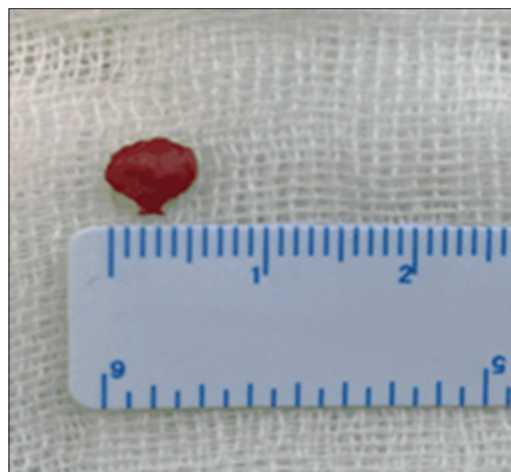


Figure 4: The resected tumor, 6 × 5 × 2 mm in size

Histopathological examination of the tumor tissue was performed. The patient was diagnosed with post resection of the nasal bone tumor with the columella approach with a differential diagnosis of nasal bone osteoma. The patient was given therapy of ceftriaxone injection 2 × 1 gram (IV) and paracetamol 3 × 500 mg (orally).

On February 16, 2021, a week postoperatively, there was no complaints, the surgical wound was good, and the suture was released. Patients bring the results of histopathologic examination of tissue sections that appear to contain proliferation trabecular bones containing osteocytes and capillaries, connective tissue capsule appeared also on the outside with the conclusions microscopic appearance according to osteoma (Figures 5 and 6).

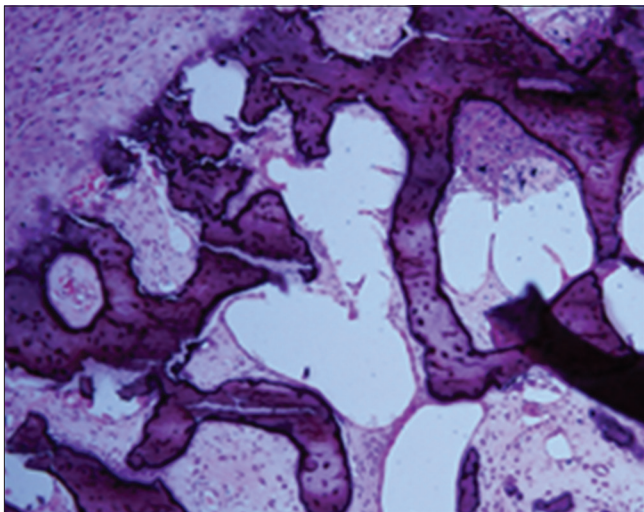


Figure 5: Histopathology of osteoma

On June 17, 2021, 4 months after surgery, the patient complained of a lump in the nose reappearing (Figure 7) since 2 months ago after surgery. Lumps appear in the same place, no pain, there was no nasal congestion, discharge or blood came out from the nose. There was no history of discharge or blood came out from the nose.

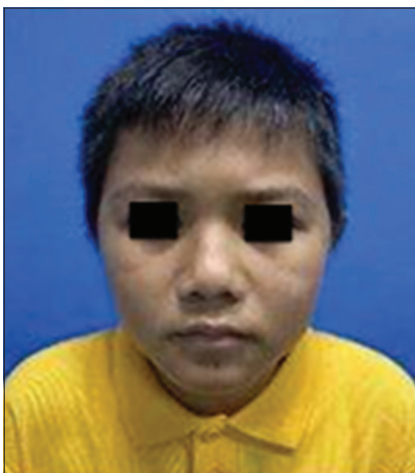

Figure 6: Picture of patient a week after surgery

There was no decreased sense of smell. There were no epiphora, decreased vision, double vision, and

protrusion of the eye. There was no numbness in the nose or face, and headache. There was no history of trauma to the face and nose.

On physical examination, general condition was good with vital signs within normal limits. Based on ENT examination, the nose, there was a mass on the right lateral nasal dorsum with a size of 15 × 10 × 5 mm, with hard palpation, fixed, flat surface, not hyperemic, and no tenderness.

On June 25, 2021, a re-examination of paranasal sinus CT scan and 3D reconstruction CT scan was performed on the patient and the results were nasal bone osteoma and maxillary sinus retention cyst with a differential diagnosis of mucocele (Figure 8). The patient was planned for resection of the tumor and the patient was consult to the rhinology subdivision for further management of retention cysts.

Discussion

Osteoma is a benign tumor that grows slowly, which often develops in the craniofacial area. Osteoma of the nose is reported to be very rare [2]. Where based on the literature reported in 2013–2020, there were four cases of nasal bone osteoma [5]. The most common cases of osteoma are located in the mandible followed by the paranasal sinuses such as the frontal sinus, maxillary sinus ethmoid sinus, and also rarely in the nasal cavity or in the conchae [3], [5]. Reported incidence rates of frontal sinus osteoma by 52%, 22% ethmoid sinus, the maxillary sinus 5.1%, and sphenoid sinus 1.7% [6].

The incidence of osteoma is more common in men than women [3], it was reported that the highest prevalence occurred in the 3rd decade and 4th decade, with a male-to-female ratio of 1.5–3.1:1 [7]. While in other literature, it is said that the prevalence of osteoma occurs at the age of the 2nd decade and 3rd decade of life [8]. The etiology of osteoma is still unclear. In this case, the theory reactivation on embryonic stem cells is a theory that may be the cause of osteoma because from the patient anamnesis, there were no history of recurring trauma on the face or nose area and the history of previous infection [4].

Nasal bone osteomas are usually asymptomatic, painless, and cause an irregular nose shape [2]. In addition to complaining about bumps on the nose, the osteoma that occurs in nasal bone that located close to the orbita, nasolacrimal duct, the patient may complain of other symptoms such as proptosis, epiphora or diplopia [6]. The symptoms depend on the location and size of the osteoma [9]. Osteomas can also cause asymmetry of craniofacial, headache, neuralgia, and orbital symptoms in cases that have extended to

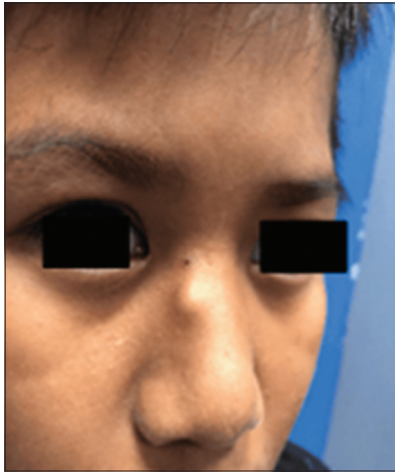

Figure 7: Picture of patient on 4th months after surgery

the orbit [2]. The nose is a complex structure consisting of subunits esthetic that gives character to a person's face [10] and nose is the most prominent part of the face. Therefore, nasal bone osteoma will cause esthetic problems on the nasal dorsum in patients who complain of a lump in the nose [3]. On physical examination of a patient with nasal bone osteoma, palpation found hard and round in shape, fixed to the bone and painless [3]. Osteoma measuring more than 30 mm or weighing 110 g is called a giant osteoma [11].

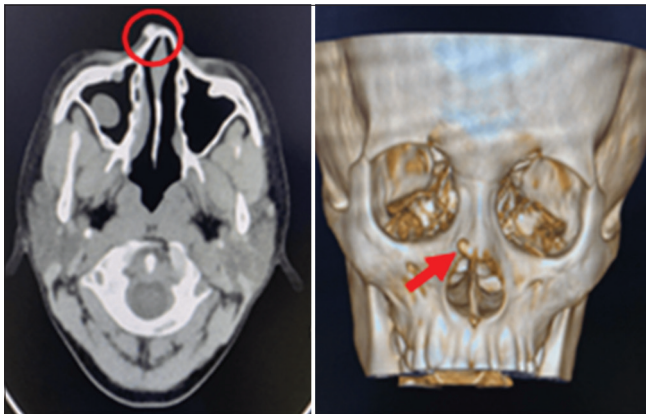


Figure 8: CT scan of paranasal sinuses and CT scan 3D 4th months after surgery

Asymptomatic osteoma is sometimes detected incidentally on radiological examination. CT scan is still the gold standard for diagnosis and surgical planning [5], [12]. CT scan is the best imaging modality to determine the location of the tumor, tumor extension, tumor attachment, and relationship with the surrounding area [13]. On CT scan, the osteoma lesion is homogeneous, dense with well-defined lesion boundaries [4]. The overview of radiology from osteoma was mass sclerotic on periosteal or sclerotic appearance on the periphery of the periosteal with trabecular on the central area of the masses [13]. CT scan is more specific in diagnosing osteogenic and chondrogenic lesions [14]. The patient underwent a 3D CT scan, where the 3D CT scan provides an overall spatial concept that allows a better understanding of the complexities of multiple axial

imaging in 2D CT scan and can assist in explaining and educating patients and families about the patient's disease [12]. Magnetic resonance imaging (MRI) is performed if an image of the tumor extends into the intracranial cavity. Where in the literature, it is stated that MRI examination is better than CT scan to distinguish inflammatory conditions and neoplastic processes [14].

On histopathological examination of the patient, microscopic of tissue sections containing proliferation with bone trabeculae containing osteocytes and capillaries were seen, and connective tissue capsules were also visible on the outside. In histopathology, osteoma is classified into a compact, spongiosa, and mixed osteoma [13]. Based on histopathological results, the patient was classified as osteoma spongiosa, which is an osteoma with characteristics of trabecular bone and fibrous fat tissue covered by osteoblasts and surrounded by cortical bone. Spongiosa osteoma is a type of osteoma that has invasive osteoblastic activity [15]. Where based on the literature, spongiosa osteoma is one of the types that have a fast growth [11]. Overall, the microscopic appearance of osteoma types containing fibrous connective tissue in the central section consisting of blood vessels and osteoblasts, which are bridged by a network of trabecular and compact bone tissue enveloped in the periphery [7].

The indication for surgery in this patient is esthetic, because, functionally, there were no abnormalities. Osteoma can be treated surgically with an external approach or with an endoscopic approach. Although there is no standard procedure in treating nasal bone osteoma, because it is a rare case. The surgical technique with an incision technique open rhinoplasty with a transcolumella incision with infracartilaginous extensions is effective, because it minimizes surgical scars post-operative. Hence, in young patients or women, this technique is preferred as surgical therapy. In addition, this technique can also help in correcting the asymmetry of the nose. By applying the open rhinoplasty technique, a surgeon can not only easily hide surgery scars, but also revise functional and esthetic results simultaneously during excision [2]. The surgical technique of tumor resection with the columella approach shows the success of therapy in cases of nasal bone osteoma [5]. In the patient, the tumor mass was chiseled, followed by curettage at the attachment of the tumor mass. Sculpting and curettage of the attachment of the tumor mass is useful in clearing the surgical margins and smoothing the surface of the nasal bones [6].

In the 4th month post-operative, the patient complained of lumps reappearing in the same place. It is reported that the recurrence of osteoma after surgery is very rare. Whereas, the change of osteoma to a malignancy has not been reported in the literature [13]. The rate of recurrence of osteoma reported in the literature after surgery is about 10% [11]. The recurrence of this osteoma results from incomplete

surgical removal of the tumor mass, especially in the case of large osteomas [8], [11]. Osteomas arising near healthy bone that has a broad base have been reported to be more prone to recurrence if there is no prior radical resection of the tumor [16]. The maximal growth rate of osteoma is observed during the period of skeletal growth, it is said that growth in untreated osteoma or osteoma that is not completely resected the growth will be much slower when the skeletal growth period is over [17].

In this case, a recurrence occurred 4 months after surgery. The patient is 11 years old, which is the age of puberty. Based on the literature, the growth of craniofacial in this case the nose reaches its maximum growth in women aged 12 years and men aged 14 years [18]. The nose is a location located on the medial 1/3 of the face, where there is a suture where the nasal bone and cartilage meet, known as the "Keystone" area [19]. This area is a center for osteogenic embryonic skeletal growth. In this area, there were a sutures that play an important role in craniofacial growth [20]. This may lead to rapid recurrence in the patient. Follow-up is recommended for asymptomatic osteomas depending on the reported annual growth rate of the osteoma, which is 0.44–6.0 mm/year [6].

Conclusion

Nasal bone osteoma is a very rare benign tumor. The diagnosis is obtained from the history, physical examination, and supporting examinations such as CT scan and confirmed by histopathological examination.

Nasal bone osteoma was treated surgically with tumor resection using the technique columella approach which gave good results, because it can minimize surgical scars post-operative and correct esthetic problems especially for young and woman patients. Nasal osteoma has a very rare recurrence rate and has a good prognosis.

References

- Elwatidy S, Alkathlan M, Alhums T, Kattan A, Al-Faky Y, Alessa M. Strategy for surgical excision and primary reconstruction of giant frontal sinus osteoma. *Interdiscip Neurosurg.* 2021;23:1-7. <https://doi.org/10.1016/j.inat.2020.100905>
- Hwang JH, Lee DG, Kim KS, Lee SY. Peripheral osteoma of the nasal bone after laser treatment: A case report. *Medicine (Baltimore).* 2019;98(40):e17036. <https://doi.org/10.1097/MD.00000000000017036> PMID:31577698
- Savas SA, Savaş E, Karakaya YA. Outer side of the nasal bone osteoma. *J Craniofac Surg.* 2017;28(4):e399-400. <https://doi.org/10.1097/SCS.00000000000003766> PMID:28437269
- Watkinson J, Clarke R. Osteomas. *Scotts Brown's Otorhinolaryngology Head and Neck Surgery.* 8th ed., Vol. 1. Oxfordshire United Kingdom: Taylor and Francis Group; 2019. p. 1099-100.
- Ono MC, De Moraes AD, Freitas RD. Nasal Bone Osteoma Approach. *J Craniofac Surg.* 2020;31(1):e80-1. <https://doi.org/10.1097/SCS.00000000000005940> PMID:31634315
- El-Anwar MW, Elsheikh E. Isolated osteoma of the ascending process of the maxilla. *J Craniofac Surg.* 2015;26(4):e317-9. <https://doi.org/10.1097/SCS.0000000000001702> PMID:26080246
- Karunaratne YG, Gunaratne DA, Floros P, Wong EH, Singh NP. Frontal sinus osteoma: From direct excision to endoscopic removal. *J Craniofac Surg.* 2019;30(6):e494. <https://doi.org/10.1097/SCS.00000000000005371> PMID:30921069
- Deepa R, Anuradha P. Osteoma of maxillary sinus: A rare cause of epiphora. *TNOA J Ophthalmic Sci Res.* 2020;58(3):192. https://doi.org/10.4103/tjosr.tjosr_50_20
- Esmaili SN. Osteoma. In: *Bailey's Head and Neck Surgery Otolaryngology.* 5th ed., Vol. 2. Pennsylvania, United States: Lippincott Williams and Wilkins; 2014. p. 2074.
- Hafiz A, Huriyati E, Budiman BJ, Munilson J. Paramedian forehead flap for reconstruction of the nose. *Maj Kedokt Andalas.* 2015;38(2):147. <https://doi.org/10.22338/mka.v38.i2.p147-154.2015>
- Humeniuk-Arasiewicz M, Stryjewska-Makuch G, Janik MA, Kolebacz B. Giant fronto-ethmoidal osteoma-selection of an optimal surgical procedure. *Braz J Otorhinolaryngol.* 2018;84(2):232-9. <http://doi.org/10.1016/j.bjorl.2017.06.010> PMID:28760714
- Murizky B, Al Hafiz AH. Open reduction of the isolated anterior frontal sinus fracture. *J Kesehat Andalas.* 2020;9(1S):178-88.
- Bocchialini G, Villaret AB, Negrini S, Tironi A, Salvagni L, Castellani A. The first case of osteoma of the mandibular notch located both medially and laterally and treated with a transoral endoscopy assisted approach. A case report. *Int J Surg Case Rep.* 2018;49:70-3. <https://doi.org/10.1016/j.ijscr.2018.06.013> PMID:29966952
- Mafee MF. Tumor of the Paranasal Sinuses in *Ballenger's Otorhinolaryngology Head and Neck Surgery.* 8th ed. Connecticut: People's Medical Publishing House; 2016. p. 680-2.
- Bagheri A, Feizi M, Kanavi MR. Superficial orbital rim osteoma. *J Craniofac Surg.* 2019;30(8):2542-3. <https://doi.org/10.1097/SCS.00000000000005686> PMID:31232994
- Zala AP, Shah MM, Parikh HS, Ramchandani G, Hiriyur SP. Case study of giant frontal-ethmoid sinus osteoma. *Int J Clin Diagn Pathol.* 2020;3(3):244-7. <https://doi.org/10.33545/pathol.2020.v3.i3d.290>
- Maroldi R, Berlucchi M, Farina D, Tomenzoli D, Borghesi A, Pianta L. Benign neoplasms and tumor-like lesions. In: *Maroldi R, Nicolai P editors. Imaging Treat Plan Sinonasal Diseases.* Berlin, Heidelberg, New York: Springer Verlag; 2005. p. 107-58.
- Hsiao SY, Cheng JH, Tseng YC, Chen CM, Hsu KJ. Nasomaxillary and mandibular bone growth in primary school girls aged 7 to 12 years. *J Dent Sci.* 2020;15(2):147-52. <https://doi.org/10.1016/j.jds.2020.03.010> PMID:32595894

19. Sakarya E, Kar M, Bafaqeeh S. Surgical anatomy of the external and internal nose. In: All Around the Nose. Berlin, Germany: Springer Nature; 2020. p. 39-47.
20. Manlove AE, Romeo G, Venugopalan SR. Craniofacial growth: Current theories and influence on management. *Oral Maxillofac Surg Clin North Am.* 2020;32(2):167-75. <https://doi.org/10.1016/j.coms.2020.01.007>
PMid:32151371