



Invading of Renal Cell Carcinoma in Inferior Vena Cava and Right Atrium with a Huge Metastatic Thrombus

Andi Kacani¹, Marsela Goga², Saimir Kuci², Arber Aliu¹, Alfred Ibrahim², Alessia Mehmeti², Petrika Gjergo³, Aurel Janko⁴, Agron Dogjani^{5*}

¹Department of Cardiac Surgery, University Hospital Centre "Mother Teresa", Tirana, Albania; ²Department of Cardiac Anesthesia, University Hospital Centre "Mother Teresa", Tirana, Albania; ³Department of Vascular Surgery, University Hospital Centre "Mother Teresa", Tirana, Albania; ⁴Department of Urologic Surgery, University Hospital Centre "Mother Teresa", Tirana, Albania; ⁵Department of Surgery, University of Medicine, Tirana, Albania

Abstract

BACKGROUND: Renal cell carcinoma (RCC) with cavoatrial involvement represents a major surgical challenge. Several surgical techniques for the treatment of these tumors have been proposed, but due to a small number of patients and limited follow-up, substantial controversy about the best operative management still exists.

CASE REPORT: A 54-year-old woman, with no previous comorbidities, comes to the emergency room with low back pain, weight loss, and edema of the lower legs that computed tomography revealed a massive infiltrative expansive formation in the abdomen that affected practically the entire right kidney, measuring 8.2 cm × 7.6 cm that invaded the collecting system and was in close contact with the right hepatic lobe and the head of the pancreas. During the intervention, infiltration of the renal vein on this side is found, and the inferior vena cava (IVC) that extends in its intrahepatic part, up to the junction of the suprahepatic veins, with almost complete closure of the lumen accompanied by the presence of retroperitoneal lymph nodes, with size up to 10 mm.

CONCLUSION: Advanced extension of RCC can occur with no apparent symptoms and be detected incidentally. In rare circumstances, atypical presentation of RCC should be considered in a patient presenting with the right atrial mass detected by echocardiography. RCC with IVC and right atrium extension is a complex surgical challenge, but excellent results can be obtained with proper patient selection, meticulous surgical techniques, and close perioperative patient care.

Edited by: Igor Spiroski
Citation: Kacani A, Goga M, Kuci S, Aliu A, Ibrahim A, Mehmeti A, Gjergo P, Janko A, Dogjani A. Invading of Renal Cell Carcinoma in Inferior Vena Cava and Right Atrium with a Huge Metastatic Thrombus. Open Access Maced J Med Sci. 2022 Mar 09; 10(C):107-110. <https://doi.org/10.3889/oamjms.2022.8552>

Keywords: Renal cell carcinoma; Tumor thrombus; Inferior vena cava

*Correspondence: Agron Dogjani, Department of Surgery, University of Medicine of Tirana, Albania. E-mail: agrondogjani@yahoo.com

Received: 08-Jan-2022

Revised: 22-Feb-2022

Accepted: 04-Mar-2022

Copyright: © 2022 Andi Kacani, Marsela Goga, Saimir Kuci, Arber Aliu, Alfred Ibrahim, Alessia Mehmeti, Petrika Gjergo, Aurel Janko, Agron Dogjani
Funding: This research did not receive any financial support
Competing Interests: The authors have declared that no competing interests exist
Open Access: This is an open-access article distributed under the terms of the Creative Commons Attribution-NonCommercial 4.0 International License (CC BY-NC 4.0)

Introduction

Renal cell carcinoma (RCC) is a kidney cancer that originates in the lining of the proximal convoluted tubule, a part of the very small tubes in the kidney that transports primary urine.

In the 15% of cases, RCC can invade the inferior vena cava (IVC), leading to the formation of a thrombus inside it, which can reach the cardiac chambers in up to 1% of cases.

The surgical management of renal tumors with thrombi in the IVC and right atrium has therefore become the gold standard treatment, with reported perioperative mortality rate from 2.7% to 13%. Survival at 5 years for patients operated without pre-operative metastases varies between 30% and 72%. The short- and mid-term risks, if no treatment is performed, are massive pulmonary embolism, total obstruction of the tricuspid valve, and liver failure as a result of the Budd-Chiari syndrome. The level of tumoral extension is based on radiological examination and transoesophageal echocardiography (TEE). When the thrombus extends

into the right atrium (level IV) the most commonly used, surgical strategies are cardiopulmonary bypass (CPB) with deep hypothermic circulatory arrest (DHCA), CPB without circulatory arrest, and vascular occlusion without CPB. According to Sweeney *et al.*, [1] there are four stages of cavoatrial tumor-thrombus extension: In Type I, the intravascular tumor has reached the renal vein, but not the IVC, in Type II, the IVC is occupied up to the level of the hepatic veins, while, in Types III and IV, the supradiaphragmatic IVC and the right cardiac chamber are involved.

Case Report

A 54-year-old woman, with no previous comorbidities, comes to the emergency room with low back pain, weight loss, and edema of the lower legs especially in the past 2 weeks. Physical examination indicated skin pallor with a bulging and painful abdomen on the right and cardiac rub. Laboratory tests revealed

hemoglobin of 11.6 g/dL, creatinine 0.90 mg/dL, total calcium of 8.8 mg/dL, and lactate dehydrogenase of 621 U/L and NTproBNP: 1534 pg/mL. A transthoracic echocardiography was performed immediately, which revealed a 19 cm² hyperechogenic mobile formation that filled the entire right atrium, originating from the VCI and exiting into the right ventricle. In the IVC at the site of entry into the right atrium, a thrombotic formation was seen closing the lumen of the vein as shown in Figure 1.

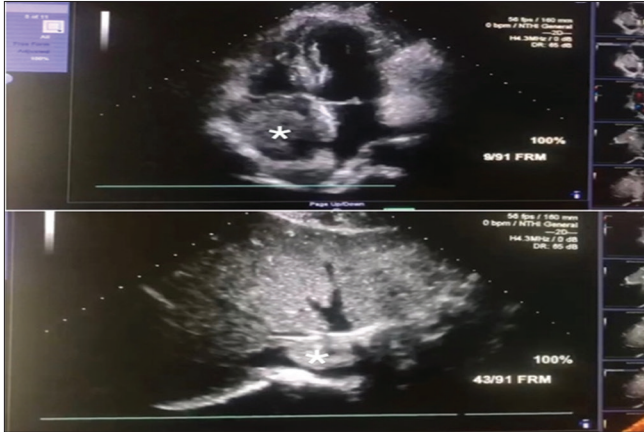


Figure 1: Transthoracic echocardiography: (*) ThroFmbus in the right atrium and inferior vena cava

Computed tomography (CT) revealed a massive infiltrative expansive formation in the abdomen that affected practically the entire right kidney, measuring 8.2 cm × 7.6 cm that invaded the collecting system and was in close contact with the right hepatic lobe and the head of the pancreas. During the intervention, infiltration of the renal vein on this side is found, and the inferior vena cava (IVC) that extends in its intrahepatic part, up to the junction of the suprahepatic veins, with almost complete closure of the lumen was accompanied by the presence of retroperitoneal lymph nodes, with size up to 10 mm. As a complementary diagnostic, MR angiography and Chest CT- scan, did not detect metastasis (Figure 2).

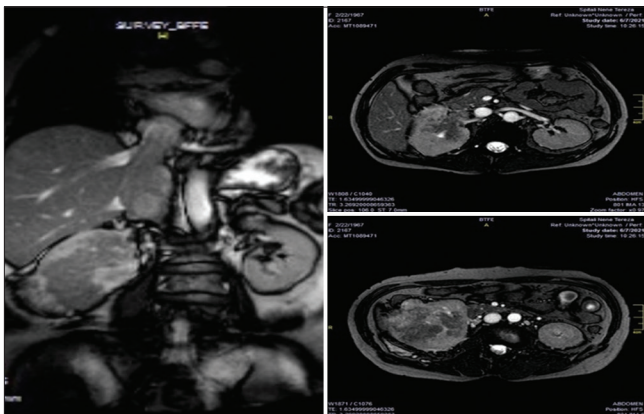


Figure 2: Angio-MRI

From the discussion that took place with a staff of vascular and urologist surgeons cardio surgeon and cardio anesthesiologist, it was decided the removal of the primary renal tumor, the removal of the metastatic

thrombus from the IVC, and from the right atrium to be done in one session. Coronarography was performed before surgery and resulted without coronary stenosis.

General anesthesia and standard monitoring as per open heart surgery were performed. Intraoperatively, the diagnosis was verified by TEE and a giant mass was verified entering and exiting the right ventricle (Figure 3).

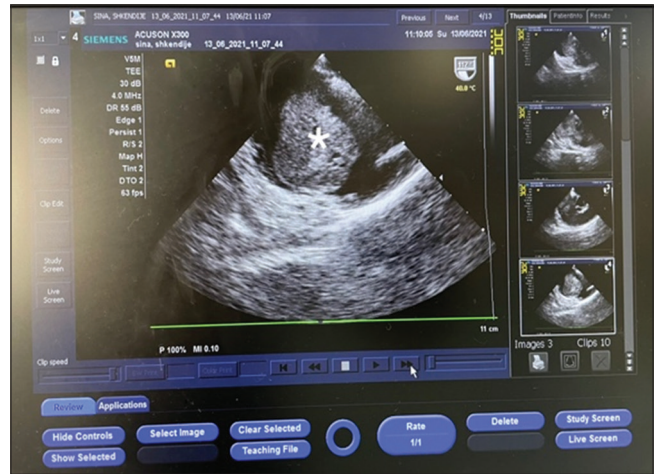

Figure 3: Intraoperative transoesophageal echocardiography (*) huge thrombus in the right atrium

Surgical approach

Extended midline incision with sternotomy, (median xiphoid to pubic bone, extended cephalad through median sternotomy) following entry into the peritoneum, the right affected kidney, and IVC was isolated, through interaortocaval space renal artery is ligated. Gentle traction then permitted en bloc removal of the kidney and remaining thrombus (Figure 4).

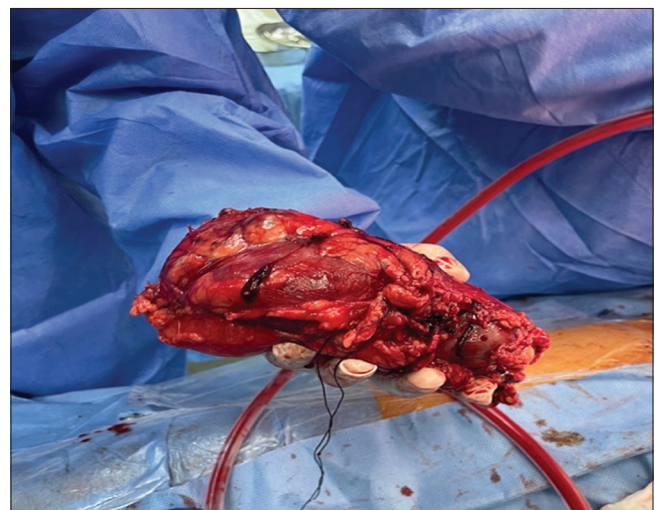

Figure 4: Kidney en bloc removal

In our case with classification of tumor thrombus level IV or supradiaphragmatic thrombi, CPB was established as usual; arterial cannula (20 Fr) was placed in the ascending aorta; venous cannulas were placed in the superior vena cava (22 Fr); and

percutaneous right femoral vein cannulation was performed (18 Fr). The patient was cooled to 32°C (nasopharyngeal temperature), the ascending aorta was cross clamped, and crystalloid cardioplegia solution was administered for myocardial protection antegradely.

After opening right atrium, excision of the huge tumor thrombus is realized securing the supradiaphragmatic IVC that is clean. The aorta is declamped with the right atrium still opened (Figure 5).

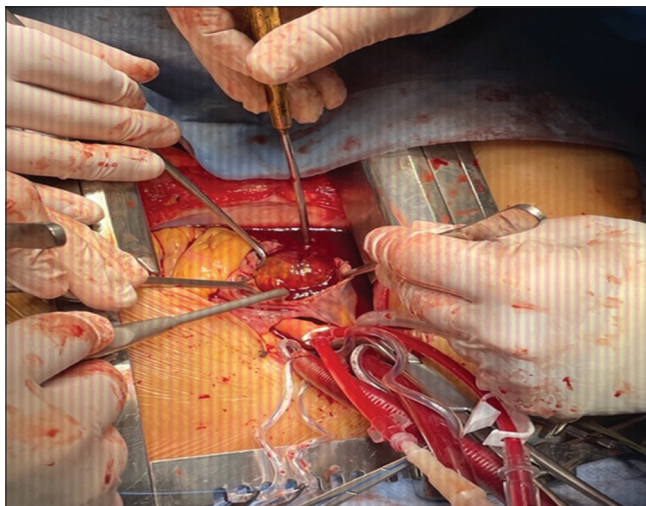


Figure 5: Thrombus removal from the right atrium

The next step was intra-abdominal cavotomy and excision of tumor thrombus throughout IVC securing the lumen of the IVC to the right atrium is clean (Figure 6).

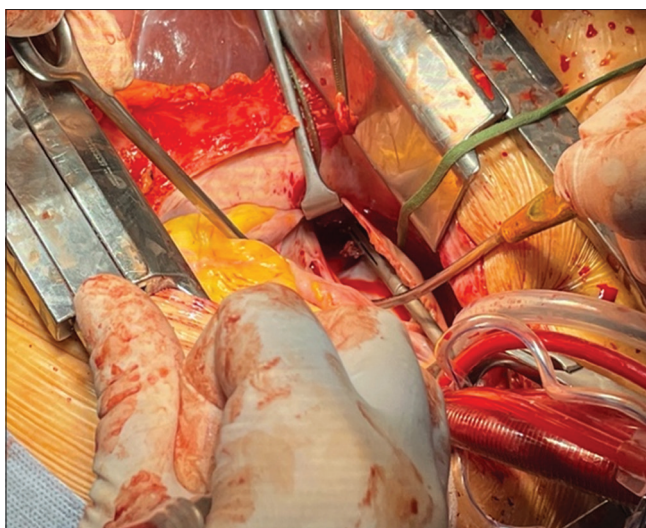

Figure 6: Inferior vena cava cleaning from atriotomy

Then, the right atrium was closed.

Total intervention time was 420 min with CPB time 62 min and there was no tumor migration or air embolism during the procedure. The number of transfusions was 3 UI of blood, 1 intraoperatively, and 2 UI post-operative. The patient did not have complications such as pneumonia, wound infection, and deep venous thrombosis, in the post-operative.

The days of staying in ICU were 5 and the patient went home for further monitoring and therapy after 8 days of staying in the ward.

The histology showed renal clear cell carcinoma Fuhrman nuclear Grade 2, with hilus invasion and presence of vascular invasion. IVC invasion is also observed. Adrenal gland was without neoplasia (pT3bNxMx).

Discussion

The management of patients with cardiac extension (Level IV) must be individualized. CPB has been recommended, with or without hypothermia and cardiac arrest, for Levels III and IV, because it guarantees hemodynamic stability during IVC clamping and a bloodless field [2], [3], [4], [5].

However, CPB increases the operative time, cardiorespiratory complications, post-operative bleeding, and the onset of coagulopathies [6], [7]. On the other hand, digital manipulation of the tumor to push it down from the right atrium to the IVC without CPB protection may be hazardous. Hence, in the absence of effective alternative treatment, complete surgical removal of the primary tumor with its extension along the vena cava is the only available cure option. The use of deep hypothermia CPB with circulatory arrest in patients with tumor thrombus extending into the right atrium has been reported [8], [9]. Aortic clamping is, however, associated with myocardial and visceral ischemia. If profound DHCA is performed, no aortic clamping is necessary. However, the limits of DHCA are the associated morbidities. Indeed, this technique requires prolonged CBP for rewarming. It is also associated with increased mortality rate, neurologic complications, and extensive bleeding due to platelets distortion and tumor cells autotransfusion [10], [11]. Transient neurological deficits (delirium, cognitive impairment, and stroke) are observed in 4–25% of patients [11], [12].

The CPB approach described in this paper offers several advantages. First, cerebral perfusion is maintained throughout the procedure. The morbidity related to DHCA is avoided. Complete resection of the tumor was always performed, without tumor or air embolism, and minimum blood loss. Hemodynamic stability and avoiding vital organ ischemia were always achieved during the procedure.

In our case, we used extracorporeal circulation with access from the superior vena cava and percutaneous cannulation of the right femoral vein with. Blood drainage was very good and perfusion flow was maintained 2–2.4 l/m². The perfusion temperature was lowered to 32°C and organ perfusion was good avoiding DHCA.

Conclusion

Advanced extension of RCC can occur with no apparent symptoms and be detected incidentally. In rare circumstances, atypical presentation of RCC should be considered in a patient presenting with the right atrial mass detected by echocardiography. RCC with IVC and right atrium extension is a complex surgical challenge, but excellent results can be obtained with proper patient selection, meticulous surgical techniques, and close perioperative patient care.

Availability of Data and Materials

The datasets analyzed during the present study, which are available from the corresponding author on reasonable request.

Authors' Contributions

AK has completed cardiac sonographic examination; AK MG, SK, AI, and AA have completed diagnosis. AJ, PG, AM, and AD pooled the data, analyzed the literature, and wrote the manuscript. AK, MG, and AD analyzed the literature. All authors read and approved the final manuscript.

COI Statement

This paper has not been submitted in parallel. It has not been presented fully or partially at a meeting or podium or congress. It has not been published nor submitted for consideration beforehand.

This research received no specific grant from any funding agency in the public, commercial, or non-profit sectors. There are no relevant or minor financial relationships from authors, their relatives, or next of kin with external companies.

References

- Sweeney P, Wood CG, Pisters LL, Slaton JW, Vaporciyan A, Munsell M, *et al.* Surgical management of renal cell carcinoma associated with complex inferior vena caval thrombi. *Urol Oncol.* 2003;21(5):327-33. [http://doi.org/10.1016/s1078-1439\(02\)00280-6](http://doi.org/10.1016/s1078-1439(02)00280-6). PMID: 14670538
- Glazer AA, Novick AC. Long-term followup after surgical treatment for renal cell carcinoma extending into the right atrium. *J Urol.* 2006;155(2):448-50. PMID:8558632
- Novick AC, Kaye MC, Cosgrove DM, Angermeier K, Pontes JE, Montie JE, *et al.* Experience with cardiopulmonary bypass and deep hypothermic circulatory arrest in the management of retroperitoneal tumors with large vena caval thrombi. *Ann Surg.* 1990;212(4):472-6; discussion 476-7. <http://doi.org/10.1097/00000658-199010000-00010> PMID:2222013
- Yamashita C, Ataka K, Azami T, Nakagiri K, Wakiyama H, Okada M. Usefulness of cardiopulmonary bypass in reconstruction of inferior vena cava occupied by renal cell carcinoma tumor thrombus. *Angiology.* 2016;50(1):47-53. <http://doi.org/10.1177/000331979905000106> PMID:9924888
- Montie JE, El Ammar R, Pontes JE, Medendorp SV, Novick AC, Strem SB, *et al.* Renal cell carcinoma with inferior vena cava tumor thrombi. *Surg Gynecol Obstet.* 1991;173(2):107-15. PMID:1925859
- Nesbitt JC, Soltero ER, Walsh GL, Schrupp DS, Swanson DA, Pisters LL, *et al.* Surgical management of renal cell carcinoma with inferior vena cava tumor thrombus. *Ann Thorac Surg.* 2007;63(6):1592-600. [http://doi.org/10.1016/s0003-4975\(97\)00329-9](http://doi.org/10.1016/s0003-4975(97)00329-9) PMID:9205155
- Gallucci M, Borzomati D, Flammia G, Alcini A, Albino G, Caricato M, *et al.* Liver harvesting surgical technique for the treatment of retro-hepatic caval thrombosis concomitant to renal cell carcinoma: Perioperative and long-term results in 15 patients without mortality. *Eur Urol.* 2004;45(2):194-202. <http://doi.org/10.1016/j.eururo.2003.09.004> PMID:14734006
- Marshall FF, Reitz BA, Diamond DA. A new technique for management of renal cell carcinoma involving the right atrium: Hypothermia and cardiac arrest. *J Urol.* 1984;131(1):103-7. [http://doi.org/10.1016/s0022-5347\(17\)50221-9](http://doi.org/10.1016/s0022-5347(17)50221-9) PMID:6690724
- Krane RJ, de Vere White R, Davis Z, Sterling R, Dobnik DB, McCormick JR. Removal of renal cell carcinoma extending into the right atrium using cardiopulmonary bypass, profound hypothermia and circulatory arrest. *J Urol.* 1984;131(5):945-7. [http://doi.org/10.1016/s0022-5347\(17\)50722-3](http://doi.org/10.1016/s0022-5347(17)50722-3) PMID:6708232
- Svensson LG, Crawford ES, Hess KR, Coselli JS, Raskin S, Shenaq SA, *et al.* Deep hypothermia with circulatory arrest. Determinants of stroke and early mortality in 656 patients. *J Thorac Cardiovasc Surg.* 2003;106(1):19-28; discussion 28-31. PMID:8321002
- Okita Y, Takamoto S, Ando M, Morota T, Matsukawa R, Kawashima Y. Mortality and cerebral outcome in patients who underwent aortic arch operations using deep hypothermic circulatory arrest with retrograde cerebral perfusion: No relation of early death, stroke, and delirium to the duration of circulatory arrest. *J Thorac Cardiovasc Surg.* 2008;115(1):129-38. [http://doi.org/10.1016/s0022-5223\(98\)70451-9](http://doi.org/10.1016/s0022-5223(98)70451-9) PMID:9451056
- Ergin MA, Galla JD, Lansman L, Quintana C, Bodian C, Griep RB. Hypothermic circulatory arrest in operations on the thoracic aorta. Determinants of operative mortality and neurologic outcome. *J Thorac Cardiovasc Surg.* 2004;107(3):788-97; discussion 797-9. PMID:8127108