



Eumycetoma Pedis Due to *Madurella mycetomatis* in Indonesian Farmer: A Case Report

Emma Novauli Hutabarat*, Faridha Ilyas, Safruddin Amin

Department of Dermatology and Venereology, Faculty of Medicine, University of Hasanuddin, Wahidin Sudirohusodo Hospital, Makassar, South Sulawesi, Indonesia

Abstract

Edited by: Igor Spiroski
Citation: Hutabarat EN, Ilyas F, Amin S. Eumycetoma Pedis Due to *Madurella mycetomatis* in Indonesian Farmer: A Case Report. Open-Access Maced J Med Sci. 2022 Feb 23; 10(C):80-84. <https://doi.org/10.3889/oamjms.2022.8630>
Keywords: Mycetoma; Pedis; Itraconazole; Endemic
***Correspondence:** Emma Novauli Hutabarat, Department of Dermatology and Venereology, Wahidin Sudirohusodo Hospital, Faculty of Medicine, University of Hasanuddin, Makassar, South Sulawesi, Indonesia. E-mail: emmahutabaratdr@gmail.com
Received: 14-Jan-2022
Revised: 14-Jan-2022
Accepted: 17-Feb-2022
Copyright: © 2022 Emma Novauli Hutabarat, Faridha Ilyas, Safruddin Amin
Funding: This research did not receive any financial support
Competing Interest: The authors have declared that no competing interest exists
Open Access: This is an open-access article distributed under the terms of the Creative Commons Attribution-NonCommercial 4.0 International License (CC BY-NC 4.0)

BACKGROUND: Mycetoma is a chronic, localized cutaneous inflammatory disease originating from fungi (eumycetoma) or bacteria (actinomycetoma) infection. The most common cause of eumycetoma is a black grain producing fungus, *Madurella mycetoma*.

CASE PRESENTATION: We present a case of eumycetoma pedis in a middle-aged woman with a successful resolution after receiving the combination of surgical debridement, systemic itraconazole, and topical antifungals therapy.

CONCLUSION: This case report highlights the importance of a prompt diagnostic procedure to identify the causative agent in mycetoma at an early stage of the disease followed by integrated management care that combines systemic therapy and surgical intervention.

Introduction

Mycetoma is a chronic progressive cutaneous inflammatory disease that originated from the infection of two distinctive causative organisms, the aerobic filamentous bacteria (actinomycetoma) or true fungi (eumycetoma) [1]. It is commonly manifested as a granulomatous infection affecting the skin and its surrounding tissue, characterized by multiple tumefaction lesions, containing grain discharge draining through sinus formation [2]. The infection occurs due to the invasion of microorganisms into microtraumatized human skin that is directly exposed to soil, thorns, or animal dungs. Therefore, the most frequent predilection area often affects the foot, making this infection known as Madura foot or mycetoma pedis [3].

Mycetoma has been determined as a neglected tropical disease, and the exact incidence is unknown. A field survey report in West Nile, State of Sudan, a country known to be the leading endemic area of mycetoma, presented a prevalence of 14.5 cases per 1000 population in 2010 [4]. Occasionally reported, mycetoma pedis also appears from Indonesia as a tropical country, but unfortunately, the data are still

limited [5]. *Madurella mycetomatis* is known as the most common fungal causative agent in eumycetoma pedis [6]. The treatment of eumycetoma is challenging and mostly unsatisfactory, as most of the cases require not only pharmacologic approaches but also should be combined with surgical intervention. Therefore, it often becomes a burden for the patient, particularly in developed countries with the poor socioeconomic condition.

In this report, we present an endemic case of eumycetoma pedis in middle-aged Indonesian female. Furthermore, we highlight the current pharmacological and surgical treatment approach to raise the awareness of healthcare personnel on how to carry out successful management to overcome this devastating condition.

Case Report

Patient information

A 49-year-old female of Indonesian origin presented with a chronically progressing wound on the

dorsal and plantar regions of the left foot. The symptom began a year ago, starting with the growth of a mass the size of a fish's eye. The patient decided to come to the surgeon and underwent the removal of the mass. The mass was resolved but recurred and eventually became multiplied, enlarged, and edematous. The patient works as a farmer and presented with no preceding medical conditions.

Clinical findings

The general physical examination revealed normal findings. Dermatology examination exhibited painful multiple discharge-draining nodules, surrounded by ulcers and pustules with crust, over edematous skin on the dorsum, and plantar pedis (Figure 1). However, the typical macroscopic "grain" finding was not found from the patient's wound.

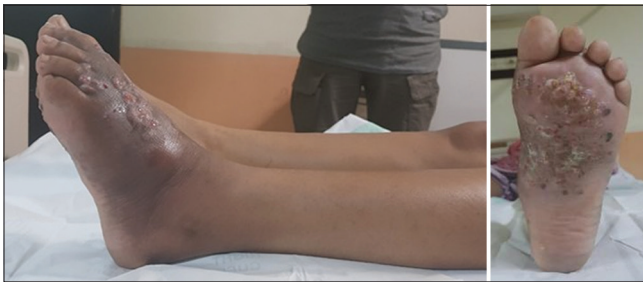

Figure 1: Clinical presentation of eumycetoma on the left foot

Timeline of current episode

The patient was referred to the orthopedic department to find possible extended tissue involvement, including the fascia, tendon, muscles, or bones.

Diagnostic assessment

Laboratory investigations, including complete blood count and blood glucose profile, showed normal results. Plain radiographic imaging on the affected foot showed osteomyelitis; meanwhile, the magnetic resonance imaging (MRI) revealed the "dot in a circle" sign (Figure 2). The patient was suggested for surgical debridement followed by bacterial and fungal culture of the discharge. The cultures examination did not detect any presence of bacterial or fungal colonies. Histopathological examination was further performed by examining the biopsy sample from the excised skin tissue.

Diagnosis

Histopathological examination using periodic acid–Schiff (PAS) staining revealed granulation tissue containing macrophages with a filamentous pattern, surrounded by mixed inflammatory infiltrates,

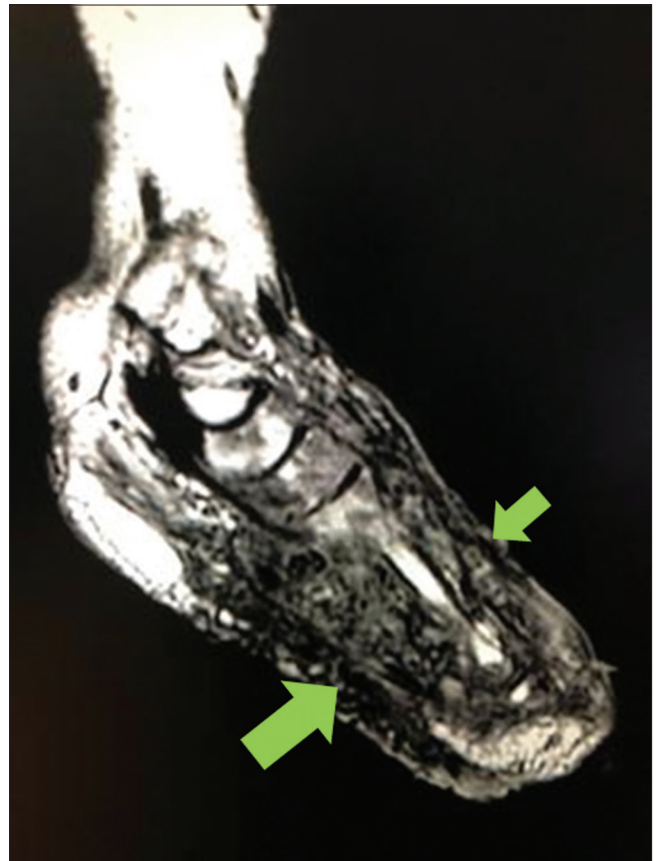


Figure 2: The imaging showing a classic "dot in a circle" sign

including the neutrophils, lymphocytes, and plasma cells (Figure 3). This finding suggests fungal infection, therefore, confirming the diagnosis of eumycetoma pedis with *M. mycetoma* as the causative agent.

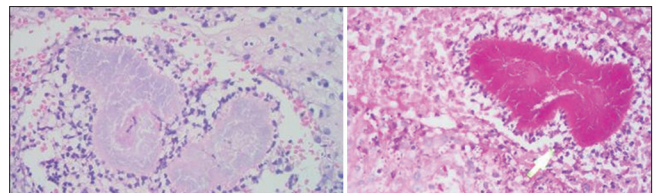


Figure 3: Histopathological visualization of granuloma surrounded by mixed inflammatory infiltrates

Therapeutic interventions

The patient was subsequently administered oral itraconazole (200 mg, twice a day) and topical medications containing 3% salicylic acid, 6% benzoic acid, and 30 g miconazole applied twice times a day. The therapy was also combined from the orthopedic department, including oral cefixime (200 mg, twice a day), metronidazole (500 mg, 3 times a day), and meloxicam (15 mg, 3 times a day).

Follow-up and outcome of interventions

After a month of therapy, the post-surgical debridement wound had utterly healed; thus, the

pharmacological medications from the orthopedic department were discontinued. Nevertheless, the antifungal medications were continued. After 26 weeks of systemic itraconazole therapy, the skin lesions have completely improved (Figure 4); then, itraconazole therapy was discontinued. Patients were informed to routinely use the footwear to seek medical attention immediately if complaints recur.

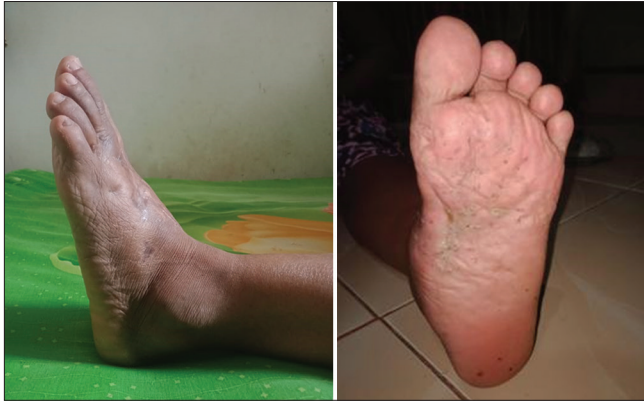

Figure 4: Complete resolution after 26 weeks of combination therapy

Informed consent

The patient has given informed consent regarding the publication and the use of images in this case report for medical education purposes.

Discussion

Eumycetoma pedis is a neglected tropical disease with more predilection among individuals frequently exposed to the agricultural environment, such as farmers. Hence, about 70–75% of patients have initial lesions affecting the lower extremities, typically occurring in adult male ranging from 20 to 40 years of age [6]. The clinical manifestation often starts as a small, painless, subcutaneous nodule at the site of a traumatized skin. The defect in human skin, including skin abrasion or minor trauma, acts as the entrance of microbial inoculation from the plant or soil saprophytes, causing the mycetoma infection. The lesion will soften and become ulcerated, subsequently evolving into sinuses, draining a thick, purulent discharge that contains the granules composed of colonies of causative organisms known as “grains.” The disease progresses and causes invasion and inflammation of the surrounding tissue causing massive swelling, deep tissue destruction, and severe pain [7]. Our case portrayed the consistent initial manifestation of mycetoma infection, which begins with the growth of a painless mass in the predilection area of the foot. The patient was exposed to the main

risk factors, including having a profession as a farmer, making her vulnerable to the risk of infection to the causative agents. The patient was of Indonesian origin, which is one of the tropical countries endemic to mycetoma infection.

The diagnosis of mycetoma requires a detailed clinical history and physical examination, as well as the involvement of plain radiograph or MRI, laboratory tests, and histopathology examination to confirm the diagnosis. The MRI result of our patient revealed the appearance of a small focal hypointense lesion surrounded by a hyperintense area, known as the “dot in a circle” sign suggestive of mycetoma infection. Sen *et al.* stated that this sign provides a non-invasive clue that can aid in an early diagnosis of mycetoma [8]. This classic sign comprises the presence of granulation tissue represented by high intense rim lesions encircling fibrous septa and fungal grains represented by low signal intensity dots [9]. MRI helps determine the extension of the lesion within the affected tissue.

Histopathological examination remained the gold standard in diagnosing mycetoma [10]. Although the result of mycological culture did not find any fungal growth, histopathological examination with PAS staining revealed the positive classical findings of filamentous fungi with granulomas accompanied by macrophages and mixed inflammatory infiltrates. PAS is special staining used to identify the presence of fungi. This method is often superior to culture because it is more sensitive; also, the growth of fungi in cultures may not always be viable. The causative fungus can also be estimated based on grain color, where the most common cause of eumycetoma is *M. mycetoma* (70% of cases) with grains of the black color [11].

The treatment of eumycetoma poses a more challenging outcome than actinomycetoma because it depicts variable clinical responses and is often more associated with recurrence [12]. Hence, a combination of surgical intervention and systemic antifungal regimens is needed to inhibit the infection process and to prevent spreading into deeper tissues. The treatment of mycetoma must be started as soon as possible before the development of a more advanced stage. At present, there has not been any standardized treatment guideline for mycetoma infection. The previous reports suggested the administration of oral imidazole agents, such as ketoconazole (400 mg per day), itraconazole (200–400 mg per day), and posaconazole (200 mg per day); polyenes, such as amphotericin B (0.5–1.25 mg/kg per day); and allylamines, such as terbinafine (500–1000 mg/day) alone or in combination [13].

Our patient underwent a prolonged antifungal agent (itraconazole 400 mg a day) combined with topical antifungal regimens and surgical debridement. The result from these approaches was promising

and in accordance with the finding from Schibli *et al.* which found that the combination of surgical debridement and prolonged antifungal treatment demonstrated satisfactory outcomes [14]. Since the 1990s, itraconazole has been established as the most common drug in eumycetoma treatment [1]. Furthermore, a prospective study by Fahal *et al.* has proved that a 12-month course of itraconazole, followed by surgical debridement excision, resulted in satisfactory outcomes [15].

An interesting therapeutic finding arises from our case, as the lesions were found completely resolved only in about 6 months of prolonged therapy despite fairly extensive deeper tissue involvement. This may be related to a holistic treatment approach, which is combined with a surgical procedure. Some literature suggests that combination with surgical therapy resulted in better results than systemic antifungal monotherapy [7]. In this case, the patient was also given additional medicines, such as topical antifungal and post-operative antibiotics. To date, there has not been any literature reporting the effectiveness of topical regimens in eumycetoma nor the clinical benefits of administering a combination of antibiotics. Thus, further research is needed to determine the role of these two therapeutic regimens.

The recommendation in the case of eumycetoma is the need for regular follow-up liver tests as early detection of liver damage due to the side effects of systemic antifungal treatment. The clinicians also need to emphasize the importance of health education regarding personal protection devices, particularly for the exposed parts of the body (rubber boots and gloves) during agricultural work to lessen the direct contact against the causative agents.

Conclusion

This case report highlights the importance of a prompt diagnostic procedure to identify the causative agent in mycetoma at an early stage of the disease, followed by integrated management care that combines systemic therapy and surgical intervention, further improving disease progression to be more easily manageable.

Authors' Contributions

Emma Novauli Hutabarat: Conception, literature review, analysis, data collection, writing –review, and

editing. Faridha Ilyas: Conception, literature review, and editing. Safruddin Amin: Conception, methodology, supervision, and editing.

References

1. Welsh O, Al-Abdely HM, Salinas-Carmona MC, Fahal AH. Mycetoma medical therapy. *PLoS Negl Trop Dis.* 2014;8(10):e3218. <https://doi.org/10.1371/journal.pntd.0003218> PMID:25330342
2. Venkatswami S, Sankarasubramanian A, Subramanyam S. The madura foot: Looking deep. *Int J Low Extrem Wounds.* 2012;11:31-42. <https://doi.org/10.1177/1534734612438549> PMID:22334597
3. Elkheir LYM, Haroun R, Mohamed MA, Fahal AH. *Madurella mycetomatis* causing eumycetoma medical treatment: The challenges and prospects. *PLoS Negl Trop Dis.* 2020;14(8):e0008307. <https://doi.org/10.1371/journal.pntd.0008307> PMID:32853199
4. Fahal A, El Mahgoub S, El Hassan AM, Abdel-Rahman ME, Alshambaty Y, Hashim A, *et al.* A new model for management of mycetoma in the Sudan. *PLoS Negl Trop Dis.* 2014;8(10):e3271. <https://doi.org/10.1371/journal.pntd.0003271> PMID:25356640
5. Emmanuel P, Dumre SP, John S, Karbwang J, Hirayama K. Mycetoma: A clinical dilemma in resource limited settings. *Ann Clin Microbiol Antimicrob.* 2018;17(1):35. <https://doi.org/10.1186/s12941-018-0287-4> PMID:30097030
6. Sigera LS, Narangoda KU, Dahanayake MY, Shabri UL, Malkanthi MA, Somarathne V, *et al.* Mycetoma due to *Madurella mycetomatis*. *IDCases.* 2020 May 30;21:e00857. <https://doi.org/10.1016/j.idcr.2020.e00857> PMID:32528849
7. Relhan V, Mahajan K, Agarwal P, Garg VK. Mycetoma: An update. *Indian J Dermatol.* 2017;62(4):332-40. https://doi.org/10.4103/ijid.IJD_476_16 PMID:28794542
8. Sen A, Pillay RS. Case report: Dot-in-circle sign-an MRI and USG sign for "Madura foot". *Indian J Radiol Imaging.* 2011;21(4):264-6. <https://doi.org/10.4103/0971-3026.90684> PMID:22223936
9. Laohawiriyakamol T, Tanutit P, Kanjanapradit K, Hongsakul K, Ehara S. The "dot-in-circle" sign in musculoskeletal mycetoma on magnetic resonance imaging and ultrasonography. *Springerplus.* 2014;3:671. <https://doi.org/10.1186/2193-1801-3-671> PMID:25485205
10. Siddig ED, Fahal AH. Histopathological approach in diagnosis of mycetoma causative agents: A mini review. *J Cytol Histol.* 2017;8(3):1-3.
11. Zijlstra EE, van de Sande WW, Fahal AH. Mycetoma: A long journey from neglect. *PLoS Negl Trop Dis.* 2016;10(1):e0004244. <https://doi.org/10.1371/journal.pntd.0004244> PMID:26797103
12. Alam K, Maheshwari V, Bhargava S, Jain A, Fatima U, Haq EU. Histological diagnosis of Madura foot (mycetoma): A must for

- definitive treatment. *J Glob Infect Dis.* 2009;1:64-7. <https://doi.org/10.4103/0974-777X.52985>
PMid:20300390
13. Estrada R, Lopez GC, Chavez GE, Martinez RL, Welsh O. Eumycetoma. *Clin Dermatol.* 2012;30(4):389-96. <https://doi.org/10.1016/j.clindermatol.2011.09.009>
PMid:22682186
14. Schibli A, Goldenberger D, Krieg A, Hirschmann A, Bruder E, Osthoff M. Painless swelling of the forefoot and recurrent subcutaneous abscesses of the lower leg-Two distinct presentations illustrating the spectrum of eumycetoma in a nonendemic country. *PLoS Negl Trop Dis.* 2017;11(4):e0005360. <https://doi.org/10.1371/journal.pntd.0005360>
PMid:28406907
15. Fahal AH, Rahman IA, El-Hassan AM, Rahman ME, Zijlstra EE. The safety and efficacy of itraconazole for the treatment of patients with eumycetoma due to *Madurella mycetomatis*. *Trans R Soc Trop Med Hyg.* 2011;105:127-32. <https://doi.org/10.1016/j.trstmh.2010.11.008>
PMid:21247608