




Severe Respiratory Failure from SARS-CoV-2, Complicated with Pneumothorax in a Pregnant Woman: A Case Report

Najada Como¹, Nevila Gjermeni^{1*}, Esmeralda Meta¹, Dhimiter Kraja¹, Zamira Hysenaj², Renato Osmenaj³, Fadil Gradica⁴, Mirela Rexhepi⁵, Artan Mesi⁶

¹Infectious Disease Service, University Hospital Centre "Mother Theresa", Tirana, Albania; ²Intensive Care Unit, University Hospital Centre "Mother Theresa", Tirana, Albania; ³Radiology Unit, University Hospital Centre "Mother Theresa", Tirana, Albania; ⁴Thoracic Surgery Unit, University Hospital of Pulmonary Diseases, Tirana, Albania; ⁵Department of Pharmaceuticals, University Hospital Centre "Mother Theresa", Tirana, Albania; ⁶National Professional Officer, WHO Country Office, Tirana, Albania

Abstract

Edited by: Ksenija Bogoeva-Kostovska
Citation: Como N, Gjermeni N, Meta E, Kraja D, Hysenaj Z, Osmenaj R, Gradica F, Rexhepi M, Mesi A. Severe Respiratory Failure from SARS-CoV-2, Complicated with Pneumothorax in a Pregnant Woman: A Case Report.

Open-Access Maced J Med Sci. 2022 May 26; 10(C):217-221. <https://doi.org/10.3889/oamjms.2022.8967>

Keywords: COVID-19; Pregnancy; Pneumothorax; Severe form; Cesarean section

***Correspondence:** Nevila Gjermeni, Infectious Disease Service, University Hospital Centre "Mother Theresa", Tirana, Albania. E-mail: nevilagjermeni@yahoo.com

Received: 11-Feb-2022

Revised: 12-May-2022

Accepted: 16-May-2022

Copyright: © 2022 Najada Como, Nevila Gjermeni, Esmeralda Meta, Dhimiter Kraja, Zamira Hysenaj, Renato Osmenaj, Fadil Gradica, Mirela Rexhepi, Artan Mesi

Funding: This research did not receive any financial support

Competing Interest: The authors have declared that no competing interest exists

Open Access: This is an open-access article distributed under the terms of the Creative Commons Attribution-NonCommercial 4.0 International License (CC BY-NC 4.0)

INTRODUCTION: The first data for COVID-19 in pregnancy showed mild-to-moderate forms of the disease while the current data speak of severe forms in these subjects. Here, we present a case of a severe form of COVID-19 in a gemelar pregnant woman complicated with pneumomediastinum and pneumothorax, during her hospital stay, in a late stage of disease.

CASE PRESENTATION: A 38-year-old multiparous woman was referred to university hospital at 25 weeks of gemelar pregnancy. On admission, the patient presented with signs of moderate respiratory insufficiency, which after 12 h progressed further to severe ARDS. She tested positive for SARS-CoV-2 on quantitative real-time polymerase chain reaction. Under these conditions, it was decided that the patient undergoes a cesarean section for termination of pregnancy. Remdesivir 200 mg/day and tocilizumab 8 mg/kg were administered, based on national guidelines. The patient's fever subsided, but her SpO₂ remained at 94%, even with a 15 L/min oxygen mask. After 12 days, the patient complains of a severe back pain and her respiratory condition rapidly worsened and reduced saturations up to 80% being under O₂ therapy with facial mask with 15 l/min. Chest CT findings confirmed pneumomediastinum and pneumothorax, which deteriorated the patient's status. Thereafter, tube thoracostomy was performed. There was a clinical and ABG analysis parameter's improvement. The patient was discharged 34 days after cesarean delivery with a proper general health.

CONCLUSION: Our case highlights even more convincingly the fact that, in pregnancy, can be severe to life-threatening forms of COVID-19. Pneumothorax and pneumomediastinum are complications that can be encountered even in the late stages of severe forms cases with COVID-19 in pregnancy. Early diagnosis of these complications is essential in adequate management and treatment to avoid fatal outcome.

Introduction

COVID-19 is a serious public health emergency and it seems particularly deadly in vulnerable populations. Pregnant women and their fetuses represent a high-risk population during infectious disease outbreaks [1]. Physiological and mechanical changes in pregnancy increase susceptibility to infections in general, particularly when the cardiorespiratory system is affected, and encourage rapid progression to respiratory failure [1], [2]. The first data for COVID-19 in pregnancy showed mild-to-moderate forms of the disease in this subject [3], [4], while the current data speak of severe forms up to threatening complications for pregnant women diagnosed as having coronavirus disease 2019 [5], [6].

Patients who are pregnant may present with atypical features such as the absence of fever as well as leukocytosis [3], while dyspnea and severe back pain are mainly manifestations of its complicated forms.

Pneumothorax and pneumomediastinum are rare complications of severe forms of COVID-19 in pregnant women [7], [8].

Here, we present a case of a severe form of COVID-19 in a gemelar pregnant woman complicated with pneumomediastinum and pneumothorax in a late stage of disease, during her hospital stay.

Case Presentation

A 39-year-old multiparous woman was referred to university hospital at 25 weeks of gemelar pregnancy. The patient had a 7-day history of fever, cough, asthenia, and dyspnea. She tested positive for SARS-CoV-2 on quantitative real-time polymerase chain reaction.

On admission, the patient's respiratory rate 37 breaths/min, blood pressure 118/62, pulse

was 105 beats/min, and temperature 38.9°C. Her saturation O₂ (SpO₂) was 91% (room air). During episodes of coughing, her oxygen saturation fell to SpO₂ 88%, but with 6–7 L of oxygen on mask, the saturation rose to 95%. We perform a CT scan by applying an abdominal lead shielding to reassure patients of risks of scatter radiation to the fetus. A chest computed tomography (CT) scan revealed bilateral multifocal ground-glass opacities with partial consolidation, corresponding to COVID-19 pneumonia (Figure 1).

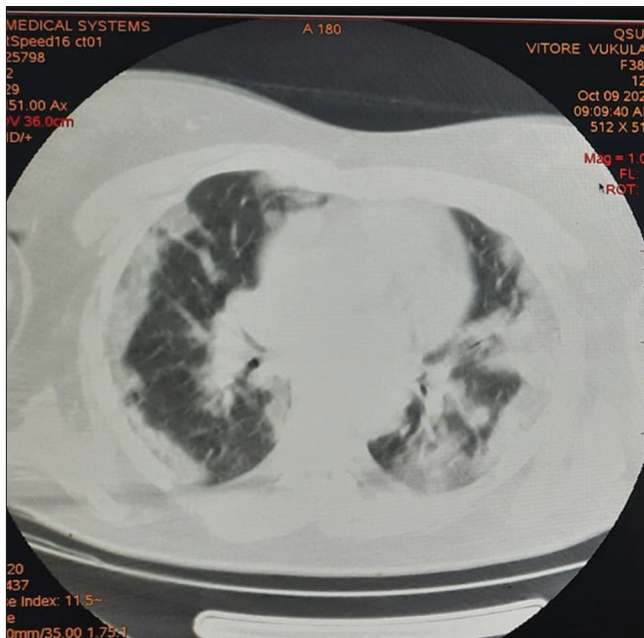


Figure 1: Chest CT scan multifocal ground-glass opacities with partial consolidation

Laboratory data showed a white blood cell count of 4900/ μ L, lymphocyte 12.4%, C-reactive protein 3.3 mg/dL, ferritinemia 4320 ug/ml, and D-dimer 2.24 μ g/mL (<1.0 μ g/mL).

We put her immediately under the treatment with dexamethasone 12 mg/day, heparin sodium 10,000 U/day, and imipenem 3 g/day which were initiated. For about 12 h after admission, the patient was afebrile but her dyspnea worsened. SpO₂ was 95% with a 15 L/min oxygen flow through facial mask. Arterial blood gas (ABG) analyzer shows PaO₂ 58%, PaCO₂ 35%; Sat O₂ 95%, and FiO₂/PaO₂=155.

In these conditions we knew that delivery might decrease maternal oxygen consumption and improve lung mechanics. In addition, it would be easier to manage the patient's breathing after delivery, an emergency cesarean section was performed under spinal anesthesia, and two male infants were delivered with an Apgar score of 6/8.

The newborns were intubated and admitted to the neonatal ICU. Remdesivir 200–100 mg/day and tocilizumab 8 mg/kg, and methylprednisolone 1–2 mg/kg were administered, based on national guidelines. The patient's fever subsided, but her SpO₂ remained at

94%–95%, even with a 10 L/min oxygen mask on the day after the cesarean section.

The patient's respiratory condition deteriorated, and pneumonia findings on chest CT had worsened, showing rapidly increased consolidation

We put her under non-invasive mechanical ventilation, continuous positive airway pressure (CPAP), FiO₂ 50%, and PEEP 6 for 60 min. The patient's respiratory condition quickly improved; she was successfully taken off non-invasive mechanical ventilation the other day, her ABG analysis improved from PO₂ 56% to PO₂ 68% (Table 1).

ABG analysis is shown in Table 1.

After 12 days, the patient complains of a severe back pain and her respiratory condition rapidly worsened and reduced saturations up to 80% being under O₂ therapy with facial mask with 15 l/min. Chest CT findings confirmed pneumothorax (Figure 2), which deteriorated the patient's status.

Thereafter, tube thoracostomy was performed. An X-ray was performed before and 4 h after clamping the chest tube, which was removed after 12 days (Figures 3 and 4).

One of the infants died 2 weeks after birth, while the other who is about 6 weeks old continues to be intubated.

Nasal swabs for SARS-CoV-2 were negative at 24 and 60 h postpartum.

The patient was discharged 34 days after cesarean delivery with a proper general health.

Discussion

Pregnant women may be at an increased risk of illness from COVID-19 compared with non-pregnant women. Preexisting comorbidities, high maternal age, and high body mass index seem to be risk factors for severe COVID-19 [6], [9]. Our case had not preexisting comorbidities, but she had two risk factors (high maternal age, she was 39 years old and her body mass index 32.5 kg/m²), which may explain the severity of disease in this pregnant woman. Rates of preterm birth are higher in pregnant women with COVID-19 than in pregnant women without the disease [6]. Maternal deaths due to COVID-19 have been reported in the second or third trimesters [10], [11]. Accordingly, our patient was on the border between the second and third trimesters, which have a high risk of mortality in severe forms of COVID-19 just like our patient, and in addition this was her fourth pregnancy in a multiparous mother. In these conditions, as the risk was high for both premature birth and maternal mortality, it was decided in a joint consultation between infectologists, obstetricians,

Table 1: ABG analysis

ABG	Patient's ABG on admission	12 h before the section cesarean	1 h after the section cesarean	24 h after the section cesarean	48 h after the section cesarean	12 days after the section cesarean	4 h after draining	10 days after draining	30 days from the beginning of the disease	35 days from the beginning of the disease
pH	7.322	7.4	7.46	7.39	7.41	7.43	7.41	7.45	7.47	7.41
PaO ₂	65.2 mm/Hg	58.6	72.3	56.5	68.4	53.1	62.8	69.4	72	76%
PCO ₂	38.3 mm/Hg	37.4	35.4	38.3	40.0	38.4	35.1	36.3	34	38%
cHCO ₃	30.0 mmol/L	28.2	32.1	31.7	28.2	27.6	33.0	28.5	32	28 mmol/L
BE	5.6 mmol/L	4.8	4.5	3.9	2.3	2.4	3.2	2.9	1.9	2.3 mmol/L
SO ₂	95%	94	95	80	92	82	90	93	94	94%
	6-7 l/min	15 l/min	15 l/min	Under O ₂ therapy 15 l/min. The patient has to be placed under CPAP FiO ₂ 50% PEEP6 for 60 min	15 l/min	15 l/min performed chest CT scan which evidenced massive Pnx	12 l/min	10 l/min	5-6 l/min	In the room air

ABG: Arterial blood gas.

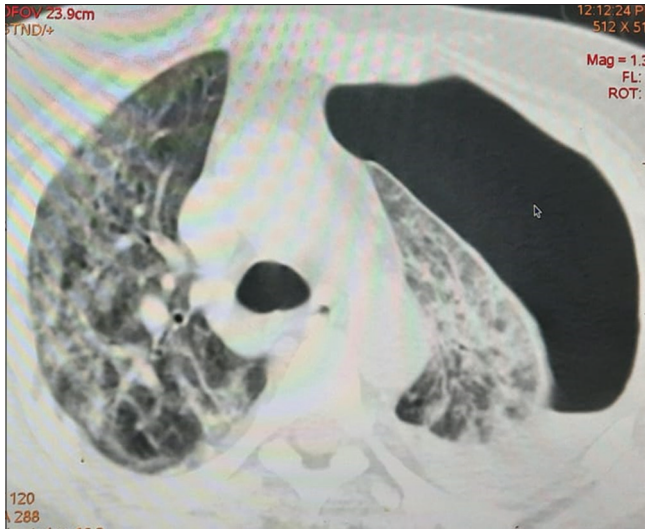


Figure 2: Chest CT findings that confirmed pneumothorax

and anesthetists to terminate the pregnancy with a cesarean section under spinal anesthesia.

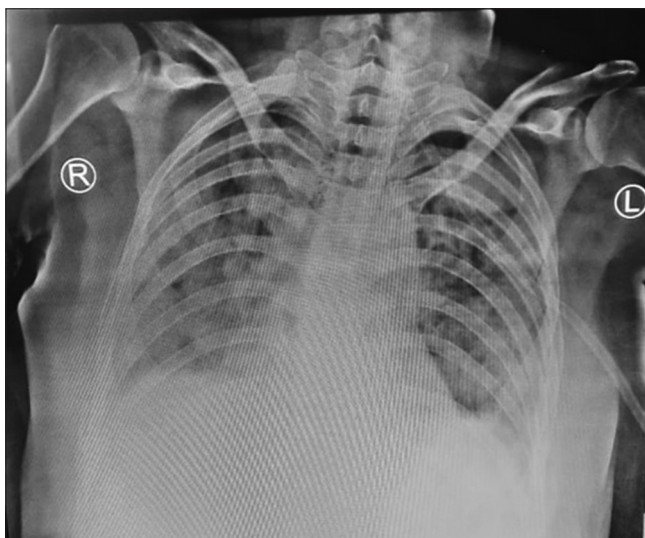

Figure 3: Chest X-ray findings confirmed

Pregnant women with COVID-19 who experience respiratory failure present multiple management challenges, one of which is the decision to terminate the pregnancy even at a young gestational age where the risk to the fetus is high, as in our case (25 weeks).

In severe form of the disease, where the life of mother and consequently of the fetus are threatened, while termination of pregnancy can improve or facilitate respiratory function by reducing decompression, make us think that the decision for cesarean termination of pregnancy in these cases should be made and implemented quickly in time.

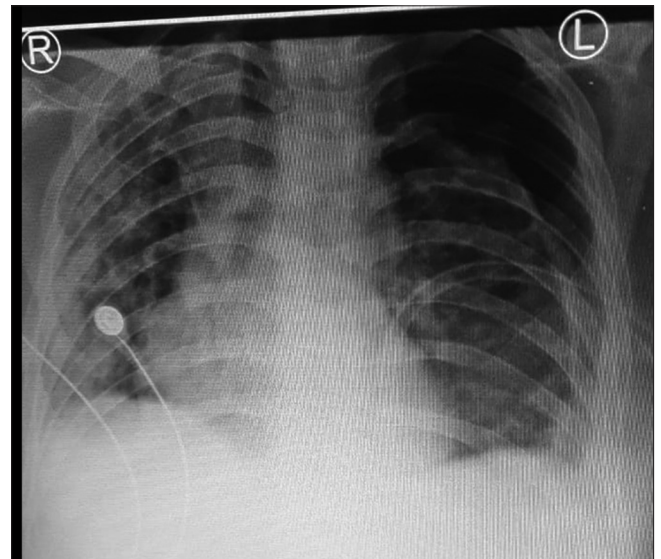


Figure 4: Chest X-ray, after tube pneumothorax thoracostomy was performed

When a pregnant woman with COVID-19 desaturates, there are multiple etiopathologies: Exacerbation of viral pneumonia, ARDS, overlap of a bacterial pneumonia, systemic inflammatory response syndrome, peripartum cardiomyopathy, viral myocarditis, and non-cardiogenic pulmonary edema (hypertensive and non-hypertensive pulmonary edema). Morbid manifestations of COVID-19 such as severe pneumonia, ARDS, and multiorgan dysfunction syndrome (MODS) require advanced ventilatory support. Especially pulmonary causes of desaturation are more difficult to manage as they may require prolonged mechanical ventilation [2], [3]. Knowing the P-F ratio which is the ratio between PaO₂ and fraction of inspired oxygen (FiO₂) is useful in predicting the degree of lung compromise [12] and to determine the severity and the evolutionary stage of the disease, thus helping in the selection of adequate pathogenetic and supportive treatment in a timely manner.

Our case had three moments of rapidly desaturations:

The first 12 h after hospitalization was associated with high systemic inflammatory response syndrome and exacerbation of viral pneumonia, complicated by severe ARDS in this early acute stage of the disease;

The second, deterioration after cesarean delivery, which has been evidenced also by other authors, may be related to re-expansion of the lungs and increased blood volume in the reflux circulation after delivery [2], [13]. In our case in the second deterioration, we did not put the patient under mechanical ventilation, instead of it we use non-invasive mechanical ventilation (CPAP), 60 min sessions with CPAP, Fi O₂ 50%, PEEP 6, 5 times a day, and 5 sessions in total after which we had a significant clinical and laboratory improvement.

The third episode of deterioration, 12 days after cesarean delivery, is associated with the presence of pneumomediastinum and pneumothorax. These are complications that other authors also talk about [7], [8], [14], [15]. The data so far on complications such as pneumothorax and pneumomediastinum in the same time in COVID 19 in pregnancy are in the form of case reports, and moreover, we have not identified any published case of occurrence of both of these complications in the late stage of severe form in these subjects.

Conclusion

Our case highlights even more convincingly the fact that, in pregnancy, can be severe to life-threatening forms of COVID-19, where cesarean delivery is indicated to give the mother and infant the maximum chance of survival. Pneumothorax and pneumomediastinum are complications that can be encountered even in the late stages of severe forms of COVID-19 in pregnant woman. Early diagnosis of these complications is essential in adequate management and treatment to avoid fatal outcome.

References

- Dashraath P, Wong JL, Lim MX, Lim LM, Li S, Biswas A, *et al.* Coronavirus disease 2019 (COVID-19) pandemic and pregnancy. *Am J Obstet Gynecol.* 2020;222(6):521-31. <https://doi.org/10.1016/j.ajog.2020.03.021> PMID:32217113
- Chinena Y, Kinjyo Y, Mekaru K, Kinjo T, Higure Y, Kinjo T, *et al.* Critical respiratory failure in pregnancy complicated with COVID-19: A case report. *Case Rep Womens Health.* 2021;30:00309. <https://doi.org/10.1016/j.crwh.2021.e00309> PMID:33777708
- Ashokka B, Loh MH, Tan CH, Su LL, Young BE, Lye DC, *et al.* Care of the pregnant woman with COVID-19 in labor and delivery: Anesthesia, emergency cesarean delivery, differential diagnosis in the acutely ill parturient, care of the newborn, and protection of the healthcare personnel. *Am J Obstet Gynecol.* 2020;223(1):66-74.e3. <https://doi.org/10.1016/j.ajog.2020.04.005> PMID:32283073
- Chen H, Guo J, Wang C, Luo F, Yu X, Zhang W, *et al.* Clinical characteristics and intrauterine vertical transmission potential of COVID-19 infection in nine pregnant women: A retrospective review of medical records. *Lancet.* 2020;395(10226):809-15. [https://doi.org/10.1016/S0140-6736\(20\)30360-3](https://doi.org/10.1016/S0140-6736(20)30360-3) PMID:32151335
- Chen L, Li Q, Zheng D, Jiang H, Wei Y, Zou L, *et al.* Clinical characteristics of pregnant women with Covid-19 in Wuhan, China. *N Engl J Med.* 2020;382(25):100. <https://doi.org/10.1056/NEJMc2009226> PMID:32302077
- Allotey J, Stallings E, Bonet M, Yap M, Chatterjee S, Kew T, *et al.* Clinical manifestations, risk factors, and maternal and perinatal outcomes of coronavirus disease 2019 in pregnancy: Living systematic review and meta-analysis. *BMJ.* 2020;370:3320. <https://doi.org/10.1136/bmj.m3320> PMID:32873575
- Rasekhjahromi A, Jafarzadehjahromi Z, Kalani N, Babaarabi ZZ. Spontaneous pneumothorax in a pregnant woman with COVID-19: A case report. *Front Emerg Med.* 2022;6(1):1-9. <https://doi.org/10.18502/fem.v6i1.7681>
- Berdai MA, Benlamkadem S, Labib S, Harandou M. Spontaneous Pneumomediastinum in labor. 2017;2017:6235076. <https://doi.org/10.1155/2017/6235076> PMID:28316849
- Royal College of Obstetricians and Gynaecologists. Coronavirus (COVID-19) Infection in Pregnancy. United Kingdom: Royal College of Obstetricians and Gynaecologists; 2020. p. 460 Available from: https://www.rcog.org.uk/globalassets/documents/guidelines/coronavirus-covid-19-virus461_infection-in-pregnancy-2020-03-09.pdf [Last accessed on 2020 Mar 22].
- Hantoushzadeh S, Shamshirsaz AA, Aleyasin A, Seferovic MD, Aski SK, Arian SE, *et al.* Maternal death due to COVID-19. *Am J Obstet Gynecol.* 2020;223(1):109.e1-16. <https://doi.org/10.1016/j.ajog.2020.04.030> PMID:32360108
- Andrikopoulou M, Madden N, Wen T, Aubey JJ, Aziz A, Baptiste CT, *et al.* Symptoms and critical illness among obstetric patients with coronavirus disease 2019 (COVID-19) infection. *Obstet Gynecol.* 2020;136(2):291-9. <https://doi.org/10.1097/aog.0000000000003996> PMID:32459701
- Zeserson E, Goodgame B, Hess JD, Schultz K, Hoon C, Lamb K, *et al.* Correlation of venous blood gas and pulse oximetry with arterial blood gas in the undifferentiated critically ill patient. *J Intensive Care Med.* 2018;33(3):176-81. <https://doi.org/10.1177/0885066616652597> PMID:27283009
- Dennis AT, Solnordal CB. Acute pulmonary oedema in pregnant women. *Anesthesia.* <https://doi.org/10.1111/j.1365-2044.2012.07055.x>

PMid:22420683

14. Akanni BA, Gold I, Nwafor IA, Eze JC. Management of spontaneous pneumothorax in pregnancy in a low-income country during COVID-19 pandemic. *Niger J Med.* 2021;30(3):20. https://doi.org/10.4103/NJM.NJM_192_20
15. SayitAT, Muzaffer E, Onal M. Spontaneous pneumomediastinum associated with Covid-19 pneumonia in a pregnant woman. *Rev Soc Bras Med Trop.* 2021;54:01852021. <https://doi.org/10.1590/0037-8682-0185-2021>
PMid:34105631