



# Speckle-tracking Echocardiography in Early Diagnosis of Myocardial Dysfunctions of Women with Hypertension in the Perimenopausal Period

Zhanar Balmukhamedova\*, Gulmira Derbissalina, Natalya Zemlyanskaya, Aliya Dzholdasbekova, Dariga Blyalova

Department of General Medical Practice with a Course of Evidence-Based Medicine, NJSC "Astana Medical University", Astana, Kazakhstan

## Abstract

**Edited by:** Igor Spiroski

**Citation:** Balmukhamedova Z, Derbissalina G, Zemlyanskaya N, Dzholdasbekova A, Blyalova D. Speckle-tracking Echocardiography in Early Diagnosis of Myocardial Dysfunctions of Women with Hypertension in the Perimenopausal Period. Open-Access Maced J Med Sci. 2022 Apr 15; 10(B):1176-1182. <https://doi.org/10.3889/oamjms.2022.9027>

**Keywords:** Speckle-tracking echocardiography; Arterial hypertension; Perimenopause

\*Correspondence: Zhanar Balmukhamedova, NJSC "Astana Medical University," Kazakhstan. E-mail: [balmukhamedova.zhanar@gmail.com](mailto:balmukhamedova.zhanar@gmail.com)

**Received:** 17-Feb-2022

**Revised:** 01-Apr-2022

**Accepted:** 05-Apr-2022

**Copyright:** © 2022 Zhanar Balmukhamedova, Gulmira Derbissalina, Natalya Zemlyanskaya, Aliya Dzholdasbekova, Dariga Blyalova

**Funding:** This research did not receive any financial support

**Competing Interest:** The authors have declared that no competing interest exists

**Open Access:** This is an open-access article distributed under the terms of the Creative Commons Attribution-NonCommercial 4.0 International License (CC BY-NC 4.0)

**AIM:** This study aims to evaluate the role of speckle-tracking echocardiography in detecting early myocardial dysfunction of women with arterial hypertension in perimenopausal period.

**MATERIALS AND METHODS:** The study involved 50 women in the perimenopausal period aged 45–55 years. Perimenopause was diagnosed by clinical examination, including a gynecologist and female hormonal status studies. The sample of women was divided into two groups depending on the presence of arterial hypertension. The main group included 24 patients with arterial hypertension diagnosed in the perimenopausal period. The examination methods listed above also included electrocardiography, echocardiography, and speckle-tracking echocardiography.

**RESULTS:** According to the speckle-tracking echocardiography, statistically significant indicators were found in the basal anterior septal and lower basal segments ( $p = 0.016$  and  $0.001$ ). The difference in the left ventricular myocardial mass index was statistically significant in both compared groups ( $p = 0.038$ ). ROC analysis was utilized to assess the quality of the resulting logistic regression model. The area under the ROC curve was  $0.806 \pm 0.065$  (95% CI:  $0.679$ – $0.933$ ,  $p < 0.001$ ). These indicators show a good predictive model.

**CONCLUSION:** In the group women with arterial hypertension, the indicators for the basal anterior septal and basal inferior segments are more sensitive, which can be used as a significant indicator of dysfunction with unchanged indicators of standard echocardiography.

## Introduction

Speckle-tracking echocardiography is a modern and promising technique for assessing structural and functional changes in the myocardium [1], [2]. The index of local and global longitudinal myocardial strain, assessed using speckle-tracking echocardiography, is more sensitive to early changes in the left ventricular contractility, as well as subclinical myocardial dysfunction [3]. The diagnostic capabilities of speckle-tracking echocardiography are reflected in the clinical guidelines of the European Society of Cardiology from 2016 to 2018, the European Association of Cardiovascular Imaging (EACVI), as well as American Society of Echocardiography from 2016 to 2018 [4], [5], [6], [7]. At present, much attention has been focused to the use of speckle-tracking echocardiography in such pathologies as heart failure [8], coronary pathology [9], valvular heart disease [10], the effect of cardiotoxicity during the treatment of oncopathology [11]. One of the areas of the use of speckle-tracking echocardiography in clinical

practice is the study of myocardial function in diseases accompanied by the left ventricular hypertrophy, in particular, in arterial hypertension [12], [13], [14].

The current recommendations of the European Society of Cardiology (ESC) on hypertension emphasize that in patients with this pathology, a worsening of longitudinal strain of the left ventricle, which makes it possible to use this indicator for diagnostic purposes at an early stage of the disease progress [13], [15]. It is important that speckle-tracking echocardiography can be used not only for diagnosis but also for assessing the prognosis of cardiovascular events.

According to the WHO, arterial hypertension is one of the most common non-specific diseases, accounting for 30% of all deaths. According to a number of sources, the prevalence of arterial hypertension in general population in Kazakhstan varies from 15.2 to 27% and among women is about 40% [16].

Understanding the physiological changes that occur in the hearts of women during and after menopause is critical in determining why the incidence of cardiovascular disease increases dramatically

and the outcomes worsen in postmenopausal women [17], [18], [19]. Therefore, the issue of maintaining and improving health states to improve the quality of life and life expectancy of this category of the population is becoming widespread and continues to be relevant.

The main objective of our research is to study the significance of speckle-tracking echocardiography in detecting early changes in the myocardium in women in the perimenopausal period with arterial hypertension. Perimenopause – the period combines premenopause and the 1<sup>st</sup> year after menopause. This period is determined by clinical data as well as the level of hormonal status [20].

## Materials and Methods

The study involved 50 women in perimenopausal period aged 45–55 years. The main group included patients with arterial hypertension diagnosed in the perimenopausal period. The control group consisted of women without arterial hypertension. According to the WHO, arterial hypertension is considered when systolic blood pressure  $\geq 140$  mmHg or diastolic blood pressure  $\geq 90$  mmHg [7], [13]. In addition to the general clinical examination and gynecological history taking, lipid profile, biochemical blood analysis, and hormonal status, all women were examined by echocardiographic examination. Anthropometric indicators such as weight, height, body mass index (BMI), and body surface area (BSA) were determined for all women during the survey. Biochemical analysis of blood was determined on a Mindray blood analyzer, hormones were determined by immunochemiluminescent analysis.

### Inclusion criteria

The following criteria were included in the study:

1. Presence of informed consent.
2. Perimenopausal period diagnosed after consulting a gynecologist.
3. Sinus rhythm on an ECG with a heart rate of 60–90 per min.

### Exclusion criteria

The following criteria were excluded from the study:

1. Surgical menopause, taking menopausal hormone therapy
2. Various endocrine disorders (diabetes mellitus, premature ovarian failure syndrome, polycystic ovary syndrome, thyroid diseases, and hyperlipidemia)
3. Ejection fraction less than 50% on

echocardiography

4. Congenital and acquired heart defects, the presence of acute diseases (acute coronary syndrome, arrhythmias) at the time of inclusion
5. Verified diagnoses of valvular defects, dilated and hypertrophic cardiomyopathy, acute myocardial infarction
6. Taking chemotherapeutic agents and radiation therapy.

### Echocardiography research guideline

Echocardiography was performed for each patient using a GE VIVID E9 ultrasound scanner (USA) available at the Medical Centre Hospital of the President's Affairs Administration of the Republic of Kazakhstan.

Speckle-tracking echocardiography was used to assess the global longitudinal strain and rotation of the left ventricle. Three cycles of sinus rhythm were obtained for the study.

The echocardiographic protocol was consistent with the guidelines for cardiac chamber quantification from the American Society of Echocardiography and the European Association of Cardiovascular Imaging [4], [6]. Echocardiographic measurements were performed by a senior physician who is board certified in echocardiography and was blinded for clinical data and patient results.

The left ventricular ejection fraction and end-diastolic and end-systolic volumes were assessed using modified biplane Simpson's rule. The left ventricular mass and its indexed values (related to body surface area in square meter) were calculated using the formula of Devereux *et al.* [21].

The left ventricular diastolic filling was assessed using pulsed-wave Doppler echocardiography using transmitral flow. The E-wave peak velocity (early filling wave), the transmitted Doppler E-wave deceleration time, and the A-wave peak velocity (late filling wave) were measured. Myocardial velocity in the basal interventricular septum was assessed using pulsed-wave tissue Doppler echocardiography in systole (Sm) and diastole (Em) [4], [22].

The E/Em ratio was calculated as a measure of the left ventricular filling pressure. The Valsalva test was used to assess the pseudonormal type of diastolic myocardial dysfunction. The volume of the left atrium was measured using biplane Simpson method in the apical four-chamber and two-chamber projections and was indexed according to the body surface area [6].

The left ventricle was divided into 16 segments by the software to assess the magnitude and timing of regional myocardial strain in accordance with the American Society of Echocardiography and the European Association of Cardiovascular Imaging

guidelines. Three-dimensional wall movement tracking made it possible to determine simultaneously the total longitudinal, circumferential, and radial systolic strain, as well as the rotation of all 16 segments of the left ventricle. The mean rotation of six basal (anterior, anterior septal, inferior septal, inferior, inferior lateral, and anterior lateral) and four apical (septal, inferior, lateral, and anterior) segments was calculated [4].

The study did not contradict the principles of the Declaration of Helsinki and was approved by the local ethics committee (Minutes No. 1 dated December 19, 2019). All patients signed a voluntary informed consent for the examination.

### Statistical analysis

Statistical analysis was performed using Microsoft Excel 2019, IBM SPSS Statistics for Windows, Version 23.0., USA.

Verification of quantitative signs for normal distribution in each group of patients was carried out using the Shapiro–Wilk test and graphical construction of histograms and normal distribution diagrams.

Depending on the distribution, quantitative indicators were compared using the Student's t-test and the Mann–Whitney U-test. Qualitative characteristics were compared using Pearson's Chi-square test and Fisher's exact test.

To predict the development of arterial hypertension, binary logistic regression was applied. To assess the quality of the obtained model and calculate the separating values of quantitative features, the ROC analysis was used. Indicators with maximum and approximately equal values of sensitivity and specificity were chosen as a cutoff point.

## Results

All 50 women participated in the study in different periods of perimenopause. The average age was  $51.56 \pm 5.27$ . There were no statistically significant differences between the studied groups of women by age ( $p = 0.07$ ). By our sample, the average level of estradiol was  $158 \pm 45.47$  pmol/l and follicle-stimulating hormone (FSH)  $5.2 \pm 1.23$  mIU/ml.

According to Table 1, on anthropometric parameters and the status of the cardiovascular state, there were no statistically significant differences between the study groups. The average BMI of patients was  $28.2 \pm 4.5$  kg/m<sup>2</sup>, which corresponded to overweight state. I degree obesity was observed in 24 (48%) patients, 3 (6%) had II degree obesity, and 1 (2%) had obesity of III degree.

**Table 1: Basic laboratory and anthropometric parameters of patients**

Parameters	Patients in total, n = 50	Group of patients with arterial hypertension, n = 24	Group of patients without arterial hypertension, n = 26	p
Height (cm)	160.42 ± 4.97	159.46 ± 4.05	161.31 ± 5.62	0.186
Weight (kg)	72.58 ± 11.29	74.33 ± 9.34	70.96 ± 12.80	0.296
BMI (kg/m <sup>2</sup> )	28.27 ± 4.58	29.23 ± 3.50	27.39 ± 5.31	0.059
BSA (m <sup>2</sup> )	1.75 ± 0.12	1.76 ± 0.11	1.74 ± 0.13	0.581
Office SBP (mm Hg)	128.0 ± 21.88	148.13 ± 10.92	109.42 ± 8.98	<0.001
Office DBP (mm Hg)	79.80 ± 15.65	93.13 ± 9.19	67.50 ± 8.63	<0.001
Creatinine (mmol/l)	67.42 ± 11.63	68.25 ± 10.25	66.65 ± 12.93	0.630
Cholesterol (mmol/l)	5.41 ± 0.92	5.34 ± 1.07	5.49 ± 0.78	0.571
Triglycerides (mmol/l)	1.54 ± 0.55	1.68 ± 0.58	1.41 ± 0.49	0.085
HDL (mmol/l)	1.62 ± 0.34	1.50 ± 0.34	1.72 ± 0.31	0.020
Total protein (g/l)	71.34 ± 5.75	71.42 ± 6.25	71.27 ± 5.37	0.924

BMI: Body mass index, BSA: Body surface area, office SBP: Office systolic blood pressure, DBP: Diastolic blood pressure, HDL: High-density lipoproteins.

The average cholesterol level was 5.4 mmol/L, the maximum was 8.1 mmol/L, and the minimum was 3.8 mmol/L. A statistically significant indicator in the comparison groups is the level of high-density lipoprotein (HDL), which was higher in the group without hypertension ( $p = 0.020$ ).

We also analyzed the indicators of the performed electrocardiography. All patients had sinus rhythm with the average heart rate of 66 beats/min. According to ECG, 6 (12%) of patients demonstrated a slowdown in intraventricular conduction along the right bundle branch, and 10 (2%) of patients showed impaired repolarization of the anterior wall of the left ventricle.

According to Table 2, it is demonstrated that there was no significant difference between the groups in terms of volumetric parameters of the left atrium and left ventricle. Patients with arterial hypertension in comparison with the group of patients without arterial hypertension had increased left ventricular myocardial mass index ( $87.2$  vs.  $76.1$  g/m<sup>2</sup>). The only statistically significant difference in the compared groups was in the left ventricular myocardial mass index ( $p = 0.038$ ). Concentric remodeling of the left ventricular geometry was observed in 15 (62.5%) patients with arterial hypertension.

**Table 2: Functional and volumetric indicators of echocardiographic examination**

Characteristics/parameters	Patients (total), n = 50	Group of patients with arterial hypertension, n = 24	Group of patients without arterial hypertension, n = 26	p
EDV (ml)	87.70 ± 14.55	89.83 ± 15.38	85.69 ± 13.74	0.320
ESV (ml)	33.78 ± 6.48	34.13 ± 6.30	33.46 ± 6.74	0.721
SV (ml)	54.12 ± 9.49	55.71 ± 10.03	52.65 ± 8.91	0.260
MV (l/min)	34.49 ± 7.25	35.91 ± 7.08	33.18 ± 7.30	0.185
LAV (ml)	48.76 ± 9.31	50.50 ± 8.57	47.15 ± 9.84	0.207
LAVI (ml/m <sup>2</sup> )	27.42 ± 4.66	28.07 ± 4.27	26.81 ± 5.0	0.348
Ascending aorta (mm)	28.87 ± 3.11	29.21 ± 2.99	28.54 ± 3.26	0.464
Sinus of Valsalva (mm)	29.96 ± 2.78	29.83 ± 2.68	30.08 ± 2.93	0.759
RWT	0.43 ± 0.06	0.44 ± 0.07	0.42 ± 0.06	0.300
LVMI, grams/m <sup>2</sup>	81.50 ± 19.04	87.28 ± 18.61	76.16 ± 18.17	0.038
LVM (grams)	143 ± 36.3	151 ± 35.2	135 ± 36.3	0.117
Ejection fraction (%)	62.0 (60.0;63.0)	62.0 (60.0;63.8)	62.0 (60.0;63.0)	0.399

EDV: End-diastolic volume, ESV: End-systolic volume, SV: Stroke volume, MV: Minute volume, LAV Left atrial volume, LAVI: Indexed left atrial volume, RWT: Relative wall thickness, LVMI: Indexed left ventricular mass, LVM: Left ventricular mass.

According to Figure 1 and Table 3, the area under the ROC curve of the correlation between the presence

**Table 3: Indicators of longitudinal strain of the myocardium**

Parameters	Patients (total), n = 50	Group of patients with arterial hypertension, n = 24	Group of patients without arterial hypertension, n = 26	p
GLS_Avg (%)	18.95 (-19.60; -18.28)	-18.50 (-19.40; -18.13)	-19.0 (-19.95; -18.55)	0.061
Basal septal (%)	-18.80 ± 3.476	-17.58 ± 3.374	-19.92 ± 3.236	0.016
Basal inferior (%)	-19.50 (-23.00; -16.75)	-17.50 (-20.00; -15.00)	-22.00 (-24.00; -18.75)	0.001
Mid inferior lateral (%)	-20.00 (-22.25; -17.75)	-19.00 (-21.00; -17.00)	-20.50 (-26.00; -19.00)	0.019

GLS\_Avg: Global longitudinal strain average.

of hypertension and the basal septal segment of the left ventricle was  $0.696 \pm 0.075$  (95% CI: 0.549–0.842,  $p = 0.018$ ). The threshold value of the basal septal segment at the cutoff point was -19.50. When basal septal segment was equal to or higher than this value, a high risk of arterial hypertension was predicted. The sensitivity and specificity of the method were 70.8% and 57.7%, respectively.

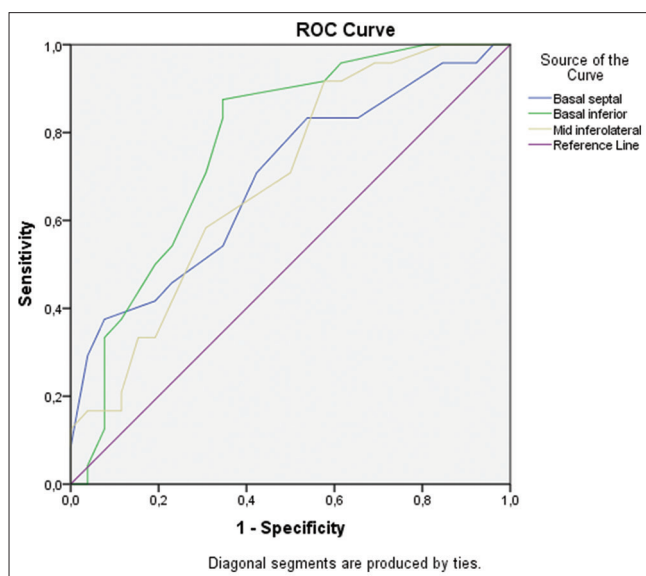


Figure 1: ROC curve of the relationship between arterial hypertension and segments of speckle-tracking echocardiography

The area under the ROC curve of the correlation between the presence of hypertension and inferior basal was  $0.772 \pm 0.068$  (95% CI: 0.639–0.904,  $p = 0.001$ ). The threshold value of the basal inferior segment at the cutoff point was -21.50. When the basal inferior segment was equal to or higher than this value, a high risk of hypertension was predicted. The sensitivity and specificity of the method were 87.5% and 65.4%, respectively.

The area under the ROC curve of the correlation between the presence of hypertension and the mid-lateral segment was AUC  $0.692 \pm 0.074$  (95% CI: 0.547–0.838,  $p = 0.020$ ). The threshold value of the mid-lateral segment at the cutoff point was -20.50. When the mid-lateral segment was equal to or higher than this value, a high risk of arterial hypertension was predicted. The sensitivity and specificity of the method were 70.8% and 50.0%, respectively.

A binary logistic regression was created to determine the probability of patients to belong to a group with hypertension, by introducing 2-basal septal, 4-basal inferior, and 11 mid inferior lateral parameters into the analysis by Wald's stepwise selection method

(Figure 2). As a result, one logistic regression equation was chosen with a correct prediction rate of 80% with a sensitivity of 87.5% and a specificity of 73.1% (Table 4).

$$P = \frac{1}{1 + e^{-z}}, \text{ where } z = 8.226 + 0.197 X_1 + 0.236 X_2$$

Where, 8.226 is a constant;

$X_1$  – the value of the basal septal segment

$X_2$  – the value of the basal inferior segment

The classification threshold in the model (cutoff value) was defined as 0.43. In cases when  $p < 0.43$  was considered after calculations, it was considered that the risk of the presence of hypertension in a patient is higher than its absence.

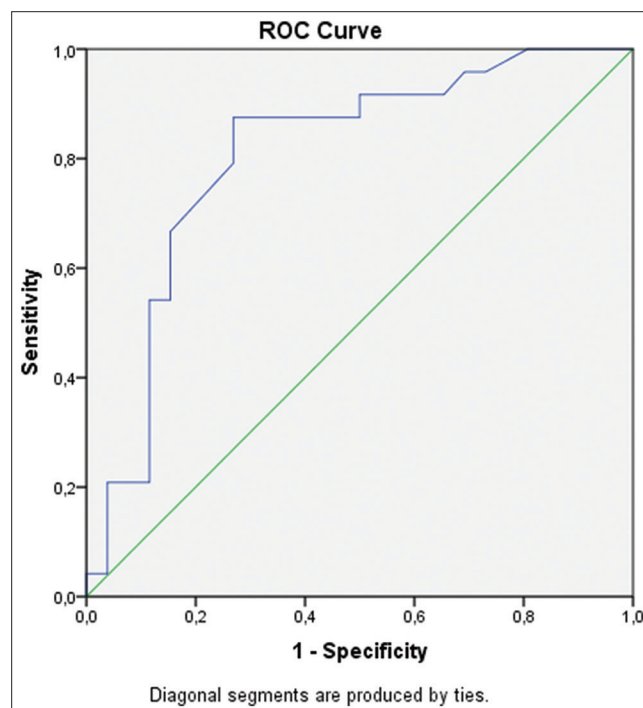


Figure 2: ROC curve of the model for predicting the presence of arterial hypertension according to the result of logical regression

ROC analysis was applied to assess the quality of the resulting logistic regression model.

The area under the ROC curve was  $0.806 \pm 0.065$  (95% CI: 0.679–0.933,  $p < 0.001$ ), which indicates a “very good” predictive quality of the model.

## Discussion

According to the WHO, mortality from cardiovascular pathology is the leading one. The



**Table 4: Results of the step-by-step construction of the logistic regression model**

Step	Value	Variable	Wald's statistics	Standardized regression coefficient	Percentage of correct prediction, %	Odds ratio	p
1	X1	Basal septal	3.974	0.97	73.1	1.217	0.046
2	X2	Basal inferior	7.90	0.236	87.5	1.266	0.008
		Constant = 8.226					0.002

impact of arterial hypertension on morbidity and complication of cardiovascular pathology remains a widely discussed issue. Speckle-tracking echocardiography is a non-invasive imaging modality that helps to objectively and quantify global and regional myocardial function [23]. Global longitudinal strain is the most clinically used parameter in speckle-tracking echocardiography. The clinical advantage of speckle-tracking echocardiography is that it can detect early myocardial dysfunction before any obvious cardiac dysfunction occurs, while traditional echocardiographic parameters such as left ventricular ejection fraction are normal [2].

Arterial hypertension is an ideal model for the assessment of changes in various types of deformities that develop following the development of concentric geometry of the left ventricle (concentric remodeling and concentric left ventricular hypertrophy) [24].

In the present study, perimenopausal women had similar ejection fraction parameters ( $p = 0.399$ ). With normal systolic function, according to speckle-tracking echocardiography in two segments, there were statistically significant changes, mainly in the basal regions.

In their study, Hensel *et al.* demonstrated a decrease in the levels of peak systolic left ventricular strain and strain rate at rest in patients with mild hypertension, while conventional echocardiographic parameters such as ejection fraction and mid-wall fractional shortening remained unchanged in comparison with healthy patients [25].

Tanaka and Hidekazu reported that speckle-tracking echocardiography, sensitive marker of early subtle anomalies of the LV myocardium, useful for predicting outcomes various heart diseases, and exceeds the usual echocardiographic indicators [26]. A prospective study by Chinese scientists presents a detailed deformity analysis to identify different characteristics of circumferential and longitudinal deformity in young people with hypertension. This systolic dysfunction can be easily and accurately detected by speckle-tracking echocardiography in young adults with hypertension [27].

New prognostic and diagnostic data continue to emerge as we continue to apply speckle-tracking echocardiography in a selected group of patients. We would also like to add further study of the left atrial and right ventricular speckle tracing in perimenopausal women.

Speckle-tracking echocardiography has a high sensitivity and specificity and can be used in general

clinical practice as a simple and cost-effective indicator of the risk of subclinical arterial hypertension.

## Conclusion

The routine electrocardiography and echocardiography did not show the effect of arterial hypertension on the left ventricular remodeling in perimenopausal women. Thus, only the use of speckle-tracking echocardiography in the assessment of the systolic function of the left ventricle in patients with arterial hypertension can reveal subclinical changes in the biomechanics of the heart at the stage of the preserved ejection fraction. Analysis of the basal segments of the left ventricle can be a prognostically significant indicator for women in perimenopausal women with the symptoms of arterial hypertension.

## Authors' Contributions

All authors have sufficiently contributed to the study and agreed with the results and conclusions.

## References

1. Hodzic A, Chayer B, Wang D, Porée J, Cloutier G, *et al.* Accuracy of speckle tracking in the context of stress echocardiography in short axis view: An *in vitro* validation study. *PLoS One*. 2018;13(3):0193805. <https://doi.org/10.1371/journal.pone.0193805> PMID:29584751
2. Collier P, Phelan D, Klein A. A test in context: Myocardial strain measured by speckle-tracking echocardiography. *J Am Coll Cardiol*. 2017;69(8):1043-56. <https://doi.org/10.1016/j.jacc.2016.12.012> PMID:28231932
3. Bhamhani A, Mathew A. Comparison of three-dimensional echocardiography and speckle tracking echocardiography in quantification and mapping of intraventricular mechanical dyssynchrony. *Indian Heart J*. 2019;71(3):256-62. <https://doi.org/10.1016/j.ihj.2019.04.006> PMID:31543199
4. Lang RM, Badano LP, Mor-Avi V, Afilalo J, Armstrong A, Ernande L, *et al.* Recommendations for cardiac chamber quantification by echocardiography in adults: An update

- from the American society of echocardiography and the European association of cardiovascular imaging. *J Am Soc Echocardiogr.* 2015;28(1):1-39.e14. <https://doi.org/10.1016/j.echo.2014.10.003>  
PMid:25559473
5. Luke P, Eggett C, Spyridopoulos I, Irvine T. A comparative analysis of British and American society of echocardiography recommendations for the assessment of left ventricular diastolic function. *Echo Res Pract.* 2018;5(4):139-47. <https://doi.org/10.1530/erp-18-0024>  
PMid:30400022
  6. Galderisi M, Cosyns B, Edvardsen T, Cardim N, Delgado V, Di Salvo G, et al. Standardization of adult transthoracic echocardiography reporting in agreement with recent chamber quantification, diastolic function, and heart valve disease recommendations: An expert consensus document of the European association of cardiovascular Imaging. *Eur Heart J Cardiovasc Imaging.* 2017;18(12):1301-10. <https://doi.org/10.1093/ehjci/jex244>
  7. Bakris G, Ali W, Parati G. ACC/AHA Versus ESC/ESH on hypertension guidelines: JACC guideline comparison. *J Am Coll Cardiol.* 2019;73(23):3018-26. <https://doi.org/10.1016/j.jacc.2019.03.507>  
PMid:31196460
  8. Vdovenko DV, Libis RA. The myocardial deformation and diastolic function of the left ventricle in patients with heart failure with preserved left ventricular ejection fraction. *Arter Hypertens.* 2018;24(10):74-80. <https://doi.org/10.18705/1607-419x-2018-24-1-74-80>
  9. Vachalcova M, Valočík G, Kurečko M, Grapsa J, Ali Taha V, Michalek P, et al. The three-dimensional speckle tracking echocardiography in distinguishing between ischaemic and non-ischaemic aetiology of heart failure. *ESC Heart Fail.* 2020;7(5):2297-04. <https://doi.org/10.1002/ehf2.12766>  
PMid:32558395
  10. Baumgartner H, Hung J, Bermejo J, Chambers JB, Edvardsen T, Goldstein S, et al. Recommendations on the echocardiographic assessment of aortic valve stenosis: A focused update from the European association of cardiovascular imaging and the American society of echocardiography. *Eur Heart J Cardiovasc Imaging.* 2017;18(3):254-75. <https://doi.org/10.1093/ehjci/jew335>  
PMid:28363204
  11. Quintana RA, Bui LP, Moudgil R, Palaskas N, Hassan S, Abe JI, et al. Speckle-tracking echocardiography in cardio-oncology and beyond. *Tex Heart Inst J.* 2020;47(2):96-107. <https://doi.org/10.14503/THIJ-18-6736>  
PMid:32603473
  12. Neisius U, Myerson L, Fahmy AS, Nakamori S, El-Rewaify H, Joshi G, et al. Cardiovascular magnetic resonance feature tracking strain analysis for discrimination between hypertensive heart disease and hypertrophic cardiomyopathy. *PLoS One.* 2019;14(8):0221061. <https://doi.org/10.1371/journal.pone.0221061>  
PMid:31433823
  13. Shavarova EK, Kobalava ZD, Yezhova NE, Khomova IA, Bazdyreva EI, et al. Early structural and functional left ventricular disorders in young patients with hypertension: A role of insulin resistance. *Russ J Cardiol.* 2020;25(3):33-41. <https://doi.org/10.15829/1560-4071-2020-3-3774>
  14. Teixeira R. Three-dimensional speckle tracking echocardiography: The future is now. *Rev Port Cardiol.* 2018;37(4):339-40. <https://doi.org/10.1016/j.repc.2018.03.008>  
PMid:29685849
  15. Williams B, Mancia G, Spiering W, Rosei EA, Azizi M, Burnier M, et al. 2018 ESC/ESH guidelines for the management of arterial hypertension. *Eur Heart J.* 2018;39(33):3021-104. <https://doi.org/10.1093/eurheartj/ehy339>  
PMid:30165516
  16. Bekbergenova ZH, Derbissalina G, Umbetzhanova A, Koikov V, Bedelbayeva G. Evaluating the effectiveness of a screening program for cardiovascular diseases in Kazakhstan. *Eur J Public Health.* 2019;29(Suppl 4):299. <https://doi.org/10.1093/eurpub/ckz186.229>
  17. Wenger NK, Arnold A, Merz CN, Cooper-DeHoff RM, Ferdinand KC, Fleg JL, et al. Hypertension across a woman's life cycle. *J Am Coll Cardiol.* 2018;71(16):1797-813. <https://doi.org/10.1016/j.jacc.2018.02.033>  
PMid:29673470
  18. Pollow DP, Romero-Aleshire MJ, Sanchez JN, Konhilas JP, Brooks HL, et al. ANG II-induced hypertension in the VCD mouse model of menopause is prevented by estrogen replacement during perimenopause. *Am J Physiol Regul Integr Comp Physiol.* 2015;9(12):1546-52. <https://doi.org/10.1152/ajpregu.00170.2015>  
PMid:26491098
  19. Harvey RE, Coffman KE, Miller VM. Women-specific factors to consider in risk, diagnosis and treatment of cardiovascular disease. *Womens Health (Lond).* 2015;11(2):239-57. <https://doi.org/10.2217/whe.14.64>  
PMid:25776297
  20. Inwald EC, Albring C, Baum E, Beckermann M, Bühling KJ, Emons G, et al. Perimenopause and postmenopause-diagnosis and interventions. Guideline of the DGGG and OEGGG (S3-Level, AWMF registry number 015-062, September 2020. *Geburtshilfe Frauenheilkd.* 2021;81(6):612-36. <https://doi.org/10.1055/a-1361-1948>  
PMid:34168377
  21. Jafary FH. Devereux formula for left ventricular mass-be careful to use the right units of measurement. *J Am Soc Echocardiogr.* 2007;20(6):783. <https://doi.org/10.1016/j.echo.2007.02.034>  
PMid:17543757
  22. Nagueh F, Smiseth OA, Appleton CP, Byrd 3<sup>rd</sup> BF, Dokainish H, Edvardsen T, et al. Recommendations for the evaluation of left ventricular diastolic function by echocardiography: An update from the American society of echocardiography and the European association of cardiovascular imaging. *J Am Soc Echocardiogr.* 2016;29(4):277-314. <https://doi.org/10.1016/j.echo.2016.01.011>  
PMid:27037982
  23. Davis AM, Adams D, Venkateshvaran A, Alenezi F. Speckle tracking strain echocardiography: What sonographers need to know. *J Indian Acad Echocardiogr Cardiovasc Imaging.* 2017;1(2):133-9.
  24. Breetveld NM, Alers RJ, Geerts L, Van Kuijk SM, Van Dijk AP, Van der Vlugt MJ, et al. Low plasma volume and increased pressure load relate to concentric left ventricular remodeling after preeclampsia: A longitudinal study. *J Am Heart Assoc.* 2020;9(19):015043. <https://doi.org/10.1161/JAHA.119.015043>  
PMid:32924785
  25. Hensel KO, Jenke A, Leischik R. Speckle-tracking and tissue-Doppler stress echocardiography in arterial hypertension: A sensitive tool for detection of subclinical LV impairment. *Biomed Res Int.* 2014;2014:472562. <https://doi.org/10.1155/2014/472562>  
PMid:25389528
  26. Tanaka H. Efficacy of echocardiography for differential diagnosis of left ventricular hypertrophy: Special focus on speckle-tracking longitudinal strain. *J Echocardiogr.* 2021;19(2):71-9. <https://doi.org/10.1007/s12574-020-00508-3>

- 
- PMid:33460030
27. Xu L, Wang N, Chen X, Liang Y, Zhou H, *et al.* Quantitative evaluation of myocardial layer-specific strain using two-dimensional speckle tracking echocardiography among young adults with essential hypertension in China. *Medicine*. 2018;97(39):12448. <https://doi.org/10.1097/MD.00000000000012448>  
PMid:30278524