



# The Effectiveness of Curcumin on Transforming Growth Factor- $\beta$ and the Proportion of Liver Fibrosis in Deutschland Denken Yoken Mice with Common Bile Duct Ligation

Prathita Amanda<sup>1</sup> , Erik Prabowo<sup>2</sup> , Muflihatul Muniroh<sup>3</sup> , Abdul Mughni Rozy<sup>2</sup> , Neni Susilaningsih<sup>4\*</sup> 

<sup>1</sup>Department of General Surgery, Faculty of Medicine, Universitas Diponegoro, Dr. Kariadi General Hospital, Semarang, Indonesia; <sup>2</sup>Department of Digestive Surgery, Faculty of Medicine, Universitas Diponegoro, Semarang, Indonesia; <sup>3</sup>Department of Physiology, Faculty of Medicine, Universitas Diponegoro, Semarang, Indonesia; <sup>4</sup>Department of Anatomy Histology, Faculty of Medicine, Universitas Diponegoro, Semarang, Indonesia

## Abstract

**BACKGROUND:** Curcumin has been associated to reduce liver fibrosis damage.

**AIM:** For this purpose, transforming growth factor (TGF- $\beta$ ) and proportion of liver fibrosis were assessed.

**METHODS:** A total of 75 male Deutschland Denken Yoken mice models were included in 15 treatment groups. The treatment and positive control groups were given curcumin, ursodeoxycholic acid (UDCA), and a combination of curcumin and UDCA. Common bile duct ligation was performed 7 days after the treatment following the histopathology examination of the liver on days 7, 14, and 21.

**RESULTS:** Curcumin decreased the expression of TGF- $\beta$  compared to the positive control group ( $p < 0.001$ ). It also reduces the expression of TGF- $\beta$  compared to UDCA but without any significant differences ( $p = 0.755$ ;  $p = 0.701$ ; and  $p = 0.677$ ), and combination group ( $p = 0.204$ ;  $p = 0.549$ ; and  $p = 0.276$ ). Curcumin also reduces the proportion of liver fibrosis compared to UDCA but without any significant differences ( $p = 0.825$ ;  $p = 0.199$ ; and  $p = 0.915$ ), and combination group ( $p = 0.859$ ,  $p = 0.328$ , and  $p = 0.076$ ).

**CONCLUSIONS:** Curcumin has the ability on reducing the expression of TGF- $\beta$  and the proportion of liver fibrosis. It can be suggested that curcumin almost has the same effectiveness as UDCA.

**Edited by:** Ksenija Bogoeva-Kostovska

**Citation:** Amanda P, Prabowo E, Muniroh M, Rozy AM, Susilaningsih N. The Effectiveness of Curcumin on Transforming Growth Factor- $\beta$  and the Proportion of Liver Fibrosis in Deutschland Denken Yoken Mice with Common Bile Duct Ligation. Open Access Maced J Med Sci. 2022 Jun 10; 10(A):1157-1163. https://doi.org/10.3889/oamjms.2022.9152

**Keywords:** Curcumin; Ursodeoxycholic acid; Common bile duct ligation; Liver fibrosis

**\*Correspondence:** Neni Susilaningsih, Department of Anatomy Histology, Faculty of Medicine, Universitas Diponegoro, Semarang, Indonesia. E-mail: nsusilaningsih@gmail.com

**Received:** 22-Feb-2022

**Revised:** 28-May-2022

**Accepted:** 31-May-2022

**Copyright:** © 2022 Prathita Amanda, Erik Prabowo, Muflihatul Muniroh, Abdul Mughni Rozy, Neni Susilaningsih

**Funding:** This research did not receive any financial support

**Competing Interests:** The authors have declared that no competing interests exist

**Open Access:** This is an open-access article distributed under the terms of the Creative Commons Attribution-NonCommercial 4.0 International License (CC BY-NC 4.0)

## Study highlights

- There is a lack of evidence about the effectiveness of curcumin in managing liver fibrosis based on transforming growth factor (TGF)- $\beta$  and proportion of liver fibrosis
- Curcumin has similar effectiveness as ursodeoxycholic acid (UDCA) in decreasing TGF- $\beta$  expression
- The proportion of fibrosis is lower in the curcumin group although no significant differences compared to UDCA as the standard treatment
- TGF- $\beta$  has a sufficient correlation with the proportion of liver fibrosis on day 14 and a strong correlation with the proportion of fibrosis on day 21.

## Introduction

Liver fibrosis is a frequent and potentially life-threatening complication associated with most chronic liver diseases causing a high medical and economic burden [1]. Based on numerous experimental and clinical data showing the important role of reactive oxygen species and cholestasis produced by a biliary obstruction in the pathogenesis of liver damage [2].

The pivotal process of fibrogenesis is the interaction of many different soluble mediators (cytokines and chemokines) and various hepatic cellular subsets and their infiltration which is further modulated by the chemical and biological properties of the disease-causing agents. Liver fibrosis is characterized by the formation and deposition of excess fibrous connective tissue, leading to progressive architectural tissue

remodeling [1]. In response to hepatic damage, hepatic stellate cells which take charge of hepatic extracellular matrix secretion and deposition, are activated [3]. The following process is myofibroblast differentiation and stimulates the production of extracellular matrix, which leads to fibrosis and ultimately to hepatic failure [4]. It strongly suggests that this process has an association with the transforming growth factor- $\beta$  (TGF- $\beta$ ) signaling pathway. The TGF- $\beta$ /Smad signaling pathway is activated by TGF- $\beta$  binding to its receptors located on the cell membrane [3], [5].

Antioxidant compounds have been used to protect the liver and hepatocytes from reactive oxygen and are currently being investigated as therapeutic strategies in various liver pathologies. Natural products provide a new lead that can be used in treating different types of diseases including liver diseases. Curcumin, a polyphenol is an active compound found in the perennial plant *Curcuma longa* [6]. It has been associated with the inhibition of lipid peroxidation, free radical formation, and DNA damage under the role of radical scavengers and/or antioxidants [7]. It is also known that curcumin reduces liver fibrosis damage through inhibition of the TGF- $\beta$ 1/SMAD pathway [8].

Some previous studies have shown that ursodeoxycholic acid (UDCA) is also effective for the treatment of cholestasis, even representing as the standard therapy for many types of cholestasis [9]. Many studies show that UDCA can activate anti-apoptotic pathways and maintain cellular structures such as plasma membranes and mitochondria, and prevent hepatocyte damage from bile acids that result in inflammation and damage mitochondrial function [10]. However, until now there has been no study comparing the effectiveness of curcumin and UDCA by looking at the expression of TGF- $\beta$ .

Common bile duct ligation in rodents has been carried out as the experimental procedure on many researches for decades. This procedure induced a high yield of fibrosis in mice with morphological changes. During cholestasis, bile acids remain retained in the liver parenchyma which causes damage to hepatocytes and triggers inflammatory mechanisms [11]. This study is designed to determine the effects of curcumin against liver fibrosis induced by common biliary duct ligation. For this purpose, TGF- $\beta$  and proportion of liver fibrosis were assessed.

## Methods

### Chemicals

The curcumin used in this study was purchased from Sigma-Aldrich, St. Louis, MO. The UDCA was

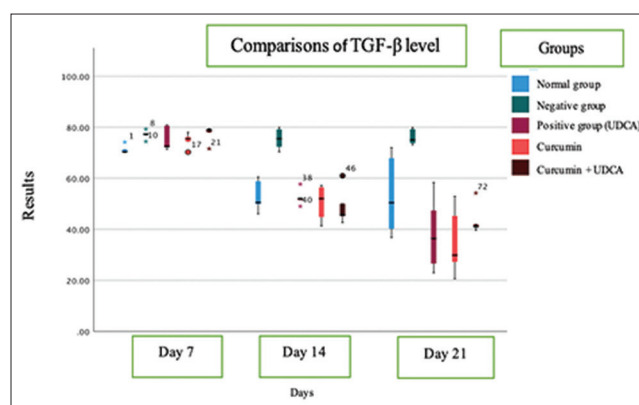


Figure 1: Expression of transforming growth factor- $\beta$  in all groups, data presented as mean  $\pm$  standard deviation

purchased from Novell Pharmaceutical Company, Bogor.

### Animals and induction

10 weeks old male Deutschland Denken Yoken mice (250  $\pm$  50 g) were kept under room temperature 22  $\pm$  2°C. The procedure of animal care was accepted by the Animal Care Ethics Committee of Universitas Diponegoro. Cholestasis was induced by performing common bile duct ligation until 7 days after the treatment.

### Experimental design

Mice were divided into 15 groups: Cholestasis-induced mice receiving carboxymethylcellulose (0.5 ml/day) for 7, 14, and 21 consecutive days; cholestasis-induced mice receiving curcumin (200 mg/kg/day, orally) for 7, 14, and 21 consecutive days; cholestasis-induced mice receiving UDCA (80 mg/kg/day, orally); cholestasis-induced mice receiving curcumin + UDCA (200 and 80 mg/kg/day, orally, respectively) for 7, 14, and 21 consecutive days. The expression of TGF- $\beta$  and proportion of fibrosis was measured on days 7, 14, and 21 after the ligation procedure by obtaining the liver sample.

### Assessment of proportion of fibrosis in hepatocytes

Masson trichrome staining technique was used for the analysis of fibroblast accumulation in hepatocytes. Briefly, paraffin-embedded tissue sections were deparaffinized and hydrated, which were then immersed with Bouin's solution in a microwave for 30 s. Following rinsing with distilled water, the sections were stained Weigert's Iron Hematoxylin 1:1 for 10 min and then washed with distilled water. The sections were then stained with Biebrich Scarlet-Acid fuchsin for 10 min. Clean again with distilled water for 30 s then immersed with Phospho-tungstic acid for 5 min.

Move the sections to Aniline Blue for 5–10 min. Drop 1% Acetic acid for 1 min. Rinsed and mounted the sections.

### Immunohistochemistry staining

Formalin-fixed paraffin-embedded tissue sections were deparaffinized and rehydrated in ethanol 100%, 96%, and 70%. Tissue sections were immersed in a peroxidase blocking solution for 10 min. Incubated the sections in prediluted blocking serum 25°C for 10 min then immersed once more in TGF- $\beta$  25°C for 10 min. Washed gently the sections with phosphate buffer saline for 5 min. Incubated the sections with a secondary antibody (conjugated to horseradish peroxidase) 25°C for 10 min. Rinsed again and added peroxidase 25°C followed by incubation for 10 min. A diaminobenzidine-substrate-chromogen 25°C was added to the tissue sections following incubation for 10 min, washing and counterstaining with Masson Trichrome for 3 min. Rinsed with distilled water and a coverslip was placed. Positive immunohistochemistry staining was observed as blue stains under a light microscope.

### Statistical analysis

Analysis was done using SPSS software and all values were presented as means  $\pm$  SD. Normality test was carried out in each group with the Shapiro–Wilk test with a normal or abnormal result. A one-way ANOVA test was used if the data is normal for comparison among the group.  $P \leq 0.05$  was considered to be statistically significant. Meanwhile, a non-parametric hypothesis test such as Kruskal–Wallis was used in comparative analysis. *Post-hoc* least significant difference test was used on paired group comparative analysis (per group at the time of sampling on 7<sup>th</sup>, 14<sup>th</sup>, and 21<sup>st</sup> days after ligation). In addition, the correlation test between the expression level of TGF- $\beta$  and the proportion of fibrosis was also carried out using the Pearson or Spearman statistical test.

## Results

### The effects of curcumin on TGF- $\beta$ compared to the positive control group on days 7, 14, and 21

In cholestasis-induced mice, the expression of TGF- $\beta$  remained high on the positive control group (Table 1 and Figure 1). Meanwhile, the administration of curcumin significantly decreased the expression of TGF- $\beta$  as determined by immunohistochemistry. As it is shown in Figure 2, the blue stain indicates the amount of fibroblast.

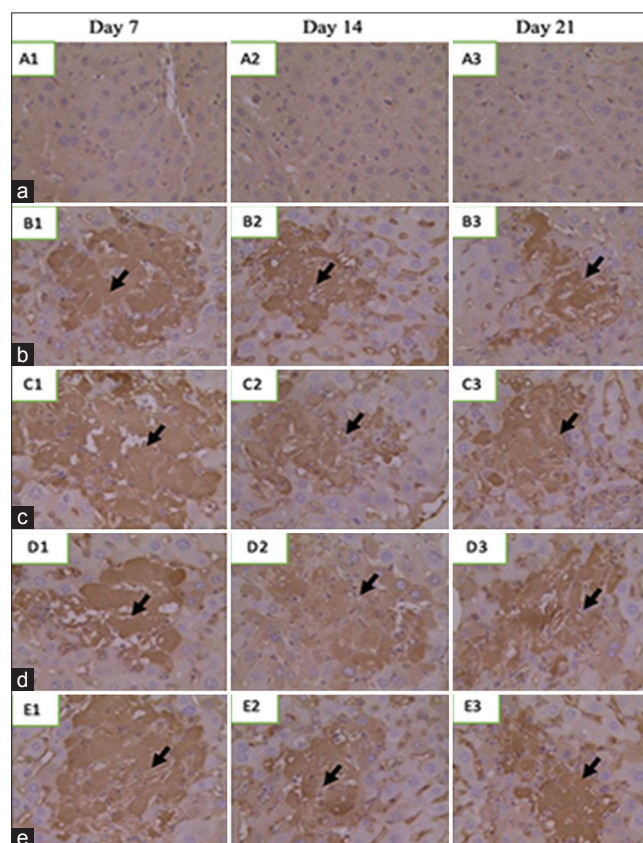
**Table 1: Transforming growth factor- $\beta$  level on days 7, 14 and 21 after common bile duct ligation procedure**

Group	Mean $\pm$ SD	Median (minimum–maximum)
Normal		
Day 7	71.2738 $\pm$ 1.67982	70.3873 (70.20–74.20)
Day 14	53.1462 $\pm$ 6.22818	50.4543 (46.00–60.52)
Day 21	53.4486 $\pm$ 15.92295	50.4029 (36.79–71.98)
Positive control group		
Day 7	77.0658 $\pm$ 1.72411	77.2544 (74.41–79.23)
Day 14	75.4653 $\pm$ 4.16340	75.5296 (70.38–79.91)
Day 21	76.2123 $\pm$ 3.13555	75.0753 (73.12–79.87)
UDCA treated group		
Day 7	75.5154 $\pm$ 4.81379	72.5471 (71.34–80.92)
Day 14	52.4700 $\pm$ 3.18040	52.0231 (49.02–57.69)
Day 21	38.3152 $\pm$ 14.68189	36.4012 (22.93–58.35)
Curcumin treated group		
Day 7	74.8924 $\pm$ 2.89393	75.5122 (70.26–78.02)
Day 14	51.0727 $\pm$ 6.43194	52.8618 (41.27–57.25)
Day 21	35.1579 $\pm$ 13.41805	29.8706 (20.59–52.90)
Curcumin+UDCA treated group		
Day 7	77.4729 $\pm$ 3.31776	79.0784 (71.61–79.44)
Day 14	48.8918 $\pm$ 7.26520	45.6472 (42.64–60.99)
Day 21	43.5191 $\pm$ 6.03412	40.9389 (39.65–54.22)

SD: Standard deviation, UDCA: Ursodeoxycholic acid.

### The effects of curcumin on TGF- $\beta$ compared to UDCA on days 7, 14, and 21

The immunohistochemistry results showed that TGF- $\beta$  expression in curcumin was lower than UDCA treatment group without any significant difference (Table 1). The reduction of TGF- $\beta$  expression was observed in the curcumin group where the lowest level was on day 21.



**Figure 2: Transforming growth factor- $\beta$  expression on necrosis area; (a) normal (A1: Day 7, A2: Day 14, and A3: Day 21), (b) cholestasis-induced (B1: Day 7, B2: Day 14, and B3: Day 21), (c) curcumin treatment (C1: Day 7, C2: Day 14, and C3: Day 21), (d) UDCA treatment (D1: Day 7, D2: Day 14, and D3: Day 21), (e) combination of curcumin and UDCA (E1: Day 7, E2: Day 14, and E3: Day 21)**

### **The effects of curcumin on TGF- $\beta$ compared to the combination of curcumin and UDCA on TGF- $\beta$ on days 7, 14, and 21**

This study showed that co-administration therapy, however, was found to have no better outcome, as compared to curcumin alone. As it is shown in Tables 1 and 2, the combination of curcumin and UDCA had a higher expression of TGF- $\beta$  than curcumin alone on days 7 and 21 (Table 3).

### **The effects of curcumin on the proportion of fibrosis compared to the positive control group on days 7, 14, and 21**

As shown in Tables 4 and 5, in cholestasis-induced mice, the proportion of fibrosis was lower in the curcumin treatment group compared to the positive control group without any significant difference as shown in Figure 3.

**Table 2: One-way analysis of variance of transforming growth factor- $\beta$**

Dependent variable	Significant
TGF- $\beta$ day 7	
Between groups	0.037
Within groups	
Total	
TGF- $\beta$ day 14	
Between groups	<0.001
Within groups	
Total	
TGF- $\beta$ day 21	
Between groups	<0.001
Within groups	
Total	

TGF- $\beta$ : Transforming growth factor- $\beta$ .

### **The effects of curcumin on the proportion of fibrosis compared to UDCA on days 7, 14, and 21**

Histopathological results using *Masson trichrome* staining showed that the proportion of fibrosis in the curcumin treatment group was unexpectedly lower than the UDCA without any significant difference on days 7 and 14, respectively. Meanwhile, the proportion of fibrosis on day 21 was higher in the curcumin group compared to UDCA (Table 5 and Figure 4).

### **The effects of curcumin on the proportion of fibrosis compared to the combination of curcumin and UDCA on days 7, 14, and 21**

Compared to the combination of curcumin and UDCA treatment, the proportion of fibrosis in the curcumin treatment group was lower. Meanwhile, on day 21, in the curcumin and UDCA treatment group, the proportion of fibrosis increased. The result was in contrast to the proportion of fibrosis in the curcumin group, which continued to decrease until the last day of sampling (Table 5 and Figure 4).

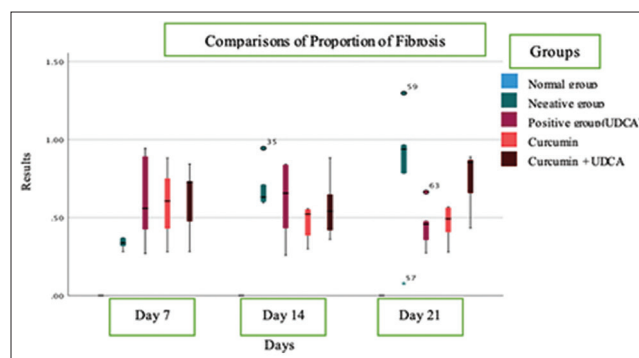


Figure 3: Proportions of fibrosis in all groups, data presented as mean  $\pm$  standard deviation

### **The correlation between TGF- $\beta$ and proportion of fibrosis on days 7, 14, and 21**

Based on the results of the analysis, there was no correlation between TGF- $\beta$  expression and the proportion of fibrosis on day 7 ( $p < 0.001$ ), while the correlation between TGF- $\beta$  expression and the proportion of fibrosis on day 14 was found ( $p = 0.336$ ) which indicates a sufficient correlation. A strong correlation was found between TGF- $\beta$  expression and the proportion of fibrosis on day 21 ( $p = 0.513$ ) (Table 6).

## **Discussion**

Our study has shown a therapeutic effect of curcumin for the reduction of cholestasis induced by common bile duct ligation. The importance of curcumin is highlighted in this research which decreased the expression of TGF- $\beta$  and the proportion of fibrosis due to the ligation procedure. It is seen that the curcumin lowers the expression of TGF- $\beta$  compared to the positive control group significantly ( $p \leq 0.001$ , respectively) through inhibition of the TGF- $\beta$ 1/Smad signaling pathway [12]. Based on molecular pathways, it has been demonstrated that downregulation of the TGF- $\beta$ 1/Smad3 axis mediates the antifibrotic effect [13].

This research also demonstrated that there were differences between the administration of curcumin compared to UDCA on days 7, 14, and 21 based on the level of TGF- $\beta$  ( $p = 0.755$ ;  $p = 0.701$ ; and  $p = 0.677$ , respectively) without any significant difference statistically. It seems that curcumin has similar effectiveness as UDCA in decreasing TGF- $\beta$  expression. Many studies show that UDCA can activate anti-apoptotic pathways and maintain cellular structures such as plasma membranes and mitochondria, and prevent hepatocyte damage from bile acids that result in

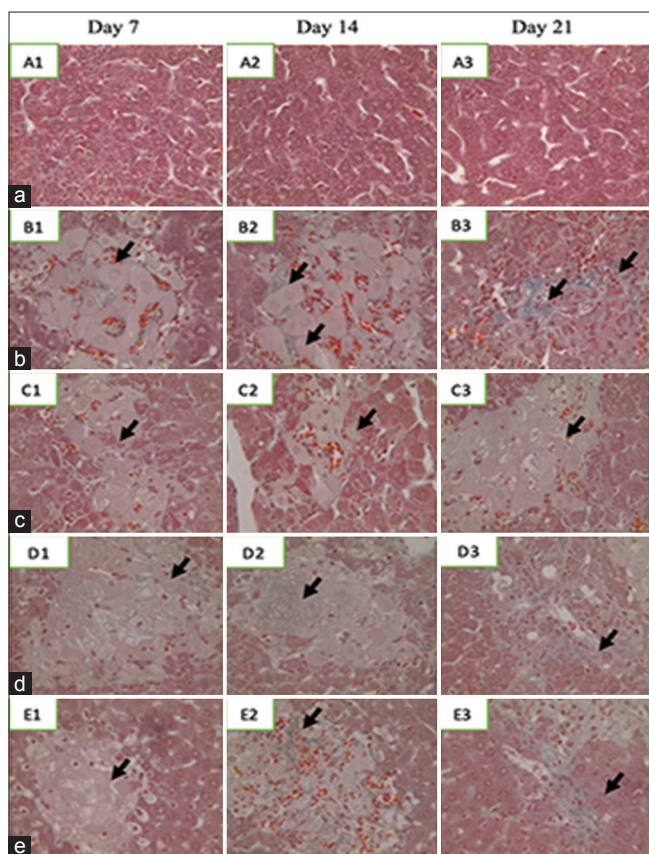


Figure 4: Cross-section from liver tissue with Masson trichrome staining; (a) normal (A1: Day 7, A2: Day 14, and A3: Day 21), (b) cholestasis-induced (B1: Day 7, B2: Day 14, and B3: Day 21), (c) curcumin treatment (C1: Day 7, C2: Day 14, and C3: Day 21), (d) UDCA treatment (D1: Day 7, D2: Day 14, and D3: Day 21), and (e) combination of curcumin and UDCA (E1: Day 7, E2: Day 14, and E3: Day 21)

Table 3: Post hoc least significant difference test on transforming growth factor-β expression in each groups

Dependent variable	Treatment group	Study groups	Significant
TGF-β day 7	Curcumin	Normal	0.081
		Positive control group	0.282
		UDCA	0.755
		Curcumin+UDCA	0.204
TGF-β day 14	Curcumin	Normal	0.569
		Positive control group	< 0.001
		UDCA	0.701
		Curcumin+UDCA	0.549
TGF-β day 21	Curcumin	Normal	0.024
		Positive control group	< 0.001
		UDCA	0.677
		Curcumin+UDCA	0.276

\*The mean difference was significant at <0.05. TGF-β: Transforming growth factor-β, UDCA: Ursodeoxycholic acid.

inflammation and damage mitochondrial function [10]. Meanwhile, it is believed that the mechanism of TGF-β as one of most potential cytokines that contribute to fibrogenesis by activating platelet-derived growth factor receptor and induction of oxidative stress by TGF-β also mediates the proliferative action of TGF-β in hepatic stellate cells. TGF-β also downregulated microRNA-30c (miR-30c) and microRNA-193 (miR-193) in hepatic stellate cells resulting in modifications in extracellular matrix remodeling [14].

The level of TGF-β in the curcumin group compared to the combination group interestingly

Table 4: The proportion of fibrosis on day 7, 14 and 21 after common bile duct ligation procedure

Group	Mean ± SD	Median (minimum–maximum)
Normal	0.000 ± 0.00	0.000 ± 0.00
Positive control group		
Day 7	0.3348 ± 0.03750	0.3370 (0.28–0.37)
Day 14	0.6962 ± 0.14610	0.6310 (0.59–0.94)
Day 21	0.8122 ± 0.45163	0.9380 (0.80–1.30)
UDCA treated group		
Day 7	0.6172 ± 0.29359	0.5580 (0.27–0.94)
Day 14	0.6048 ± 0.25655	0.6560 (0.26–0.84)
Day 21	0.4448 ± 0.14724	0.4570 (0.27–0.66)
Curcumin treated group		
Day 7	0.5890 ± 0.24177	0.6060 (0.28–0.88)
Day 14	0.4624 ± 0.11511	0.5220 (0.30–0.56)
Day 21	0.4610 ± 0.14724	0.4920 (0.28–0.57)
Curcumin+UDCA treated group		
Day 7	0.6116 ± 0.22828	0.7250 (0.28–0.84)
Day 14	0.5698 ± 0.20746	0.5400 (0.36–0.88)
Day 21	0.7400 ± 0.19552	0.8530 (0.43–0.89)

UDCA: Ursodeoxycholic acid, SD: Standard deviation.

showed less TGF-β expression in the curcumin group on days 7 and 21 (p = 0.204 and p = 0.276) without any significant differences. As it is shown in Table 1, the expression of TGF-β increased on day 14. It is believed that the effectiveness of curcumin against TGF-β as fibrosis therapy is dose and time-dependent. This is associated with alteration in oxidative stress and antioxidant gene expression levels that lead to the inhibition or promotion of cell death [13].

Table 5: One-way analysis of variance of proportion of fibrosis

Dependent variable	Significant
Proportion of fibrosis day 7	
Between groups	< 0.001
Within groups	
Total	
Proportion of fibrosis day 14	
Between groups	< 0.001
Within groups	
Total	
Proportion of fibrosis day 21	
Between groups	< 0.001
Within groups	
Total	

Based on histopathology examination, the proportion of fibrosis between the curcumin group and positive control group, the liver fibrosis proportion is seen less in the curcumin group on days 14 and 21 (p = 0.41 and p = 0.29) without any significant differences. Curcumin inhibits extracellular matrix synthesis by suppressing TGF-β to improve collagen synthesis and cell migration during fibrogenesis [1].

Table 6: Post hoc least significant difference test on proportion of fibrosis in each groups

Dependent variable	Treatment group	Study groups	Significant
Proportion of fibrosis day 7	Curcumin	Normal	< 0.001
		Positive control	0.057
		UDCA	0.825
		Curcumin+UDCA	0.859
Proportion of fibrosis day 14	Curcumin	Normal	< 0.001
		Positive control	0.041
		UDCA	0.199
		Curcumin+UDCA	0.328
Proportion of fibrosis day 21	Curcumin	Normal	0.006
		Positive control	0.029
		UDCA	0.915
		Curcumin+UDCA	0.076

\*The mean difference was significant at < 0.05. UDCA: Ursodeoxycholic acid.

Curcumin appears to have a contribution in reducing the expression of TGF-β optimally in liver tissue after administration for 2 weeks. Decreases of TGF-β levels were correlated to the reduction of liver fibrosis proportion in week 2 [12]. This result is similar to

another research that recommends the optimal time of curcumin administration were given 10–14 days to achieve the maximal effect [15]. Its inhibitory effects on hepatic stellate cell proliferation also was concentration-dependent [3].

The effectiveness of the curcumin group compared to UDCA based on the proportion of fibrosis was surprisingly lower in the curcumin group ( $p = 0.825$ ;  $p = 0.199$ ; and  $p = 0.915$ , respectively) without any significant differences. Curcumin has antioxidant and anti-inflammatory activity; meanwhile, UDCA is known as a standard treatment for cholestatic liver diseases that reduced fatty degeneration, cellular necrosis, edema, and immune cell infiltration. Both have different mechanisms in managing liver fibrosis [16].

This study showed the comparison between curcumin and a combination of curcumin and UDCA on days 7, 14, and 21 where the proportion of fibrosis is lower in the curcumin group with no significant difference ( $p = 0.859$ ,  $p = 0.328$ , and  $p = 0.076$ ). Nonetheless, it can be seen that long-term administration of curcumin and UDCA resulted in a higher proportion of fibrosis. This is thought to be related to the failure of the regeneration process of liver cells due to the cholestasis process. Various phases occur in the chronic course of liver diseases, such as initiation, regeneration, perpetuation, fibrogenesis, tumorigenesis, and metastasis [12].

Correlation between TGF- $\beta$  expression and proportion of fibrosis in control group, curcumin treatment group, UDCA treatment group, and combination group showed there was no correlation on days 7 ( $p < 0.001$ ), but there was a sufficient correlation on day 14 ( $p = 0.336$ ) and strong correlation on day 21 ( $p = 0.513$ ). However, there are some limitations of this study due to the long period of study which is a very high risk for the sample to drop out. The procedure and examination are also relatively expensive.

## Conclusion

Curcumin was shown to decrease TGF- $\beta$  expression compared to positive control group with a significant difference. In comparison to UDCA and combination of curcumin and UDCA, TGF- $\beta$  expression was also lower in the curcumin group but no significant differences.

The administration of curcumin was also shown to reduce the proportion of fibrosis compared to the positive control group, UDCA group, and combination group with almost the same results. It can be suggested that curcumin almost has the same effectiveness as UDCA in decreasing TGF- $\beta$  expression.

## Ethics Consideration

Ethics approval has been obtained from the Ethics Committee, Faculty of Medicine, Universitas Diponegoro, Semarang, Indonesia, before the study being conducted.

## Acknowledgments

The authors would like to thank and appreciate the cooperation and support of the Biomedical Science Program of Universitas Diponegoro and iRatco Laboratorium, Bogor. The author also would like to appreciate those who were helpful in this study.

## Author's Contribution

PAA: Planned the study, collected the data, performed the analysis, and wrote the manuscript; EP, MM, AMR, and NS: Critically revised the draft for important intellectual content and finally approved the manuscript. All authors read and approved the final manuscript.

## References

1. Weiskirchen R, Weiskirchen S, Tacke F. Recent advances in understanding liver fibrosis: Bridging basic science and individualized treatment concepts. *F1000Res*. 2018;7:F1000 FacultyRev-921. <https://doi.org/10.12688/f1000research.14841.1> PMID:30002817
2. Coban S, Yildiz F, Terzi A, Al B, Aksoy N, Bitiren M, *et al*. The effects of *Nigella sativa* on bile duct ligation induced-liver injury in mice. *Cell Biochem Funct*. 2010;28(1):83-8. <https://doi.org/10.1002/cbf.1624> PMID:20029957
3. Chen N, Geng Q, Zheng J, He S, Huo X, Sun X. Suppression of the TGF- $\beta$ /Smad signaling pathway and inhibition of hepatic stellate cell proliferation play a role in the hepatoprotective effects of curcumin against alcohol-induced hepatic fibrosis. *Int J Mol Med*. 2014;34(4):1110-6. <https://doi.org/10.3892/ijmm.2014.1867> PMID:25069637
4. El-Meguid MA, Dawood RM, Mokhles MA, El Awady MK. Extrahepatic upregulation of transforming growth factor beta 2 in HCV genotype 4-induced liver fibrosis. *J Interferon Cytokine Res*. 2018;38(8):341-7. <https://doi.org/10.1089/jir.2018.0045> PMID:30130153
5. Derynck R, Budi EH. Specificity, versatility, and control of TGF beta family signaling. *Sci Signal*. 2019;12(570):eaav5183. <https://doi.org/10.1126/scisignal.aav5183>

- PMid:30808818
6. Rivera-Espinoza Y, Muriel P. Pharmacological actions of curcumin in liver diseases or damage. *Liver Int.* 2009;29(10):1457-66. <https://doi.org/10.1111/j.1478-3231.2009.02086.x>  
PMid:19811613
  7. Farzaei MH, Zobeiri M, Parvizi F, El-Senduny FF, Marmouzi I, Coy-Barrera E, et al. Curcumin in liver diseases: A systematic review of the cellular mechanisms of oxidative stress and clinical perspective. *Nutrients.* 2018;10(7):855. <https://doi.org/10.3390/nu10070855>  
PMid:29966389
  8. Supriono S, Pratomo B, Praja DI. *The effects of curcumin on NF- $\kappa$ B level and degree of liver fibrosis* in rat liver fibrosis. *J Penyakit Dalam Indones.* 2019;5(4):174-83. <https://doi.org/10.7454/jpdi.v5i4.271>
  9. Tang N, Zhang Y, Liang Q, Liu Z, Shi Y. The role of ursodeoxycholic acid on cholestatic hepatic fibrosis in infant mice. *Mol Med Rep.* 2018;17(3):3837-44. <https://doi.org/10.3892/mmr.2017.8284>  
PMid:29257337
  10. Milani M. Ursodeoxycholic acid (UDCA) in biliary diseases: A Clinical review. *Br J Med Med Res.* 2014;4(9):1783-90. <https://doi.org/10.9734/bjmmr/2014/7186>
  11. Tag CG, Sauer-Lehnen S, Weiskirchen S, Borkham-Kamphorst E, Tolba RH, Tacke F, et al. Bile duct ligation in mice: Induction of inflammatory liver injury and fibrosis by obstructive cholestasis. *J Vis Exp.* 2015;96:52438. <https://doi.org/10.3791/52438>  
PMid:25741630
  12. Supriono S, Nugraheni A, Kalim H, Eko MH. The effect of curcumin on regression of liver fibrosis through decreased expression of transforming growth factor- $\beta$ 1 (TGF- $\beta$ 1). *Indones Biomed J.* 2019;11(1):52-8. <https://doi.org/10.18585/inabj.v11i1.463>
  13. Guan S, Yu P, Cao J, Xi X, Zhang Q, Zhu C et al. Ginsenoside Rg1 protects against cigarette smoke-induced airway remodeling by suppressing the TGF- $\beta$ 1/Smad3 signaling pathway. *Am J Transl Res.* 2020;12(2):493-506.  
PMid:32194898
  14. Fabregat I, Moreno-Càceres J, Sánchez A, Dooley S, Dewidar B, Giannelli G, et al. TGF-signalling and liver disease. *FEBS J.* 2016;283(12):2219-32. <https://doi.org/10.1111/febs.13665>  
PMid:26807763
  15. Putra R, Handaya AY, Barmawi A. Effectivity of glutathione and curcumin in hepatic fibrosis induced by cholestasis in Wistar mice. 2021;12(2):459-62. <https://doi.org/10.15562/ism.v12i2.997>
  16. Gheibi S, Ghaleh HE, Motlagh BM, Azarbayjani AF, Zarei L. Therapeutic effects of curcumin and ursodexychoic acid on non-alcoholic fatty liver disease. *Biomed Pharmacother.* 2019;115:108938. <https://doi.org/10.1016/j.biopha.2019.108938>  
PMid:31071511