




Gynecological Examination in Children and Adolescents

Muhammad Rusda^{1*}, Berry Eka Parda Bancin¹, Andrina Yunita Murni Rambe²

¹Department of Obstetrics and Gynecology, Endocrinology Reproductive Division, School of Medicine, Universitas Sumatera Utara, Medan, Indonesia; ²Department of Otorhinolaryngology, School of Medicine, Universitas Sumatera Utara, Medan, Indonesia

Abstract

Edited by: Ksenija Bogoeva-Kostovska
Citation: Rusda M, Bancin BEP, Rambe AYM. Gynecological Examination in Children and Adolescents. Open-Access Maced J Med Sci. 2022 Mar 25; 10(T7):68-73. <https://doi.org/10.3889/oamjms.2022.9262>
Keywords: Gynecological; Examination; Pediatric; Adolescent

***Correspondence:** Muhammad Rusda, Department of Obstetrics and Gynaecology, Division of Reproductive Endocrinology and Infertility, Medical Faculty, Universitas Sumatera Utara, Medan, Indonesia.
E-mail: m.rusda@usu.ac.id

Received: 10-Dec-2021

Revised: 17-Feb-2022

Accepted: 15-Mar-2022

Copyright: © 2022 Muhammad Rusda,

Berry Eka Parda Bancin, Andrina Yunita Murni Rambe

Funding: This research did not receive any financial support

Competing Interest: The authors have declared that no competing interest exists

Open Access: This is an open-access article distributed under the terms of the Creative Commons Attribution-NonCommercial 4.0 International License (CC BY-NC 4.0)

Pediatric gynecological examination is one of the gynecological examinations that are quite simple, but many doctors are unable to do it properly because of the infrequentness of doing this examination. Consulting a child with gynecological complaints, endocrine problems, or sexual abuse often takes a long time and is thorough. However, evidence-based data on the problem of gynecological examinations in children and adolescents are inadequate because of the high bias in many studies. The purpose of this review is to seek from the literature regarding the correct procedures for gynecological examinations in children and adolescents, the order of examinations, and how to carry out a good examination so as not to leave a traumatic experience for children.

Introduction

Gynecology is a branch of medicine that studies women as a whole, from children to old women. Gynecology discusses the female reproductive organs, problems that may arise, be it congenital problems, infection problems, hormonal problems, or benign tumors in the female organs. Along with the development of the times, many patients who come are children and adolescents, where previously patients with this age usually consulted to pediatricians. This is a problem in itself because a gynecologist must master the anatomy and physiology of women at the age of children and adolescents, which are different from conditions in adulthood [1], [2]. This condition needs a deep understanding, not to mention, at this age range, gynecological examinations become examinations that are taboo in some ethnic groups. The patient's parents need education and in-depth explanations. Gynecological examinations in this age group can also be a traumatic experience for this group, a good examination technique is needed so that the patient feels comfortable and accepts the examination [3], [4], [5].

Endocrinology Physiology of the Female Reproductive System

The neuroendocrine system systematically regulates the development of the female reproductive system. When the woman is still a fetus, gonadotropin-releasing hormone (GnRH) starts being produced in the olfactory placodes. These neurons will then migrate through the forebrain to the arcuate nucleus of the hypothalamus at 11 weeks of gestation. These neurons then form axons that extend to the median apex and the plexus of the capillary system at the pituitary portal. Higher cortical centers influence a decapeptide, GnRH. These neurons also release GnRH in a pulsed manner into the pituitary portal plexus. Consequently, during mid-pregnancy, GnRH "pulse generator" will stimulate gonadotropin secretion from the anterior pituitary. Gonadotropins are follicle-stimulating hormone (FSH) and luteinizing hormone (LH). In turn, the release of gonadotropins will stimulate the maturation of follicles in the ovaries so that the ovaries will produce sex steroid hormones and release them into the fetal blood circulation. Simultaneously, germ cell division is accelerated and follicular development begins,

and 6–7 million oocytes are formed by 5 months of gestation. In late pregnancy, sex steroids exert negative feedback on hypothalamic GnRH and suppress pituitary gonadotropin secretion. During this period, the number of oocytes decreases through a process of gene-associated apoptosis until only 1–2 million eggs remain in both ovaries when a woman is born [1], [6], [10].

At birth, FSH and LH concentrations increase abruptly in response to decreased placental estrogen levels. Gonadotropin hormone in the blood reaches the highest levels in the first 3 months of life (Figure 1). Sex steroid hormone concentrations increase is following a transient increase in GnRH levels. This increase can cause vaginal bleeding in neonates, temporary breast development, follicular cysts in newborns, and in some cases, vaginal discharge. After these initial months, gonadotropin levels gradually decrease until they reach pre-pubertal levels at 1–2 years of age. Thus, low plasma levels of FSH, LH, and estradiol characterize childhood. Usually, the estradiol level is measured <10 pg/mL, and the LH value is <0.3 ml U/mL. Both are able to assess if there is premature development suspected. During childhood, the ovaries undergo active follicular growth and oocyte atresia. As a result of this friction, at puberty, only about 300,000 oocytes remain [6], [7], [8], [9], [10].

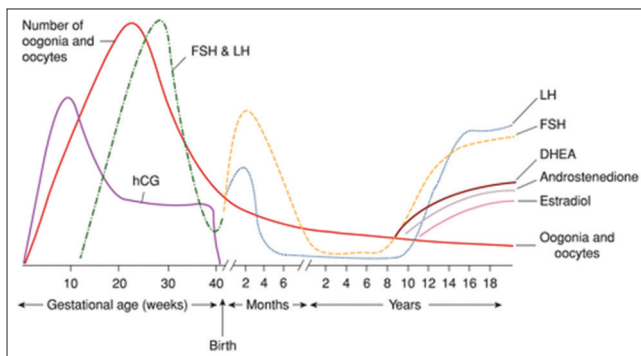


Figure 1: Variations in oocyte count and hormone levels during the prenatal and postnatal periods [11]

Anatomy of the Female Reproductive System

Pelvic anatomy is certainly different in children when compared to adolescents and adult women. These changes occur as a woman matures due to the growth of the pelvis and the influence of the hormone estrogen, the body begins to produce estrogen when a woman has experienced menarche. In neonates, sonographically, the uterus is about 3.5–4 cm long and 1.5 cm wide. Echogenic central endometrial streaks are common and reflect the transient increases in sex steroid levels described previously. During childhood, the uterus measures 3–4 cm and is tubular because

the cervix and fundus are the same sizes. The size of the ovary increases with the development of childhood, and its volume ranges from 0.5 to 2 cm³. In Table 1, we can see in detail the changes that occur in the genitalia of children, adolescents, and adult women [12], [13], [14], [15], [16].

Gynecological Examination in Children

Indications for gynecological examinations in pediatric and adolescent patients include (1) external genital examination – examination of the external genitalia, including the vulva, clitoris, labia, and urethra, as well as the anal canal, is a part of a routine physical examination. Assessment of the vulva, hymen, and lower vagina for signs of vulvar rash, vulvar pigmented/non-pigmented lesions, masses, lichen sclerosis, labial adhesions, and/or vaginal discharge is most often performed visually without the use of tools and (2) internal genitalia examination – internal genitalia examination allows visualization of the vagina and cervix and is performed in children with genitourinary complaints or suspected genitourinary pathology (e.g., vaginal bleeding, persistent discharge, foreign body examination, trauma, acute sexual abuse with penetration, cystic or solid mass, and suspected congenital anomaly) [17], [18].

Vaginal visualization is able to perform without instruments if the child is relaxed and placed in a knee-chest position, while examination of the internal genitalia can only be performed using hysteroscopy or ultrasound. However, occasionally, examination under anesthesia with a Killian nasal speculum, fiber-optic binoculars, or other instruments may be necessary if the complaint cannot be adequately evaluated by the above examination in unmarried child and adolescent patients, the examination must be followed by parents and guardians by first providing informed consent to the family or guardian [19], [20].

Patient Positioning For Examination

Before examining this age group, one should focus on getting the cooperation of the child. Explaining the examination entails and letting the child have a sense of control (for example, letting the child choose which examination gown to wear) can be a way to solicit cooperation and make the examination easier. Not doing many examinations at the same time can also play a role in examining children so that children feel more comfortable and cooperative [21].

As the clinician seeks to obtain the cooperation of the patient for an adequate examination, positioning

Table 1: General anatomical findings in newborns, pre-pubertal, and adolescent girls [16]

Site	Newborn baby	Pre-puberty	Teenager post-puberty
Clitoris	The clitoral sheath may be thicker at birth	Mean clitoral length 3 mm, width 3 mm	The mean clitoral width is 2–4 mm, with a longitudinal diameter of 5.1 + 1.4 mm Nitrogenized and thickened
Hymen	Maybe thicker, fimbriated, and protruded from the introitus	Annular, atrophic crescentic form, thin, with visible blood vessels	Thickens and feels different from the surrounding tissue
labia major	Edema may be present	Small, average	Larger but not fully developed until puberty
labia minor	Maybe thick and there is protrusion toward the labia major	Thin and short, a rudimentary extension of the clitoral sheath extending to 1/3 of the length of the labia majora	
Vagina	Thickening of the vaginal mucosa, with white discharge, usually 3–6 cm long	4–7 cm long atrophic walls, red and thin lining	8 cm long, moist, pale pink, and has rugae
Cervix	Prominent, with a fundus/cervix ratio of ½	Merges with the vagina with a small opening in the middle	Adult form, usually pale pink and has a prominent ectopic appearance
Uterus	The mean uterine length is 3.5 cm, with a maximum thickness of 1.4 cm, the endometrial appearance is echogenic	Length includes cervix 3.2 cm thickness 1 cm, the endometrium is thin and may not be visible	4.72 cm long on tanner breast 2, and 7.4 cm on tanner breast 4
Ovaries	Located intra-abdominally, with a volume of 1.0 cm ³	Intra-abdominal location with a volume of 0.54 + 0.25 cm	Volume 1.9 cm ³ on tanner breast 2, and 4.19 cm on tanner breast 4

becomes a key component of a successful pediatric gynecological assessment. In some situations, more than 1 position may be required to obtain adequate visualization of the genitals. The patient's age may also play a role in the examination position. Clinician should be able to describe several positions to allow adequate visualization of the area, and the most useful are those that facilitate the purpose at hand. In children under the age of 2 years, the parents can do the examination while changing diapers. The *frog-leg* position is the most commonly used in young pre-pubertal patients and allows the patient to see directly the examiner and himself (Figure 2a). Using a leg brace and a lithotomy position can help better visualize of the perineal area as the child grows up. Asking the mother for help with the examination proved useful and placing her daughter between her legs may be helpful (Figure 2b). Combining the use of low-power magnification such as with an otoscope or knee-chest positional ophthalmoscope, often allows a better visualization of the lower and upper vagina. This position may be particularly helpful in patients with symptoms of vaginal discharge or suspected presence of a foreign body (Figure 2c and d). Despite the best efforts that made, some patients may not cooperate as long as optimal genital examination and evaluation are not possible. In these patients, it is important to consider the severity of the complaint and the clinical consequences of the pathology. This will enable a decision regarding the examination on several subsequent visits or take the under anesthesia examination under into weighing [21], [22].

Tools for Gynecological Examination in Children

As with most gynecological examinations, efficiency is important to minimize the time the patient spends feeling exposed. Therefore, all the necessary equipment must be available beforehand. A height-adjustable table with stirrups for older girls and teens is ideal. In addition to bright lighting, our office also often

uses handheld mirrors so that patients can observe the examination. Instead of frightening the patient, it seems to make the process less scary by allowing him to visualize the examination and make him an active participant. Most offices now only provide latex-free non-powdered nitrile gloves to avoid triggering reactions in latex-sensitive patients. This is especially important when treating patients with spina bifida who have a latex allergy prevalence of 10–28%. For vaginal examination, various sizes of speculum should be available, preferably a small, short Pederson or Huffman specula for pre-pubertal patients. Otoscopy or a nasal speculum may also be helpful for examination. The longer Pederson speculum is useful for post-pubertal virgin patients and provides adequate length for cervical visualization. If possible, the specula should be stored in a warming drawer for patient comfort. Although the use of water-based lubricants is often avoided due to concerns about interference with cervical cytology, several studies have shown that they do not alter cytology results and do not interfere with modern nucleic acid amplification tests, and therefore can be used for patient convenience [18], [20], [21], [22].

Genital Examination

When evaluating a newborn, clinicians should pay attention on the key characteristics of the external genitalia, which are the result of maternal estrogen stimulation. These findings should not be considered abnormal and tend to decrease within 6–8 weeks. Recognizing these characteristics are important for practitioners when asked to evaluate a newborn. The pre-pubertal hymen is thin, red, and nitrogenized. At puberty, with androgenization, it thickens, becomes pale pink, and is often more exaggerate in its configuration. Figures 2 and 3 show the typical appearances and normal variants. The location of the hymeneal notch and ridge may be important, as those between the 5 and 7 o'clock positions may be associated with child sexual abuse and may warrant further questioning.

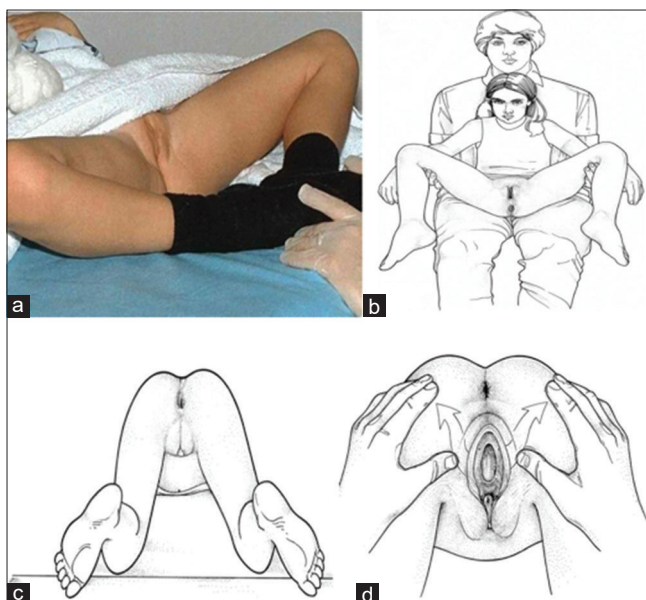


Figure 2: (a) A 5-year-old child demonstrates the supine “frog-leg” position, (b) child in lithotomy position on mother’s lap, (c) child in knee-chest position for genital examination, and (d) technique for examining female genitalia in knee-chest position [16], [17]

The presence of vulvar edema, vaginal discharge, and breast enlargement is common in this age group. The hymen appears thick and may protrude into the introitus. This particular finding can persist for up to 2 years and may interfere with full visualization of the introitus. In pre-pubertal women, the non-estrogenic nature of the hymen and vulvar tissue makes them sensitive to touch and prone to tearing during the examination. Clinicians should take care and do not cause trauma or pain in the area, as this will immediately make further investigations difficult. The use of gentle lateral and downward traction improves visualization and does not interfere with the normal integrity of the pre-pubertal genitalia [20].

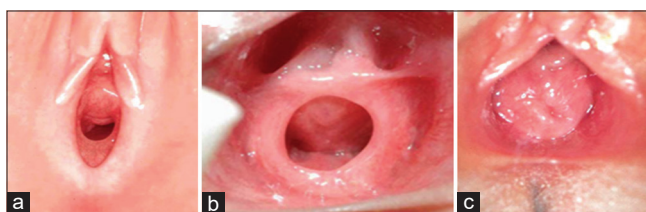


Figure 3: Hymen type: Crescentic (a), annular (b), and redundant (c) [16]

Hymen examination is an important part of the evaluation of girls, especially in possible sexually abused case. The examiner should be able to distinguish a normal hymen and its normal variant from an abnormal hymen. However, 90–95% of girls known as victims of sexual harassment have normal genital examinations. Anatomical variants sometimes misinterpreted as a sign of sexual abuse include *midline sparing* (linea vestibular), lichen sclerosis, failure of midline fusion, urethral prolapse, labial adhesions, pemphigoid, and other dermatological conditions [16], [23].

Certain patients may present with symptoms that require sampling of vaginal secretions. If the culture

is indicated, swab Dacron moistened urethra can be used (Figure 4).

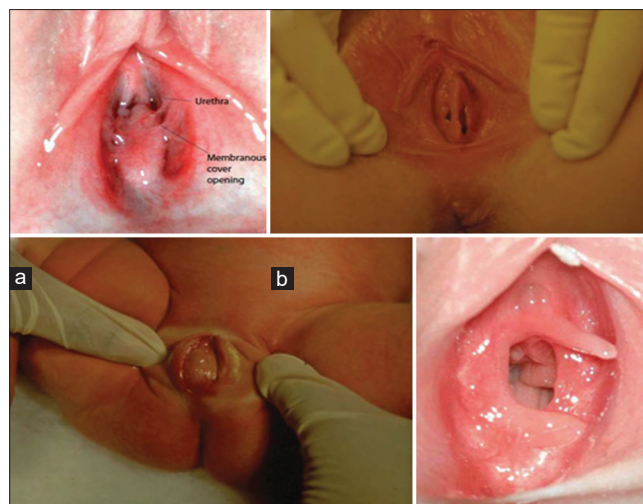


Figure 4: Hymenal variations: Microperforate (a), septated (b), imperforate (c), and hymeneal tag (d) [22]

Taking Specimens on Genital Examination

Certain patients may present with symptoms that require sampling of vaginal secretions. If the culture is indicated, swab Dacron moistened urethra can be used (Figure 5a). The hymen hole is still small in this age group, and the use of traditional cotton swabs can be uncomfortable because of their larger size. It can also traumatize the surrounding tissue, creating a lesion that is not pathological but may confuse the practitioner on other examinations. Another helpful method is the technique of *catheter-within-a-catheter* where intravenous catheter along 10 cm is inserted into the proximal end of the catheter is a rubber bladder No. 12. Then, it is connected to the syringe with liquid and carefully inserted into the vagina. The fluid is then introduced and aspirated several times to allow a good mixture of secretions to be created (Figure 5b).

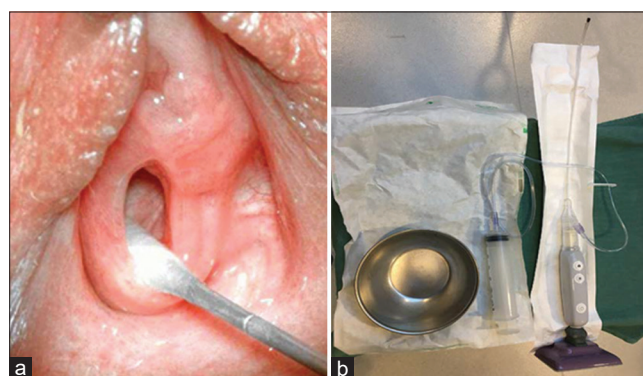


Figure 5: (a) Small Dacron swab to obtain vaginal secretions, (b) assembled catheter-within-catheter aspirator, as used to obtain samples of vaginal secretions from pre-pubertal patients [22]

Ultrasound of Pelvic Organs in Children

Clinicians image the pediatric patient's uterus, vagina, and ovaries optimally when the patient's bladder is full. Therefore, clinicians asked all patients not to urinate 1 h before undergoing imaging and advised to drink. Transducers *Ultrasonography* (USG) transabdominal and the *linear array* are generally adequate for most examinations USG pelvis. The transperineal approach is useful in young girls with urogenital malformations, hydrometrocolpos, labial masses, or anal atresia (Figure 6) [24].

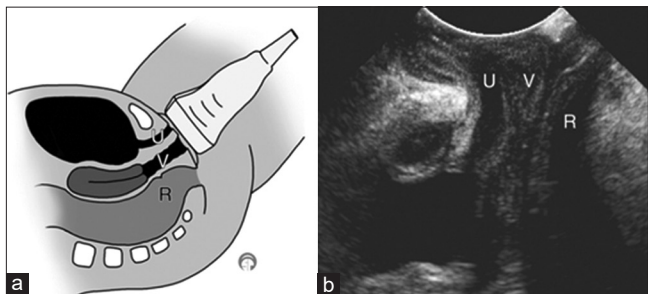


Figure 6: Image depicting transducer placement and normal female anatomy on transperineal ultrasound. (a) Sagittal diagram showing the placement of linear array transducers in the perineum. (b) According to the transperineal sagittal ultrasound image. R = rectum, U = urethra, and V = vagina [24]

In sexually active adolescents, clinicians use a transvaginal approach to complement the transabdominal examination. The size and shape of the uterus and ovaries are age dependent and influenced by hormonal influences. Maternal and placental hormones result in relatively large sizes of the neonatal uterus (Figure 7) and ovaries, compared to their size in infancy, where they remain relatively stable until the first growth spurt occurs at 7–8 years of age [24], [25].

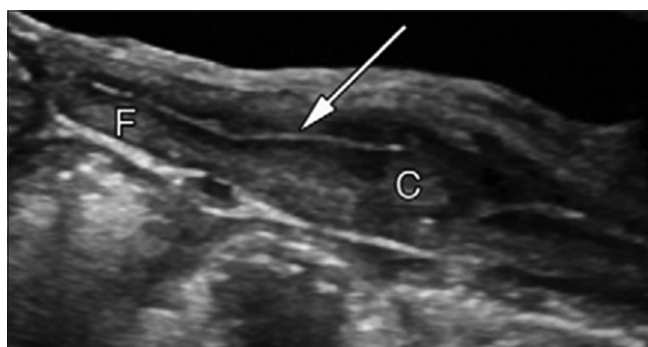


Figure 7: The sagittal ultrasound image of the neonatal uterus shows that the anteroposterior diameter of the cervix (c) is larger than that of the fundus (f). The endometrial cavity is seen as a thin echogenic line in the middle of the uterus (arrows) [24]

Mature follicles in the ovary can be documented at all ages, as the secretion of FSH (Figure 8a). Cervical pre-pubertal has a thickness equal to or greater than the fundus and relatively inconspicuous endometrial lining (Figure 8b). The length of the uterus varies, averaging 2.5–4 cm, with a thickness of ≤ 1 cm. Pre-pubertal ovarian volume is slightly < 1 cm³. During puberty, the uterine fundus lengthens and thickens is larger than

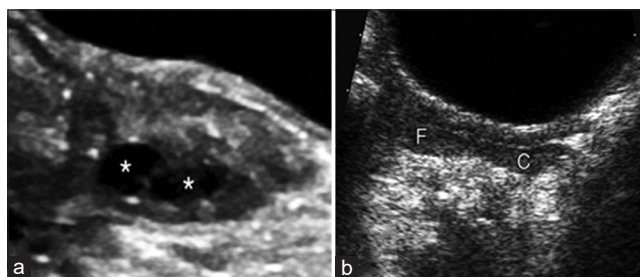


Figure 8: (a) Sagittal ultrasound of the ovaries in an 11-month-old infant showing normal follicles (*). (b) Sagittal ultrasound of the uterus in a 7-year-old girl shows a cervix (c) which is comparable in thickness to the fundus (f) [24]

the cervix. The endometrial lining undergoes cyclical changes associated with the menstrual cycle [24], [25].

Conclusion

Gynecological examination in children is quite easy to do but requires a deep understanding. Doctors often fail to carry out a good and thorough examination of this group of patients because often these patients do not come to the obstetrician. An understanding of sexual growth in children is important as well as an understanding of the physiology and anatomy of the internal and external genitalia in children. The communication factor is also something that requires more attention considering that this group of patients is different from adult patients, so clinicians need more effort to be able to get satisfactory examination results.

References

- Cheikhelard A, Chaktoura Z, Thibaud E. Gynecologic clinical examination of the child and adolescent. *Endocr Dev.* 2012;22:1-10. <https://doi.org/10.1159/000326622> PMID:22846517
- Sultan C, editor. *Pediatric and Adolescent Gynecology: Evidence-based Clinical Practice.* Vol. 22. Basel, Switzerland: Karger Medical and Scientific Publishers; 2012.
- Baldwin DD, Landa HM. Common problems in pediatric gynecology. *Urol Clin North Am.* 1995;22(1):161-76.
- Kass-Wolff J, Wilson E. Pediatric gynecology: Assessment strategies and common problems. *Semin Reprod Med.* 2003;21(4):329-38. <https://doi.org/10.1055/s-2004-815589> PMID:14724766
- Deligeoroglou E, Karountzos V, Creatsas G. Abnormal uterine bleeding and dysfunctional uterine bleeding in pediatric and adolescent gynecology. *Gynecol Endocrinol.* 2013;29(1):74-8. <https://doi.org/10.3109/09513590.2012.705384> PMID:22946701
- Gordts S, Gordts S, Puttemans P, Campo R, Brosens I. Neonatal uterine bleeding and adolescent endometriosis. Endometriosis in adolescents. *J Matern Fetal Neonatal Med.*

- 2020;2020:359-66.
7. Lee H, Woo S, Kim J, Suh S. "Daughter Cyst" sign: A sonographic finding of ovarian cyst in neonates, infants, and young children. *Am J Roentgenol.* 2000;174(4):1013-5. <https://doi.org/10.2214/ajr.174.4.1741013>
PMid:10749241
 8. Vogtländer MF, Rijntjes-Jacobs EG, van den Hoonaard T, Versteegh FG. Neonatal ovarian cysts. *Acta Paediatr.* 2003;92(4):498-501. <https://doi.org/10.1111/j.1651-2227.2003.tb00585.x>
PMid:12801120
 9. Strickland JL. Ovarian cysts in neonates, Children and adolescents. *Curr Opin Obstet Gynecol.* 2002;14(5):459-65. <https://doi.org/10.1097/00001703-200210000-00004>
PMid:12401972
 10. Zeitoun MM, El-Dawas AO, Ateah MA, El-Deen MA. Consequences of twinning induction to Noemi ewes by a recombinant human follicle-stimulating hormone compared with pituitary-derived porcine follicle-stimulating hormone on follicular dynamics, maternal biochemical attributes, and neonatal traits. *Vet World.* 2020;13(4):633-41. <https://doi.org/10.14202/vetworld.2020.633-641>
PMid:32546905
 11. Hoffman B.L, Schorge J.O, Halvorson L,M, Hamid C, Corton M, Schaffer J. *Williams Gynecology.* 4th ed. New York: McGraw Hill; 2020.
 12. Sultan C. *Pediatric and Adolescent Gynecology, Endocrine Development.* Germany: S.Karger; 2004. p. 7.
 13. Bizzarri C, Cappa M. Ontogeny of hypothalamus-pituitary gonadal axis and minipuberty: An ongoing debate? *Front Endocrinol.* 2020;11:187. <https://doi.org/10.3389/fendo.2020.00187>
PMid:32318025
 14. Lanciotti L, Cofini M, Leonardi A, Penta L, Esposito S. Up-to-date review about minipuberty and overview on hypothalamic-pituitary-gonadal axis activation in fetal and neonatal life. *Front Endocrinol.* 2018;9:410. <https://doi.org/10.3389/fendo.2018.00410>
PMid:30093882
 15. Kaplan S, Edgar JC, Ford EG, Adgent MA, Schall JI, Kelly A, et al. Size of testes, ovaries, uterus and breast buds by ultrasound in healthy full-term neonates ages 0-3 days. *Pediatr Radiol.* 2016;46(13):1837-47. <https://doi.org/10.1007/s00247-016-3681-0>
PMid:27580909
 16. Simms-Cendan J. Examination of the pediatric adolescent patient. *Best Pract Res Clin Obstet Gynaecol.* 2018;48:3-13. <https://doi.org/10.1016/j.bpobgyn.2017.08.005>
PMid:29056510
 17. Habeshian K, Fowler K, Gomez-Lobo V, Marathe K. Guidelines for pediatric anogenital examination: Insights from our vulvar dermatology clinic. *Pediatr Dermatol.* 2018;35:693-5. <https://doi.org/10.1111/pde.13586>
PMid:29974531
 18. Smith T, Raman S, Madigan S, Waldman J, Shouldice M. Anogenital findings in 3569 pediatric examinations for sexual abuse/assault. *J Pediatr Adolesc Gynecol.* 2018;31(2):79-83. <https://doi.org/10.1016/j.jpag.2017.10.006>
PMid:29111300
 19. Abu-Alhaja H, Zayed E, Abu-Alhaja B. Anogenital papular lesions in children five year old and younger: Gender differences. *Med Res Arch.* 2020;74(1):28. <https://doi.org/10.5455/medarh.2020.74.28-33>
PMid:32317831
 20. Schmitz A. *Examining Child Life's Role in Pediatric, Master of Science.* Alabama: University of Alabama; 2019.
 21. Sanfilippo J, Lara-Torre E, Gomez-Lobo V. *Sanfilippo's Textbook of Pediatric and Adolescent Gynecology.* 2nd ed. Boca Raton: CRC Press; 2019.
 22. McCaskill A, Inabinet C, Tomlin K, Burgis J. Prepubertal genital bleeding: Examination and differential diagnosis in pediatric female patients. *J Emerg Med.* 2018;55(4):e97-e100. <https://doi.org/10.1016/j.jemermed.2018.07.011>
PMid:30170834
 23. Adams J, Kellogg N, Farst K, Harper N, Palusci V, Frasier L, et al. Updated guidelines for the medical assessment and care of children who may have been sexually abused. *J Pediatr Adolesc Gynecol.* 2016;29(2):81-7. <https://doi.org/10.1016/j.jpag.2015.01.007>
PMid:26220352
 24. Paltiel H, Phelps A. US of the pediatric female pelvis. *Radiology.* 2014;270(3):644-57.
 25. Norton M, Callen P. *Callen's Ultrasonography in Obstetrics and Gynecology.* Amsterdam: Elsevier; 2016.