



Successful Treatment of Post-dural Puncture Headache with Sphenopalatine Ganglion Block in Post-cesarean Section Patient: A Case Report

Rohedi Yosi Asmara¹ , Besthadi Sukmono^{2*} , Pryambodho Pryambodho² 

¹Department of Anesthesiology and Intensive Care, Faculty of Medicine, University of Indonesia, Tarakan Regional Hospital, Government Hospital in Central Jakarta, Jakarta, Indonesia; ²Department of Anesthesiology and Intensive Care, Faculty of Medicine, University of Indonesia, Cipto Mangunkusumo Hospital, Hospital in Central Jakarta, Jakarta, Indonesia

Abstract

BACKGROUND: Post-dural puncture headache is a symptom often found in post-operative patients who receive spinal anesthesia. Therefore, therapy to reduce patient complaints becomes a comparison to find the best alternative for action. This case discusses post-dural puncture headache risk factors in post-cesarean section patients and sphenopalatine ganglion block as an alternative pain intervention.

CASE PRESENTATION: The patient is a 26-year-old woman, G1P0A0, 80 kg, who presented for the first cesarean delivery at 37 weeks of gestational age due to concern for breech presentation. The patient was put into a sitting posture before the spinal anesthetic was administered. She was offered spinal-epidural anesthesia using a Quincke type 26 G spinal needle. The patient was successfully given one shot of spinal anesthesia using the paramedian approach technique. The medication of 1 g paracetamol was given at 8 h intervals as post-operative analgesia. On post-operative day 2, the patient was consulted by the anesthesiologist, and the patient reported an 8/10 severity positional headache on the numerical rating scale. Intra-nasal SPGB has been performed on the patient with lidocaine spray 20 mg. The patient's headache reduced from an NRS of 8/10 to a 6/10 after 5 min of sphenopalatine ganglion block. Twenty-four hours after the procedure, the patient can sit up, lower the neck tension and headache, and resume activities independently. The patient was released the next day with a manageable headache. In 48 h post-block, the patient was called and inquired about PDPH and almost no headache with various positions.

CONCLUSION: SPG block can be a minimally invasive treatment for PDPH. The faster PDPH is treated using an SPG block, the better the patient's pain scale outcome. Several studies have shown that patients who received SPG block therapy did not continue to get EBP.

Edited by: Ana Vucurevic

Citation: Asmara RY, Sukmono B, Pryambodho P. Successful Treatment of Post-dural Puncture Headache with Sphenopalatine Ganglion Block in Post-cesarean Section Patient: A Case Report. Open-Access Maced J Med Sci. 2022 Jun 19; 10(C):231-234. <https://doi.org/10.3889/oamjms.2022.9684>

Keywords: Post-dural puncture headache;

Sphenopalatine ganglion block; Spinal; Cesarean section
***Correspondence:** Besthadi Sukmono, Sp.An, KAR, Jl. Diponegoro No.71, Jakarta Pusat, DKI Jakarta, Indonesia.
E-mail: besth25@gmail.com

Received: 06-Apr-2022

Revised: 26-Apr-2022

Accepted: 09-Jun-2022

Copyright: © 2022 Rohedi Yosi Asmara, Besthadi

Sukmono, Pryambodho Pryambodho

Funding: This research did not receive any financial

support

Competing Interest: The authors have declared that no

competing interest exists

Open Access: This is an open-access article distributed under the terms of the Creative Commons Attribution-NonCommercial 4.0 International License (CC BY-NC 4.0)

Introduction

Because of the extensive use of neuraxial blocks in young females, post-dural puncture headache (PDPH), symptoms of headache caused by spinal anesthesia, is more common in obstetric patients than in the general population [1]. PDPH impairs the mother's capacity to care for her child, raises the risk of persistent headache, and restricts early ambulation, raising the risk of venous thrombosis and pulmonary embolism. The conservative therapy of PDPH includes intravenous fluid replacement, analgesic medications, and theophylline. In patients who do not experience a reduction in headache, epidural blood patching (EBP) is the standard gold treatment for PDPH. However, EBP carries the risks of complications such as meningitis, arachnoiditis, seizures, hearing or vision loss, radicular pain, and neurological impairments. It can also raise the chances of a recurrent dural puncture [2], [3]. Sphenopalatine ganglion block (SPGB) is an alternative that can be an option in these patients.

Case Illustration

The patient is a 26-year-old woman, G1P0A0, BW of 80 kg, who presented for the first cesarean delivery at 37 weeks of gestational age due to breech presentation. The patient did 8 h of fasting preoperatively. We did standard monitoring using non-invasive blood pressure, electrocardiography, and oxygen saturation. We inserted an intravenous line using Ringer's lactate solution. We did spinal anesthesia for this patient, and the injection was done in a sitting position using a Quincke type 26 G spinal needle (B Braun). The spinal anesthesia was successful with a paramedian approach technique on the first attempt. The surgery lasted for 1 h and was uneventful.

Post-operative analgesia used was 1 g of IV paracetamol t.i.d. On a post-operative day 2 (POD 2), the patient complained of severe headache that did not decrease after intravenous fluids and paracetamol 1 g. The patient reported an 8/10 severity positional headache on the numerical rating scale (NRS). The

headache description was bilateral pressure on the head, which grew more intense when sitting, standing, or ambulating and lessened during supine position. The patient has complained of neither phonophobia nor vomiting. Vital indicators were initially within normal ranges.

We planned for intranasal SPGB after informed consent [MOU1]. We obtained histories of coagulopathy, nasal septal deviation, polyps, nasal bleeding, allergy to local anesthetics, local nasal infections, and base of skull fractures before the intervention. We performed the procedure on the patient supine with the neck extended by placing a pillow beneath both shoulders. We chose Xylocaine 10% Pump Spray® (lidocaine 100 mg/ml) as it contains a higher concentration of local anesthetics, and then, we applied it using a long applicator with a cotton swab tip. We inserted the needle parallel to the nose's floor and placed the swab above the middle turbinate on the posterior pharyngeal wall. The applicator was left in place for 5–10 min before removal. We also performed the procedure in the opposite nostril (Figure 1).

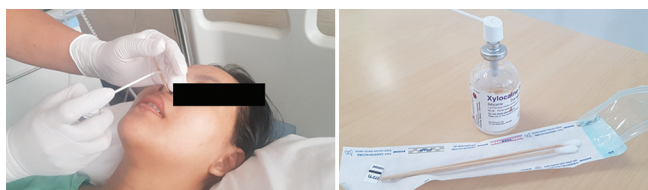

Figure 1: Sphenopalatine ganglion block procedure

The patient complained of mild discomfort and a flowing liquid sensation in her nasopharyngeal area to the throat during the procedure. The patient complained of throat numbness after the intervention. Post-procedure, the patient's headache reduced from an NRS of 8/10 to a 6/10 after 5 min of sphenopalatine ganglion block. Twenty-four hours post-procedure, the patient could sit up and lower the neck tension and headache. The patient was able to resume activities without assistance. We discharged the patient the next day with a manageable headache. We did the follow-up 48 h post-block by telephone, and the patients had no complaints of headache in various positions (Figure 2).

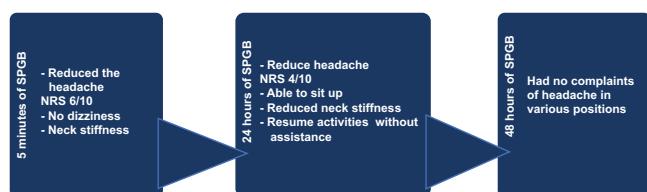


Figure 2: The symptom after the SPGB procedure

Discussion

The high frequency of PDPH in the obstetric population has been linked to several variables, including dehydration, hormonal imbalance, and elevated serum

estrogen altering the tone of the cerebral arteries. The accidental dural puncture (ADP) group contributed to just 25% of patients with PDPH [4]. However, there are some causes of PDPH from spinal anesthesia, epidural injection, spine operation, and lumbar puncture. The causes of PDPH were shown to be significantly different in two groups in a previous study comparing EBP and conservative treatment. The most common reason in the conservative treatment group was a lumbar puncture, while the most common cause in the EBP group was epidural injection (55.0%). In most cases, patients who developed PDPH after lumbar puncture, symptoms recovered with simply conservative therapy without EBP. In those cases, it may be because there was only a stab injury without extensive dura mater damage. EBP was performed in 59.3% (16 of 27) of patients with PDPH caused by procedures other than a diagnostic lumbar puncture, such as epidural injection. Because epidural injection causes dural tears and spinal anesthesia involves injecting drugs into the spinal cavity, these procedures are more invasive than a diagnostic lumbar puncture [5].

In this case, the patient had spinal anesthesia using a Quincke type 26 G spinal needle. Compared to non-cutting needles, cutting needles correlated to a greater incidence of PDPH. Smaller diameter needles can reduce the incidence of PDPH by creating a minor dural puncture, although this relationship is more specific with cutting needles than with pencil-point needles. Multiple attempts during spinal anesthesia were substantially related to PDPH. In addition, rather than perpendicularly entering the needle and severing the fibers, putting the needle with the bevel facing parallel to the dural fibers, and spreading them can reduce the incidence of PDPH [6], [7]. Another study found that patients who received a 25 G Whitacre spinal needle had a much lower incidence of PDPH than those who received a 25 G Quincke spinal needle during a cesarean section under spinal anesthesia [8].

The needle's entrance direction during lumbar dural puncture and the patient's posture may substantially impact the incidence of PDPH. Studies *in vitro* models of the dura mater reveal that the oblique angle of dural puncture induces reduced leakage across the dura mater, implying that the paramedian technique reduces the incidence of PDPH. A recent meta-analysis investigated the relationship between the patient's position during lumbar puncture and PDPH. The lateral decubitus position resulted in less PDPH than the sitting position. CSF pressure is 40 cm H₂O in the sitting posture, whereas it is 5–20 cm H₂O in the lateral position. This high pressure, it is hypothesized, is linked to a larger puncture and lengthier leakage at a more significant pressure. The patient, in this case, had a paramedian approach and sitting position. The brain and meninges travel lower more quickly in the sitting position, resulting in more symptoms. Compared to the midline technique, the paramedian approach

does not diminish the incidence of post-dural puncture headaches, but it raises the rate of spinal anesthesia failure. PDPH incidence is reduced in spinal anesthesia performed in a parallel technique supports the theory of a thin cover mechanism [1], [9]. Another study suggests that the paramedian method for spinal anesthesia should be taught and utilized regularly. There was a much decreased post-dural puncture headache in the paramedian route for spinal anesthesia [10].

Sphenopalatine ganglion block and PDPH

A dull or throbbing headache in a frontal-occipital distribution, often accompanied by neck stiffness, photophobia, dizziness, auditory problems, and nausea, is a characteristic PDPH symptom. The headache is positional, meaning that lying down relieves it while standing or sitting exacerbates it. After a dural puncture, which results in cerebrospinal fluid (CSF) loss, intracranial hypotension and a drop in overall CSF volume reduce a cerebral cushion, resulting in traction on intracranial structures such as falx cerebri, cerebral blood vessels, and tentorium cerebelli. Distension of blood vessels is another factor contributing to the development of PDPH. Venous enlargement of the lateral sinus was the most prevalent anomaly in PDPH patients' brain MRIs. Tightening of the cranial nerves responsible for ocular movement, particularly cranial nerve six, which has a lengthy intracranial course, causes visual problems. Parasympathetic activity mediated by neurons with synapses in the SPG is one of the contributors to this vasodilation. Vasodilatation is how an SPG block works to relieve headaches, mediated by the neurons in the SPG [2], [3], [5], [6].

PDPH usually appears within 72 h after the dural puncture and dissipates within a week. If we use a blood patch, the headache should go away within 48 h of the procedure. The patient, in this case, did not need a week to be able to carry out everyday activities without getting EBP. A study reported that 69% of patients do not need an epidural blood patch following sphenopalatine ganglion block, which makes SPGB a potential therapy technique [6], [11], [12].

The SPG is placed in the pterygopalatine fossa and runs along the greater petrosal nerve. It consists of somatosensory, sympathetic, and parasympathetic fibers and receives a sensory, motor, and sympathetic root. It is a primarily parasympathetic neural center with many connections to the trigeminal, facial, and sympathetic systems. Due to its complicated nature, sphenopalatine ganglion block has been used for several medical disorders, ranging from low back pain to asthma. It is now mainly used to treat persistent facial pain, migraine, cluster headache, trigeminal neuralgia, local neoplastic compression mechanisms, and myofascial head-and-neck pain. It has also been shown to reduce pain in patients who have had endoscopic sinus surgery [13]. The ganglion is surrounded by a

1–1.5 mm thick layer of connective tissue and mucous membrane; the medication can be injected or applied topically. Although the swab does not make direct contact with the ganglion, the local anesthetic infiltrates around it at that location. The connective tissue and mucous membrane coating aided the dissemination and penetration of the drug [3]. A transoral, infrazygomatic, or intranasal method can be used to block SPG. When this patient is supine, an intranasal technique is used to apply a long cotton swab with lidocaine administered to the posterior nasal cavity through the nose. A study found that this method can also be utilized with a new gadget called Tx360 [13].

The patient, in this case, received therapy in the form of an SPG block right after complaints appeared on the 2nd day of surgery and turned out to give an excellent response. The patient does not require additional analgesic therapy to reduce PDPH symptoms or continue EBP treatment. Several studies and case reports supporting the reduction in pain with SPG blockade with significant value use the visual analog score (VAS). The findings imply that SPGB could be employed as an initial modality in treating PDPH to manage severe pain quickly. Statistical analysis demonstrated comparisons between PDPH patients receiving analgesic therapy and those receiving immediate SPG block. The results showed that patients receiving analgesic therapy had lower pain scores after 4 h. However, SPGB provided adequate pain reduction with the numerical rating scale (NRS) throughout the trial time. Up to 6 h, most patients receiving SPGB did not require rescue analgesia even if no treatment was given [6], [11], [12].

Lidocaine was recognized to have anti-inflammatory and analgesic characteristics. Therefore, it was explored as an intravenous formulation as an alternative to popular therapies like abortive migraine treatments. Lidocaine reduces the activity of voltage-gated sodium channels (VGSCs), which are essential in transmitting pain signals from the peripheral nervous system [12].

Prevention

Findings suggest that inserting an intrathecal catheter after ADP may be a safe and effective way to reduce the incidence of PDPH and the need for a TEBP in obstetric patients [14]. On the contrary, an intrathecal catheter cannot minimize the incidence of PDPH, although it does lessen the requirement for an epidural blood patch, according to systematic reviews. After an accidental dural puncture, the triple preventive regimen of epidural saline, intravenous cosyntropin, and epidural morphine shows tremendous promise in reducing the incidence of PDPH and the requirement for a blood patch in obstetric patients. The synergistic effect of several mechanisms of action addressing multiple levels in the complicated pathophysiology of

PDPH could explain the outcome [15]. By replacing lost corporal fluid and enhancing CSF production, increased fluid intake may prevent a hydrostatic pull on pain-sensitive tissues and vasodilation. Fluid therapy has not been proven to be effective in preventing or treating PDPH. Although the most widely accepted etiology of PDPH is downward pressure on pain-sensitive tissues caused by a cerebrospinal fluid leak from the subarachnoid space, there is little evidence that liberal fluid replacement will enhance CSF volume and prevent PDPH. A study found that limiting fluid therapy was linked to a decreased risk of PDPH following cesarean delivery without affecting the patient's hemodynamic profile [16].

Conclusion

Anesthesiologists should understand the risks and prevention of PDPH to give the appropriate treatment. SPG block can be a minimally invasive treatment for PDPH. In addition, the faster PDPH is treated using an SPG block, the better the patient's pain scale outcome. Several studies have shown that patients who received SPG block therapy did not get an epidural blood patch. In the future, we hope that there will be further studies regarding the timing of PDPH therapy based on the onset and severity of PDPH and its relationship with SPG block.

References

- Bicak M, Salik F, Akelma H. Is there an effect on the development of postdural puncture headache of dural puncture made with the spinal needle in three different orientations during spinal anaesthesia applied to pregnant patients. *J Pain Res.* 2019;12:3167-74. <https://doi.org/10.2147/JPR.S227717>
PMid:31819601
- Yilmaz M, Yilmaz VK, Turan AZ, Turkay, Unal T, Hasan T, *et al.* Transnasal sphenopalatine ganglion block for treatment of post-dural puncture headache in obstetric population. *South Clin Ist Euras.* 2020;31(4):335-9. <https://doi.org/10.14744/scie.2020.39358>
- Nair AS, Rayani BK. Sphenopalatine ganglion block for relieving postdural puncture headache: Technique and mechanism of action of block with a narrative review of efficacy. *Korean J Pain.* 2017;30(2):93-7. <https://doi.org/10.3344/kjp.2017.30.2.93>
PMid:28416992
- Bakshi SG, Gehdoo RS. Incidence and management of post-dural puncture headache following spinal anaesthesia and accidental dural puncture from a non-obstetric hospital: A retrospective analysis. *Indian J Anaesth.* 2018;62(11):881-6. https://doi.org/10.4103/ija.IJA_354_18
PMid:30532325
- Lee GH, Kim J, Kim HW, Cho JW. Comparisons of clinical characteristics, brain MRI findings, and responses to epidural blood patch between spontaneous intracranial hypotension and post-dural puncture headache: Retrospective study. *BMC Neurology.* 2021;21(1):253. <https://doi.org/10.1186/s12883-021-02279-5>
PMid:34187377
- Hanwool RC, Daniel F, Alexander H, Chris L. Intractable post-dural puncture headache (PDPH): A challenging case report. *J Anesth Perioper Med.* 2019;6(1):28-34. <https://doi.org/10.24015/japm.2019.0008>
- Weji BG, Obsa MS, Melese KG, Azeze GA. Incidence and risk factors of postdural puncture headache: Prospective cohort study design. *Perioper Med (Lond).* 2020;9(1):32. <https://doi.org/10.1186/s13741-020-00164-2>
PMid:33292510
- Mehraj A, Raja A, Rehman S, Adil N. To compare the incidence of post dural puncture headache with pencil point 25 gauge whitacre verse cutting 25 gauge quincke spinal needle in patients for c section under spinal anaesthesia. *Pak Armed Forces Med J.* 2020;70(6):1897-01. <https://doi.org/10.37506/ijphrd.v11i5.9321>
- Batova R, Georgiev S. Impact of spinal needle design and approach to postdural puncture headache and spinal anesthesia failure in obstetrics. *Anaesthesiol Intensive Ther.* 2019;51(2):77-82. <https://doi.org/10.5114/ait.2019.86166>
PMid:31268266
- Nasir Z, Mahboob S, Mehmood T, Haider SZ. Post dural puncture headache: A comparison of midline and paramedian approach of spinal anesthesia. *Pak Armed Forces Med J.* 2020;70(4):1188-92.
- Puthenveetil N, Rajan S, Mohan A, Paul J, Kumar L. Sphenopalatine ganglion block for treatment of post-dural puncture headache in obstetric patients: An observational study. *Indian J Anaesth.* 2018;62(12):972-7. https://doi.org/10.4103/ija.IJA_443_18
PMid:30636799
- Khawaja SS, Rafiq MY, Rafi H, Ali S, Sufyan A. Transnasal sphenopalatine ganglion block, an innovative modality for treatment of post dural punctural headache. *Pak Armed Forces Med J.* 2019;69(2):403-7.
- Gunduz OH, Coskun OK. Ganglion blocks as a treatment of pain: Current perspectives. *J Pain Res.* 2017;10:2815-26. <https://doi.org/10.2147/JPR.S134775>
PMid:29276402
- Deng J, Wang L, Zhang Y, Chang X, Ma X. Insertion of an intrathecal catheter in parturients reduces the risk of post-dural puncture headache: A retrospective study and meta-analysis. *PLoS One.* 2017;12(7):e0180504. <https://doi.org/10.1371/journal.pone.0180504>
PMid:28678882
- Perez ER, Sanchez MG, Rocuts A, Jimenez E. Use of a triple prophylactic strategy to prevent post-dural puncture headache: An observational study. *Cureus.* 2020;12(2):e7052. <https://doi.org/10.7759/cureus.7052>
PMid:32219046
- Elsonbaty M, Agiza NA, Abdelbarr T, Salah H. Restrictive versus liberal perioperative fluid strategies to prevent post-dural puncture headache after cesarean delivery. *Ain-Shams J Anesthesiol.* 2021;13:17. <https://doi.org/10.1186/s42077-021-00134-w>