



Evaluation of In-brace Correction in Individuals with Adolescent Idiopathic Scoliosis: A Retrospective and Descriptive Study

Raden Achmad Candra Putra^{1,2} , Danaithep Limskul³, Pattarapol Yotnuengnit⁴, Trai Promsang⁵, Somsak Kuptniratsaikul^{3*}

¹Clinical Sciences Program, Faculty of Medicine, Chulalongkorn University, Bangkok, Thailand; ²Department of Prosthetics and Orthotics, Poltekkes Kemenkes Jakarta I, Jakarta, Indonesia; ³Department of Orthopedics, Faculty of Medicine, Chulalongkorn University, Bangkok, Thailand; ⁴Department of Rehabilitation Medicine, Faculty of Medicine, Chulalongkorn University, Bangkok, Thailand; ⁵Department of Orthopedics, Sikarin Hospital, Bangkok, Thailand

Abstract

BACKGROUND: Achieving maximum correction at the beginning of brace treatment in AIS is the only factor that can be controlled by the bracing provider if we have a better understanding of the prognostics and factors associated with achieving in-brace correction.

AIM: The present study aimed to evaluate in-brace correction in a cohort of AIS patients who were treated by full-time bracing with plastic molded thoracolumbosacral spinal orthosis (TLSO).

METHODS: This study was a retrospective and descriptive study. We screened data from the medical records of individuals with AIS who receiving full-time braces treatment from our orthotic clinic from January 2017 to December 2021. Demographic data including age, gender, weight, height, and body mass index (BMI) were recorded. Cobb angle, Risser sign, and curve type were determined using pre- and post-brace standing post-eroanterior (PA) radiographs. Correlation and the mean difference analysis was performed to investigate in-brace correction with associated factors.

RESULTS: We included 91 patients' data and radiographic images with AIS, with seven (7.69%) boys and 84 (92.31%). The overall mean Cobb angle was $32.9 \pm 8.5^\circ$, and during brace treatment, it was $22.5 \pm 11.5^\circ$. There was a significant mean difference in the mean Cobb angle before and in-brace ($p < 0.001$). The overall mean in-brace correction in the study was $34.1 \pm 22.7\%$. Initial Cobb angle and BMI were found to be significantly negatively associated with in-brace correction with a Pearson coefficient of -0.49 and -0.24 , respectively.

CONCLUSION: The mean of first in-brace correction TLSO was 34.1% from the initial Cobb angle. There was no difference in in-brace correction between curve types. There was a significant Cobb angle changed before and in-brace radiograph. We found that in-brace correction was significantly associated with initial Cobb angle and BMI.

Edited by: Sinisa Stojanoski
Citation: Putra RAC, Limskul D, Yotnuengnit P, Promsang T, Kuptniratsaikul S. Evaluation of In-brace Correction in Individuals with Adolescent Idiopathic Scoliosis: A Retrospective and Descriptive Study. *Open Access Maced J Med Sci.* 2022 May 08; 10(B):1533-1537. <https://doi.org/10.3889/oamjms.2022.9759>
Keywords: Adolescent idiopathic scoliosis; In-brace correction; Bracing

***Correspondence:** Somsak Kuptniratsaikul, Department of Orthopedics, Faculty of Medicine, Chulalongkorn University, Bangkok, Thailand. E-mail: somk50@hotmail.com

Received: 11-Apr-2022

Revised: 26-Apr-2022

Accepted: 28-Apr-2022

Copyright: © 2022 Raden Achmad Candra Putra, Danaithep Limskul, Pattarapol Yotnuengnit, Trai Promsang, Somsak Kuptniratsaikul

Funding: This study was supported by Graduate School Thesis Grant, Graduate School, Chulalongkorn University.

Competing Interests: The authors have declared that no competing interests exist.

Open Access: This is an open-access article distributed under the terms of the Creative Commons Attribution-NonCommercial 4.0 International License (CC BY-NC 4.0)

Introduction

Adolescent idiopathic scoliosis (AIS) is a spinal deformity that affects children between the ages of 10 and 18. The cause of AIS is unknown. It is defined simply by a lateral spine curvature $<10^\circ$ away from the coronal plane [1]. In addition, other planes of spine deformity, such as hyperlordosis in the sagittal plane and vertebral rotation in the transverse plane, might be detected [2]. Globally, AIS affects between 2% and 8% of adolescents aged 10 to 16, where females are more likely to get AIS than males [3], [4].

The treatment of AIS is either conservative or surgery. The scoliosis research society (SRS) suggested that patients with a Cobb angle of $20-40^\circ$ with a remaining growth period can be prescribed for bracing where the Cobb angle is over 45° for surgical consideration [5]. Untreated AIS might cause the curve to develop beyond 60° , which could result in severe back pain and appearance problems [6]. Therefore,

the main goal of conservative treatment is to keep the curve from growing to the point where surgery is needed during the growth period.

A plastic molded thoracolumbosacral orthosis (TLSO) is a common brace type to be prescribed in full-time usage for AIS patients. There has been a long debate about its effectiveness due to insufficient evidence for bracing in AIS. However, a clinical trial in bracing for AIS confirmed the benefit of full-time bracing in significantly lowering the risk of curve progression in AIS [4]. This efficacy of bracing was strengthened by a meta-analysis study by Zhang in 2019 [7], which found that bracing in AIS was effective and safe over the observation. This evidence makes bracing become a primary conservative treatment in AIS for mild-to-moderate curvature at this time.

The successful outcome of bracing in AIS can be influenced by several factors [8], [9], [10]. From the current literature review study, in-brace correction and compliance were found to be important factors in brace outcomes in AIS [8]. From these two factors,

achieving maximum correction at the beginning of brace treatment is the only factor that can be controlled by the bracing provider if we have a better understanding of the prognostics and factors associated with achieving in-brace correction. Meanwhile, compliance mostly depends on a patient's motivation and ability to understand the importance of bracing. Therefore, the evaluation of in-brace correction is an essential aspect for brace providers to improve brace treatment and provide the maximum in-brace correction that AIS patients can achieve with bracing.

The present study aimed to evaluate in-brace correction in a cohort of AIS patients who were treated by full-time bracing with TLSO in the orthotic clinic at King Chulalongkorn Memorial Hospital (KCMH). The result of this first brace correction was compared to the recommended amount of in-brace correction from the previous literatures.

Materials and Methods

This study was a retrospective and descriptive study. We screened medical records of individuals with AIS between January 2017 and December 2021, who had been receiving full-time brace treatment from Orthotic Clinic. Of total 125 patients, 91 patients were included for analysis. The study population ranged in age from 10 to 18 years; the Cobb angle was equal to or $>20^\circ$, and the complete radiograph data set included a post-eroanterior standing radiograph and an in-brace radiograph with no prior treatment. AIS patients with additional secondary diseases and poor radiographic imaging were excluded from screening. Demographic data included age, gender, weight, height, and body mass index (BMI). Cobb angle, Risser sign, and curve type were determined using pre- and post-brace standing post-eroanterior (PA) radiographs. The curve type in the study only included the major curve from each patient. The in-brace correction was calculated as the percent difference between the Cobb angle before brace and the side bending radiograph for in-brace correction, divided by the Cobb angle before brace. This study was approved by Institutional Review Board (IRB) of Chulalongkorn University Faculty of Medicine.

Statistical analysis

Descriptive data were presented in the form of mean \pm standard deviation (SD) for continuous data with a normal distribution, the median (IQR) for non-normal distribution, and the number (percentage) for categorical data. The association between in-brace correction and associated factors was investigated using Pearson's correlation. The mean difference was analyzed by a paired t-test. The mean difference

across binary variables was assessed by the Wilcoxon signed-rank test. The difference between the mean of the Cobb angle and the in-brace correction across categorical variables was assessed using one-way ANOVA for normal distribution data and Kruskal-Wallis for non-normal distribution data. Statistical significance was defined as $p < 0.05$. The statistical analysis was performed using the STATA version 14.1 software (College Station, TX, USA).

Results

The study included 91 patients' data and radiographic images, with seven (7.69%) boys and 84 (92.31%) girls diagnosed with AIS and treated with bracing as the primary treatment. Table 1 describes the demographic characteristics data of included patients in the study. The mean age of patients was 12.95 ± 1.23 years. The mean weight was 46.30 ± 7.67 kg, and the mean height was 157 ± 8.10 cm. The mean BMI was 18.72 ± 2.48 kg/m² during the initial brace treatment. Twelve (14.63%) patients had Risser sign 0, 38 (41.76%) patients had Risser sign 1, and 41 (45.05%) patients had Risser sign 2. Of the 91 patients, 40 (42.12%) had thoracic, 28 (30.77%) had thoracolumbar, and 23 (25.27%) had lumbar curves.

Table 1: Demographic of patients in the study

Variable	Sample (n = 91)
Age (years)	12.95 \pm 1.23
Sex	
Boy	7 (7.69)
Girl	84 (92.31)
Weight (kg)	46.30 \pm 7.67
Height (cm)	157.08 \pm 8.10
BMI (kg/m ²)	18.72 \pm 2.48
Risser sign	
0	12 (13.19)
1	38 (41.76)
2	41 (45.05)
Curve type	
Thoracic	40 (43.96)
Thoracolumbar	28 (30.77)
Lumbar	23 (25.27)

Data are presented as mean \pm SD or numbers (%).

The distribution of Cobb angle before brace treatment, in-brace treatment, and in-brace correction is described in Table 2. Before brace treatment, the overall mean Cobb angle was $32.9 \pm 8.5^\circ$, and during brace treatment, it was $22.5 \pm 11.5^\circ$. There was a significant mean difference in the mean Cobb angle before and in-brace ($p < 0.001$). There was no statistically significant mean difference in Cobb angle before brace and in-brace across curve types with

Table 2: Distribution of Cobb angle and in-brace correction across curve types

Curve types	Cobb angle ($^\circ$)			In-brace correction (%)
	Before brace	In-brace	Mean difference	
All curve (91)	32.9 \pm 8.5	22.5 \pm 11.5	10.3 \pm 6.1*	34.1 \pm 22.7
Thoracic (40)	33.0 \pm 9.4	23.5 \pm 11.6	9.5 \pm 5.4*	31.5 \pm 21.2
Thoracolumbar (28)	33.1 \pm 6.6	22.6 \pm 10.0	10.5 \pm 6.4*	33.4 \pm 22.0
Lumbar (23)	32.3 \pm 9.3	20.8 \pm 13.2	11.4 \pm 7.2*	39.6 \pm 28.6
P	0.126	0.378	0.314	0.128

Data are presented as mean \pm SD. *p-value < 0.001 .

$p = 0.126$ and $p = 0.378$, respectively. The overall mean in-brace correction in the study was $34.4 \pm 22.6\%$. No meaningful difference in in-brace correction was found across the curve types ($p > 0.05$).

The association between in-brace correction and clinical information was analyzed with Pearson's correlation as shown in Table 3. There was a negative significant association between in-brace correction and initial Cobb angle ($r = -0.49$), weight ($r = -0.28$), and BMI ($r = -0.24$). No significant association was found between in-brace correction and age ($r = -0.07$), gender ($r = -0.001$), and height ($r = -0.14$).

Table 3: Correlation analysis between in-brace correction with associated factors

Variables	Correlation coefficient (r)	p
Age	-0.065	0.612
Sex	-0.005	0.961
Height	-0.145	0.123
Weight	-0.304	0.003*
BMI	-0.259	0.012*
Risser	-0.122	0.248
Initial Cobb angle	-0.487	< 0.001*

*Significant $P < 0.05$.

The effect of in-brace correction was also analyzed according to the skeletal maturity measured by the Risser sign as shown in Figure 1. The amount of in-brace correction was not found to be a statistically significant difference across the Risser sign ($p = 0.331$). In addition, no statistically significant difference in in-brace correction was also observed between boys and girls ($p = 0.887$) in Figure 2. We also analyzed BMI stratified into three categories suggested for the Asian population, which consist of underweight (<18.5), normal (18.5–22.9), and overweight (23–27.5). As shown in Figure 3, overweight patients had a lower median of in-brace correction of 17.75% (15.80%) compared to normal-weight patients, who had a median of 23.28% (35.41%) and underweight patients who had a median of 34.63% (31.25%). Because the number of overweight patients in our study was limited to only six patients and the data were not normally distributed, a non-parametric Kruskal–Wallis test was performed. There was a statistically significant in-brace correction found across different categorical BMI ($p > 0.05$).

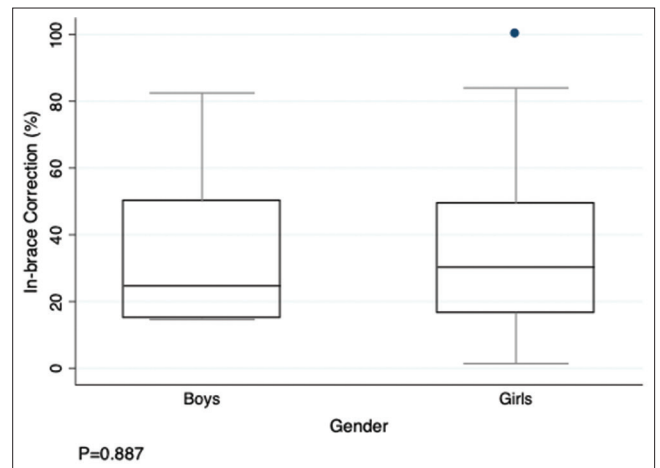


Figure 2: Box plot distribution of in-brace correction by gender

Discussion

The effectiveness of using braces as a main conservative treatment for AIS was described in the previous studies [4], [7]. A recent literature review discovered evidence of several factors that may contribute to the effectiveness of bracing in AIS, including the type of prescribed brace, in-brace correction, compliance, BMI, curve magnitude, and specific exercise for scoliosis [8]. In addition, it found that in-brace correction is one of the important factors for bracing in AIS to be successful besides compliance [8]. Similarly, a study by Boogart *et al.* also found that strong evidence of low initial brace correction was associated with brace failure.

There was no clear information on the minimum in-brace correction to be achieved for bracing to be successful. Knott *et al.* suggested that 50% in-brace must be achieved to optimize the braces outcomes [11]. However, several studies have found different cutoff points for in-brace correction in AIS [9], [12], [13], [14], [15], [16], [17], [18], making it difficult to determine what a specific number of corrections must be achieved during initial brace wearing. Several

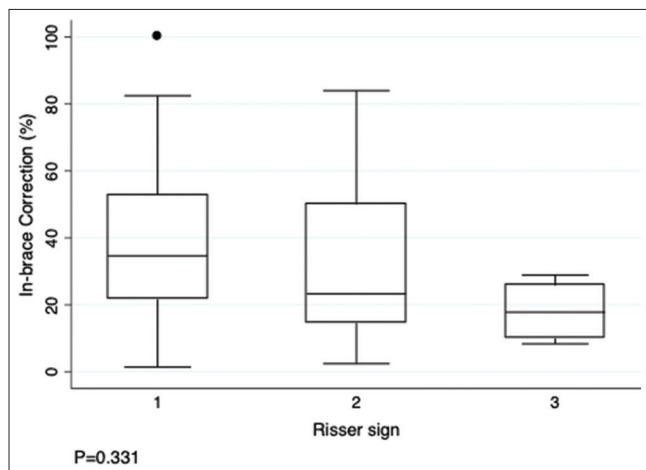


Figure 1: Box plot distribution of in-brace correction by Risser sign

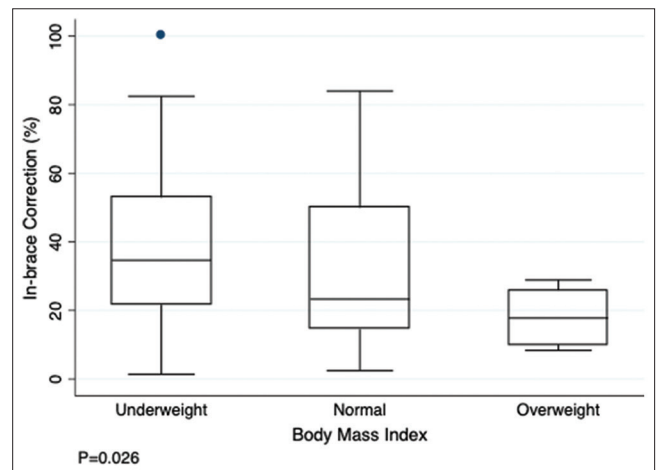


Figure 3: Box plot distribution of in-brace correction by body mass index

factors were investigated for their association with the in-brace correction to maximize the results. A study by Lang *et al.* found that in-brace correction was associated with initial Cobb angle, sagittal and coronal balance, and LPR [19]. In the current literature study, strong evidence was found between flexibility and in-brace correction and moderate evidence for curve pattern influencing in-brace correction [20].

The mean in-brace correction in this study was 34.1% for all major curve types. Our in-brace correction result is comparable to the previous studies using the full-time Boston brace principle, with 35–50% in-brace correction [15], [21]. The study by Katz, 2001 [15] described a minimum of 25% of in-brace correction and showed a high success rate with a minimum of 18 h/day of bracing. Goodbody *et al.* [14] suggested a minimum of 45% of in-brace correction increased the success rate at the end of treatment. Another study by Xu *et al.* [18] found that the cutoff point for in-brace correction was 10% for a successful brace outcome. Although there was no clearly described cutoff point for in-brace correction for successful brace treatment, there was strong evidence that greater in-brace correction increased the likelihood of success rate of brace treatment in AIS [9].

There was no clear information on how the curve pattern affects in-brace correction. Nissen *et al.* [22] found that the thoracic curve had significantly less in-brace correction compared to the lumbar and thoracolumbar curves. Similarly, a study by Chan *et al.* [23] also reported that AIS patients with a thoracic curve had lower initial brace correction than thoracolumbar or lumbar curves. In contrast, a study by Lang *et al.* [19] found that there was no significant mean Cobb angle difference in the thoracic, lumbar, and thoracolumbar. Descriptively, our study showed that the thoracic curve had the lowest mean in-brace correction (31.5%), followed by the thoracolumbar (33.4%) and lumbar (39.6%) curves. However, there was no statistically significant difference in mean in-brace correction across these curve types.

The finding of the present study was that initial Cobb angle and BMI influenced the amount of in-brace correction. Our study found that the initial Cobb angle had a negative correlation with in-brace correction. Similar findings were observed in the previous studies which found a negative significant association between the initial Cobb angle and in-brace correction [19], [24]. This finding shows that the large Cobb angle magnitude makes the curve more difficult to correct. Late detection of spinal deformity is commonly associated with a large Cobb angle magnitude at initial brace treatment. Early detection of scoliosis would help AIS patients because it would allow them to start bracing while the Cobb angle is still low, which would help them get the best results from bracing.

Although low evidence was found in the association of BMI and in-brace correction in a previous review study [20], this present study found a significant

negative correlation between in-brace correction and BMI. Similarly, a study by Goodbody *et al.* [14] concluded that overweight AIS patients had lower results in immediate brace correction as compared to the normal-weight group. However, in contrast to our finding for underweight patients, this study also found the association of brace failure with the low BMI group. Failure of brace treatment in the overweight group is mostly caused by low in-brace correction and compliance. Further study into improving in-brace correction in a group of overweight AIS patients might benefit for this group of patients.

This present study was the first evaluation describing TLSO in-brace correction for AIS at King Chulalongkorn Memorial Hospital. The limitation of this study was conducted in retrospective nature, where variables included for analysis were only based on available data at our institution. In-brace correction radiograph was performed within 2–4 weeks after the brace had been checked out by a physician. Adjustment for correction could be done if the correction was insufficient. Alvarez *et al.* [25] described the importance of having additional X-ray after a major brace adjustment to accurately monitor the real in-brace correction. However, to prevent too much radiation exposure, the more in-brace correction X-ray was not recommended. A study by Lou *et al.* [26] suggested utilizing ultrasound in assisting brace casting and in-brace correction monitoring while reducing radiation exposure.

Conclusion

The mean of the first in-brace correction TLSO was 34.1% of the initial Cobb angle. There was no difference in in-brace correction across curve types. There was a significant Cobb angle change between before brace and in-brace radiographs. We found that in-brace correction was significantly associated with initial Cobb angle and BMI. Analysis of associated factors of this study provided important information to improve initial-brace correction in AIS. Prospective research on the topics of how to improve in-brace correction in overweight AIS patients and the feasibility of ultrasound as a monitoring tool for brace treatment in AIS patients is suggested for further study to improve brace outcomes.

Ethical Approval

This research was reviewed and approved by Institutional Review Board, Faculty of Medicine, Chulalongkorn University, Bangkok, Thailand.

References

- Negrini S, Donzelli S, Aulisa AG, Czaprowski D, Schreiber S, De Mauroy JC, et al. 2016 SOSORT guidelines: Orthopaedic and rehabilitation treatment of idiopathic scoliosis during growth. *Scoliosis Spinal Disord.* 2018;13:3. <https://doi.org/10.1186/s13013-017-0145-8>
PMid:29435499
- Miller MD, Thompson SR, Hart JA. *Review of Orthopaedics.* 6th ed. Philadelphia, PA: Elsevier Saunders; 2012.
- Konieczny MR, Senyurt H, Krauspe R. Epidemiology of adolescent idiopathic scoliosis. *J Child Orthop.* 2013;7(1):3-9. <https://doi.org/10.1007/s11832-012-0457-4>
PMid:24432052
- Weinstein SL, Dolan LA, Wright JG, Dobbs MB. Effects of bracing in adolescents with idiopathic scoliosis. *N Engl J Med.* 2013;369(16):1512-21. <https://doi.org/10.1056/nejmoa1307337>
PMid:24047455
- Richards BS, Bernstein RM, D'Amato CR, Thompson GH. Standardization of criteria for adolescent idiopathic scoliosis brace studies: SRS Committee on bracing and nonoperative management. *Spine.* 2005;30(18):2068-75. <https://doi.org/10.1097/01.brs.0000178819.90239.d0>
PMid:16166897
- Weinstein SL, Dolan LA, Spratt KF, Peterson KK, Spoonamore MJ, Ponseti EV. Health and function of patients with untreated idiopathic scoliosis: A 50-year natural history study. *JAMA.* 2003;289(5):559-67. <https://doi.org/10.1001/jama.289.5.559>
PMid:12578488
- Zhang Y, Li X. Treatment of bracing for adolescent idiopathic scoliosis patients: A meta-analysis. *Eur Spine J.* 2019;28(9):2012-9. <https://doi.org/10.1007/s00586-019-06075-1>
PMid:31332572
- Karavidas N. Bracing in the treatment of adolescent idiopathic scoliosis: Evidence to date. *Adolesc Health Med Ther.* 2019;10:153-72. <https://doi.org/10.2147/ahmt.s190565>
PMid:31632169
- Van den Bogaart M, Van Royen BJ, Haanstra TM, De Kleuver M, Faraj SS. Predictive factors for brace treatment outcome in adolescent idiopathic scoliosis: A best-evidence synthesis. *Eur Spine J.* 2019;28(3):511-25. <https://doi.org/10.1007/s00586-018-05870-6>
PMid:30607519
- Hawary RE, Zaa-roor-Regev D, Floman Y, Lonner BS, Alkhalife YI, Betz RR. Brace treatment in adolescent idiopathic scoliosis: Risk factors for failure—a literature review. *Spine J.* 2019;19(12):1917-25. <https://doi.org/10.1016/j.spinee.2019.07.008>
PMid:31325626
- Knott P, Techy F, Cotter T, Jansen L, Kove P, Loving J, et al. Retrospective analysis of immediate in-brace correction of scoliosis attainable in patients with AIS: A SOSORT initiative. *Scoliosis.* 2013;8(Suppl 1):O49. <https://doi.org/10.1186/1748-7161-8-S1-O49>
- Castro FP. Adolescent idiopathic scoliosis, bracing, and the Hueter-Volkman principle. *Spine J.* 2003;3(3):180-5. [https://doi.org/10.1016/s1529-9430\(02\)00557-0](https://doi.org/10.1016/s1529-9430(02)00557-0)
PMid:14589197
- De Mauroy JC, Lecante C, Barral F, Pourret S. Prospective study and new concepts based on scoliosis detorsion of the first 225 early in-brace radiological results with the Lyon brace: ARTbrace. *Scoliosis.* 2014;9:19. <https://doi.org/10.1186/1748-7161-9-19>
PMid:25741377
- Goodbody CM, Asztalos IB, Sankar WN, Flynn JM. It's not just the big kids: Both high and low BMI impact bracing success for adolescent idiopathic scoliosis. *J Child Orthop.* 2016;10(5):395-404. <https://doi.org/10.1007/s11832-016-0763-3>
PMid:27501808
- Katz DE, Durrani AA. Factors that influence outcome in bracing large curves in patients with adolescent idiopathic scoliosis. *Spine (Phila Pa 1976).* 2001;26(21):2354-61. <https://doi.org/10.1097/00007632-200111010-00012>
PMid:11679821
- Landauer F, Wimmer C, Behensky H. Estimating the final outcome of brace treatment for idiopathic thoracic scoliosis at 6-month follow-up. *Pediatr Rehabil.* 2003;6(3-4):201-7. <https://doi.org/10.1080/13638490310001636817>
PMid:14713586
- Weiss HR, Rigo M. Expert-driven Chêneau applications: Description and in-brace corrections. *Physiother Theory Pract.* 2011;27(1):61-7. <https://doi.org/10.3109/09593985.2010.503991>
PMid:21198406
- Xu L, Qin X, Qiu Y, Zhu Z. Initial correction rate can be predictive of the outcome of brace treatment in patients with adolescent idiopathic scoliosis. *Clin Spine Surg.* 2017;30(4):E475-9. <https://doi.org/10.1097/BSD.0000000000000343>
PMid:28437355
- Lang C, Huang Z, Sui W, Di M, He S, Fan H, et al. Factors that influence in-brace correction in patients with adolescent idiopathic scoliosis. *World Neurosurg.* 2019;123:e597-603. <https://doi.org/10.1016/j.wneu.2018.11.228>
PMid:30529518
- Peeters CM, Van Hasselt AJ, Wapstra FH, Jutte PC, Ruth Kempen DH, Faber C. Predictive factors on initial in-brace correction in idiopathic scoliosis: A systematic review. *Spine (Phila Pa 1976).* 2022;47(8):E353-61. <https://doi.org/10.1097/BRS.0000000000004305>
PMid:35500086
- Yrjönen T, Ylikoski M, Schlenzka D, Poussa M. Results of brace treatment of adolescent idiopathic scoliosis in boys compared with girls: A retrospective study of 102 patients treated with the Boston brace. *Eur Spine J.* 2007;16(3):393-7. <https://doi.org/10.1007/s00586-006-0167-z>
PMid:16909249
- Ohrt-Nissen S, Hallager DW, Gehrchen M, Dahl B. Supine lateral bending radiographs predict the initial in-brace correction of the providence brace in patients with adolescent idiopathic scoliosis. *Spine (Phila Pa 1976).* 2016;41(9):798-802. <https://doi.org/10.1097/BRS.0000000000001519>
PMid:26909835
- Chan SL, Cheung KM, Luk KD, Wong KW, Wong MS. A correlation study between in-brace correction, compliance to spinal orthosis and health-related quality of life of patients with adolescent idiopathic scoliosis. *Scoliosis.* 2014;9(1):1. <https://doi.org/10.1186/1748-7161-9-1>
PMid:24559234
- Weiss HR, Werkmann M, Stephan C. Correction effects of the ScolioOlogiC "Chêneau light" brace in patients with scoliosis. *Scoliosis.* 2007;2(1):2. <https://doi.org/10.1186/1748-7161-2-2>
PMid:17257399
- Alvarez I, Poppino K, Karol L, McIntosh AL. Lack of in-brace x-rays in compliant AIS patients wearing full-time TLSO braces associates with failure. *J Orthop Surg Res.* 2021;16(1):540. <https://doi.org/10.1186/s13018-021-02650-9>
PMid:34465348
- Lou EH, Hill DL, Donauer A, Tilburn M, Hedden D, Moreau M. Results of ultrasound-assisted brace casting for adolescent idiopathic scoliosis. *Scoliosis Spinal Disord.* 2017;12:23. <https://doi.org/10.1186/s13013-017-0130-2>
PMid:28795156