



Effect of Hydrogel Use on Healing Diabetic Foot Ulcers: Systematic Review

Armayani Armayani^{1,2}, Anisa Purnamasari¹, La Ode Reskiadin³, Lisnawati Lisnawati¹, Nazaruddin Nazaruddin¹, Indra Indra¹, Wa Ode Aisa Zoahira¹, Fauziah H. Wada⁴, Amzal Mortin Andas^{2,5*}

¹Nursing Study Program, Faculty of Health Sciences, Mandala Waluya University, Kendari, South East Sulawesi, Indonesia; ²Doctoral Student of Nursing, Lincoln University Malaysia, Kota Bharu, Malaysia; ³Public Health Study Program, Faculty of Medicine and Health Sciences, Universitas Jambi, Jambi, Indonesia; ⁴Department of Maternity Nursing, Bani Saleh College of Health Sciences, Bekasi, Indonesia; ⁵Department of Medical Surgical Nursing, Bani Saleh College of Health Sciences, Bekasi, Indonesia

Abstract

BACKGROUND: The prevalence of diabetic foot ulcers in Indonesia with an amputation rate of 15%, a mortality rate of 32%, and diabetic ulcers as the cause of hospitalization is 80%. One of the treatments for diabetic foot ulcers is using a hydrogel dressing.

AIM: This systematic review aims to determine the effect of using hydrogel on the healing of diabetic foot ulcers.

METHODS: The design in this scientific paper is a systematic review by searching using an electronic database, namely, Semantic Scholar and PubMed. The keywords used in the search are; diabetic foot ulcer OR diabetic foot wound AND hydrogel dressing OR hydrogel use AND wound healing. With accessible inclusion criteria, the subject is patients with diabetic foot ulcers, Fulltext manuscript, the language used is Indonesian and English, published in the past 10 years, according to the research topic.

RESULTS: Based on a review of the systematic review of two articles, it shows that healing of diabetic foot ulcers using hydrogel is quite short, 7–9 days good changes have been seen, and starting to have granulation tissue, namely, the color of the wound is bright red and the edges of the wound are clearly visible.

CONCLUSION: Of the systematic review show that hydrogel can help heal diabetic foot ulcers.

Edited by: Eli Djulejic
Citation: Armayani A, Purnamasari A, Ode Reskiadin L, Lisnawati L, Nazaruddin N, Indra I, Aisa Zoahira WO, Wada FH, Andas AM. Effect of Hydrogel Use on Healing Diabetic Foot Ulcers: Systematic Review. Open Access Maced J Med Sci. 2022 Feb 05; 10(F):448-453. <https://doi.org/10.3889/oamjms.2022.9835>
Keywords: Hydrogel; Diabetic foot ulcer; Wound Healing
***Correspondence:** Amzal Mortin Andas, Doctoral Student of Nursing at Lincoln University Malaysia, Malaysia. E-mail: andazmortin.ai@gmail.com
Received: 03-May-2022
Revised: 17-May-2022
Accepted: 20-May-2022
Copyright: © 2022 Armayani Armayani, Anisa Purnamasari, La Ode Reskiadin, Lisnawati Lisnawati, Nazaruddin Nazaruddin, Indra Indra, Wa Ode Aisa Zoahira, Fauziah H. Wada, Amzal Mortin Andas
Funding: This study was supported by Stikes Bani Saleh
Competing Interests: The authors have declared that no competing interests exist
Open Access: This is an open-access article distributed under the terms of the Creative Commons Attribution-NonCommercial 4.0 International License (CC BY-NC 4.0)

Introduction

Diabetes is a metabolic disorder characterized by high blood sugar levels or hyperglycemia and is associated with metabolic abnormalities of carbohydrates, fats and proteins [1]. The International Diabetic Federation (IDF) estimates that the number of diabetes continues to increase, including in Indonesia [2]. One of the chronic complications of diabetes is diabetic foot ulcer (DFU) [3]. The prevalence of diabetic foot ulcers (DFU) varies from about 1% in Europe, and more than 11% in reports from several African countries [4]. Patients with DFU in Indonesia are 15%, with an amputation rate of 30%, a mortality rate of 32%, and diabetic ulcers are the most common cause of hospitalization by 80% [5].

Diabetic foot ulcers are abnormalities that occur in diabetic feet and are caused by foot vascular disorders, nerve disorders, and infection due to decreased immune system. These problems can cause calluses (callus), cracked skin (fissures), and

inflammation of the big toe [6]. There are several etiologies of DFU itself including neuropathic, ischemic and neuroischemic. Neuroischemia is a combination of diabetic neuropathy with ischemia in which macrovascular disease and microvascular dysfunction impair perfusion in the diabetic foot [6].

Factors that influence the occurrence of diabetic foot ulcers (DFU) are gender where men are more dominant, duration of DM disease where from 100% of patients with diabetes mellitus (DM) with diabetic foot ulcers (DFU) 58% were found in patients with diabetes mellitus (DM) more than 10 years, then neuropathy that causes motor nerve disorders (muscle atrophy, foot deformity, changes in foot biomechanics, and disturbed foot pressure distribution), sensory nerve disorders (loss of sensation or feeling numb), and autonomic nerves (slight secretion of sweat so that feet become dry and easy to form fissures), and finally, Pheripheal Artery Disease (PAD) which is a disease of arterial blockage in the lower extremities caused by atherosclerosis; and foot care which is the primary prevention of DFU [7].

Diabetic foot ulcer (DFU) including complex chronic wounds has a large long-term impact on patient morbidity, mortality, and quality of life. Individuals who develop diabetic foot ulcers are at greater risk of premature death, myocardial infarction, and fatal stroke than those without a history of diabetic foot ulcers [8]. Unlike other chronic wounds, development of diabetic foot ulcers is very difficult because of the wide range of diabetic changes, such as neuropathy and diabetes vascular disease. This, together with the altered neutrophil function, reduced tissue perfusion and impaired protein synthesis often accompany diabetes, present practitioners with specific, and unique management challenges [9].

Management of DFU is divided into two, namely, pharmacological and non-pharmacological therapy. Non-pharmacological therapy is using a moist wound care method or moisture balance known as modern dressing. One of them is a dressing made from natural or synthetic materials, namely, hydrogel [10]. In addition to hydrogel, you can also use additional therapy, namely, Hyperbaric Oxygen Therapy [11]. The role of hyperbaric oxygen (HBO) is to improve the amount of oxygen delivered to the wound area, both bound to hemoglobin and dissolved in plasma [12]. And pharmacologically the treatment of diabetic foot ulcers requires the use of antibiotics which are usually in collaboration with a doctor. However, the use of antibiotics that are used inappropriately can result in not achieving therapeutic goals and developing antibiotic resistance [9].

Hydrogel wound dressing is a polymer wound dressing with the highest global use reaching 43% which has transparent, soft, flexible, and non-irritating characteristics. Hydrogels have compound release properties (transport media) so that they can be applied in wound healing management. Hydrogels can be produced from natural or synthetic polymers or the addition of both to obtain the best properties. However, the average use of hydrogels is still very limited because of the high price [13]. The gel is excellent at creating and maintaining a moist wound healing environment. The purpose of wound care using a moist dressing is to maintain a moist and protected wound environment isolation during the healing process to accelerate healing by 45% and reduce the occurrence of infectious complications and the growth of residual scar tissue. The benefits of the hydrogel itself are to lyse/maintain moisture around the wound, and can also help the sloughing of necrotic tissue that is black (black necrotic tissue), or yellow-brown (sloightly) automatically by the body itself (autolysis debridement) and granulation tissue can grow faster [14].

The current phenomenon in the community is that there are many people with diabetes mellitus who experience diabetic foot ulcers and lead to amputation, on average after amputation they experience shame because of disability. From a preliminary study that the author did while practicing at a wound clinic, it was found

that patients with diabetic foot wounds were treated with hydrogel dressings, because hydrogel has soft, non-irritating properties, cools the wound and can also help slough off necrotic tissue (autolysis debridement). Treatment and dressing changes were carried out every 3 days, judging by the results of documentation and information at the clinic, initially the wound was black, the edges of the wound were irregular, and the diameter was quite wide but after 3 x treatment, that is for 9 days.

Researcher Zhang *et al.* [15] stated the results of his research on the comparison of wound care using hydrogel with NaCl 0.9% that wound care using NaCl 0.9% the average value of wound healing was 45.08 while the hydrogel was 15.92 which means wound healing using hydrogel 3× more effective compared to 0.9% NaCl. The mean value in the study using NaCl from 23.26 to 20.67 only decreased by 3 points, in contrast to the use of hydrogel, the change in the mean from 23.63 to 10.00, which decreased to 13 points in 9 days. The range of status according to Betes-Jansen the smaller the mean value of eating closer to healthy tissue, then the use of hydrogel is more effective because the value of wound healing tends to be closer to wound regeneration [14].

Based on the previous research data and preliminary studies conducted by the author, it is known the ability of hydrogel dressings to help slough off necrotic tissue and to moisturize so that it is not irritating. However, it has not been seen how much influence the use of hydrogel has on healing diabetic foot ulcers. Therefore, the authors are interested in conducting a study on several scientific articles to determine the effect of using hydrogel on the healing of diabetic foot ulcers.

Objective

The purpose of this systematic review is to find out the Effect of Using Hydrogel on Healing Diabetic Foot Ulcers.

Methods

PICOT formulation

Effect of hydrogel use on diabetic foot ulcers. One of the chronic complications of diabetes is diabetic foot ulcer (DFU) in the form of an open wound on the skin surface which can be accompanied by local tissue death and can lead to amputation. According to the American Diabetes Association, diabetic foot ulcers account for approximately 12–15% of all diabetics and are usually located in the lower extremities, to avoid amputation in the lower extremities through non-pharmacological treatment, namely, hydrogel. Hydrogel

is a polymer wound dressing with the highest global use reaching 43% which has the characteristics of being transparent, soft, flexible, and non-irritating [10].

To find out the evidence based on the effect of using hydrogel on diabetic foot ulcers, a literature search was carried out with the PICOT formulation as follows:

Population: Diabetic foot ulcer/diabetic foot ulcer

Intervention: Hydrogel/hydrogel dressing

Comparison:

Outcome: Wound Healing

Time: 2011–2021

Based on the PICOT analysis above, the authors formulate research questions, namely, how is the effect of using hydrogel on diabetic foot ulcers?

Search strategy

The literature search was carried out by searching for article publications from the Health and medical Education literature, the search was carried out using databases: Google scholar, semantic scholar, PubMed, science direct, Garuda, ProQuest, and DOAJ. Search literature using keywords in Indonesian: Diabetic foot ulcers OR diabetic foot wounds AND hydrogel dressing OR use of hydrogel AND wound healing. Keyword in English: Diabetic foot ulcer OR diabetic foot lesion AND application hydrogel OR hydrogel dressing AND wound healing. Found 433 articles relevant to keywords, consisting of Google Scholar (12), Semantic Scholar (1), PubMed (87), Science Direct (333), Garuda (0), ProQuest (0), and DOAJ (0) (Figure 1).

After that, the year limitation was carried out with a span of the past 10 years (2011-2021) and 128

articles were obtained, namely on Google Scholar 11 articles, Semantic Scholar 1 article, PubMed 77 articles, Science Direct 39 articles, then reading the titles one by one and also selecting the appropriate journals with the inclusion criteria (articles published from 2011 to 2021, in Indonesian and English, free of charge, full text), only two articles were found that matched the title with the keywords above (Table 1). Database Used: Google scholar, semantic scholar, PubMed, and science direct. Garuda, proquest, and DOAJ (The Directory Of Open Access Journals) With keywords: Diabetic foot ulcer OR diabetic foot wound AND hydrogel dressing OR hydrogel application AND wound healing. Diabetic foot ulcer OR diabetic foot lesion AND hydrogel dressing OR application hydrogel AND wound healing.

Discussion

Social demographic characteristics

The characteristics of the intervention respondents at age <50 years were 3 people, 50–60 years the most were 20 people, and with age > 60 years there were 7 people, but here it is not explained about gender [17]. Characteristics of respondents for the level of education are not in school – SD 7 people, SMP – SMA 20 people, and college 3 people. Then the characteristics of the respondents based on the location of the wound and the degree of injury: Deep ulcers with abscess and inflammation were 18 people, gangrene of the forefoot or heel was 11 people, and gangrene of the whole foot or part of the heel was 1 person.

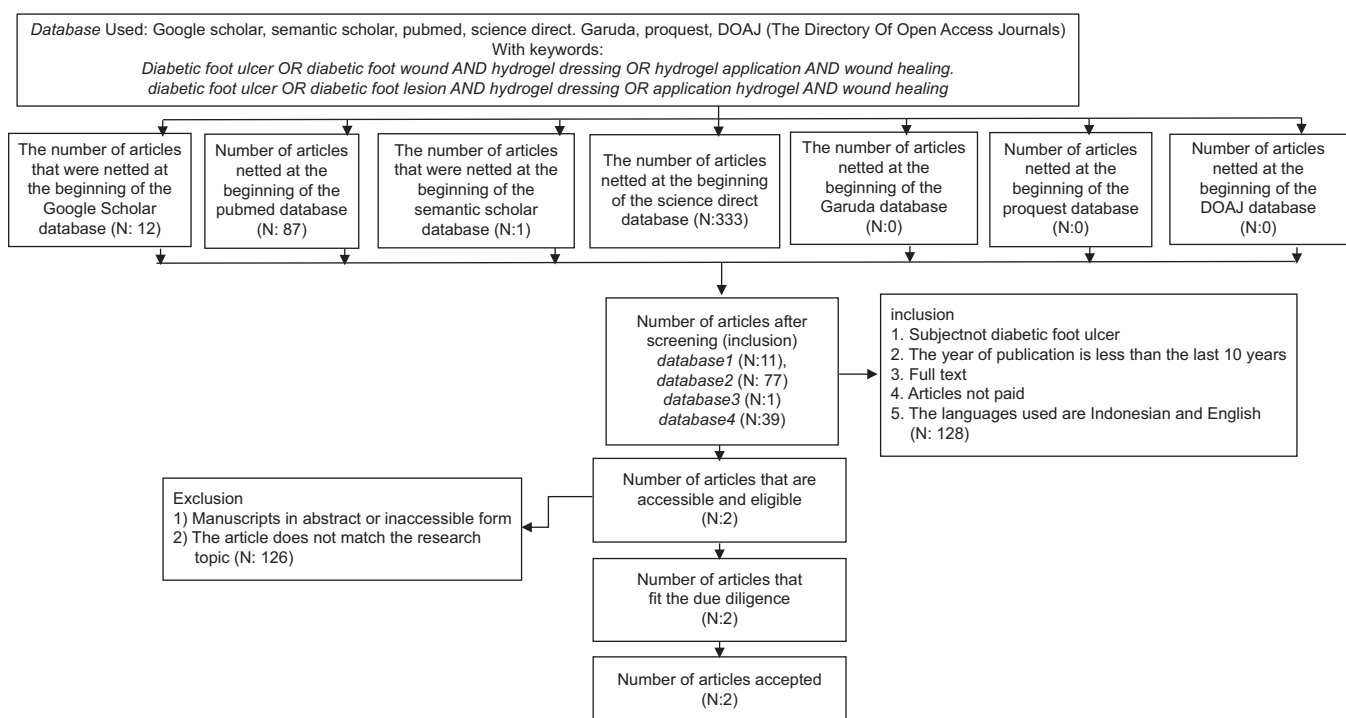


Figure 1: Flowchart of the investigation

Table 1: Results

No	Title/Author name, author	Journal name	Research purposes	Population and sample	Types of research	Method of collecting data	Important findings
1	Title: Wound healing using 0.9% NaCl and Hydrogel for Diabetes Mellitus Ulcers at Semarang City General Hospital Purnomo et al. [16]	UNIMUS Journal (University of Muhammadiyah Semarang)	To determine the effectiveness of wound healing with 0.9% NaCl and hydrogel on ulcers diabetes mellitus.	The whole population diabetic patients with ulcers. The sampling technique uses purposive sampling so that samples obtained in the hydrogel group of 30 people, in the 0.9% NaCl group 30 people.	This type of research is quantitative using an experimental design. Using an instrument measuring the range of wound status.	Data collection in this study used an instrument, namely an observation sheet on diabetic foot ulcer patients who were given hydrogel intervention and 0.9% NaCl. Intervention and observation in patients who were given hydrogel was 3 days once for 9 days, whereas in patients who were given NaCl, observations and interventions were carried out every day. Observations were carried out longitudinally, namely an instrument to measure the process of wound development using an assessment of the range of wound status of Bates Jansen. To know the progress of the wound with each intervention.	Healing of diabetes mellitus ulcers using 0.9% NaCl compresses did not show significant improvement/changes. The Bates-Jansen score in 9 days of treatment has decreased between 2 and 3 points, so it takes a long time to achieve regeneration-maturation grade wound repair. Whereas in the hydrogel group, the wound score decreased between 10 and 13 points, with the wound edges being clearly distinguished and adjacent to the wound bed, the color of the wound was bright red or whitish to the touch. This means that hydrogel is 3 times more effective than 0.9% NaCl because the smaller the mean value of wound healing, the closer to healthy tissue.
2	Title: A diabetic foot ulcer treated with hydrogel and hyperbaric oxygen therapy: a case study Aguiar et al. [17]	Journal of Wound care	To determine the development of wounds treated with hydrogels and hyperbaric oxygen therapy, and to determine the efficacy of topical hydrogels in conjunction with HBOT on the healing process of diabetic foot wounds to improve recovery and quality of life.	There is 1 group with the population of elderly patients, diabetics Hydrogel group with hyperbaric oxygen with sample 1 person, namely a 71-year-old man with type 2 diabetes	This type of research is a case study in the Joint Hydrogel group with hyperbaric oxygen (HBOT).	In this case study group 1: hyperbaric oxygen was administered 5 times a week for 60 days, while dressing changes and hydrogel were administered once a day for 60 days. (60 treatment sessions) Data collection techniques by collecting the results of clinical history and physical examination tests of patients once a week, recording photos of injuries, and observing every time a dressing is changed, namely every day for 60 days, observations by measuring wound size, wound depth, wound edge condition, area necrotic tissue, type of exudate, amount of exudate, condition of the skin around the wound, peripheral edema, size of granulation tissue, and size of epithelialization.	The results of the article showed that the cure of DFU with the use of a combination of topical hydrogel and oxygen supply increased the healing of DFU. After 7 days of treatment there was a reduction in edema, and there was granulation tissue in the wound bed. In the 19 th session, granulation continued to be observed, wound contraction decreased. Session 26 had well vascularized granulation tissue, lower fibrinous count, less edema around the wound, better wound appearance with regular wound edges and reduced wound size. The hydrogel keeps the wound moisture level stable without causing skin maceration. In session 46 the formation of granulation tissue remained, there was less and less fibrinous, the depth of the wound decreased, the open area continued to decrease, the epithelium began to cover almost the entire surface and edges of the wound. In session 58 the open wound fell further. And the patient underwent a total of 60 sessions without complications.

Then research with a diabetic foot ulcer that was treated with hydrogel and hyperbaric oxygen therapy with a case study research design or a case study with a case of a 71 year old patient with type 2 diabetes who came to the RSU with a bullous wound on the left toe that worsened so that it had to be amputated. Angiotomography of the lower leg shows marked atheromatous disease of the arteries, with moderate (50–75%) stenosis in the middle third of the left superficial femoral artery. The post-operative wound had malodorous serosanguinous drainage, and necrotic areas with exposed muscles and tendons [18].

The results of the study in the two articles above show that the characteristics of respondents in the use of hydrogels in healing diabetic foot ulcers do not limit age, from preschool children to over 60 years of age can use hydrogel as a topical to help heal diabetic foot ulcers.

Interventions and instruments

Study Purnomo *et al.*, (2014) perform hydrogel intervention for diabetic ulcer healing. The goal is to maintain the isolation of the wound environment so that moisture remains and reduces the risk of infection. Treatment is carried out every 3 days 1 time for 9 days. Observations were carried out longitudinally, namely both measuring wound status using the Bates-Jansen wound assessment instrument, namely evaluating wound size, wound depth, wound edge condition, tunneling in the wound, type of necrotic tissue, area of necrotic tissue, type of exudate, amount of exudate, skin condition around the wound, peripheral edema, granulation tissue size, and epithelialization size every dressing change that is every 3 days.

Research conducted by Aguiar *et al.*, (2017), namely, by changing the hydrogel dressing every day for

60 days. The wound was cleaned with 0.9% saline, and then hydrogel was applied and closed using a secondary dressing. During the treatment the patient was measured blood pressure, heart rate, respiratory rate, temperature, and blood glucose. Patients were instructed to stick to a diet and control blood sugar, maintain, and protect the wound from injury and get plenty of rest. In addition, every change of dressing on the wound, photographic documentation and observations of the wound are taken, in the form of wound size, wound depth, wound edge condition, necrotic tissue area, type of exudate, amount of exudate, condition of the skin around the wound, peripheral edema, size of granulation tissue, and the size of the epithelialization. According to the researcher, the research above shows that wound care using hydrogel dressings can help accelerate wound healing.

Comparison/ratio

On research Purnomo *et al.*, (2014), made a comparison of two groups, namely, the group treated with a hydrogel dressing and the group treated with a 0.9% NaCl dressing. Observations were carried out longitudinally, namely, both measuring wound status using the Bates-Jansen wound assessment instrument for each wound treatment carried out, namely, evaluating wound size, wound depth, wound edge condition, tunneling of the wound, type of necrotic tissue, area of necrotic tissue, type of exudate, the amount of exudate, the condition of the skin around the wound, peripheral edema, the size of the granulation tissue, and the size of the epithelialization. In wound care using hydrogel, the observations were carried out according to the dressing change schedule. While wound care using 0.9% NaCl, observations were made every day. Measurements were carried out by the researcher and his assistant.

The results of the comparison of the two in the first 3 days have not seen a change, but on the 6th and 9th days there is a very significant change in the results of measurements and observations, the mean value using NaCl from 23.26 to 20.67 in 9 days only experienced 3 points. Whereas in wound care using hydrogel, the mean value was obtained from 23.63 to 10.00, namely, the wound score decreased between 10 and 13 points, with the edges of the wound being clearly distinguishable and adjacent to the wound bed, the color of the wound was bright red or whitish to the touch. This can be seen in the range of wound status according to Bates-Jansen, the smaller the mean value of wound healing, the closer to healthy tissue. It was seen that hydrogel was proven to be 3 times more effective than 0.9% NaCl.

Hydrogel effectiveness

Researcher Purnomo *et al.*, (2014), stated that the results of observations after the 3rd day were not too visible, but on the 6th and 9th days the change was obtained

from the mean value from 23.63 to 10.00, that is, the wound score decreased between 10 and 13 points, with a sharp edge of the wound. Clearly distinguishable and adjacent to the wound bed, the color of the wound is bright red or whitish to the touch. The value of 10.00 based on the Bates-Jansen wound status range was included in the wound regeneration-maturation range. This can be seen in the range of wound status according to Bates-Jansen, the smaller the mean value of wound healing, the closer to healthy tissue. So this proves that the use of hydrogels is effective in helping the wound healing process.

On research Aguiar *et al.*, (2017), it was observed that the use of hydrogels was carried out every day when changing dressings and after 7 days of treatment, there was a reduction in edema, with a small amount of fibrinous material and granulation tissue in the wound bed. In session 19, granulation continued to be observed, wound contraction decreased. Many changes occurred in session 26, there were granulation tissue that was well vascularized, the amount of fibrinous material was lower, there was less edema and the appearance of the wound was better, the wound edges were clearly visible and the size of the wound was reduced. In this wound, hydrogel plays a role in keeping the moisture level of the wound stable without causing skin maceration. At session 46, granulation tissue formation persisted, wound depth was reduced. The new epithelium covers almost the entire surface and edges of the wound. In session 58, the open wound fell further. During the intervention, there were no discomfort or complications from using the hydrogel during the 60 sessions the patient underwent. The results of these observations indicate that the use of hydrogel for wound care has improved well.

The results of the two articles above show that the most effective article to be applied to diabetic foot ulcer patients is the article belonging to Purnomo *et al.*, (2014) with the title of the effectiveness of wound healing using 0.9% NaCl and hydrogel on diabetes mellitus ulcers at the Semarang City General Hospital, because the wound healing time is very short, namely, 9 days.

According to the researcher, the two studies above show that the use or replacement of hydrogel dressings that are carried out every day can show better results, for example, reduced edema and faster granulation tissue compared to using NaCl.

Nursing implications

Based on the results of the review in the two scientific articles above, it shows that the use of hydrogel is very influential on healing diabetic foot ulcers, in terms of the time of using hydrogel 7–9 days, good changes have been seen, starting from the presence of granulation tissue, namely the color of the wound is bright red or whitish when touched, the edges of the wound are bright red or whitish to the touch a clearly identifiable wound adjacent to the wound bed.

If in the world of nursing using hydrogel as a topical in healing diabetic foot ulcers, with its very simple use, and a very fast healing time span, it will save time from patient to patient, thereby reducing the nurse's workload. However, the therapy of giving hydrogel to diabetic foot ulcers must still be carried out by nurses in accordance with standard operating procedures as they should. Before administering hydrogel therapy, the nurse must first assess the patient's wound, to determine the type of therapy that can be given, and the nurse can find out whether with this type of wound hydrogel therapy can be given so that there is no worsening of the wound.

Conclusion

Based on the results of the literature review of the two scientific articles above, it shows that the characteristics of respondents in the use of hydrogels in healing diabetic foot ulcers do not limit age, from preschool children to over 60 years of age can use hydrogel as a topical to help heal diabetic foot ulcers. Healing of diabetic foot ulcers using hydrogel is very short, within 7-9 days good changes can be seen, starting from the presence of granulation tissue, namely the color of the wound is bright red or whitish when touched, the edges of the wound are clearly visible. In addition, hydrogel has moist properties that can hydrate the wound, keep the wound moist, not irritating, and has the advantage of being able to help slough off necrotic tissue (black/yellow dead tissue).

References

- Subandi E, Sanjaya KA. Efektifitas Modern Dressing Terhadap Proses Penyembuhan Luka Diabetes Melitus Tipe 2. *J Kesehatan*. 2020;10(1):1273-84.
- Kemendes, Pusdatin. Infodatin 2020 diabetes melitus.pdf. 2020.
- Harding JL, Pavkov ME, Magliano DJ, Shaw JE, Gregg EW. Global trends in diabetes complications: A review of current evidence. *Diabetologia*. 2019;62(1):3-16. <https://doi.org/10.1007/s00125-018-4711-2>
PMid:30171279
- Harreiter J, Roden M. Diabetes mellitus-definition, classification, diagnosis, screening and prevention (Update 2019). *Wien Klin Wochenschr*. 2019;131(Suppl 1):6-15. <https://doi.org/10.1007/s00508-019-1450-4>
PMid:30980151
- Rubio JA, Jiménez S, Lázaro-Martínez JL. Mortality in patients with diabetic foot ulcers: Causes, risk factors, and their association with evolution and severity of ulcer. *J Clin Med* 2020;9(9):3009. <https://doi.org/10.3390/jcm9093009>
PMid:32961974
- Bandyk DF. The diabetic foot: Pathophysiology, evaluation, and treatment. *Semin Vasc Surg*. 2018;31(2-4):43-8. <https://doi.org/10.1053/j.semvascsurg.2019.02.001>
PMid:30876640
- Banik PC, Barua L, Moniruzzaman M, Mondal R, Zaman F, Ali L. Risk of diabetic foot ulcer and its associated factors among Bangladeshi subjects: A multicentric cross-sectional study. *BMJ Open* 2020;10(2):e034058. <https://doi.org/10.1136/bmjopen-2019-034058>
PMid:32114471
- Jupiter DC, Thorud JC, Buckley CJ, Shibuya N. The impact of foot ulceration and amputation on mortality in diabetic patients. I: From ulceration to death, a systematic review. *Int Wound J* 2016;13(5):892-903. <https://doi.org/10.1111/iwj.12404>
PMid:25601358
- Dixon D, Edmonds M. Managing diabetic foot ulcers: Pharmacotherapy for wound healing. *Drugs*. 2021;81(1):29-56. <https://doi.org/10.1007/s40265-020-01415-8>
PMid:33382445
- Saputra AS, Dewi T, Rahmawati EK, Ibrahim N, Wibisono G. Penutup Luka Hydrogel Berbasis Polivinil Alkohol (pva), Kitosan, Pati Dengan Penambahan Asap Cair dan Vitamin K. University of Diponegoro; 2019. p. 1-10.
- Sharma R, Sharma SK, Mudgal SK, Jelly P, Thakur K. Efficacy of hyperbaric oxygen therapy for diabetic foot ulcer, a systematic review and meta-analysis of controlled clinical trials. *Sci Rep*. 2021;11(1):1-12.
- Dismalyansa. Pengaruh Hiperbarik Oksigen Terhadap Kualitas Hidup Penderita Ulkus Kaki Diabetik di RSAL Dr. Ramelan Surabaya; 2019.
- Liu H, Li Z, Zhao Y, Feng Y, Zvyagin AV, Wang J, et al. Novel diabetic foot wound dressing based on multifunctional hydrogels with extensive temperature-tolerant, durable, adhesive, and intrinsic antibacterial properties. *ACS Appl Mater Interfaces* 2021;13(23):26770-81. <https://doi.org/10.1021/acsmi.1c05514>
PMid:34096258
- Sari SI, Andas AM, Wada FH. The effectiveness of hydrogel on wound healing in pressure ulcer patients. *J IMELDA Nurs Sci*. 2022;8(1):52-7. <https://doi.org/10.52943/jikeperawatan.v8i1.688>
- Zhang X, Sun D, Jiang GC. Comparative efficacy of nine different dressings in healing diabetic foot ulcer: A Bayesian network analysis. *J Diabetes*. 2019;11(6):418-26. <https://doi.org/10.1111/1753-0407.12871>
PMid:30324760
- Purnomo SE, Dwiningsih SU, Lestari KP. Efektifitas Penyembuhan luka Menggunakan NaCl 0,9% dan HYDROGEL Pada Ulkus Diabetes di RSUD Kota Semarang. *Pros Konf Nas II PPNi Jawa Tengah*; 2014. p. 144-52.
- Aguiar P, Amaral C, Rodrigues A, De Souza AH. A diabetic foot ulcer treated with hydrogel and hyperbaric oxygen therapy: A case study. *J Wound Care*. 2017;26(11):692-5. <https://doi.org/10.12968/jowc.2017.26.11.692>
PMid:29131751
- Aguiar P, Amaral C, Rodrigues A, De Souza AH. A diabetic foot ulcer treated with hydrogel and hyperbaric oxygen therapy: A case study. *J Wound Care*. 2017;26(11):692-5.