



# Prospective Comparative Analysis Study of Minimally Invasive Surgical Decompressions versus Traditional Surgical Decompression of Carpal Tunnel Syndrome

Ahmed Alkhuzai\* 

Department of Orthopaedic Surgical, Faculty of Medicine, Sulaimani University, Sulaymaniyah, Iraq

## Abstract

**Edited by:** Ksenija Bogoeva-Kostovska  
**Citation:** Alkhuzai A. Prospective Comparative Analysis Study of Minimally Invasive Surgical Decompressions versus Traditional Surgical Decompression of Carpal Tunnel Syndrome. Open Access Maced J Med Sci. 2022 Aug 18; 10(B):1882-1888. https://doi.org/10.3889/oamjms.2022.9900  
**Keywords:** Boston functional status score; Caretakers; Classical; Carpal tunnel syndrome; Decompression; Minimally invasive  
**\*Correspondence:** Ahmed Alkhuzai, Department of Orthopaedic Surgical, Faculty of Medicine, Sulaimani University, Iraq. E-mail: ahmed.kazar@univsul.edu.iq  
**Received:** 20-Apr-2022  
**Revised:** 05-Aug-2022  
**Accepted:** 08-Aug-2022  
**Copyright:** © 2022 Ahmed Alkhuzai  
**Funding:** This research did not receive any financial support  
**Competing Interests:** The authors have declared that no competing interests exist  
**Open Access:** This is an open-access article distributed under the terms of the Creative Commons Attribution-NonCommercial 4.0 International License (CC BY-NC 4.0)

**BACKGROUND:** Carpal tunnel syndrome (CTS) occurs when there is compression on the median nerve within the carpal tunnel in the wrist joint. It commonly affects those who make frequent, repetitive hand movements, with women being more affected than men.

**AIM:** The present study was aimed at comparing minimally invasive and classical surgical decompression techniques for CTS.

**MATERIALS AND METHODS:** One hundred and four patients with CTS who were scheduled for carpal tunnel decompression were chosen at random. The patients were divided into two Groups. Group A had standard classical long incision decompression, whereas Group B had minimally invasive decompression. The patients were evaluated with the Boston Functional Score Scale. Between the two Groups, a comparison of visit reports was made at 3, 6, and 12 months after surgery.

**RESULTS:** There was no significant difference in patient age (Group A was 38 years old and Group B was 36 years old) and availability of bilateral CTS status (A was 34 and B was 31). The female-male ratios in Groups A and B were 3.6 to 0.2 and 3.1 to 0.3, respectively, with p-value of  $p < 0.05$  indicating significant difference. Comparing both Groups, the minimally invasive decompression technique showed a high rate of functional hand grip and a low rate of complications including early wound healing, rapid resumption of palmar strength grip, and rapid return to daily activities.

**CONCLUSION:** The findings indicate that patients who underwent the minimally invasive surgical decompression one-stitch technique showed significant improvement over the traditional method.

## Introduction

Caretakers are the occupations with the highest frequency of carpal tunnel syndrome (CTS). These include housewives who focus on homework in great detail. Women who work as leisure workers in markets, hair and body care, food items, and carpet makers are more susceptible to CTS than men. The other most common reasons are wrist arthritis, thyroiditis, myxedema, and trauma, which are all linked to carpal bone fractures in pregnant women [1], [2]. However, tingling, numbness, and pain in the implicated hands are clinical characteristics of CTS, it affects the daily activities and its signs and symptoms have conflict with other illnesses such as pronator syndrome, thoracic outlet syndrome, and cervical radiculopathy [3].

The CTS diagnosis is necessary before initiating treatment, and surgical decompression [4]. For a CTS diagnosis, nerve conduction investigations are 60% specific and 90% sensitive. They also provide information to the surgeon that allows him to rule out other syndromes with comparable symptoms. The diagnosis is supported by distal motor latency  $>4.5$  ms and sensory

latency  $>3.5$  ms. However, electrodiagnostic studies can produce consistent results regardless of signs and symptoms of median nerve compression dysfunction [5]. In patients with CTS who do not respond to other forms of conservative treatment (splints, nonsteroidal anti-inflammatory drugs, and local steroid infiltration) physiotherapy is also an effective method of treatment. Carpal tunnel decompression by incision division of the transverse carpal ligament (TCL) with an open or endoscopic method is performed. However, this is not a completely risk-free method, with several reports of persistent symptoms, painful hypertrophic scars, and long-term strength reduction. Physiotherapy is also an effective method of treatment [6], [7], [8] [9].

In comparison to traditional decompression, the benefits of this surgical procedure include reduced post-operative pain, earlier strength recovery, hand grip, and an early return to daily life activities with fewer complications [10]. The use of a minimum surgical procedure to cut the carpal tunnel ligament with a tiny incision produces better results than the classical [11], [12]. Following surgical divisions of the carpal ligament and flexor retinaculum to decompress the median nerve, diabetics and those of the female sex

have a greater relapse risk [13], [14], [15]. The TCL is a broad ligament that runs from the scaphoid to the hamate and pisiform bones in the flexor region of the hand, covering the carpal tunnel tissues in the wrist joint [16]. The main cause of pseudoaneurysm mass formation is an iatrogenic injury with median nerve damage and superficial palmar arch damage, which is treated with endoscopic decompression. During the decompression of the carpal tunnel, the palmar cutaneous branches can be injured [17], [18]. They are options if there was clinical confirmation of median nerve denervation or if patients accepted surgical treatment, according to the American academy of orthopedic surgeons early surgery and treatment guidelines [19], [20], [21], [22].

## Materials and Methods

The aim of the present study was to conduct a comparative analysis of minimally invasive and traditional surgical decompression of CTS this study was designed and settled by the author Dr. Ahmed Alkhuzai Orthopedic Surgeon, University of Sulaimani, College of Medicine, Orthopedic Department.

### **Ethical approval and study group**

This is a cross-sectional study. Ethical approval was obtained number 11 on date of September 1, 2020 from the Department of Orthopedic Surgery, College of Medicine, Sulaimani University, Iraq. From July 2015 to August 2017, a total of 104 patients were randomly gathered from private clinic patients with CTS who were scheduled for carpal tunnel decompression at a private hospital. Patients were divided into two groups after being randomly chosen: Group A (n = 50) underwent standard classical long incision decompression and Group B (n = 54) was treated through minimally invasive decompression.

### **Characteristics of the participants and clinical assessment of the study groups**

Patients' results and complications were assessed based on the Boston Functional Status Scale (Disability and Rehabilitation, Volume 43, [Issue 11]), which was used for statistical analyses in this study. Clinical assessments were included in the patients' selection after clinical examination and diagnostic criteria were examined for each of them. Some of the clinical features include the Phalen test, Tinel sign, Duran compression test, (July 2006 The Journal of Hand Surgery 31(6):919-24). Furthermore, a nerve conduction investigation was performed in the EMG/NCS Neuroelectrophysiological Clinic, which demonstrated the stages of nerve compression, the

majority of which were higher than moderate to severity. The EMG and NCS provide evidence of the diagnostic and medicolegal utility.

### **Description, interventions, and comparisons of the processes**

#### *Inclusion and exclusion criteria for the study groups*

The study's inclusion criteria include caretakers, who were housewives whose daily activities were influenced by having one or more family members with a congenital or acquired handicap, and leisure workers, who are women who work in markets, hair, and body care, food goods, and carpet makers. The exclusion criteria are patients with cervical radiculopathy root compression, thoracic outlet syndrome, and pronator syndrome. Furthermore, patients with ulnar compartment syndrome and thenar muscle atrophy with shelf signs were excluded from the study. Patients who have improved following conservative treatment, or who have improved utilizing a wrist splint, local steroid medication, or who have improved well following physiotherapy, as well as elderly patients with systemic disorders, were all excluded from the study.

### **Mini-palmar incision**

All of the operations were performed under general anesthesia with an upper-arm pneumatic or rubber tourniquet, both of which were provided by Esmarch. The site of surgical decompression was 4–6-mm ulnar toward the depressed point space between the thenar and hypothenar regions of the hand. The dotted line must pass distally to the third web space axis between the middle and ring fingers, outside of the thumb axis, on the anterior aspect of the wrist. From the surgical theater, where the operations were performed, the intraoperative photos used are provided in the supplementary materials.

The aponeurosis layers were dissected layer by layer until the TCL was reached (white transverse fibers horizontally in the middle of the central part of the wrist). Hand retractors were employed from side to side; proximal-distal retraction along with the retractors' elevation allowed for enhanced surgical field visibility. The midway length from the superficial palmar arch to the distal TCL in this study, however, ranged from 20 to 24.6 mm  $\pm$  0.4 mm. The thumb was completely outspread, and 2–2.5 cm of longitudinal curvilinear incisions were made on the volar aspect of the wrist crease between the palmaris longus tendon and the flexor carpi radial tendon toward the palmaris longus tendon, distal to the intersection of the third web axis. The TCL was severed without other structures, the palmar skin and overlying subcutaneous tissues were left intact, and the aponeurosis was opened at a

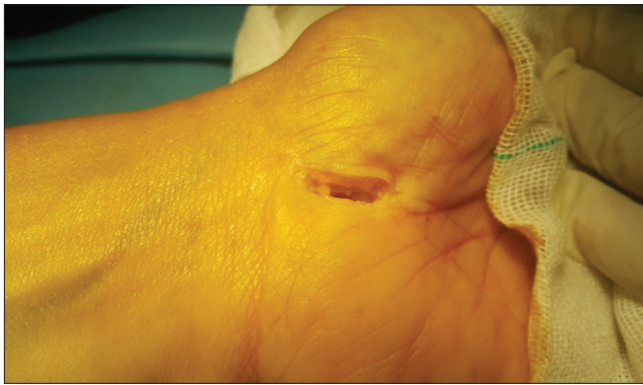

Figure 1: Skin Incision post minimal decompression (Our patients)

one-stitch distance during the surgical decompression operation.

To avoid artery arch injury, a small scalpel was passed under this ligament above the median nerve, and then the ligament was decompressed and divided with a No.15 blade scalpel, cutting upward and downward proximally and distally but not beyond the distal boundary (Kaplan's line). Incisions were sutured with a one-stitch technique and wrapped with a crepe bandage for 5–7 days, as shown in Figures 1 and 2 (from the surgical theater intraoperative photos used in the supplementary material).

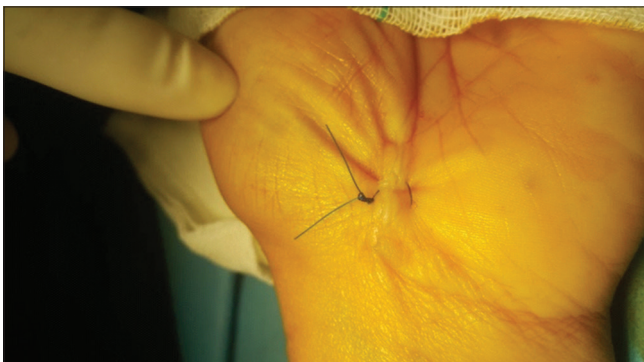


Figure 2: One Stitch for CTS Nerve decompression

Direct pressure was applied to the wrist wound for 5–7 min after decompression, over the bandage after the tourniquet was removed, to reduce bleeding from the single stitch minimal incision. Post-operative follow-up revealed that patients only had a small healing scar, indicating that this procedure will decrease the rate of relapses. These were compared to the classical (long incision) approach, which required 4–5 stitches. Figures 3 and 4 depict patients who had conventional decompression and were bandaged for 14–20 days. Patients with shelf sign thenar muscle atrophy were excluded from the study. Patients were re-evaluated after the 2<sup>nd</sup> week, and then every 3, 6, and 12 months after that. Both groups began physiotherapeutic activities right away, for 3 weeks, physiotherapeutic types were directed to work on palmar grip strength and wrist, in the form of putty grip and squeeze, thumb pinch strengthening, isometric hook, and rubber band finger and thumb exercises.

The limitations of this study are patients selection criteria for decompression post inclusion-exclusion

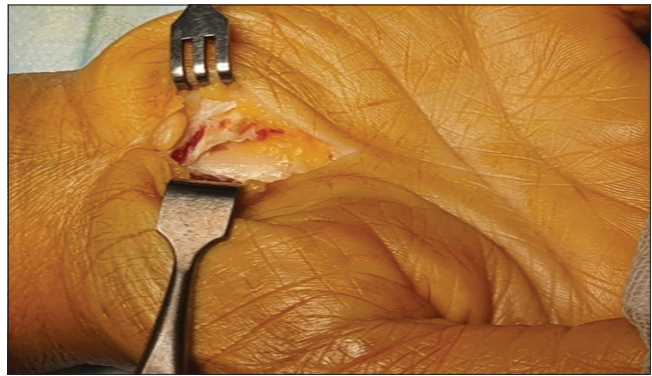


Figure 3: Surgical incision for long decompression (Our patients)

criteria, primarily does not know the long incision lead to relapses of patients complaining from same CTS features, plus establishment direct pressure over decompressions wrist wound site signs to decrease bleeding post tourniquet removal. Using Boston functional status score (BFSS), data were the same for patients complaining as international based paper publishing were identical to hand grip evaluation. Scopic techniques for decompression were expensive cost factor, lead to limitation using scope in CTS decompression, advocated using minimal incision one-stitch techniques treatment strategy.

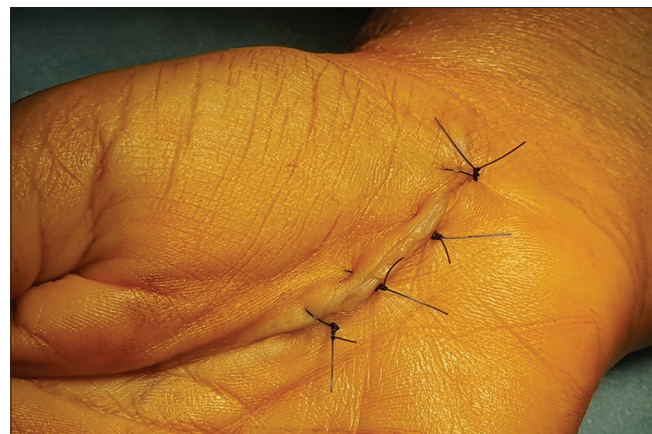

Figure 4: Suturing long decompression (Our patients)

### Statistical analysis

Statistical analysis of numerical data was carried out independently to compare the differences between two mean values, which were presented as means + standard deviation. The Statistical Package for the Social Sciences (SPSS version 25.0; Armonk, NY: IBM Corp, USA) was used for the statistical analyses. The independent t-test was used to analyze the differences between the two means. At  $p < 0.05$ , p-value was considered significant.

### Results and Discussion

A total of 104 patients who were eligible for carpal tunnel decompression were divided into two groups

based on clinical data and neuroelectrophysiological studies. Group A (n = 50) got standard long incision decompression and Group B (n = 54) underwent less-invasive decompression. For recorded visits at 3, 6, and 12 months after surgery, the groups' outcomes were compared. There was no significant difference in the age of the patients in the groups. It was observed that Group A had a mean age of 38 years, ranging from 36 to 40, and Group B had a mean age of 36 years, ranging from 34 to 38. Other differences included the availability of bilateral CTS status (A: 34 vs. B: 31) and the duration of patients' complaints (A: 1.5–2 years vs. B: 1.5–2.5 years). In both groups, the study population was predominantly female; female-male ratios were 3.6 to 0.2 in Group A and 3.1 to 0.3 in Group B; the standard deviation after 12 months was 0.18 in Group A and 0.12 in Group B, and the rate of P value was significant at  $p < 0.05$  (Table 1).

**Table 1: Patients' characteristics of the study group**

Patients/score	Group A	Group B
Number of patients	50	54
Mean of age (years) (maximal–minimal)	38 (40–36)	36 (38–34)
Female to male ratio	3.6:0.2	3.1:0.3
Body weight mean (kg) (maximal–minimal)	84 (86–82)	83 (85–81)
Body height mean (cm) (maximal–minimal)	164 (166–162)	162 (164–160)
Duration of CTS (years)	1.5–2	1.5–2.5
SD/both Groups A/B (104 patients/post 12 months)	0.18	0.12
Bilateral	34	31
Right side only	10	13
Left side only	6	10

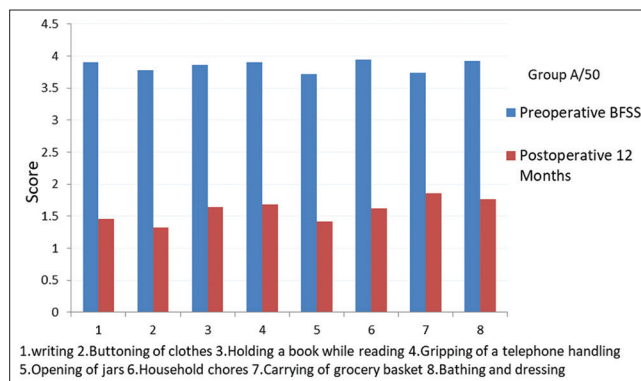
SD: Standard deviation, CTS: Carpal tunnel syndrome.

All the 104 patients experienced sign and symptom relief after surgical decompression. Paresthesia and nocturnal pain were significantly reduced, as evidenced by clinical evaluations detected 12 months after surgery, using BFSS scoring data for functional evaluations of the handgrip test. This includes dressing, bathing, carrying a grocery basket, household chores, the opening of jars, holding a book, to button clothes, writing, holding the telephone, and so on. Patients of both groups were identified, from a pre-operative score mean of 3.84 in Group A patients to 1.59. There was a significant reduction, as well as functional improvements, from 12 months after decompression, the BFSS scores represent little difficulty scoring (zero: no difficulty; (1) minimal difficulty; (2) moderate difficulty; and 5: cannot perform any daily activity). However, patients in Group B, on the other hand, had a pre-operative mean score of 3.93, which improved to 0.95 in 12 months after decompression, indicating no any difficulties.

**Table 2: Boston functional status score pre-operative/post-operative mean Boston functional status score for Groups A: 50 and Group B: 54**

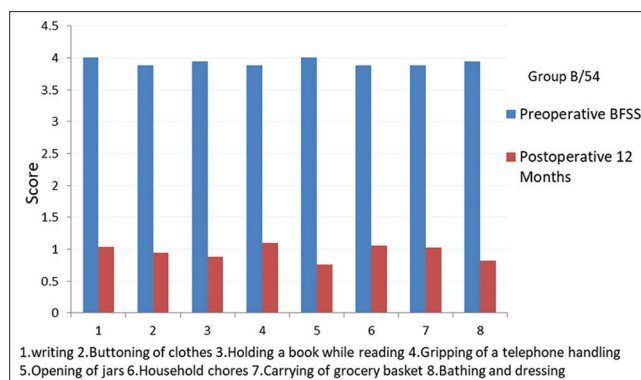
Score	Mean BFSS/ Group A ± SD	p	Mean BFSS/ Group B ± SD	p
Mean scoring of BFSS/pre-operative	3.84 ± 0.09	0.05	3.93 ± 0.05	0.05
Mean scoring of BFSS/1–3 months	2.19 ± 0.34		1.87 ± 0.07	
Mean scoring of BFSS/6 months	1.77 ± 0.35		1.28 ± 0.1	
Mean scoring of BFSS/12 months (BFSS; 1. Writing, 2. Buttoning of clothes, 3. Holding a book while reading, 4. Gripping of a telephone handle, 5. Opening of Jars, 6. Household chores, 7. Carrying of grocery basket, 8. Bathing and dressing)	1.59 ± 0.18		0.95 ± 0.12	

SD: Standard deviation, BFSS: Boston functional status score.



**Figure 5: BFSS/Pre-operative – Post-operative 12 Months-Group A/50, BFSS: Boston functional status score**

These factors account for the gradual improvements in BFSS mean scores from pre-operative to post-operative periods after 12 months for both Groups with no or little issues. However, Group B patients were <1 score of no difficulty superior to Group A patients of little difficulty, utilizing mini-invasive techniques one-stitch visible in Figures 1 and 2, as indicated in Table 2 and Figures 5 and 6. In comparison to Group A shown in Figures 3 and 4, which employed long incision procedures, these demonstrated substantial statistical differences, functional outcomes, clinical benefits, and a lower incidence of complications ratio for Group B, which used the minimal incisional one-stitch technique in compare to Group A used long incision. Post-operative discomfort, paresthesia, infections, return to work delay, and fibrosis-adhesion problems were all low in both groups. Both groups experienced post-operative pain, which reduced over time.



**Figure 6: BFSS/Pre-operative – Post-operative 12 months-Group B/54, BFSS: Boston functional status score**

Paresthesia was observed in Groups A (8%) and B (3.7%). Both Groups had infections that were completely healed after antibiotic treatment. The time to return to work in Group A was 4 weeks, while the time to return to work in Group B was 2 weeks. Fibrosis-adhesion post decompression was 12% in Group A and 3.7% in Group B. Both Groups have low complications, although Group B, which utilized the mini one-stitch approach, has fewer complications than Group A, which used the classical long incision decompression.

Both Groups' success was improving as measured by muscle power, satisfaction, and functional

**Table 3: Post-operative results percentage and mean both Groups A and B**

Functional outcome	Patients (Group A = 50)	Percentage (100%)	Patients (Group B = 54)	Percentage (100%)
Pain	8	16	6	11.11
Parasthesia	4	8	2	3.7
Infections	4	8	3	5.5
Return to work (time factor)	4 weeks	8	2 weeks	3.7
Post-operative (fibrosis-adhesion)	6	12	2	3.7
Muscle power (good-excellent grade)	40	80	46	85.18
Patient satisfaction	42	84	50	92.59
Functional score	40	80	48	88.88

scores. Patients in Group A had an average muscle power of 80%, a satisfaction rating of 84%, and a functional score of 80%. However, Group B patients' muscle power reached 85.18%, patient satisfaction rate was 92.59%, and functional score of 88.88%, indicating that Group B outperformed Group A in terms of muscle power, patient satisfaction, and functional scores, as shown in Table 3.

Mini-incision one-stitch in the depressed region between the thenar and hypothenar muscle decompression was observed. Only TCL incision with preservation of other structures (palmar skin, subcutaneous tissue, palmar aponeurosis, and short palmar muscles palmaris brevis), toward the web space between the middle and ring fingers was present. This is an avascular region that enabled decompression of the median nerve with less bleeding, plus a decreased rate of complications, and fibrosis with adhesion.

Several studies compared and evaluated various treatments for CTS after conservative measures failed, including long-incision surgery, mini-palmar decompression [23], and endoscopy through a proximal portal [24]. In this study, the classical and minimum surgical decompressions were directly compared. Several studies have found that endoscopic techniques that selectively divide only the TCL while leaving other anatomical structures intact (palmar skin, subcutaneous tissue, palmar aponeurosis, and short palmar muscles) result in fewer complications. They also found that endoscopic principles combined with minimal incision procedures left these structures intact [25]. TCL decompression using both long and mini-incision methods resulted in a high rate of significant improvement. In comparison to long incision decompression, mini decompression has several advantages. These include less post-operative pain, faster strength, power recovery, and a faster return to daily activities with fewer complications such as less bleeding, fibrosis, and adhesion. Furthermore, the earlier functional rehabilitation physiotherapy postoperatively leads to decreased stiffness and improved wrist and hand mobility [26].

The one-stitch minimal incision procedure described in this study simply slices the anterior TCL, leaving all other tissues intact. Healing of these structures results in the formation of a scar, which can interfere with palmar grip in long incisions due to fibrosis, which is higher in long incision compared to the low rate of micro decompression. Meanwhile, the

appropriate technique is vital in evaluations due to the significant differences in outcomes [27].

According to Sacks and colleagues, the median distance from the superficial palmar arch to the distal TCL was 18.80 mm ± 0.60 mm, whereas the median nerve to the thenar branch was 6.90 mm ± 0.40 mm, according to Sacks and colleagues. TCL length was averaged to be 28.50 mm ± 0.80 mm [28]. However, the average length from the superficial palmar arch to the distal TCL in the present study ranged from 20.0 to 24.60 mm ± 0.40 mm. Some authors have described a safe region between the thenar and hypothenar regions about 5.0 mm ulnar and 6.0 mm radial to the junction between the longitudinal axis of the third finger and the distal skin crease at wrist level [29]. In this study, this corresponds to the depressed region between the thenar and hypothenar areas.

The results indicated that using a one-stitch approach with a small incision is related to improved functional and esthetic outcomes. In comparison to the long traditional incision Group A, which had between 1 and 2 difficulties, the mean of functional handgrip in Group B patients explains no difficulty of <1. Both endoscopic and open decompression might have difficulties, complications, and consequences. However, using the same principles as mini-incision and endoscopic decompression, TCL was decompressed, while leaving the rest of the body tissues intact, resulting in minimal complications in both techniques. Endoscopic decompression was used to treat a rare iatrogenic lesion to the median nerve, as well as damage to the superficial palmar arch, which resulted in the creation of a pseudoaneurysm mass. The study found that the mini principle has a low complication rate when compared to other principles [25], [26], [27], [28], [29], [30].

Mauro T, plus teams described perspective randomized study, and minimal-access carpal tunnel release minimal-access carpal tunnel decompression were identified significant data improvement compared to traditional open carpal tunnel release traditional open carpal tunnel incision for the treatment of CTS until 12 months follow-up [31]. Double tunnels technique, when under tissue-sparing approach, permit surgeons to restrict the incision (0.6 cm ± 0.05 cm), while care to the palmar fascia and the subcutaneous tissue were confirmed a safe and efficient approach for the treatment of CTS. This technique entails faster recovery times, better esthetic outcomes, and lower risks of complications for 12 months treatment evaluation [32]. Our results were confirm minimal decompression for CTS improve the results data, earlier return to the works and daily activities, and less chance of adverse effect than long classical incision.

Limited incision release observed by Li Gaocen allows return earlier to activities, decreases time of surgery, and improves power plus strength post-operative earlier [33]. Furthermore, same confirmation by Castillo and Yao of functional estimation for grip and pinch strength improvement in patients treated with limited carpal tunnel incision, detected greater

grip, and pinch power than standard long release [34]. The limited mid palmar incision to decompress median nerve in CTS, lead to decrease operative time, minimal analgesia, low complications rate, early return back home, and daily activities plus earlier return to job [35]. Bai *et al.* demonstrated that patients with mini-incision have high surgical outcomes, less complications postsurgical intervention in compare to conventional approach [36]. Mini open KnifeLight instrument assisted carpal tunnel release (CTR) is easy to perform and is superior to standard open CTR in the early post-operative period [37]. Significant postoperative improvements in pain relief, patient satisfaction, hand function, daily activities, and work performance significant improvement in patients' hand grip and pinch strength. Excellent functional outcomes and satisfaction were achieved using the KnifeLight for carpal tunnel decompression. Our minimally invasive method offers a quick, easy, and effective alternative to conventional or endoscopic carpal tunnel decompression.

## Conclusion

The study described the use of an incision over a dotted line between the middle and ring fingers at the depressed point between the thenar and hypothenar regions for CTS decompression. The findings reveal that patients who underwent the minimally invasive surgical decompression one-stitch technique showed significant improvement based on the results obtained. This improvement includes early recovery of palmar strength grip, a rapid return to daily life activities, as well as a superior outcome for minimal decompression technique, and a high rate of the functional hand grip. This approach carries a low rate of complications compared to classical long-incision surgical decompression of CTS.

## Acknowledgment

The author would like to thank the entire workers in the Department of Orthopedic Surgery, Faculty of Medicine, Sulaimani University, Iraq, for their support in achieving this study.

## References

- Atroshi I, Gummesson C, Johnsson R, Ornstein E, Ranstam J, Rosen I. Prevalence of carpal tunnel syndrome in a general population. *JAMA*. 1999;282(2):153-8. <https://doi.org/10.1001/jama.282.2.153>
- Jenkins PJ, Srikantharajah D, Duckworth AD, Watts AC, McEachan JE. Carpal tunnel syndrome: The association with occupation at a population level. *J Hand Surg Eur*. 2013;38(1):67-72. <https://doi.org/10.1177/1753193412455790> PMID:22832982
- "Surgery for Carpal Tunnel Syndrome". Available from: <https://www.uptodate.com>. [Last accessed on 2020 Sep 21].
- American Academy of Orthopaedic Surgeons. Management of Carpal Tunnel Syndrome Evidence-Based Clinical Practice Guideline. Rosemont, IL: American Academy of Orthopaedic Surgeons; 2016. <https://doi.org/10.1016/j.mporth.2010.02.001>
- Calandruccio JH. Carpal tunnel syndrome, ulnar tunnel syndrome, and stenosing tenosynovitis. In: Campbell's Operative Orthopaedics. 13<sup>th</sup> ed. Philadelphia, PA: Elsevier. 2017. <https://doi.org/10.1016/b978-0-323-07243-4.00076-1>
- Kuschner SH, Brien WW, Johnson D, Gellman H. Complications associated with carpal tunnel release. *Orthop Rev*. 1991;20(4):346-52. PMID:2041657
- Hui AC, Wong SM, Tang A, Mok V, Hung LK, Wong KS. Long-term outcome of carpal tunnel syndrome after conservative treatment. *Int J Clin Pract*. 2004;58(4):337-9. <https://doi.org/10.1111/j.1368-5031.2004.00028.x> PMID:15161116
- Keith MW, Masear V, Amadio PC, Andary M, Barth RW, Graham B, *et al.* Treatment of carpal tunnel syndrome. *J Am Acad Orthop Surg*. 2009;17(6):397-405. <https://doi.org/10.5435/00124635-200906000-00008> PMID:19474449
- White NT, Delitto A, Manal TJ, Miller S. The American Physical Therapy Association's top five choosing wisely recommendations. *Phys Ther*. 2015;95(1):9-24. <https://doi.org/10.2522/ptj.20140287> PMID:25223237
- Mintalucci DJ, Leinberry CF. Open versus endoscopic carpal tunnel release. *Orthop Clin North Am*. 2012;43(4):431-7. <https://doi.org/10.1016/j.ocl.2012.07.012> PMID:23026458
- Nigst H. The carpal tunnel syndrome. Operative technique for surgical decompression. *Orthop Traumatol*. 1992;1(2):122-9. <https://doi.org/10.1007/bf02620406>
- Abdulhamid SI. Carpal tunnel release through mini transverse approach CTRMTA Sayedlssa's approach. *Orthop Rheumatol*. 2018;10(10):175-8. <https://doi.org/10.15406/mojor.2018.10.00409>
- Jenkins PJ, Duckworth AD, Watts AC, McEachan JE. Corticosteroid injection for carpal tunnel syndrome: A 5-year survivorship analysis. *Hand*. 2012;7(2):151-6. <https://doi.org/10.1007/s11552-012-9390-8> PMID:23730233
- Ucar BY, Demirtaş A, Bulut M, Azboy I, Ucar D. Carpal tunnel decompression: Two different mini-incision techniques. *Eur Rev Med Pharmacol Sci*. 2012;16(4):533-8. PMID:22696883
- Acioly MA, Maior PS, Telles C, de Aguiar GB. Bilateral mini-open decompression in the treatment of carpal tunnel syndrome caused by persistent median artery: Case report. *J Neurol Surg Part A Cent Eur Neurosurg*. 2013;74 Suppl 1:e124-7. <https://doi.org/10.1055/s-0032-1328959>
- Bromley GS. Minimal-incision open carpal tunnel decompression. *J Hand Surg*. 1994;19(1):119-20. [https://doi.org/10.1016/0363-5023\(94\)90234-8](https://doi.org/10.1016/0363-5023(94)90234-8) PMID:8169355
- Murphy RX Jr., Jennings JF, Wukich DK. Major neurovascular complications of endoscopic carpal tunnel release. *J Hand Surg*. 1994;19(1):114-8. [https://doi.org/10.1016/0363-5023\(94\)90234-8](https://doi.org/10.1016/0363-5023(94)90234-8)

- org/10.1016/0363-5023(94)90233-x  
PMid:8169354
18. Watchmaker GP, Weber D, Mackinnon SE. Avoidance of transection of the palmar cutaneous branch of the median nerve in carpal tunnel release. *J Hand Surg.* 1996;21(4):644-50. [https://doi.org/10.1016/s0363-5023\(96\)80019-0](https://doi.org/10.1016/s0363-5023(96)80019-0)  
PMid:8842959
  19. Keith MW, Masear V, Chung KC, Amadio PC, Andary M, Barth RW, *et al.* American Academy of Orthopaedic Surgeons clinical practice guideline on the treatment of carpal tunnel syndrome. *J Bone Joint Surg Am.* 2010;92(1):218-9. <https://doi.org/10.2106/jbjs.i.00642>  
PMid:20048116
  20. Boyer MI. AAOS Comprehensive Orthopedic Review. Rosemont, IL: American Academy of Orthopedic Surgeons; 2014. p. 1327-35.
  21. Cranford CS, Ho JY, Kalainov DM, Hartigan BJ. Carpal tunnel syndrome. *J Am Acad Orthop Surg.* 2007;15(9):537-48. <https://doi.org/10.5435/00124635-200709000-00004>  
PMid:17761610
  22. Ariyan ST, Watson HK. The palmar approach for the visualization and release of the carpal tunnel. An analysis of 429 cases. *Plast Reconstr Surg.* 1977;60(4):539-47. <https://doi.org/10.1097/00006534-197710000-00007>  
PMid:909963
  23. Vasilidis HS, Sakellariou ME, Shrier I, Salanti G, Scholten RJ. Open release for carpal tunnel syndrome. *Cochrane Database Syst Rev.* 2019;2019. <https://doi.org/10.1002/14651858.cd011041.pub2>
  24. Agee JM, McCarroll HR Jr., Tortosa RD, Berry DA, Szabo RM, Peimer CA. Endoscopic release of the carpal tunnel: A randomized prospective multicenter study. *J Hand Surg Am.* 1992;17(6):987-95. doi: 10.1016/s0363-5023(09)91044-9. [https://doi.org/10.1016/s0363-5023\(09\)91044-9](https://doi.org/10.1016/s0363-5023(09)91044-9)  
PMid:1430964
  25. Agee JM, Peimer CA, Pyrek JD, Walsh WE. Endoscopic carpal tunnel release: A prospective study of complications and surgical experience. *J Hand Surg.* 1995;20(2):165-71. [https://doi.org/10.1016/s0363-5023\(05\)80001-2](https://doi.org/10.1016/s0363-5023(05)80001-2)  
PMid:7775746
  26. Chow JC. The Chow technique of endoscopic release of the carpal ligament for carpal tunnel syndrome: Four years of clinical results. *Arthroscopy.* 1993;9(3):301-14. [https://doi.org/10.1016/s0749-8063\(05\)80426-8](https://doi.org/10.1016/s0749-8063(05)80426-8)  
PMid:8323616
  27. Scholten RJ, Mink van der Molen A, Uitdehaag BM, Bouter LM, de Vet HC. Surgical treatment options for carpal tunnel syndrome. *Cochrane Database Syst Rev.* 2007;2007(4):CD003905. <https://doi.org/10.1002/14651858.cd003905.pub3>  
PMid:17943805
  28. Sacks JM, Kuo YR, Mclean K, Wollstein R, Lee WP. Anatomical relationships among the median nerve thenar branch, superficial palmar arch, and transverse carpal ligament. *Plast Reconstr Surg.* 2007;120(3):713-8. <https://doi.org/10.1097/01.prs.0000270305.37677.e7>  
PMid:17700123
  29. Xu X, Lao J, Zhao X. How to prevent injury to the palmar cutaneous branch of median nerve and ulnar nerve in a palmar incision in carpal tunnel release, a cadaveric study. *Acta Neurochir.* 2013;155(9):1751-5. <https://doi.org/10.1007/s00701-013-1764-3>  
PMid:23828713
  30. Urbaniak JR. Complication of treatment of carpal tunnel syndrome. In: Gelberman RH, editor. *Operative Nerve Repair and Reconstruction.* Philadelphia: JB Lippincott; 1991. p. 967-79.
  31. Tarallo M, Fino P, Sorvillo V, Parisi P, Scuderi N. Comparative analysis between minimal access versus traditional accesses in carpal tunnel syndrome: A perspective randomised study. *J Plast Reconstr Aesth Surg.* 2014;67(2):237-43. <https://doi.org/10.1016/j.bjps.2013.10.033>  
PMid:24290977
  32. Vanni D, Sirabella FS, Galzio R, Salini V, Magliani V. The double tunnels technique: An alternative minimally invasive approach for carpal tunnel syndrome. *J Neurosurg.* 2015;123(5):1230-7. <https://doi.org/10.3171/2014.11.jns14901>  
PMid:26024005
  33. Li G, Kong L, Kou N, Wang Y, Yu K, Bai J, *et al.* The comparison of limited-incision versus standard-incision in treatment of carpal tunnel syndrome: A meta-analysis of randomized controlled trials. *Medicine.* 2019;98(18):e15372. <https://doi.org/10.1097/md.00000000000015372>  
PMid:31045782
  34. Castillo TN, Yao J. Prospective randomized comparison of single-incision and two-incision carpal tunnel release outcomes. *Hand (N Y).* 2014;9:36-42. <https://doi.org/10.1007/s11552-013-9572-z>  
PMid:24570635
  35. Doski JO, Sindy RS, Hamzani FT, Omar HO. Limited mid palmar versus extended incision in surgical treatment of carpal tunnel syndrome: Clinical analysis. *Zanco J Med Sci (Zanco J Med Sci).* 2020;24(3):360-6. <https://doi.org/10.15218/zjms.2020.043>
  36. Bai J, Kong L, Zhao H, Yu K, Zhang B, Zhang J, *et al.* Carpal tunnel release with a new mini-incision approach versus a conventional approach, a retrospective cohort study. *Int J Surg.* 2018;52:105-9. <https://doi.org/10.1016/j.ijsu.2018.02.033>  
PMid:29471152
  37. Yüçetaş SC, Yildirim A. Comparative results of standard open and mini open, KnifeLight instrument-assisted carpal tunnel release. *J Neurol Surg Part A Cent Eur Neurosurg.* 2013;74(06):393-9. <https://doi.org/10.1055/s-0033-1342932>  
PMid:23929411