



# Clinical Behavior of General Practitioners for Patients who Underwent an Operative or Conservative Treatment for a Craniocervical Fracture

Mihail Kalnev<sup>1,2\*</sup> , Petar Uchikov<sup>3,4</sup> , Ivo Kehayov<sup>1,2</sup> 

<sup>1</sup>Department of Neurosurgery, Faculty of Medicine, Medical University Plovdiv, Plovdiv, Bulgaria; <sup>2</sup>Clinic of Neurosurgery, University Hospital "St. George", Plovdiv, Bulgaria; <sup>3</sup>Department of Special Surgery, Faculty of Medicine, Medical University Plovdiv, Plovdiv, Bulgaria; <sup>4</sup>Clinic of Special Surgery, University Hospital "St. George", Plovdiv, Bulgaria

## Abstract

**BACKGROUND:** Craniocervical fractures are socially important pathology. They represent one-third of the fractures in cervical region. It is typical that elderly patients suffer from low-energy traumas such as falls, while younger patients suffer from high-energy traumas as motor vehicle accidents, sport falls, etc. Craniocervical fractures are associated with an increased risk of craniocervical instability or neurological deficit. Primary therapeutic options depend on the type of the fracture. Predictors of non-unions are the displacement of fractures, patients' age, and comorbidities. The observer ship of the general practitioner in the post-operative period or the period of cervical immobilization could recognize possible malpositioning of the instrumentation, non-union of the fracture, malsanation of the wound, and possible complications in case of the external immobilization. There is a lack of information on that topic.

**AIM:** The goal of the paper is to summarize the most common fractures of the craniocervical region, their etiology, treatment options, and to present the results of our study of patients who underwent operative treatment for craniocervical fracture(s).

**METHODS:** An ambispective study of 72 patients who underwent operative treatment due to a fracture in the craniocervical region between March 2012 and December 2020 was performed. The short- and long-term results have been evaluated. The aetiology, age composition, and clinical results were collected and analyzed.

**RESULTS:** The operative techniques that have been performed are occipitocervical fusion in 58 patients, odontoid screw fixation in eight patients, and anterior cervical decompression and fusion (ACDF) in six patients. The results showed a correlation between the operative technique used and the VAS clinical outcome – the fastest improvement was achieved in the group of the odontoid screw fixation and the ACDF (ACDF in cases of a Hangman's fractures).

**CONCLUSION:** Mastering the details, the treatment options and the possible complication of the fractures in craniocervical region and general practitioners could play an important role in the treatment of patients.

**Edited by:** Ksenija Bogoeva-Kostovska

**Citation:** Kalnev M, Uchikov P, Kehayov I. Clinical Behavior of General Practitioners for Patients who Underwent an Operative or Conservative Treatment for a Craniocervical Fracture. Open Access Maced J Med Sci. 2022 Jun 01; 10(B):1667-1672.  
<https://doi.org/10.3889/oamjms.2022.9923>

**Keywords:** Fractures in craniocervical region; General practitioner; General medicine

**\*Correspondence:** Dr. Mihail Kalnev, Department of Neurosurgery, Faculty of Medicine, Medical University Plovdiv, Plovdiv, Bulgaria. E-mail: [dr.kalnev@gmail.com](mailto:dr.kalnev@gmail.com)

**Received:** 22-Apr-2022

**Revised:** 03-May-2022

**Accepted:** 22-Jun-2022

**Copyright:** © 2022 Mihail Kalnev, Petar Uchikov, Ivo Kehayov

**Funding:** This research did not receive any financial support

**Competing Interests:** The authors have declared that no competing interests exist

**Open Access:** This is an open-access article distributed under the terms of the Creative Commons Attribution-NonCommercial 4.0 International License (CC BY-NC 4.0)

## Introduction

The craniocervical junction is a unique osteoligamentous complex. The atlantoaxial junction is part of this complex and is the most mobile structure in the spine. The craniocervical junction consists of the occipital condyles, the atlas (C1), the axis (C2), and the ligaments. This apparatus provides stability and mobility [1]. The fractures in the craniocervical region could present with local pain in the region, impairment of the lower cranial nerves, mono- para-quadriplegia, or plegia. Lethal outcome could occur at the moment of the trauma [2], [3]. General practitioner's knowledge of the details of the fractures in the occipitoatlantoaxial complex may lead to the early diagnosis and treatment of the patients. We led a study of 72 patients who underwent an operation due to a fracture(s) in the craniocervical region. The results confirmed the data from the literature for the

age distribution and the long-term results measured with VAS, modified McCormick Scale, and ASIA Impairment Scale. In contrast with the other studies in our series, more patients with neurological impairment were presented. The general practitioner has a vital role in the post-operative period as he could suspect possible complications.

## Materials and Methods

An ambispective study of 72 patients who underwent operative treatment due to a fracture in the craniocervical region between March 2012 and December 2020 was performed. The short- and long-term results have been evaluated. The etiology, age composition, and clinical results were collected and analyzed.

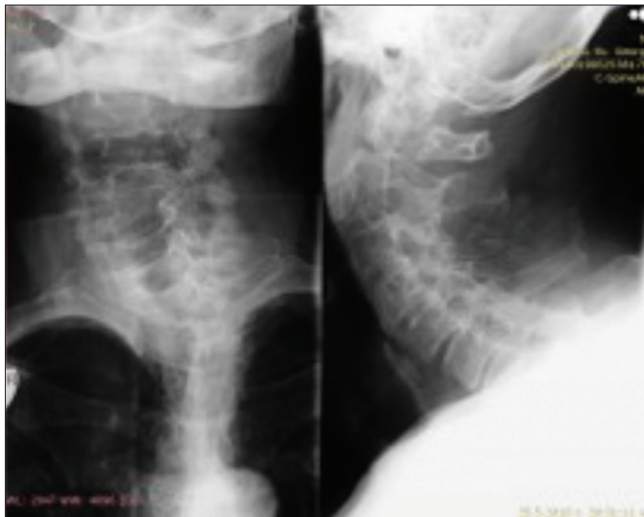

Figure 1: X-Ray - AP and lateral: Fracture of Dens (C2)

**Results**

The analysis showed that 41 patients are above 50-year old, and 25 are older than 70 years. The mean age in the cohort was 55, 46 years. In the group, the correlation between men and women is 2.6:1. The motor vehicle accidents were the most common mechanism of trauma (30.60%), followed by falls from self-high (23.61%) and falls on stairs.

Twenty-nine patients (43%) have reported neurological impairment in the studied group. The most common fracture is the dens fracture Type II, according to Anderson and D'Alonzo classification. C2 fractures were most commonly associated with C1 fractures – (83% of all cases with associated C-spine injuries).

The operative techniques that have been performed are occipitocervical fusion in 58 patients, odontoid screw fixation in eight patients, and anterior cervical decompression and fusion (ACDF) in six patients. The results showed a correlation between the operative technique used and the VAS clinical outcome

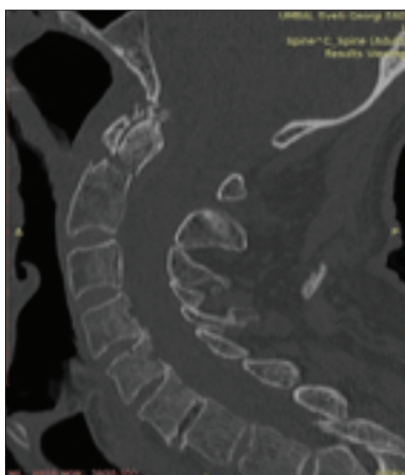


Figure 2: Cervical CT - sagittal re-construction. Fracture of Dens (C2)

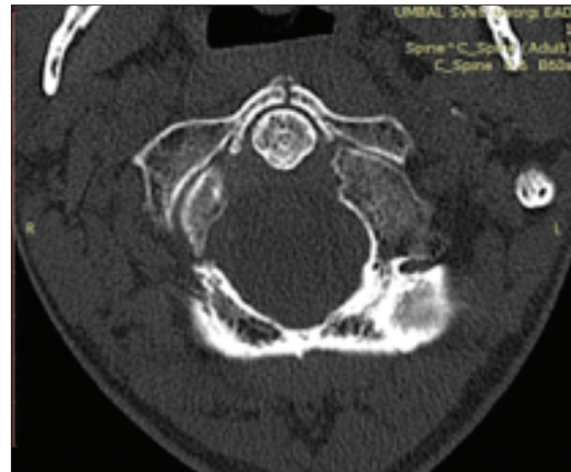

Figure 3: Cervical CT - axial reconstruction: fracture of C1

– the fastest improvement was achieved in the group of the odontoid screw fixation and the ACDF (ACDF in cases of a Hangman's fractures).

**Discussion**

The general practitioners could distinguish the trauma's mechanism and the symptoms associated with a fracture in occipitoatlantoaxial complex, atlanto-occipital dislocation, or atlantoaxial subluxation/dislocation. In our clinical practice, some patients do not reach us on an emergency basis but have been hospitalized days after the injuries. In most cases, the increasing pain in the cervical region and the pain when there are movements in the cervical region were forcing patients to seek medical assistance. Anamnesis for trauma and symptoms of neck pain, torticollis, and reduced range of motion should provoke further studies even if patients are neurologically intact. Injuries in the craniocervical region could be presented with neurological impairment – Bulbar-cervical dissociation, lower cranial nerve deficit, paresthesias, monoparesis, or central cord syndrome.

Cervical X-rays are still performed, but in some, non-displaced fractures could not be sufficient.

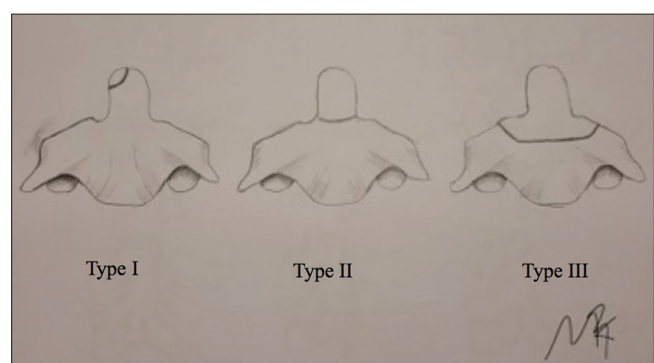


Figure 4: Anderson and D'Alonzo classification of odontoid fractures

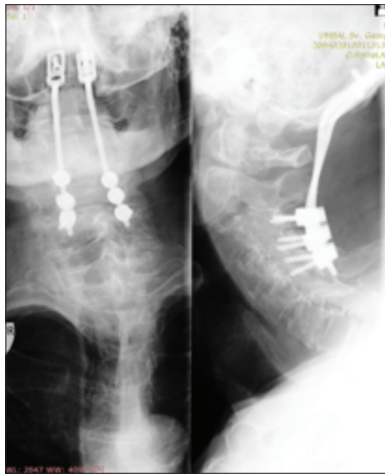

Figure 5: Occipitocervical fixation due to combined C1 and C2 fractures

A computed tomography (CT) is superior for radiographic evaluation of a craniocervical fracture Figures 1-3. The figures belong to a patient from the studied group. The X-ray had shown the fracture of the odontoid but failed to visualize the fracture of the atlas that is presented on the CT scan.

According to Squarza *et al.*, the CT is the most cost-effective method in the case of Hangman's fractures [4]. If a CT scan had been performed and dislocation of the lateral mass was diagnosed, but the study had failed to prove a rupture of the TAL, magnetic resonance imaging should be performed [5].

The occipital condyle fractures are uncommon – about 0.4%–0.7% of all traumatic injuries. According to the classification of Anderson and Montesano the Occipital Condyle fractures are three different types: Type I fracture is a comminuted fracture due to axial loading injuries and is meant to be a stable fracture. Type II occipital condyle fracture is a linear fracture of the cranium base that is extended to the occipital condyle. It is also counted for a stable fracture. Type III fractures are fractures with a fragment from the occipital condyle and are associated with traction injuries.

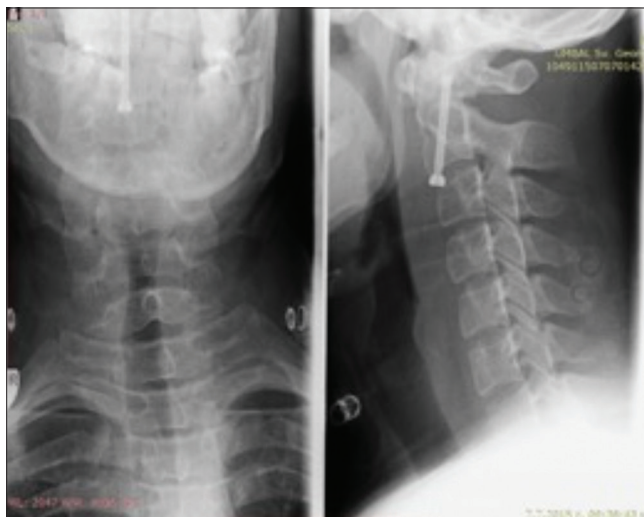

Figure 6: Anterior odontoid screw fixation due to type II fracture (Anderson and D'Alonzo)

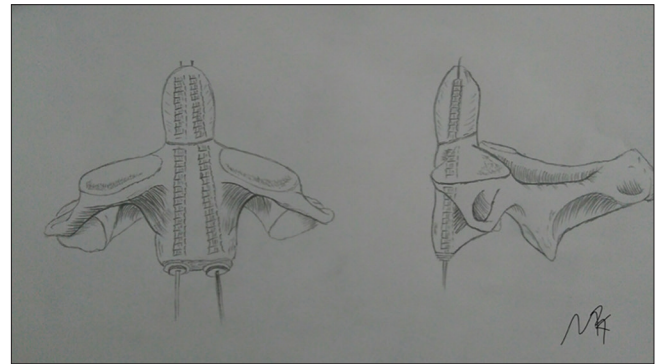


Figure 7: Anterior odontoid screw fixation

Type III fractures are considered unstable and indicated for operative treatment [2], [6], [7], [8].

C1 fractures are about 13% of all cervical fractures [9]. The results from the study of Hadley *et al.* show that only 56% of cases are isolated C1 fractures. In their series, 25 of 57 patients had a combination of C1, and C2 fractures, 9% of the cases also had non-contiguous cervical spine fractures, and 12% had additional head injuries. The results in our study correspond to the results from the series of Hadley – the most common combination was fractures of C1 and C2. This combination may result in more significant mechanical injury and instability of the segment.

The most common clinical findings are a pain in the upper cervical spine and muscle spasms in the region. These findings are associated with an impairment of the range of motion in the craniocervical region – mainly the rotation [9], [10]. Torticollis could also be seen. On the other hand – the neurologic deficit is uncommon [10]. This is why the necessity of imaging diagnostics could be overlooked. Domenicucci *et al.* have described the Collet–Sicard syndrome: As an impairment of the caudal cranial nerves (IX–XII). Furthermore, in a C1 Fracture, tinnitus, nausea, vomiting, and blurred vision could be developed. These symptoms are due to impaired perfusion in the region of the basilar artery and the possible trauma of the vertebral arteries [10]. Several classification systems are in use for evaluating the C1 fractures. Perhaps, the most widely used ones are the systems of Gehweiler, Jefferson, and Landells. Gehweiler *et al.* divide the C1 Fractures into six Groups [12]: Type I fractures are fractures on the anterior arch of the Atlas, and Type II fractures – on the posterior arch of the C1. Type III fracture equals the typical “Jefferson” fracture – both anterior and posterior arches are injured. Type IV fractures are fractures of the lateral mass of the atlas. Type V fractures are fractures of the transverse process. It is crucial to evaluate the stability of the segment. If there is a Type III fracture and the transverse Atlantal ligament is impaired – a craniocervical instability should be expected. This type of fracture is classified as Type IIIb fracture [12,13].

Fractures of the axis account for between 17% and 27% of cervical fractures [14]. In our series, 79% of

the injuries led to C2 fractures. Axis fractures could be divided into fractures of the dens of C2, a Hangman's fracture, and miscellaneous C2 fractures [14].

The odontoid fracture is the most common cervical spinal injury in adults above 70 years of age [15]. Furthermore, the odontoid fracture is more common in patients above 79 years of age than all other cervical fractures combined [15]. Crockard *et al.* report mortality rates between 25% and 40% in case of a fracture of the Dens [16]. For the general practitioners is important the age distribution of the dens fractures – two peaks are proven – high-energy traumas in young patients and low-energy injuries in elderly patients [17]. In our clinical study, the leading mechanism of injury was motor vehicle accidents – 30.6%. Falls were the second most common reason for fractures – 23.61%. This trauma mechanism was typical for elderly patients. Degenerative spine and the rigid cervical caudal segment in elderly patients are preconditions for fractures and ligamentous injuries. These facts, together with the low bone density in elderly patients, could explain the rates of craniocervical fractures in the elderly [18], [19].

Anderson and D'Alonzo classify the odontoid fractures in Type I – fracture through the tip of the Dens; Type II – fracture through the neck of the odontoid, Type II A: Similar to Type II but with a fragment, Type III – fracture that involves the body of C2. The odontoid fractures Type II and Type II an are believed to be unstable and Type III – stable. There are different opinions regarding the stability of Type I fracture, and precise evaluation of the alar ligaments is mandatory (Figure 4).

Hangman's fractures result from hyperextension and axial loading in the cervical region. The hangman's fractures are the combination of bilateral fractures of pars interarticularis and subluxation of C2 on C3. Motor vehicle accidents and diving accidents are the leading reasons for such fractures [18]. Most of the patients are neurologically intact, but symptoms such as paresthesias or monoparesis could be presented [20]. In contrast with the literature in our clinical study, about 40.3% of the patients were presented with neurological symptoms. The Effendi *et al.* classification system and the modified system by Levine are the broadest systems used [21], [22].

Fractures in the craniocervical region could be managed non-surgically (external immobilization) and surgically (variety of operative techniques) depending on the type of the fracture(s) and the integrity of the ligaments [22], [23], [24]. In cases of stable fractures and no neurologic deficit external immobilization through a rigid collar, SOMI brace or HALO brace immobilization systems could be considered [23], [24]. A Halo brace consists of a metal ring and pins that are fixed to the cranium and a vest [25]. Immobilization should take 8–14 weeks, and the system is removed after a fusion of the fracture that can be visualized with a CT [3]. The general practitioners could face the different complications of the Halo brace immobilization system: A resistance of

the patients to wear the Halo brace, pseudoarthrosis of the fracture, malposition or infection of the pins, and skin defects. Strohm *et al.* report infections of the cranial pins in 10% of the cases, and 5% have detected a loosening of the pins. About 25% of the patients had complained of pain in the inserted cranial pins [25]. In such a scenario, the general practitioner could start antibiotic treatment, and the patient should be seen by the surgeon.

If the indications are covered, different operative techniques could be performed depending on the type of fracture. Anterior (including transoral) and posterior approaches could be used – Occipitocervical fixation and fusion (Figure 5); anterior odontoid screw fixation (Figure 6); posterior atlantoaxial fusion [26]; and isolated atlas osteosynthesis [27].

The general practitioner could detect significant or minor surgical complications in the post-operative period. The different operative techniques are associated with different complications. In anterior odontoid screw fixation (Figure 7), Lall *et al.* report malposition of the screw in 3.2% of the cases, displacement of the screw in 3.2% of the cases, and fracture of the screw in 0.3%. The most common complication of the occipitocervical fixation in the previously mentioned series is the infection – 11% [10]. Further studies review occipitocervical fixation complication rates between 10% and 33% – infections, cerebral spinal fluid (CSF) leakage (a sign of a dural tear), and implant failure. Another possible complication is the damage to the vertebral artery due to screw malposition [28]. In vertebral artery impairment, a CT-angiography or digital subtraction angiography should be performed [28]. Rarely, a meningitis or misalignment of the head could be observed [28]. In such a scenario, laboratory tests of blood and CSF samples and imaging should be performed. Depending on the operative result and the patient's bone density, a neck collar could be prescribed (Philadelphia- or Miami J Collars) [28], [29], [30]. The period of immobilization is from 4 to 8 weeks. The general practitioner may prescribe a bone density test.

If the general practitioner has a patient who underwent surgery for a fracture in the craniocervical junction, it will inevitably raise the question of whether the instrumentation will be removed in the future. Depending of the surgical techniques used – with or without cervical fusion, the instrumentation may be removed after imaging that verifies the fusion of the fracture. Ma *et al.* have studied the patient postcervical instrumentation without fusion for odontoid fractures. The authors report an improvement in range of motion, reduction of the neck disability index, and neck stiffness in patients with removed instrumentation [31]. Our experience supports the results of Ma *et al.* [32] In our clinic, removal of the instrumentation in patients post-operation for craniocervical junction fracture and proven fusion of the fracture is favored. We believe that the operative risks and the risks connected with the general anesthesia are justified due to the improvement of the range of motion and neck disability index.

## Conclusion

General practitioners will likely face patients who have fractures in craniocervical junction. Not only the elderly patients but also the young patients suffer from such fractures – every age group has a specific trauma mechanism. The knowledge about the specifics of the fractures in the craniocervical segment, the diagnostic pattern, and the treatment options could help general practitioners to play a crucial role in the diagnostic, post-operative period, and observation of complications.

## References

- Lang J. Cervical region, osteology and articulations. *Neuro Orthopedics*. 1986;1:67-92.
- Maserati MB, Stephens B, Zohny Z, Lee JY, Kanter AS, Spiro RM, et al. Occipital condyle fractures: Clinical decision rule and surgical management. *J Neurosurg Spine*. 2009;11(4):388-95. <https://doi.org/10.3171/2009.5.SPINE08866>  
PMid:19929333
- Greenberg MS. *Handbook of Neurosurgery*. 8<sup>th</sup> ed. New York, United States: Thieme; 2016.
- Squarza S, Uggetti CL, Politi MA, Pescatori LC, Bisogno R, Campi A, et al. C1-C2 fractures in asymptomatic elderly patients with minor head trauma: Evaluation with a dedicated head CT protocol. *Radiol Bras*. 2019;52(1):17-23. <https://doi.org/10.1590/0100-3984.2017.0154>  
PMid:30804611
- Dickman CA, Mamourian A, Sonntag VK, Drayer BP. Magnetic resonance imaging of the transverse atlantal ligament for the evaluation of atlantoaxial instability. *J Neurosurg*. 1991;75(2):221-7. <https://doi.org/10.3171/jns.1991.75.2.0221>
- Anderson PA, Montesano PX. Morphology and treatment of the occipital condyle fractures. *Spine (Phila Pa 1976)*. 1988;13(7):731-6. <https://doi.org/10.1097/00007632-198807000-00004>  
PMid:3194779
- Bloom AI, Neeman Z, Slasky BS, Floman Y, Milgrom M, Rivkind A, et al. Fracture of the occipital condyles and associated craniocervical ligament injury: Incidence, CT imaging and implications. *Clin Radiol*. 1997;52(3):198-202. [https://doi.org/10.1016/s0009-9260\(97\)80273-5](https://doi.org/10.1016/s0009-9260(97)80273-5)  
PMid:9091254
- Caroli E, Rocchi G, Orlando ER, Delfini R. Occipital condyle fractures: Report of five cases and literature review. *Eur Spine J*. 2005;14(5):487-92. <https://doi.org/10.1007/s00586-004-0832-z>  
PMid:15754215
- Hadley MN, Dickman CA, Browner CM, Sonntag VK. Acute traumatic atlas fractures: Management and long term outcome. *Neurosurgery*. 1988;23(1):31-5. <https://doi.org/10.1227/00006123-198807000-00007>  
PMid:3173661
- Kandziora F, Scholz M, Pingel A, Schleicher P, Yildiz U, Kluger P, et al. Treatment of atlas fractures: Recommendations of the spine section of the German society for orthopaedics and trauma (DGOU). *Glob Spine J*. 2018;8(2):5S-11. <https://doi.org/10.1177/2192568217726304>  
PMid:30210964
- Domenicucci M, Mancarella C, Dugoni ED, Ciappetta P, Paolo M. Post-traumatic collet-sicard syndrome: Personal observation and review of the pertinent literature with clinical, radiologic and anatomic considerations. *Eur Spine J*. 2015;24(4):663-7. <https://doi.org/10.1007/s00586-014-3527-0>  
PMid:25150715
- Gehweiler JA, Osborne RL, Becker RF. *The Radiology of Vertebral Trauma*. St. Louis, MO: WB Saunders; 1980.
- Kandziora F, Schnake K, Hoffmann R. Injuries to the upper cervical spine. *Unfallchirurg*. 2010;113(12):1023-41. <https://doi.org/10.1007/s00113-010-1896-3>  
PMid:21153464
- Kepler CK, Vaccaro AR, Fleischman AN, Traynelis VC, Patel AA, Dekutoski MB, et al. Treatment of axis body fractures: A systematic review. *Clin Spine Surg*. 2017;30(10):442-56. <https://doi.org/10.1097/BSD.0000000000000309>  
PMid:29176489
- Ryan MD, Taylor TK. Odontoid fractures in the elderly. *J Spinal Disord*. 1993;6(5):397-401. <https://doi.org/10.1097/00002517-199306050-00005>  
PMid:8274807
- Crockard HA, Heilman AE, Stevens JM. Progressive myelopathy secondary to odontoid fractures: Clinical, radiological, and surgical features. *J Neurosurg*. 1993;78(4):579-86. <https://doi.org/10.3171/jns.1993.78.4.0579>  
PMid:8450331
- Meyer C, Oppermann J, Meermeyer I, Eysel P, Müller LP, Stein G. Therapiekonzept und Outcome bei Typ-II-Frakturen des Dens axis. *Unfallchirurg*. 2018;121:397-402. <https://doi.org/10.1007/s00113-017-0428-9>
- Malik SA, Murphy M, Connolly P, Byrne JO. Evaluation of morbidity, mortality and outcome following cervical spine injuries in elderly patients. *Eur Spine J*. 2008;17(4):585-91. <https://doi.org/10.1007/s00586-008-0603-3>  
PMid:18196293
- Brolin K. Neck injuries among the elderly in Sweden. *Inj Control Saf Promot*. 2003;10(3):155-64. <https://doi.org/10.1076/icsp.10.3.155.14558>  
PMid:12861914
- Francis WR, Fielding JW, Hawkins RJ, Pepin J, Hensinger R. Traumatic spondylolisthesis of the axis. *J Bone Joint Surg Br*. 1981;63-B(3):313-8. <https://doi.org/10.1302/0301-620X.63B3.7263740>  
PMid:7263740
- Effendi B, Roy D, Cornish B, Dussault RG, Laurin CA. Fractures of the ring of the axis: A classification based on the analysis of 131 cases. *J Bone Joint Surg Br*. 1981;63-B(3):319-27. <https://doi.org/10.1302/0301-620X.63B3.7263741>  
PMid:7263741
- Levine AM, Edwards CC. The management of traumatic spondylolisthesis of the axis. *J Bone Joint Surg Am*. 1985;67(2):217-26.  
PMid:3968113
- Dickman CA, Greene KA, Sonntag VK. Injuries involving the transverse atlantal ligament: Classification and treatment guidelines based upon experience with 39 injuries. *Neurosurgery*. 1996;38(1):44-50. <https://doi.org/10.1097/00006123-199601000-00012>  
PMid:8747950
- Polin RS, Szabo T, Bogaev CA, Replogle RE, Jane JA. Nonoperative management of types II and III odontoid fractures: The Philadelphia collar versus the halo vest. *Neurosurgery*. 1996;38(3):450-7. <https://doi.org/10.1227/00006123-199603000-00012>

- org/10.1097/00006123-199603000-00006  
PMid:8837795
25. Sonntag VK, Hadley MN. Nonoperative management of cervical spine injuries. *Clin Neurosurg.* 1988;34:630-49.  
PMid:3288418
26. Strohm PC, Müller CA, Köstler W, Reising K, Südkamp NP. Halo-fixator vest--indications and complications. *Zentralbl Chir.* 2007;132(1):54-9. <https://doi.org/10.1055/s-2006-960479>  
PMid:17304437
27. Holly LT, Anderson PA. *Essential of Spinal Stabilization.* 1<sup>st</sup> ed. Switzerland: Springer; 2017. p. 566.
28. Schmidek and Sweet *Operative Neurosurgical Techniques.* 5<sup>th</sup> ed., Vol. 1. New York: Saunders Elsevier; 1982.
29. Lall R, Patel NJ, Resnick DK. A review of complications associated with craniocervical fusion surgery. *Neurosurgery.* 2010;67(5):1396-402. <https://doi.org/10.1227/NEU.0b013e3181f1ec73>  
PMid:20871441
30. Ashafai NS, Visocchi M, Wąsik N. Occipitocervical fusion: An updated review. *Acta Neurochir Suppl.* 2019;125:247-52. [https://doi.org/10.1007/978-3-319-62515-7\\_35](https://doi.org/10.1007/978-3-319-62515-7_35)  
PMid:30610329
31. Visocchi M, Mattogno PP, Signorelli F, Zhong J, Iacopino G, Barbagallo G. Complications in craniocervical junction instrumentation: Hardware removal can be associated with long-lasting stability. Personal experience. *Acta Neurochir Suppl.* 2017;124:187-94. [https://doi.org/10.1007/978-3-319-39546-3\\_29](https://doi.org/10.1007/978-3-319-39546-3_29)  
PMid:28120073
32. Ma F, Fan Y, Liao Y, Tang Q, Tang C, Xu S, *et al.* Management of fresh odontoid fractures using posterior C1-2 fixation without fusion: A long-term clinical follow-up study. *J Neurosurg Spine.* 2021;36(6):1-11. <https://doi.org/10.3171/2021.9.SPINE21822>  
PMid:34920424