

Iselin' Disease - Apophysitis of the Fifth Metatarsal Base: Report of Two Cases

Vilson Ruci^{1*}, Artid Duni¹, Dorina Serani²

¹Department of Orthopaedics, "Mother Teresa" University Hospital, Tirana, Albania; ²Service of Rheumatology, "Mother Teresa" University Hospital, Tirana, Albania

Abstract

Citation: Ruci V, Duni A, Serani D. Iselin' Disease - Apophysitis of the Fifth Metatarsal Base: Report of Two Cases. OA Maced J Med Sci. 2013 Dec 15; 1(1):99-101. http://dx.doi.org/10.3889/oamjms.2013.020

Key words: Iselin; epiphysitis; apophysitis; adolescent; metatarsal.

***Correspondence:** Dr. Vilson Ruci. Faculty of Medicine, University of Tirana, Department of Orthopaedics. R. Lord Bairon Trauma Hospital Centre Laprake, Tirana 1000, Albania. Phone: 0035542223929. E-Mail: ruciv@yahoo.com

Received: 03-Sep-2013; **Revised:** 07-Oct-2013; **Accepted:** 16-Oct-2013; **Online first:** 30-Oct-2013

Copyright: © 2013 Ruci V. This is an open-access article distributed under the terms of the Creative Commons Attribution License, which permits unrestricted use, distribution, and reproduction in any medium, provided the original author and source are credited.

Competing Interests: The authors have declared that no competing interests exist.

Iselin' disease is a benign adolescent growth disturbance of the base of the fifth metatarsal called epiphysitis or apophysitis by others caused by abnormal traction of peroneus brevis tendon. This abnormality is rarely reported in medical literature, probably due to the benign nature and spontaneous healing in almost all cases. The affection should be known to medical specialist like orthopedists, radiologists, physical therapists and pediatricians. The differential diagnosis is made with Jones' fracture of the fifth metatarsal and os vesalianum which is a congenital anomaly. We present two our cases with their similarities in clinical findings, typical radiologic images and complete relief from symptoms with conservative treatment.

Introduction

Iselin [1] in 1912 described for the first time a traction epiphysitis of the base of the fifth metatarsal in adolescents at the time of appearance of the secondary center of ossification of the fifth metatarsal base. Most children will present with a limp and complain of pain at the outside edge of the midfoot that is exacerbated by increased physical activity (running, jumping and dance) and feels better with rest. The child may walk on the inside of the foot to relieve pressure at the growth centre. There may be localized pain, swelling, redness and warmth at the growth centre on the outside of the foot [2, 3].

The bone in this is located within the cartilaginous envelope onto which the peroneus brevis inserts. It is visible better in oblique roentgenograms, but also in anteroposterior and lateral views.

First case

A 13-years old girl was complaining of pain and tenderness over the lateral aspect of the right foot (Fig. 1). No history of acute or chronic trauma was found despite careful anamnesis. The child was participating in gymnastics and aerobic dance in the last twelve months and no sport injury was reported. The child and her parents were seeking medical help from one year with no results. The child was consulted by one of us and no medical problem was found. Erythrocyte sedimentation rate, complete blood count, alkaline and acid phosphatase and fibrinogen were within normal values. After taking a careful history, clinical observation and some roentgenograms, we concluded that there was a typical case with Iselin' disease. The foot was put in a posterior splint for three weeks. Analgesics and anti-inflammatory drugs in

moderate doses were given and complete relief of pain was seen in ten days after the first visit.

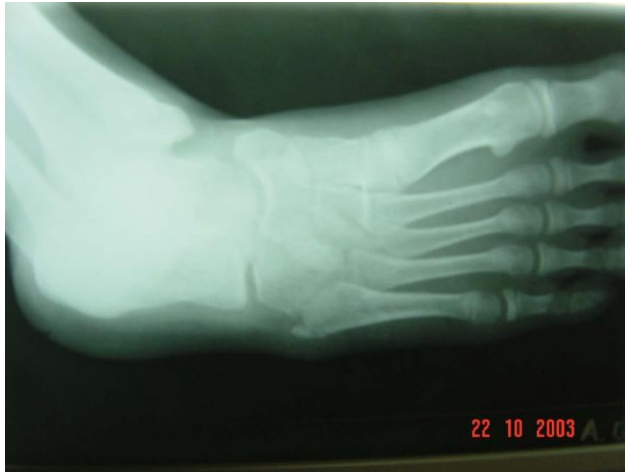

Figure 1: The base of the fifth metatarsal shows avulsion of apophysis caused by over traction of peroneus brevis tendon. The bone fragment is not completely detached from the main metatarsal bone.

Second case

A 12-years- old girl (Fig. 2) with similar findings was presented. The pain and tenderness was from only some days after a vigorous acute physical activity. The child was not participating in sport or recreational activities. Her hobby was joking and jumping. The diagnosis was much easier based on history, localization and roentgenograms taken obliquely.

The foot was splinting for two weeks and the child was much better with no pain and a localized tenderness which disappeared in two to three weeks.

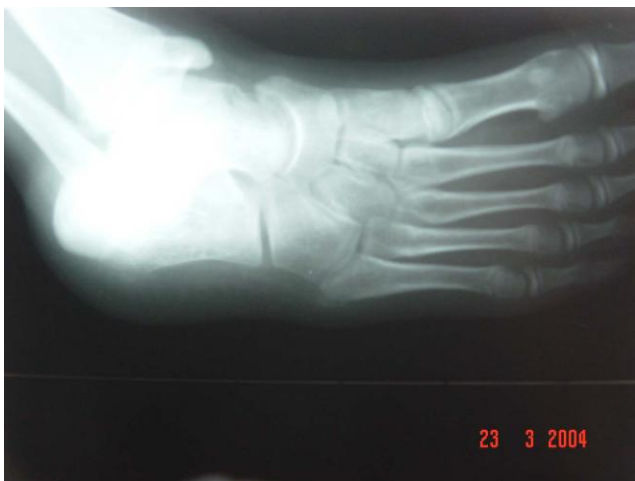

Figure 2: X-Ray of a 12 years old girl with typical finding of avulsed bone from the base of the metatarsal.

Discussion

When Iselin H. described the disease he sustained that the mechanism was similar to the

Osgood-Schlatter disease but with minor clinical findings. The disorder is rarely described in literature probably due to its benign nature and spontaneous resolution. This secondary centre of ossification rarely causes problems seeking attention or medical intervention.

Iselin's disease causes pain and tenderness over the prominent proximal fifth metatarsal. Activities like running, jumping or other movement needing dorsiflexion, may provoke the condition. Treatment options are generally conservative measures starting with rest, soft bandaging of foot along with ankle joint to relieve the tension from the peroneus brevis tendon. Anti-inflammatory drugs may be prescribed combined with analgesics and ice packages around the lateral aspect of foot. Short leg cast is rarely needed to assure complete relief from tendon traction.

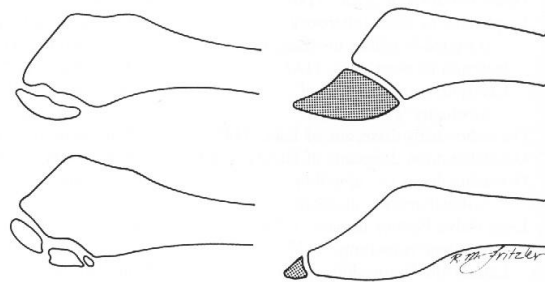


Figure 3: Schematic drawing illustrating the difference between traction epiphysitis (left) and os vesalianum (right) a congenital anomaly of the base of the fifth metatarsal bone.

If conservative treatment is not successful or the affection seems to be refractory, a non-union of the epiphysis may be established [5]. The surgical options may have a role sometimes, including removal of the bone fragment or in certain cases internal fixation of the fragment to the lateral part of the proximal metaphysis of the fifth metatarsal bone.

If removal of bone fragment is chosen the surgeon have to be sure that it does not affect the normal function of peroneus tendon. Gradual return to full physical activity should be monitored by the parents and the physician.

The condition must be distinguished from os vesalianum, a sesamoid bone in peroneus brevis tendon [9] and from fracture of the base of fifth metatarsal known as Jone's fracture (Fig. 3).

References

1. Iselin H. *Deutsch Zeit Chir.* 1912;117:529.
2. Canale ST, Williams KD. Iselin's disease. *J Pediatr Orthop.* 1992;12(1):90-3.
3. Schwartz B, Jay RM, Schoenhaus HD. Apophysitis of the fifth metatarsal base. Iselin's disease. *J Am Pediatr Med Assoc.* 1991; 81(3):128-30.

4. Gillespie H. Osteochondroses and apophyseal injuries of the foot in the young athlete. *Curr Sports Med Rep.* 2010; 9(5):265-8.
5. Ralph BG, Barrett J, Kenyhercz C, DiDomenico LA. Iselin's disease: a case presentation of nonunion and review of the differential diagnosis. *J Foot Ankle Surg.* 1999; 38(6):409-16.
6. Tessore A, Carli M, Tos L. Epiphysitis of the basis of the 5th metatarsus. (Iselin's disease). *Arch Putti Chir Organi Mov.* 1971; 26:235-45.
7. Lehman RC, Gregg JR, Torg E. Iselin's disease. *Am J Sports Med.* 1986; 14:494-496.
8. Martí Fernández J, Espinosa Farrona C. Enfermedad de Iselin; un caso en un joven deportista. *Rev Pediatr Aten Primaria.* 2013;15:69-72.
9. Dorrestijn O, Brouwer RW. Bilateral symptomatic os vesalianum pedis: a case report. *J Foot Ankle Surg.* 2011;50(4):473-5.
10. Gillespie H. Osteochondroses and apophyseal injuries of the foot in the young athlete. *Curr Sports Med Rep.* 2010;9(5):265-8.