

# Effect of Newly Synthesized Polypropylene/Silver Nonwoven Fabric Dressing on Incisional Wound Healing in Rats

Samiha M. Gawish<sup>1</sup>, Amina A. Gamal El Din<sup>2</sup>, Hanaa H. Ahmed<sup>3</sup>, Abdel Razik H. Farrag<sup>2\*</sup>, Amira Abou-El Kheir<sup>1</sup>

<sup>1</sup>Textile Division, National Research Centre, Cairo, Egypt; <sup>2</sup>Pathology Department, National Research Centre, Cairo, Egypt; <sup>3</sup>Hormones Department, National Research Centre, Cairo, Egypt

## Abstract

**Citation:** Gawish SM, El Din AAG, Ahmed HH, Farrag ARH, Abou-El Kheir A. Effect of Newly Synthesized Polypropylene/Silver Nonwoven Fabric Dressing on Incisional Wound Healing in Rats. OA Maced J Med Sci. 2014 Sep 15; 2(3):395-403.  
http://dx.doi.org/10.3889/oamjms.2014.068

**Key words:** Polypropylene/Silver; Nonwoven; Dressing; Wound healing; Rats.

**\*Correspondence:** Prof. Abdel Razik H. Farrag, National Research Centre, Pathology, 33 Elbohooth St. Dokki Cairo, Egypt 12622, Egypt. E-Mail: abdelrazikfarrag@yahoo.co.uk

**Received:** 03-Mar-2014; **Revised:** 11-May-2014; **Accepted:** 12-May-2014; **Online first:** 18-Jun-2014

**Copyright:** © 2014 Gawish et al. This is an open access article distributed under the terms of the Creative Commons Attribution License, which permits unrestricted use, distribution, and reproduction in any medium, provided the original author and source are credited.

**Competing Interests:** The authors have declared that no competing interests exist.

**AIM:** The present work aimed to investigate the effect of the antimicrobial nano Ag/polypropylene (PP\Ag) dressing on incisional wound healing on the experimental level.

**MATERIALS AND METHODS:** Male albino rats were divided into, control, PP/Ag dressing, Silver Sulfadiazine (Ag-SD) cream, blank PP dressing and undressed groups. Animals were sacrificed after 5, 10 and 15 days of incisional wound event.

**RESULTS:** Reduction was found in incision wound length in PP/Ag dressed rats, Ag-SD cream treated rats, and blank PP dressed rats after 5, 10 and 15 days compared to undressed rats. Skin of PP/Ag group showed less adverse histopathological changes, enhanced granulation tissue formation, enhanced angiogenesis, accelerated re-epithelialization and quick complete healing; compared to all other groups. Significant decrease in TGF- $\beta$  level was recorded in PP\Ag and Ag-SD cream groups as compared to blank PP group on day 5. While, significant decrease in TGF- $\beta$  level was detected in PP\Ag group when compared with undressed and blank PP groups on day 10. TGF- $\beta$  showed significant in PP\Ag group as compared to undressed, Ag-SD cream and blank PP groups on day 15.

**CONCLUSION:** The present results suggest that PP/Ag dressing enhances, promotes and plays an important role in wound healing.

## Introduction

Wound has been known as a disruption of the normal anatomical structure and, more importantly, function [1]. Superficial wounds show injury encompassing the epidermal skin surface alone. Moreover, partial thickness wound shows injury involving both the epidermis and the deep dermis layers, including the blood vessels, sweat glands and hair follicles. While, damaging in the underlying subcutaneous fat or deeper tissues in addition to the epidermis and dermal layers defined as full thickness wounds [2].

Severe wounds are very dangerous and are the primary cause of mortality in patients. The environmental microorganisms surrounding the body and the skin barrier usually infected the wound, thus the defence mechanisms is disturbed. Infection is the main cause of delayed healing in primarily closed (surgical) wounds, traumatic and burn wounds, and chronic skin ulcer [3]. In fact, microorganisms, ie, bacteria or fungi are found in chronic wounds and if

present in an acute wound can rapidly contaminate and infect, seriously impeding wound healing. Thus, levels of bacteria, multi-resistant organisms, and bacterial biofilms can impact on the wound-healing process especially in chronic wounds [4]. Bacteria delay wound healing by competing with host cells for nutrients and oxygen, their waste products are also toxic to host cells. Bacterial wound infection causes raised blood cytokines, raised matrix metallo-proteinase, and decreased growth factors which can have adverse effects on wound healing. Local wound infection causes tissue death, increase in wound size, wound hypoxia, and vessels occlusion which all further delay the wound healing process [5].

Dressings play a major part in the management of wounds [3]. In recent times, the development of resistant strains of pathogens has become a major problem and the newly designed wound dressing has provided a major breakthrough for the treatment of infection and wounds. The antibacterial properties and the toxicity of silver to

micro-organisms is well known, thus, now a days, silver is used in different kinds of formulations like surface coating agents, wound dressing, etc [6]. The silver dressings make use of delivery systems that release silver in different concentrations and the mechanism of action of metallic silver is linked with its interaction with thiol group compounds found in the respiratory enzymes of bacterial cells. As silver binds to the bacterial cell wall and cell membrane and inhibits the respiration process [7]. In case of *E. coli*, silver acts by inhibiting the uptake of phosphate and releasing phosphate, mannitol, succinate, proline and glutamine from *E. coli* cells [8].

The mechanism for the antimicrobial action of silver ions is not properly understood. However, it is suggested that when DNA molecules are in relaxed state the replication of DNA can be effectively conducted. But when the DNA is in condensed form, it loses its replication ability. Hence, when the silver ions penetrate inside the bacterial cell the DNA molecule turns into condensed form and loses its replication ability leading to cell death [9]. Reducing the particle size of materials is an efficient and reliable tool for improving their biocompatibility. In fact, nanotechnology helps in overcoming the limitations of size and can change the outlook of the world regarding science [10]. Furthermore, nanomaterials can be modified for better efficiency to facilitate their applications in different fields such as bioscience and medicine.

In the past few decades, researchers are taking interest in the development of textile fabrics containing antibacterial agents. As silver is non-toxic and possesses antimicrobial properties, it has encouraged workers to use silver nanoparticles in different textile fabrics. In this direction, silver nanocomposite fibres were prepared containing silver nanoparticles incorporated inside the fabric [11]. Thus, various silver-based dressings have been introduced and have become the latest and greatest "innovation" in wound care products. The "innovation" involved in these new wound care products is the simple fact that silver itself is incorporated within the dressing rather than being applied as a separate salt, compound, or solution.

The basic issues in choosing a silver-containing dressing can be broadly conceptualized in terms of: (1) the characteristics of the "carrier" dressing and (2) the delivery of silver by the dressing to the wound marketing blitz accompanying these products [12].

No comparative studies have previously been published and consequently there is no substantial evidence to document the added benefits of silver dressings compared with traditional absorbent moist healing dressings in the healing of venous ulcer wounds [13].

In this study, we synthesized a new wound dressing PP/Ag, a soft nonwoven fabric, using PP/Ag

nanometal and an extrusion melt spinning technique at 250°C to produce the yarns, which are crimped, cut and processed to a nonwoven fabric in NCSU. This nonwoven PP/Ag dressing was investigated to evaluate its effect on incisional wound healing on the experimental level.

## Materials and Methods

### *Materials*

Silver sulfadiazine (Ag-SD) cream was purchased from Monarch Pharmaceuticals Pfizer incorporated, USA. It is an antibiotic belongs to a class of drugs known as sulfa. It is applied topically to help prevent and treat wound infections in patients with serious burns. Silver sulfadiazine works by stopping the growth of bacteria that may infect an open wound. This helps to decrease the risk of the bacteria spreading to surrounding skin, or to the blood where it can cause a serious blood infection (sepsis). Its chemical formula is (C<sub>10</sub>H<sub>9</sub>AgN<sub>4</sub>O<sub>2</sub>S).

### *Preparation of Polypropylene/Silver Nonwoven Dressing*

The antibacterial nonwoven fabrics were produced from their corresponding PP/Ag continuous yarns. The yarns were prepared in a conjugate melt spinning machine which is composed of two extruders and gear pumps at 250 °C [14]. The nano metals additives were well blended with the dried PP chips to ensure uniform mixing before loading the feed hopper of the extruder. The yarns were formed and extruded through the spinnerets holes when the molten PP was quenched in the ambient air. The yarns were rolled into bobbins, then crimped, cut into 50-70 mm long and processed to a nonwoven fabric. Blank PP dressing was a gift from NCSU.

### *Antibacterial Activity of Polypropylene/Silver Nonwoven Dressing*

Antibacterial activity was determined according to ASTM E2149 method.

### *Silver Ion Release from Polypropylene/Silver Nonwoven Fabrics*

One gram nonwoven PP/Ag samples was stored and shake in flasks containing 100 ml aqueous solution (93 ml distilled water and 7 ml 0.1 N HNO<sub>3</sub> [15] at ambient temperature for the selected immersion time (1-8 days). HNO<sub>3</sub> was added to protect the released Ag<sup>+</sup> ions from reducing to metallic silver. Atomic absorption spectroscopy was used for the quantitative determination of the silver ion content in the solution released from the nonwoven fabric with time.

## Experimental Design

### Experimental Animals

Adult male albino rats weighing 180-200 g were obtained from the Animal House Colony of the National Research Centre, Cairo, Egypt and acclimatized in a specific area of  $25 \pm 1^\circ\text{C}$  temperature and humidity 55%. Rats were controlled constantly with a 12 hrs light/dark cycles at National Research Centre Animal Facility Breeding Colony. Rats were individually housed with *ad libitum* access to standard laboratory diet and tap water. Rats were cared for according to the guidelines for animal experiments which have been approved by the Ethical Committee of Medical Research at the National Research Centre, Cairo, Egypt.

## Methods

### Incisional Open Wound Study

The present study was conducted on 90 albino male rats (180-200 g each 18 rats/group). Wound Incision Creation: Shaving the hair of the dorsal midline of the rats was performed for an area (2.5 X 2.5 cm) under light ether anesthesia. A longitudinal full thickness wound incision; 2 cm long was made in the dorsal midline through skin and subcutaneous tissue down to the fascia of the subcutaneous muscle layer. The present was conducted on 5 groups of rats which were assigned as follows: **Group (G1)**: Positive control: rats with an induced surgical incision wound 2 cm long in the skin of back of the animal left undressed. **Group (G2)**: Rats with a surgical incision wound dressed with the prepared Ag/PP antibacterial nonwoven square dressing (5x5 cm); which is applied covering the induced wound immediately after incision wound creation, **Group (G3)**: Rats with a surgical incision wound treated with Ag-SD cream applied to the induced wound immediately after incision wound creation, **Group (G4)**: Rats with a surgical incision wound dressed with traditional absorbent moist wound healing blank PP dressing (5x5 cm) applied to the induced wound immediately after incision wound creation, **Group (G5)**: Negative control: rats were kept without any incision wounds. Each group contained three subgroups (6 rats/subgroup) which were sacrificed 5, 10 and 15 days respectively, from the start of the experiment.

### Samples Collection

Macroscopic incision wound measurements were taken from the rats in all groups after 5, 10, and 15 days from the start of the experiment. The length of the wound incision was measured and photographed. Then, the blood samples were collected from animals in each group using the orbital sinus technique under light anesthesia in EDTA free tubes to separate sera

for measurement of transforming growth factor- $\beta$  (TGF- $\beta$ ).

### Pathology Study

The rats of each group were sacrificed under anaesthesia and the wounded areas were resected with inclusion of healthy areas. Skin samples were taken on days 5, 10 and 15 from the start of the experiment. The specimens were fixed in buffered formalin. The fixed specimens were dehydrated through different grades of alcohol and xylene, embedded into paraffin blocks and cut into thin 4  $\mu\text{m}$  sections along the plane perpendicular to the skin surface using a microtome. The skin samples were processed for morphometric, histopathological and immunohistochemical evaluation.

### Morphometric Study

The morphometric analysis was performed at the Pathology Department, National Research Centre using the Leica Qwin 500 Image Analyzer (LEICA Imaging Systems Ltd, Cambridge, England) which consists of Leica DM-LB microscope with JVC color video camera attached to a computer system Leica Q 500 W. The morphometric analysis was carried out on haematoxylin and eosin stained slides. The examined slide was placed on the stage of the microscope and focused power magnification (50X). The slide was screened to determine the boundaries of the tissue to be measured. The morphometric measurements were performed on real – time image from the microscope that was visualized on the video monitor. The measuring of the area was made by drawing a line starting from one edge to the other. The results appeared automatically on the monitor in the form of the area in ( $\mu\text{m}^2$ ) with the mean  $\pm$  standard error. The capillary count (neoangiogenesis) was performed using the image analysis to count the number of capillaries per screen (area). The number of completely formed capillaries was counted in five fields for each specimen and the means were obtained automatically  $\pm$  standard error [16].

### Histopathological Investigations

The histopathological examination was carried out using light microscope after staining paraffin sections with haematoxylin and eosin [17].

### Immunohistochemical Study

In order to detect the myofibroblasts in the granulation tissue, which are believed to be a cause of wound contracture, supersensitive monoclonal antibodies for  $\alpha$ -smooth muscle-actin were applied using supersensitive monoclonal antibodies with Dako Envision (Dextran substrate polymer) detection

system. Prior microwave treatment for antigen retrieval was performed with blocking of endogenous peroxidases. DAB was used as chromogen. Sections were examined for the positive myofibroblasts in the blood vessels.

### Biochemical Study

#### Determination of Serum Transforming Growth Factor $\beta$ 1 (TGF- $\beta$ 1)

Serum TGF- $\beta$ 1 was measured quantitatively by a solid phase enzyme linked immunosorbent assay (ELISA) using a kit provided by DRG Diagnostics GmbH (Germany) according to the method of Kropf et al. [18]. In brief, this method depends on the following test principle: Prior to testing, the standards and animal samples are diluted in assay buffer, acidified with HCl and then neutralized with NaOH. Afterwards, the neutralized standards and samples were added to the antibody coated microtiter wells. After the first incubation the unbound sample material was removed by washing with diluted wash solution. Then, a monoclonal mouse anti TGF- $\beta$ 1 antibody, a biotinylated anti mouse IgG antibody and the streptavidin-horseradish peroxidase enzyme complex were incubated in succession. An immuno enzyme sandwich complex was formed. The unbound conjugate was removed by washing. Subsequently substrate solution was added. After a definite time, the color development was stopped by addition of stop solution and the absorbance at 450 nm was measured with a microtiterplate reader. The intensity of the color development is proportional to the TGF- $\beta$ 1 concentration in the sample.

**Calculations:** The results were multiplied with 50 (dilution factor). A standard curve was constructed by plotting the known concentration of standards on X-axis and its corresponding O.D. reading on Y-axis. The concentrations of sample were determined in pg/ml by interpolation on the calibration curve.

#### Statistical analysis

In the present study, all results were expressed as mean  $\pm$  SE error of the mean. Data were analyzed by one way analysis of variances (ANOVA) using the statistical package for social sciences (SPSS), version 11 followed by least significant difference (LSD) to compare significance between groups. The cases of  $P$ -value  $<$  0.05 were considered statistically different.

## Results

#### Determination of silver ion released from nonwoven PP/Ag fabric dressing

Table 1 showed the concentrations of Ag ion released from PP/Ag nonwoven fabric at different

duration. These concentrations were 0.019, 0.25, 0.102, and 0.35 mg/L/g fabric at 1, 5, 2, 7 days, respectively.

**Table 1: Concentration of Ag ion released from PP/Ag nonwoven fabric dressing.**

Type of fabric	Concentration of Ag ion release (mg/L/g fabric)	Time (day)
PP/Ag	0.019	1
PP/Ag	0.25	5
PP/Ag	0.102	2
PP/Ag	0.35	7

#### Antibacterial activity of nonwoven PP/Ag fabric dressing

PP/1% Ag nonwoven knitted fabric dressing caused 99.99% reduction in *E. coli* count after 24 hours incubation and 5 times rinsing. So this concentration was used in the PP/Ag nonwoven fabric dressing during this study.

### Pathology Study

#### Macroscopic findings after wounding

Immediately after incisions were made, a dark red area matching the wound area with edema at the circumference was seen. The lengths of incision were decreased according to the duration of the experiment. It was found that the lengths were 1.5, 0.7, and 0.0 cm after 5, 10, and 15 days in PP/Ag dressed (G2) rats. On the other hand, it was found that the lengths were 1.7, 1.0 and 0.7 in undressed rats, 1.3, 0.6 and 0.1 cm in Ag-SD dressed rats, and 1.6, 0.9 and 0.4 cm in blank PP dressed rats after 5, 10, and 15 days respectively compared to 2cm at the start. In PP/Ag dressed rats compared to blank PP dressed rats, a significant reduction in wound length was noticed on day 10 ( $P < 0.05$ ) and day 15 ( $P < 0.01$ ) as compared to undressed rats on day 10 ( $P < 0.01$ ) and on day 15 ( $P < 0.01$ ) (Table 2).

**Table 2: Morphometric of Wound Length (cm) in different groups.**

Treatment	Wound Length (cm)		
	5	10	15
PP/Ag dressing	1.5 $\pm$ 0.12	0.7 $\pm$ 0.042	0.0 <sup>c</sup>
Ag-SD cream	1.3 $\pm$ 0.117 <sup>a</sup>	0.6 $\pm$ 0.03 <sup>a</sup>	0.1 $\pm$ 0.01 <sup>ab</sup>
Blank PP dressing	1.6 $\pm$ 0.144	0.9 $\pm$ 0.08 <sup>bc</sup>	0.4 $\pm$ 0.03 <sup>abc</sup>
Positive control	1.7 $\pm$ 0.102 <sup>bc</sup>	1 $\pm$ 0.06 <sup>abc</sup>	0.7 $\pm$ 0.05 <sup>abc</sup>
Unwounded-ve control	0.0	0.0	0.0

Data are represented as Mean  $\pm$  SE, No 6 rats/group; a: Significant change in comparison with undressed positive control group; b: Significant change in comparison with Ag-SD cream treated group; c: Significant change in comparison with PP (Blank) dressed group.

#### Morphometric analysis

Morphometric analysis showed that the area of granulation tissue of rat wound were 11746.54, 7620.68 and 5211.74  $\mu\text{m}^2$  in PP/Ag dressed rats (Table 3), 12617.89, 17870.03 and 10974.85  $\mu\text{m}^2$  in Ag-SD cream dressed rats and 18743.06, 22022.6 and 19716.84  $\mu\text{m}^2$  in blank PP dressed rats, 12311.81, 18710.46 and 17620.68  $\mu\text{m}^2$  in undressed rats after 5, 10 and 15 days, respectively. Noteworthy, a highly significant reduction in granulation tissue area was noticed in PP/Ag dressed rats compared to blank

PP dressed rats on day 5 ( $P<0.01$ ), day 10 ( $P<0.01$ ) and day 15 ( $P<0.01$ ) and compared to undressed rats on day 10 ( $P<0.01$ ) and on day 15 ( $P<0.01$ ).

**Table 3: Morphometric of Granulation Tissue Area ( $\mu\text{m}^2$ ) in different groups.**

Treatment	Granulation Tissue Area ( $\mu\text{m}^2$ )		
	5	10	15
PP/Ag dressing	11746.54 $\pm$ 587.32	7620.68 $\pm$ 457.24 <sup>c</sup>	5211.74 $\pm$ 364.82 <sup>c</sup>
Ag-SD cream	12617.89 $\pm$ 261.79	17870.03 $\pm$ 1608.30 <sup>ab</sup>	10974.85 $\pm$ 877.99 <sup>ab</sup>
Blank PP dressing	18743.06 $\pm$ 1312.01 <sup>abc</sup>	22022.6 $\pm$ 1321.35 <sup>ab</sup>	19716.84 $\pm$ 577.34 <sup>abc</sup>
Positive control	12311.8 $\pm$ 1108.06	18710.46 $\pm$ 1871.04 <sup>ab</sup>	17620.68 $\pm$ 1762.06 <sup>abc</sup>
Unwounded-ve control	0.0	0.0	0.0

Data are represented as Mean  $\pm$  SE, No 6 rats/group; a: Significant change in comparison with undressed positive control group; b: Significant change in comparison with Ag-SD cream treated group; c: Significant change in comparison with PP (Blank) dressed group.

Residual granulation tissue area at wound site in Ag-SD cream dressed rats was significantly reduced compared to blank PP dressed group on day 5 ( $P<0.01$ ) and day 15 ( $P<0.01$ ), as compared to undressed group on day 15 ( $P<0.01$ ); while it was significantly increased compared to PP/Ag dressed rats on day 10 ( $P<0.01$ ) and day 15 ( $P<0.01$ ). Thus, wound healing in Ag-SD group was more enhanced compared to blank PP dressed and undressed positive control groups, while it was delayed compared to PP/Ag dressed group. A delay in dense granulation tissue formation at wound site was noticed in blank PP dressed group and in undressed group. As granulation tissue increased between days 5 and 10, and then decreased on day 15 but still not reaching its earlier day 5 value, of PP/Ag dressed rats thus delaying healing occurred.

Capillary count (neovascularization) at wound site Table 4 decreased progressively towards healing reaching 72, 25 and 13 in PP/Ag dressed rats compared to 45, 24 and 18 in Ag-SD dressed rats, 49, 32 and 24 in blank PP dressed rats and 59, 48 and 35 in undressed rats after 5, 10 and 15 days, respectively. Enhanced neovascularization at the wound site was noticed after PP/Ag dressing. Formation of new capillaries started and increased very early, then started to decline progressively starting from day 5, down to day 15. The highest value for capillary count at wound site on day 5 was noticed in PP/Ag dressed group compared to all other groups; denoting enhanced new capillaries very early formation and marked increase till day 5, after which this process progressively declined towards healing, approximating capillary count normal value in unwounded negative control group on day 15. The most marked decrease in capillary count between days 5 and 15 was noticed in PP/Ag dressed rats compared to all other groups, confirming the enhanced healing process.

A significant reduction in capillary count at the wound site was noticed in PP/Ag dressed rats compared to Ag-SD cream dressed rats on day 5 ( $P<0.01$ ) and day 15 ( $P<0.05$ ); and compared to undressed rats on day 10 ( $P<0.01$ ) and on day 15 ( $P<0.01$ ).

**Table 4: Morphometric of neoangiogenesis and re-epithelialization in different groups.**

Treatment	Number of Blood capillaries (neoangiogenesis)			Start of Re-epithelialization
	5	10	15	
PP/Ag dressing	72 $\pm$ 6.48 <sup>c</sup>	25 $\pm$ 2.00	13 $\pm$ 1.3 <sup>c</sup>	Day 5: Complete
Ag-SD cream	45 $\pm$ 3.15 <sup>ab</sup>	24 $\pm$ 2.4	18 $\pm$ 1.62 <sup>a</sup>	Day 10: Partial to complete
Blank PP dressing	49 $\pm$ 2.45 <sup>ab</sup>	32 $\pm$ 1.92 <sup>bc</sup>	24 $\pm$ 1.68 <sup>abc</sup>	Day 15: Partial
Positive control	59 $\pm$ 5.9	48 $\pm$ 4.32 <sup>abc</sup>	35 $\pm$ 3.5 <sup>abc</sup>	Day 15: Partial
Unwounded-ve control	15 $\pm$ 0.9	15 $\pm$ 1.2	15 $\pm$ 1.05	Already intact epithelium

Data are represented as Mean  $\pm$  SE, No 6 rats/group; a: Significant change in comparison with undressed positive control group; b: Significant change in comparison with Ag-SD cream treated group; c: Significant change in comparison with PP (Blank) dressed group.

### Light microscopic findings

Microscopic examination of control rat skin appears with intact epidermis covering and intact underlying tissues (Fig. 1a). Results showed that incision wound in rats skin caused histopathologic changes including: ulceration, gaping and focal loss in all skin layers; starting from the epidermis, extending down to the dermis, muscles and subcutaneous fat (Fig. 1b).

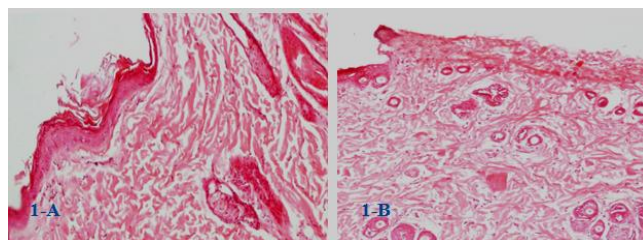


Figure 1: a) Control rat skin with intact epidermis covering and intact underlying tissues, b) Incisionally wounded rat skin; undressed; on day 5; showing loss of all epidermis layers in the incision wound area with fibrin deposition (H & E X 100).

Incisionally wounded in undressed rats skin on day 5 showed marked congestion and haemorrhage with underlying fibrin deposition (Fig. 2a). On the other hand, secondary infection was observed in the form of numerous neutrophils and pus cells. Inflammatory cells infiltrated down to the subcutis.

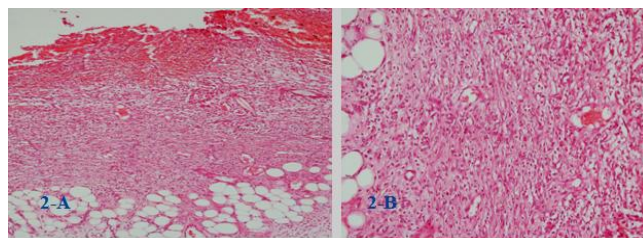


Figure 2: a) Incisionally wounded rat skin on day 5; undressed; showing marked haemorrhage and dense inflammation extending to subcutis (H & E X100), b) incisionally wounded rat skin on day 5; undressed; showing dense inflammation, fibrosis and newly formed blood vessels granulation tissue (H&E X200).

Granulation tissue and fibrosis were seen in the wound area (Fig. 2b) extending from the side margins and also from deeper to superficial layers.

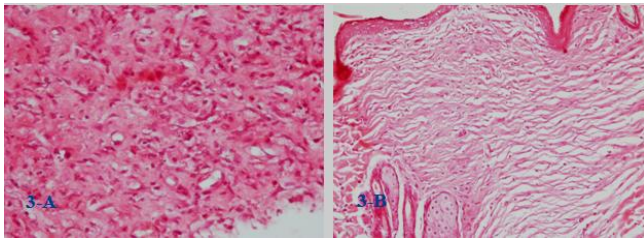


Figure 3: a) Blank PP dressing applied to incisionally wounded rat skin, on day 10, shows granulation tissue formation (H & E X 400), b) Ag-SD cream dressing applied to incisionally wounded rat skin, on day 15, showing thin re-epithelialized epidermis and wedge shaped, moderately cellular, and granulation tissue (H&E X 100).

Fig. 3a showed granulation tissue, which was narrow at the bottom, wider at the top; with numerous thin walled and newly formed blood vessels in blank dressing applied to incisionally wound of rat skin. Application of Ag-SD cream dressing to incisionally wound resulted in thin re-epithelialization of the epidermis and granulation tissue formation (Fig. 3b).

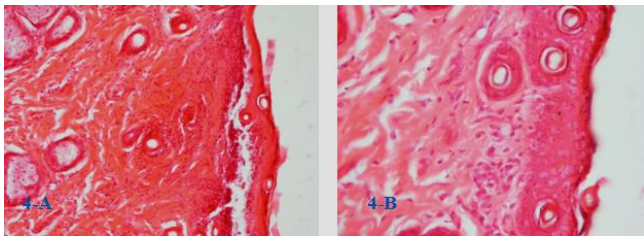


Figure 4: a) Incisionally wounded rat skin, covered with PP/Ag dressing, on day 5, showing complete re-epithelialization with underlying dense inflammation and fibrosis (H & E X 100). b) Incisionally wounded rat skin, covered with PP/Ag dressing, on day 5, showing complete re-epithelialization with underlying inflammatory cell aggregate (H&E X 200).

Skin of PP/Ag dressed rats after incision wounding, showed less adverse histopathologic changes and more quick complete healing; compared to all other groups including undressed incisionally wounded group.

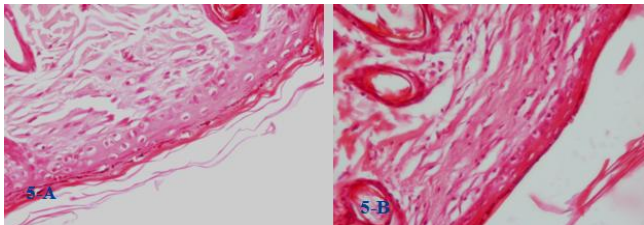


Figure 5: a) Incisionally wounded rat skin, covered with PP/Ag dressing, on day 10, showing complete re-epithelialization with underlying thin fibrotic collagenosed band, entangling scattered inflammatory cells, immediately beneath the epidermis, b) Incisionally wounded rat skin, covered by PP/Ag dressing, on day 15, showing complete re-epithelialization, with collagenosed hypocellular band of fibrous tissue (H & E X 200).

Wrapping with PP/Ag fabric dressing caused histopathologic changes to be less on day 5 (Fig. 4a & b), decreasing more on day 10 (Fig. 5a); transforming into minimal acellular fibrotic collagenosed band just

beneath the epithelium on day 15 (Fig. 5b). Meanwhile, the undressed group, on day 15, still showed wide wedge shaped fibrosis entangling scattered inflammatory cells beneath the covering partially re-epithelialized epithelium.

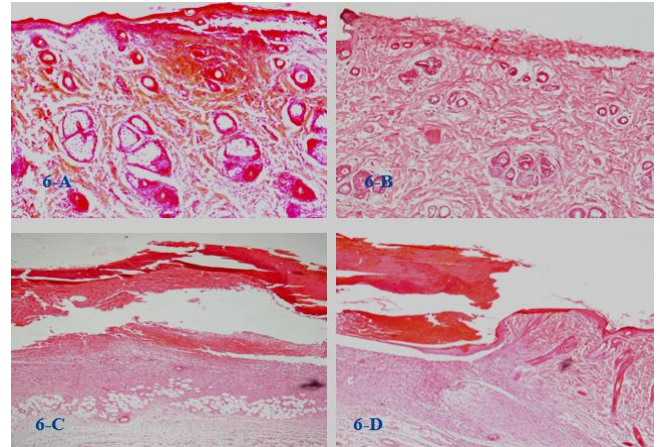


Figure 6: a) PP/Ag dressed incisionally wounded rat skin, on day 5, showing re-epithelialized epithelium with underlying dense inflammation. b) Undressed incisionally wounded rat skin, on day 5, showing epithelial ulceration with loss of all epidermis layers and fibrin deposition at wound site. c) Blank PP dressing applied to incisionally wounded rat skin, on day 10, showing wide epithelial ulceration, extensive haemorrhage and underlying dense inflammation and granulation tissue formation. d) Ag-SD cream dressing applied to incisionally wounded rat skin, on day 10, showing partial epithelial ulceration, congestion and haemorrhage with underlying granulation tissue formation (H & E X100).

Wound gaping in PP/Ag dressed group completely disappeared by day 15 on naked eye examination (Fig. 7b). Re-epithelialization under light microscopy in the re-united wound edges was complete and started from day 5 in PP/Ag dressed group (Fig. 6a), partially and progressively to complete starting from day 10 to day 15 in Ag-SD cream dressed group (Fig 6d & Fig 7a) while it was partially starting only from day 10 in blank PP dressed group (Fig 6c).

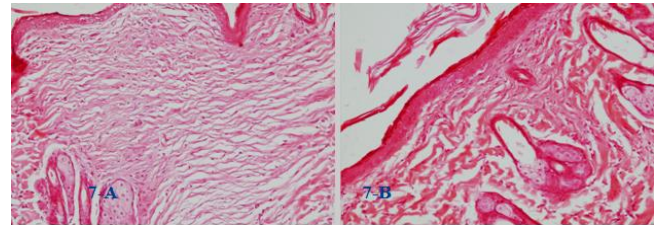


Figure 7: a) Ag-SD cream dressing applied to incisionally wounded rat skin, on day 15, showing thin re-epithelialized epidermis and wedge shaped, moderately cellular, granulation tissue compared to b)- PP/Ag dressing applied to incisionally wounded rat skin, on day 15, showing thicker completely re-epithelialized epidermis, with smaller wedge shaped hypocellular collagenosed fibrous tissue (H & E X 100).

However, in undressed group, the wounded rat skin showed epithelial ulceration with loss of all epidermis layers and fibrin deposition at wound site on day 5 (Fig. 6b).

### Immunohistochemical study

Skin of PP/Ag dressed rats after wound incision showed dense positivity for anti-smooth muscle actin within myofibroblasts in newly formed vascular spaces on day 5 (Fig. 8c) denoting marked angiogenesis enhancing wound contracture and enhanced granulation tissue, accelerating wound fibrosis and thus healing as compared to undressed incisionally wounded group. Wrapping with PP/Ag fabric dressing caused newly formed vascular spaces that initially increased at the early stages of healing process, followed by progressive decrease causing capillary myofibroblasts to be less on day 10, being negative on day 15 denoting its replacement by acellular collagenosed fibrous tissue and designating complete healing. While, incisionally wounded undressed rat skin on day 10 showed dense granulation tissue formation and new capillaries with positive reactivity with anti SMA (Fig. 8a & b).

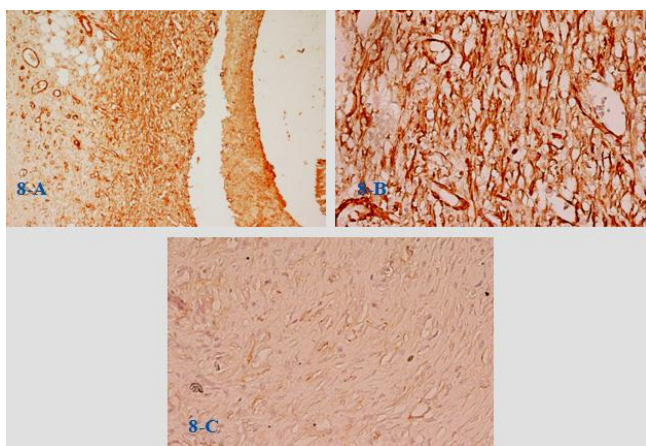


Figure 8: a) Incisionally wounded undressed rat skin on day 10 showing dense granulation tissue formation and new capillaries with positive reactivity with anti SMA (Immunoperoxidase-X 200), b) Incisionally wounded undressed rat skin on day 10 showing dense granulation tissue formation and new capillaries with positive immunoreactivity for anti SMA (Immunoperoxidase-X 400), c) Skin of incisionally wounded rat dressed with PP/Ag on day 10 showing diminished granulation tissue towards healing with fewer capillaries, immunostained with anti SMA (Immunoperoxidase X 400).

### Biochemical study

The data represented in Table 5 showed the effect of PP/Ag, Ag-SD cream and blank PP dressings on serum TGF- $\beta$  level in incisionally wounded rats after 5, 10 and 15 days. The group of rats dressed with PP/Ag or with Ag-SD cream showed highly significant decrease ( $P < 0.01$ ) in serum TGF- $\beta$  level in comparison with blank PP dressed group after 5 days of treatment. While, after 10 days, PP/Ag dressing produced highly significant decrease ( $P < 0.01$ ) in serum TGF- $\beta$  level in comparison with the undressed positive control group as well as blank PP dressed group. After 15 days, PP/Ag dressed group showed highly significant decrease ( $P < 0.01$ ) in serum TGF- $\beta$  level in comparison with the undressed positive control, Ag-SD cream treated and blank PP dressed groups. Meanwhile, Ag-SD cream dressed group

showed significant decrease ( $P < 0.05$ ) in serum TGF- $\beta$  level in comparison with blank PP dressed group.

**Table 5: Effect of PP/Ag, Ag-SD cream and blank PP dressings on serum TGF- $\beta$  level in incisionally-wounded rats after 5, 10 and 15 days.**

Treatment	TGF- $\beta$ (pg/ml)		
	5 days	10 days	15 days
PP/Ag dressing	323 $\pm$ 8.6 <sup>c</sup>	310 $\pm$ 3.6 <sup>a,c</sup>	293 $\pm$ 4.1 <sup>a,b,c</sup>
Ag-SD cream	340 $\pm$ 3.6 <sup>c</sup>	340 $\pm$ 14.6	335 $\pm$ 3.6 <sup>c</sup>
Blank PP dressing	375 $\pm$ 5.5	350 $\pm$ 3.6	345 $\pm$ 1.8
Positive control	355 $\pm$ 15.5	348 $\pm$ 6.4	341 $\pm$ 5.1
Unwounded -ve control	330 $\pm$ 1.8	335 $\pm$ 9.1	337 $\pm$ 6.4

Data are represented as Mean  $\pm$  SE, No 6 rats/group; a: Significant change in comparison with undressed positive control group; b: Significant change in comparison with Ag-SD cream treated group; c: Significant change in comparison with PP (Blank) dressed group.

## Discussion

Healing is the complex and dynamic process that results in the restoration of anatomical continuity and function [19]. Cutaneous wound healing consists of a series of co-ordinated cellular and molecular events involving numerous biological processes such as cell proliferation, differentiation, migration and increase in biosynthetic activities [20]. During treatment period, the goal is to provide optimal environment for wound contraction and epithelialization through the use of medications and bandages [21].

Wound dressings form an important segment of the medical and pharmaceutical wound care marked worldwide. Creating an optimum environment to allow epithelial cells to move unimpeded, for wound treatment is the concept that modern dressings based on. These optimum conditions involve a moist environment around the wound, effective oxygen circulation to aid regenerating cells as well as tissues and a low bacterial load [2].

Nanocrystalline silver utilizes nanotechnology to release clusters of extremely small and highly reactive silver particles [22]. The smaller the particles of silver, the greater the wound surface area that will be in contact with silver, thus increasing bioactivity and silver solubility.

Dressings that can sustain release of the silver do not need to be changed so often, thereby representing a nursing management time benefit. A reduced number of dressing changes could affect positively a patient's quality of life particularly in burn management [3].

The faster reduction which are noticed in this study including incision wound length, enhanced granulation tissue formation and neovascularization together with more quick complete re-epithelialization in incisionally wounded group dressed with PP/Ag nonwoven fabric are consistent with the findings of the previous reports [13, 23] who demonstrated the added benefit of silver releasing dressing in treatment of chronic venous leg ulcers with signs of delayed healing. This suggests fast restarting of the healing process and the important role of silver dressings in

the treatment of wounds.

Silver atom ( $\text{Ag}^0$ ) is the uncharged form of metallic silver present in nanocrystalline silver. Free silver cations have a potent antimicrobial effect which destroys microorganisms immediately by blocking the cellular respiration and disrupting the function of bacterial cell membranes. This occurs when silver cations bind to tissue proteins, causing structural changes in the bacterial cell membranes which in turn cause cell death. Silver cations also bind and denature the bacterial DNA and RNA, thus inhibiting cell replication [24].

Organisms do vary in their susceptibility to silver, but there is good evidence that silver has activity against the common pathogens, *E. aureus* and *Pseudomonas spp.*, which are commonly encountered in chronic wound care [3].

Silver nanoparticles get attached to the cell membrane and also penetrate inside the bacteria. The bacterial membrane contains sulfur-containing proteins and the silver nanoparticles interact with these proteins in the cell as well as with the phosphorus containing compounds like DNA. When silver nanoparticles enter the bacterial cell it forms a low molecular weight region in the center of the bacteria to which the bacteria conglomerates thus, protecting the DNA from the silver ions. The nanoparticles preferably attack the respiratory chain, cell division finally leading to cell death. The nanoparticles release silver ions in the bacterial cells, which enhance their bactericidal activity [25]. In a porcine infected wound model, nanocrystalline silver treatments enhanced tissue regeneration while decreasing erythema and edema relative to silver nitrate ( $\text{AgNO}_3$ ) treatments [26].

The TGF- $\beta$  causes the initiation of the healing cascade by attracting macrophages and stimulates them to secrete additional cytokines including fibroblast growth factor (FGF), platelet-derived growth factor (PDGF), tumor necrosis factor-alpha (TNF- $\alpha$ ) and interleukin-1 (IL-1). In addition, TGF- $\beta$  further enhances fibroblast and smooth muscle cell chemotaxis and modulates collagen and collagenase expression. The net result of these redundant signals is a vigorous response of the matrix producing cells to ensure a rapid deposition of new connective tissue at the injury site during the proliferative phase that follows the inflammatory phase [27, 28]. TGF- $\beta$  has a three-pronged effect on extracellular matrix deposition [29]. First, it increases transcription of the genes for collagen, proteoglycans and fibronectin, thus increasing the overall production of matrix proteins. At the same time TGF- $\beta$  decreases the secretion of proteases responsible for the breakdown of the matrix and it also stimulates the protease inhibitor, tissue inhibitor of metallo-protease (TIMP) [30]. The TGF- $\beta$  has been found to be elevated in a narrow window of time after wound injury [31].

As the proliferative phase progresses, the

TGF- $\beta$  released by the platelets, macrophages and T lymphocytes becomes a critical signal. The endotoxins which are produced by bacterial infection of the wound result in elevation of cytokines which in turn adversely affect wound repair. Consequently, in response to these cytokines matrix metalloproteinases increased, and growth factors production decreased [20]. All of these changes impair wound healing. This confirms the importance of using antiseptic and anti-inflammatory dressings such as our newly synthesized polypropylene silver nanometal to promote wound healing. This dressing exerts their effects through reducing the bacterial burden and at the same time achieving moisture balance through exudates management. Also, the anti-inflammatory action of this dressing accelerates wound healing and reduced TGF- $\beta$  serum level. This explanation stems from the previous reports, which demonstrated that the treatment of murine infected burns with silver nanoparticles leads to the increased rate of healing and decreased the scarring in comparison with silver sulfadiazine. This was accompanied by increased expression of IL-10, vascular endothelial growth factor, and interferon- $\gamma$ , with reduced IL-6 expression. Nanocrystalline silver treatments were also found to increase the polymorphonuclear cell apoptosis while the matrix metalloproteinase (MMP) levels remained low, suggesting an anti-inflammatory effect [32].

Nanosilver dressing used on humans for wound management suggested that nanocrystalline silver: is cost effective, reduces wound incidence, decreases pain levels during dressing changes, decreases the frequency of dressing changes, decreases the matrix metalloproteinase activity, reduces the wound exudates and bioburden levels, and promotes wound healing in chronic wounds. There is no *in vivo* evidence to suggest that nanosilver is toxic to skin cells such as keratinocytes and fibroblasts [33].

In summary, nonwoven soft PP/Ag dressing fabrics were synthesized and characterized. The dressings were used and applied to cover incisional wounds in rats; which caused amelioration of the histopathologic and biochemical changes compared with undressed rats. Enhancement of granulation tissue formation was noticed with angiogenesis and later fibrosis. Reduction in wound area and length was observed with reduction in transforming growth factor $\beta$  (TGF- $\beta$ ). Such findings resulted in quicker, accelerated complete healing; compared to undressed rats. Re-epithelialization was complete on day 5 in PP/Ag dressed incision wound compared to day 15 in undressed group.

In conclusion, the present results suggested that the application of PP/Ag dressing to wounds enhances, promotes and plays an important role in quicker complete wound healing. It was also demonstrated the using of silver specially ionized silver in the treatment of wound adds more benefits in wound healing process., specifically ionized silver.



Our findings showed a superior performance of silver-releasing polypropylene dressing in incisional wound healing, when compared with blank PP dressing and with Ag-SD cream dressing or application due to its powerful antimicrobial and anti-inflammatory properties.

## Acknowledgements

The authors gratefully acknowledge the financial support of the USA-Egypt cooperative research of the National Science Foundation (USA contract NSF Int. 0809520) and the Egyptian Organization: Science, Technology and Development Fund (STDF), contract No 434.

## References

1. Tsala DE, Amadou D, Habtemariam S. Natural wound healing and bioactive natural products. *Phytopharmacology*. 2013; 4(3): 532-60.
2. Vanscheidt W, Lazareth I, Routkovsky-Norval C. Safety evaluation of a new ionic silver dressing in the management of chronic ulcers. *Wounds*. 2003; 15: 371-78.
3. Leaper DJ. Silver dressings: their role in wound management. *Int Wound J*. 2006; 3(4):282-94.
4. Templeton S. Management of chronic wounds: the role of silver-containing dressings. *Primary Intention*. 2005;13:170-9.
5. Woodward M. Silver dressings in wound healing: what is the evidence? *Primary Intention*. 2005;13:153-60.
6. Duran N, Marcato PD, De Souza GIH, Alves OL, Esposito E. Antibacterial effect of silver nanoparticles produced by fungal process on textile fabrics and their effluent treatment. *J Biomed Nanotechnol*. 2007;3:203-8.
7. Klasen HJ. A historical review of the use of silver in the treatment of burns. Part I early uses. *Burns*. 2000; 30:1-9.
8. Yamanaka M, Hara K, Kudo J. Bactericidal Actions of a Silver Ion Solution on *Escherichia coli*, Studied by Energy-Filtering Transmission Electron Microscopy and Proteomic Analysis. *Appl Env Microbiol*. 2005;71(11):7589-93.
9. Feng QL, Wu J, Chen GQ, Cui FZ, Kim TN, Kim JO. A mechanistic study of the antibacterial effect of silver ions on *Escherichia coli* and *Staphylococcus aureus*. *J Biomed Mater*. 2000; 52(4):662-8.
10. Gavanji S, Larki B, Mehra M. A review of Effects of Molecular mechanism of Silver Nanoparticles on Some microorganism and Eukaryotic Cells. *Tech J Engin & App Sci*. 2013; 3(1):48-58.
11. Yeo SY, Jeong SH. Preparation and Characterization of Polypropylene/Silver nanocomposite fibres. *Polymer International*. 2003; 52:1053.
12. Mooney EK. Silver dressings [safety and efficacy reports]. *Plast Reconstr Surg*. 2006; 117(2):666-669.
13. Jørgensen B, Price P, Andersen KE, Gottrup F, Bech-Thomsen N, Scanlon E, Kirsner R, Rheinen H, Roed-Petersen J, Romanelli M, Jemec G, Leaper DJ, Neumann MH, Veraart J, Coerper S, Agerslev RH, Bendz SH, Larsen JR, Sibbald RG. The silver-releasing foam dressing, Contreet Foam, promotes faster healing of critically colonised venous leg ulcers: a randomised, controlled trial. *Int Wound J*. 2005; 2(1): 64-73.
14. Kumar R, Munstedt H. Silver ion release from antimicrobial Polyamide/silver composites. *Biomaterials*. 2005; 26: 2081-88.
15. Kumar R, Munstedt H. Antimicrobial polymers from polypropylene Silver composites-Ag<sup>+</sup> release measured by anode stripping voltammetry. *Reactive and Functional Polymers*. 2006; 66: 780-88.
16. Enayat A, Omara A, Nada A, Abdel Razik H, Farrag, Walid M, Sharaf, Sayed A. El-Toumy. Therapeutic effect of *Acacia nilotica* pods extract on streptozotocin induced diabetic nephropathy in rat. *Phytomedicine*. 2012; 19: 1059-1067.
17. Drury RA, Wallington, EA. *Careton's Histological Technique*, 4<sup>th</sup> ed. Oxford University Press, 1980, Oxford.
18. Kropf J, Schurek JO, Wollner A, Gressner AM. Methodological aspects of the immunological measurement of transforming growth factor-beta (TGF- $\beta$ 1) in blood; assay development and comparison. *Clin Chem*. 1997; 43: 1965-74.
19. Boateng JS, Mathews KH, Stevens HNE, Eccleston GM. Wound healing dressings and drug delivery systems: A review. *J Pharm Sci*. 2008; 97(8): 2892-923.
20. Wall SJ, Bevan D, Thomas DW, Harding KG, Edwards DR, Murphy G. Differential Expression of Matrix Metalloproteinases during Impaired Wound Healing of the Diabetes Mouse. *J Investigative Dermatol*. 2002; 119: 91-8.
21. Gomez JH, Schumacher J, Lauten SD, Sartin EA, Hathcock TL, Swaim SF. Effects of 3 biologic dressings on healing of cutaneous wounds on the limbs of horses. *Can J Vet Res*. 2004; 68(1): 49-55.
22. Nephew S. Dynamic silver release rapid destruction, sustained protection, Acticoat with silver cryst. Smith and Nephew Pty. Ltd. Product information, 2003.
23. Sibbald RG. The silver-releasing foam dressing, Contreet Foam, Promotes faster healing of critically colonized venous leg ulcers: a randomized Controlled trial. *Int. Wound J*. 2005; 2(1): 64-73.
24. Dunn K, Edwards-Jones V. The role of Acticoat™ with nanocrystalline silver in the management of burns. *Burns*. 2004;30(Supp 1):S1-9.
25. Song, H.Y. Ko, K. K. Oh, L.H. Lee B.T. Fabrication of silver nanoparticles and their antimicrobial mechanisms. *Eur Cells Mater*. 2006; 11: 58.
26. Tian J, Wong KK, Ho CM, Lok CN, Yu WY, Che CM, Chiu JF, Tam PK. Topical delivery of silver nanoparticles promotes wound healing. *Chem Med Chem*. 2007; 2(1):129-36.
27. Hart J. Inflammation. 1: Its role in the healing of acute wounds. *J Wound Care*. 2002; 11: 205-9.
28. Sylvia C J. The role of neutrophil apoptosis in influencing tissue repair. *J Wound Care*. 2003; 12: 13-16.
29. Diegelmann RF, Evans MC. Wound healing: an overview of acute, fibrotic and delayed healing. *Front Biosci*. 2004; 9: 283-9.
30. Hall MC, Young DA, Waters JG, Rowan AD, Chantray A, Edwards DR, Clark IM. The comparative role of activator protein 1 and Smad factors in the regulation of Timp-1 and MMP-1 gene expression by transforming growth factor-beta 1. *J Biol Chem*. 2003; 278: 10304-13.
31. Wang XJ, Han G, Owens P, Siddiqui Y, Li AG. Role of TGF beta-mediated inflammation in cutaneous wound healing. *J Investig Dermatol Symp Proc*. 2006; 11: 112-17.
32. Vaidyanathan, R Kalishwaralal, K Gopalram, S Gurunathan, S. Nanosilver-The burgeoning therapeutic molecule and its green synthesis. *Biotechnology Advances*. 2009; 27: 924-937.
33. Fong J, Wood F. Nanocrystalline silver dressings in wound management: a review. *Int J Nanomedicine*. 2006; 1(4): 441-449.