

Application of the First Expert Arthrodesis Nail to a Patient with Previous Performed Arthrodesis According to Ulrich Holz – Case Report

Slavcho Stojmenski*, Dejan Dimitrovski, Igor Merdzanovski

University Clinic for Traumatology, JZU- Clinic for TOARILUC, Medical Faculty, Ss Cyril and Methodius University of Skopje, Skopje, Republic of Macedonia

Abstract

Citation: Stojmenski S, Dimitrovski D, Merdzanovski I. Application of the First Expert Arthrodesis Nail to a Patient with Previous Performed Arthrodesis According to Ulrich Holz – Case Report. *OA Maced J Med Sci.* 2014 Sep 15; 2(3):479-482. <http://dx.doi.org/10.3889/oamjms.2014.085>

Key words: Expert HAN; paralysis of peroneal nerve; pes equinus; arthrodesis of the hindfoot.

***Correspondence:** Prof. Dr. Slavcho Stojmenski. University Clinic for Traumatology, JZU- Clinic for TOARILUC, Medical Faculty, Ss Cyril and Methodius University of Skopje, Skopje, Republic of Macedonia. E-mail: stojmenski@on.net.mk

Received: 21-Apr-2014; **Revised:** 30-May-2014; **Accepted:** 01-Jun-2014; **Online first:** 03-Jul-2014

Copyright: © 2014 Stojmenski et al. This is an open access article distributed under the terms of the Creative Commons Attribution License, which permits unrestricted use, distribution, and reproduction in any medium, provided the original author and source are credited.

Competing Interests: The authors have declared that no competing interests exist.

AIM: The aim of this paper was to present application of the first expert arthrodesis nail in our clinic to a patient with previous performed arthrodesis according to Ulrich Holz.

CASE REPORT: Patients A.M. on the age of 22 (1992) have a motor vehicle injury, (fall from a motor bike) with diagnosis polytrauma, shock, supra and transcondylar open fracture of the right femur III degree, open fracture of the right tibia and fibula. We perform reposition and fixation of supra and transcondylar femoral fracture with "cobra" plate. Also we perform reposition and fixation of right cruris with external fixation. After the operation we found fistula in the place of operation of the right crural rega. During the time the infection goes worse and the patient develop osteomyelittis on the right crural rega. After 5 months with therapy the situation become calm. We remove the external fixation. The patient develops severe "pes equinus" on the right leg and he cannot walk. We try to reduce this equines situation with elongation of the Achilles tendon in the first step, and because we didn't solve the problem we continue with complete section of the Achilles tendon and after that we perform osteotomy of the right talocrural joint simultaneous to tibia plafond and talus and resection of fibula 2sm.above the syndesmosae tibiofibularis and we fixed the talocrural joint with two screws according the technique of Ulrich Holz.

CONCLUSION: So we received fixed position on of the foot on 110 degrees which was steel unacceptable for normal walking. At last we remove the screws, make once again osteotomy with positioning of the foot in maximal dorsiflexion and perform the Expert Hindfoot arthrodesis nail so with this method we achieve correction of dorsiflexion on 95 degrees, and the patient become satisfied because he can walk without support.

Introduction

Arthrodesis is an operation designed to produce bony ankylosis of a diseased joint. It often is a satisfactory solution for infection, tumors, trauma, and paralytic conditions and in certain cases of osteoarthritis and rheumatoid arthritis. Arthrodesis often results in stiffness in adjacent joints, and in the lower extremity energy requirements for ambulation usually are increased. The ability to achieve nearly normal activity levels, especially in young, vigorous patients, often outweighs these disadvantages, however. Also, it is now possible to convert hip, and

possibly knee, arthrodeses to satisfactory arthroplasties if necessary later in life.

Since Charnley introduced the concept of compression ankle arthrodesis, more than 30 techniques and countless modifications have been described.

The bony surfaces in an arthrodesis must be held securely together by internal or external fixation. In complicated situations, especially involving malposition, infection, or poor soft-tissue coverage, the external fixation device has been useful.

Arthrodesis of the ankle is performed more frequently than arthrodesis of the hip or knee. The most common indication is posttraumatic arthritis. Other indications include rheumatoid arthritis, infection, neuromuscular conditions, and salvage of failed total ankle arthroplasty. Resection arthrodesis may be indicated for treatment of bone tumors around the ankle. Ankle arthrodesis currently is being performed more frequently in patients with neuropathic arthropathy with severe deformity, but complications, especially infection and nonunion, are more common in these patients. Alvarez et al. reported successful tibiocalcaneal arthrodesis and no infections in seven ankles with nonbraceable neuropathic deformity; their technique included the use of an adolescent condylar blade plate, large cannulated AO screws, and a special cancellous allograft-antibiotic mixture.

The optimal position for ankle fusion is 0 degrees of flexion, 0 to 5 degrees of valgus, and 5 to 10 degrees of external rotation with slight posterior displacement of the talus. This position is best attained by draping the lower extremity so that the area from the toes to above the knee is accessible.

Most current techniques of ankle arthrodesis achieve fusion in 80% to 90% of patients. After arthrodesis, most patients are satisfied with the relief of pain, but most have limited hindfoot motion that makes walking on uneven surfaces difficult. Few patients are able to run effectively. The use of a rocker-bottom shoe with a solid-ankle, cushioned-heel (SACH) foot may improve gait after arthrodesis.

The bony surfaces in an arthrodesis must be held securely together by internal or external fixation. In complicated situations, especially involving malposition, infection, or poor soft-tissue coverage, the Ilizarov external fixation device has been useful.

The aim of this paper was to present application of the first expert arthrodesis nail in our clinic to a patient with previous performed arthrodesis according to Ulrich Holz.

Case presentation

Patients A.M. on the age of 22(1992) have a motor vehicle injury, (fall from a motor bike) with diagnosis polytrauma, shock, supra and transcondylar open fracture of the right femur iii degree, open fracture of the right tibia and fibula.

We perform reposition and fixation of supra and transcondylar femoral fracture with "cobra" plate. We find lesion of some vessels near the supracondylar region in first step because there was bleeding during the operation. After the intervention we perform angiography and there is a good presentation of the main vessels of the right leg. Also we perform reposition and fixation of right cruris with external fixation. After the operation we found fistula in

the place of operation of the right crural region combined with osteitis of the front side of tibia.

During the time the infection goes worse and the patient develops Osteomyelitis on the right crural region. He received antibiotics according to antibiogram and every day stripping and after 5 months with therapy the situation became calm. We removed the external fixation.

The patient develops severe pes equinus on the right leg and he cannot walk. We try to reduce this equinus situation with elongation of the Achilles tendon in the first step, and because we didn't solve the problem we continue with complete section of the Achilles tendon and after that we perform osteotomy of the right talocrural joint simultaneous to tibia plafond and talus and resection of fibula 2cm above the syndesmosis tibiofibularis and we fixed the talocrural joint with two screws according to the technique of Ulrich Holz. So we received fixed position on of the foot on 110 degrees which was still unacceptable for normal walking

At last we remove the screws, make once again osteotomy with positioning of the foot in maximal dorsiflexion and perform the Expert Hindfoot arthrodesis nail so with this method we achieve correction of dorsiflexion on 95 degrees, and the patient became satisfied because he can walk without support.

Postoperative care is essentially the same as after the compression arthrodesis. The short leg cast is changed at 2 weeks, and weight bearing is not allowed for 4 weeks.

Discussion

Intramedullary devices for tibiotalocalcaneal arthrodesis have increased the surgeon's possibilities for hindfoot stabilization [1]. Many of the patients considered for tibiotalocalcaneal arthrodesis have multiple comorbidities affecting bony stability [1]. Intracalcaneal fixation has been shown to be an important factor affecting stability [1, 2, 3]. Mann et al. concluded that the posterior-to-anterior routing of a calcaneal locking screw significantly enhances stability [2]. Muckley et al. demonstrated the superiority of angle-stable over non-angle-stable intracalcaneal locking [3]. Klos et al. found increased stability of cement augmented locking screws [4]. However, only the locking screws themselves and not the nail position, was considered for all investigations. Most nails, including the HAN have a distal lateral bend but only the A3 has an additional posterior distal bend. This feature was designed to increase the distance of the nail within the calcaneus with the intention to increase stability.

This allows the conclusion that HAN have sufficient construct stability. The HAN construct included five locking screws in total with two calcaneal

locking screws. The spiral blade as calcaneal locking option is only available for the HAN. Additionally, the nail length was 240 mm for the HAN. There is no longer nail available for the HAN. From a mechanical standpoint, a cannulated nail is weaker than a solid nail. In contrast, bending a nail does not make it weaker. In conclusion the HAN nail as such should be

weaker because of the cannulation. Still, this potential weakness did not lead to lower construct stability in the test setting. HAN is a retrograde intramedullary interlocking nail; made of the same titanium. The still present cartilage might also influence the construct stability.

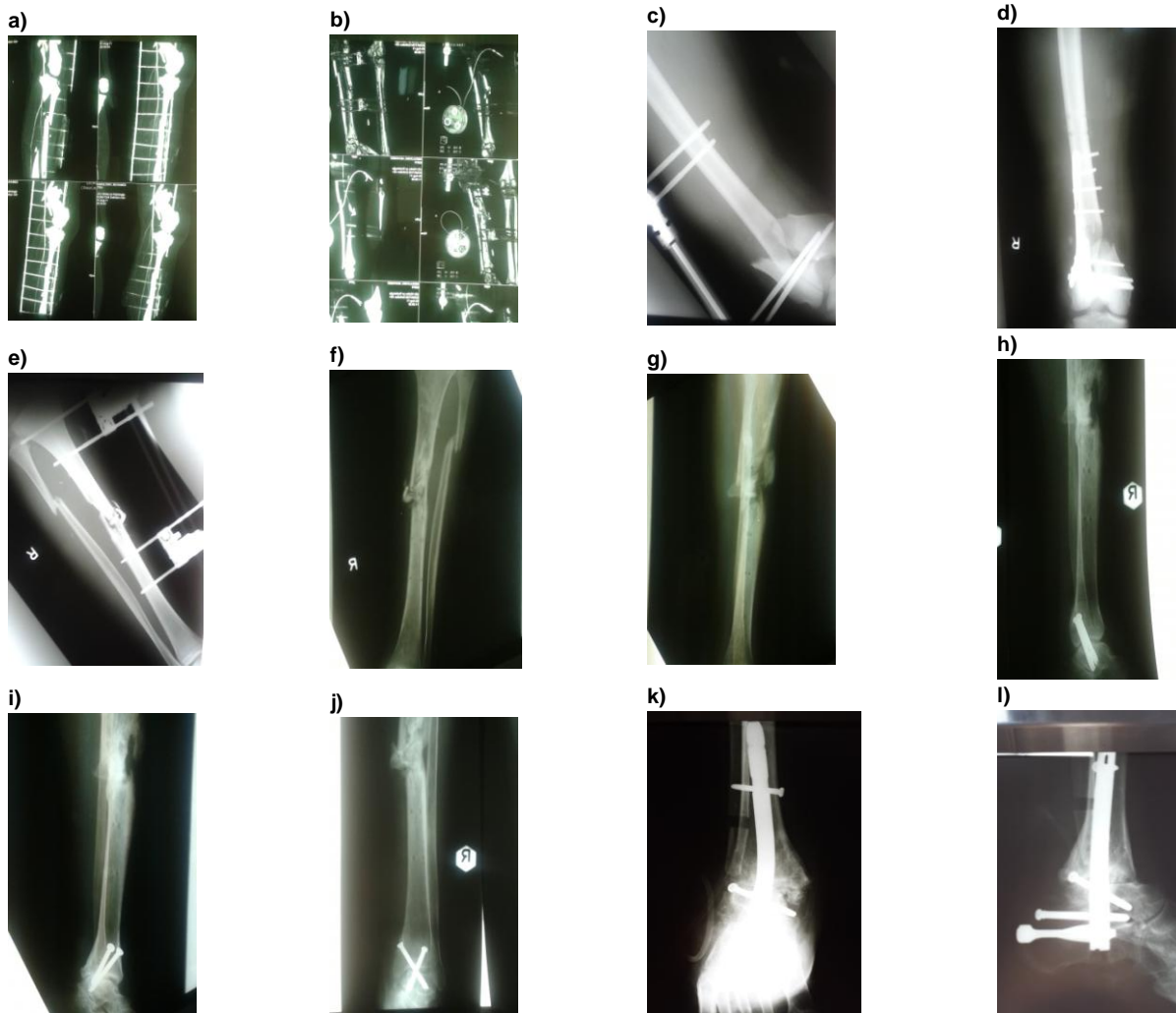


Figure 1: a) Angiography of popliteal artery on the injured place; b) Angiography of the arterial vessels of crural region; c) External temporary fixation of the fracture of supra et transcondylar femoral region (damage control); d) Conversion of external fixation to plate fixation to the supra et transcondylar femoral region; e) External fixation of the open fracture of crural region; f) AP view of crural region after removal of external fixation; g) Profile of crural region after removal of external fixation; h) Profile of Ulrich Holz Arthrodesis of talo crural joint; i) Oblique view of Ulrich Holz Arthrodesis of talo crural joint; j) AP view of Ulrich Holz Arthrodesis of talo crural joint; k) AP view of HAN arthrodesis; l) Profile view of HAN arthrodesis.

In conclusion, we can recommend this type of arthrodesis in cases with neuropathic deformity and also in cases with previous arthrodesis where the correct angle positioning of foot cannot be achieved and if the patient cannot walk without support because of the equinus position of the foot or have also a pain during weight bearing. Especially if this situation is combined with polytrauma, and if the patients are young and there is a need for fast rehabilitation but the other types of intervention cannot give optimal result and normal walking implantation of HAN combined with osteotomy and spongionasty can

be a choice of treatment. Also elongation of Achilles tendon or resection of the same can be performed previously if needed. This type of arthrodesis can be recommended for revision but also for primary arthrodesis of talocrural joint. HAN Arthrodesis can provide walking without pain and without any support. In this presented case we achieved the goal of making pain-free walking for a patient without support. We cannot compare our results with the results of other types of Arthrodesis because still we have no big series of such cases.

References

1. Klos K, Wahnert D, Gueorguiev B, Schwieger K, Hofmann GO, Windolf M, et al. Development of a technique for cement augmentation of nailed tibiototalcaneal arthrodesis constructs. *Clin Biomech (Bristol Avon)* 2010;25(6): 576–81.
2. Mann MR, Parks BG, Pak SS, Miller SD. Tibiototalcaneal arthrodesis: a biomechanical analysis of the rotational stability of the Biomet Ankle Arthrodesis Nail. *Foot Ankle Int* 2001;22(9):731–3.
3. Muckley T, Hoffmeier K, Klos K, Petrovitch A, von Oldenburg G, Hofmann GO. Angle-stable and compressed angle-stable locking for tibiototalcaneal arthrodesis with retrograde intramedullary nails. Biomechanical evaluation. *J Bone Joint Surg Am* 2008;90(3):620–7.
4. Klos K, Gueorguiev B, Schwieger K, Frober R, Brodt S, Hofmann GO, et al. Comparison of calcaneal fixation of a retrograde intramedullary nail with a fixed-angle spiral blade versus a fixed-angle screw. *Foot Ankle Int* 2009;30(12): 1212–8.
5. Berend ME, Glisson RR, Nunley JA. A biomechanical comparison of intramedullary nail and crossed lag screw fixation for tibiototalcaneal arthrodesis. *Foot Ankle Int* 1997;18(10):639–43.
6. Fleming SS, Moore TJ, Hutton WC. Biomechanical analysis of hindfoot fixation using an intramedullary rod. *J South Orthop Assoc* 1998;7(1):19–26.
7. Alfahd U, Roth SE, Stephen D, Whyne CM. Biomechanical comparison of intramedullary nail and blade plate fixation for tibiototalcaneal arthrodesis. *J Orthop Trauma* 2005;19(10):703–8.
8. Chiodo CP, Acevedo JI, Sammarco VJ, Parks BG, Boucher HR, Myerson MS, et al. Intramedullary rod fixation compared with blade-plate-and-screw fixation for tibiototalcaneal arthrodesis: a biomechanical investigation. *J Bone Joint Surg Am* 2003;85A(12):2425–8.
9. Boer R, Mader K, Pennig D, Verheyen CC. Tibiototalcaneal arthrodesis using a reamed retrograde locking nail. *Clin Orthop Relat Res* 2007;463:151–6.
10. Muckley T, Eichorn S, Hoffmeier K, von Oldenburg G, Speitling A, Hoffmann GO, et al. Biomechanical evaluation of primary stiffness of tibiototalcaneal fusion with intramedullary nails. *Foot Ankle Int* 2007;28(2):224–31.
11. Berson L, McGarvey WC, Clanton TO. Evaluation of compression in intramedullary hindfoot arthrodesis. *Foot Ankle Int* 2002;23(11):992–5.
12. Budnar VM, Hepple S, Harries WG, Livingstone JA, Winson I. Tibiototalcaneal arthrodesis with a curved, interlocking, intramedullary nail. *Foot Ankle Int* 2010;31(12):1085–92.
13. Muckley T, Klos K, Drechsel T, Beimel C, Gras F, Hofmann GO. Short-term outcome of retrograde tibiototalcaneal arthrodesis with a curved intramedullary nail. *Foot Ankle Int* 2011;32(1):47–56.
14. Wilke HJ, Wenger K, Claes L. Testing criteria for spinal implants: recommendations for the standardization of in vitro stability testing of spinal implants. *Eur Spine J* 1998;7(2):148–54.
15. Grass R. Tibiototalcaneal arthrodesis using a distally introduced femur nail (DFN). *Oper Orthop Traumatol* 2005;17(4-5):426–41.
16. O'Neill PJ, Parks BG, Walsh R, Simmons LM, Schon LC. Biomechanical analysis of screw-augmented intramedullary fixation for tibiototalcaneal arthrodesis. *Foot Ankle Int* 2007;28(7):804–9.
17. Richter M, Droste P, Goesling T, Zech S, Krettek C. Polyaxially locked plate screws increase stability of fracture fixation in an experimental model of calcaneal fracture. *J Bone Joint Surg Br* 2006;88(9):1257–63.
18. Richter M, Wippermann B, Thermann H, Schroeder G, Otte D, Troeger HD, et al. Plantar impact causing midfoot fractures result in higher forces in Chopart's joint than in the ankle joint. *J Orthop Res* 2002;20(2):222–32.
19. Richter M, Zech S, Westphal R, Klimesch Y, Gosling T. Robotic cadaver testing of a new total ankle prosthesis model (German Ankle System). *Foot Ankle Int* 2007;28(12):1276–86.
20. Noonan T, Pinzur M, Paxinos O, Havey R, Patwardhin A. Tibiototalcaneal arthrodesis with a retrograde intramedullary nail: a biomechanical analysis of the effect of nail length. *Foot Ankle Int* 2005;26(4):304–8.
21. Richter M. [Arthrodesis (with/without correction) of the ankle and subtalar joint : A3 nail fixation with triple bending and mechanical navigation.]. *Oper Orthop Traumatol*. 2013 Nov 24.