

Preoperative Evaluation of Thyroid Epithelial Lesions by DNA Ploidy and Galectin-3 Expression in FNAC

Sonia L. Elsharkawy*, Wafaa E. AbdEl-Aal, Reham S. E. Esmal, Hanan H. M. Ali, Soheir M. Mahfouz, Ahmed El-Habashi

National Research Centre – Pathology, El Behos St. Doki, Giza 046, Egypt

Abstract

Citation: Elsharkawy SL, AbdEl-Aal WE, Esmal RSE, Ali HHM, Mahfouz SM, El-Habashi A. Preoperative Evaluation of Thyroid Epithelial Lesions by DNA Ploidy and Galectin-3 Expression in FNAC. *OA Maced J Med Sci.* 2014 Dec 15; 2(4):585-594. <http://dx.doi.org/10.3889/oamjms.2014.105>

Key words: Fine needle aspiration cytology; thyroid epithelial lesions; DNA ploidy; Galectin-3; immunohistochemistry.

***Correspondence:** Prof. Sonia El-Sharkawy, National Research Center, Pathology, Dokki, Cairo 2478, Egypt. E-Mail: elsharkawy60@hotmail.com

Received: 17-Jul-2014; **Revised:** 12-Oct-2014; **Accepted:** 31-Oct-2014; **Online first:** 17-Nov-2014

Copyright: © 2014 Sonia L. Elsharkawy, Wafaa E. AbdEl-Aal, Reham S.E. Esmal, Hanan H.M. Ali, Soheir M. Mahfouz, Ahmed El-Habashi. This is an open access article distributed under the terms of the Creative Commons Attribution License, which permits unrestricted use, distribution, and reproduction in any medium, provided the original author and source are credited.

Competing Interests: The authors have declared that no competing interests exist.

AIM: This study aimed to investigate the value of DNA ploidy and galectins-3 immunostain in the preoperative evaluation of thyroid epithelial lesions.

MATERIAL AND METHODS: Sixty patients presenting with thyroid enlargement were included in this study and referred by clinicians for FNA. Routine cytological evaluation was done on PAP stained slides according to the WHO criteria and at least three slides were prepared for routine cytological examinations. The nuclear DNA analysis was performed at the Pathology Department, National Research Center using the Leica Qwin 500 Image Analyzer (LEICA Imaging Systems Ltd, Cambridge, England). Galectin-3 expression was investigated in all tissues using streptavidin-biotin technique.

RESULTS: Conventional Fine needle aspiration cytology (FNAC) of 60 cases could diagnose malignancy with a sensitivity of 60%, negative predictive value (NPV) 71.4%, and overall diagnostic accuracy of 80%. The aneuploidy was significantly associated with malignancy, with sensitivity 90.9%, specificity 83.3% and accuracy 88.3%. On using galectin-3 immunocytochemical stain on cell blocks prepared from FNA the values were improved, sensitivity 93.3% specificity 86.7% and overall accuracy 90% and it was noticed that galectin-3 over expression was significantly associated with malignancy.

CONCLUSIONS: From the results of this study we can consider that DNA ploidy and Galectin-3 could refine the FNA results and increase its sensitivity as a screening test from sensitivity(60%) to reach sensitivity (93.3%), thus decreasing the false negative cases. From this study, it is concluded that the application of ancillary techniques as galectin-3 immunocytochemical markers may become a reliable indicator for surgical intervention, DNA ploidy measurements on the other hand may be of value in galectin-3 negative cases to determine the behavior of the lesion in such cases & refine the preoperative assessment by out ruling false negative cases.

Introduction

Thyroid gland disease is one of the most common endocrine diseases. The incidence may vary considerably; and in endemic goiter areas, the thyroid nodules may be as high as 25% or more. In non-iodine –deficient areas, 4% to 7% of the population has thyroid [1]. Prophylactic operations for all thyroid nodules seems unreasonable and is not cost-effective, as four of five nodules are benign. Refraining from surgery can be done safely only when the risk to postpone removal of malignant disease is low [2]. Thus the need for reliable preoperative diagnosis is great.

Fine needle aspiration cytology (FNAC) has

emerged as a valuable, popular and routine investigation that can differentiate between benign and malignant thyroid nodules, with no or minimal complications [3]. However, the diagnostic efficacy of FNA declines sharply in the diagnosis of follicular patterned lesions of thyroid and up to 30% of patients with nodular thyroid disease will receive a FNA report that reads “follicular lesions” or “suspicious”. Most of these patients will require surgical management, and the extent of resection will need to be planned without a preoperative diagnosis of malignancy [4].

It has been shown that the malignancy rate in cases diagnosed as follicular lesions can be up to 20%. This high rate of benign lesions undergoing surgery is because FNA cannot differentiate between follicular adenoma and well-differentiated carcinoma

based on cyto-morphology. This distinction is made only by demonstration of capsular and vascular invasion upon histopathologic examination [5].

All this leads to low frequency of thyroid carcinoma recognition at early stages and necessitates the development and adoption of new, more sensitive methods for oncologic diagnosis. To date, no effective method has been established to identify malignant follicular tumors of the thyroid preoperatively.

Many studies suggested that DNA ploidy studies may be a helpful scientific tool in identification of neoplastic epithelial follicular cells, as DNA euploidy excludes the presence of neither malignancy nor neoplasia [6, 7]. Furthermore, many studies have also demonstrated that nuclear DNA content and ploidy assessment may be a prognostic factor for patients of thyroid carcinomas [8].

Recent advances in molecular diagnostics, such as immunocytochemistry and enzyme activity assays, allowed a further analysis of FNA material in an attempt to differentiate benign from malignant thyroid nodules [9]. Several molecules involved in carcinogenic processes have been proposed as markers of thyroid malignancy [10, 11].

Galectin-3 (GAL-3) seems to be one of the most promising molecules in increasing thyroid FNAC accuracy [12, 13]. As reported in several studies this lectin is expressed in thyroid carcinoma but not in normal thyrocytes and in benign lesions such as follicular adenomas [14]. In particular, many studies reported that cytoplasmic GAL-3, selectively expressed in malignant thyroid cells, is easily detectable also on FNA cytologic samples [12, 15].

The aim of this work is to evaluate the complementary diagnostic role of DNA image analysis and immunocytochemistry study using Gal-3 as diagnostic adjuvant to thyroid fine needle aspiration cytology, aiming to improve the preoperative assessment of the potential biological behavior of follicular lesions.

Material and Methods

Sixty patients presenting with thyroid enlargement were included in this study and referred by clinicians for FNA (to Cytology unit of Kasr Al-Aini Hospital- Pathology Department, and the Cytology unit in National Cancer Institute as well as several private labs). Consents were obtained from all cases according to the formula documented from the ethical committee in the *National Research Center*. Ethical approvals were obtained from the Medical Ethical Committee of National Research Center (NRC), and

Kasr Al-Aini Research Ethical Committee (REC).

Routine cytological evaluation was done on PAP stained slides according to the WHO criteria [16] and at least three slides were prepared for routine cytological examinations.

For cell blocks preparation, the correct amounts of 10% buffered formalin was used for fixating the remainder of the aspirated material and then centrifuged. The formed pellet was then paraffin embedded [14]. One formalin fixed paraffin-embedded section was prepared for H&E staining and reviewed for adequacy for further Feulgen and immunostaining which are performed on adequate samples.

Another two paraffin sections were cut at 4 micron thicknesses. One section was placed on electrocharged "plus" slides, which allows strong adhesion for tissues and minimizes tissue detachment during antigen retrieval in immunocytochemical procedures. The second was placed on ordinary slide for Feulgen staining and DNA study.

DNA content analysis

The *Feulgen* staining reaction specifically stains the DNA to give specific staining of the nuclear DNA. Nucleoli and cytoplasm should show no staining. The nuclear DNA analysis was performed at the Pathology Department, National Research Center using the Leica Qwin 500 Image Analyzer (LEICA Imaging Systems Ltd, Cambridge, England.)

Distorted or overlapping nuclei and nuclear fragments were manually eliminated from measurement. All these facilities were supplied as editing function in the Leica Qwin 500 image analysis systems.

The optical density of the selected nuclei in each microscopic field is then measured and automatically converted by the system into DNA content. Many fields were selected until the desired number of nuclei (100 – 150) had been measured.

The results were displayed as a frequency histogram on the monitor generated by plotting the DNA content versus the number of nuclei counted. Then scaling of the data was automatically performed by the system for optimal resolution, interpretation, and statistical assessment. All nuclear populations present in a tumor were represented in the histogram.

The DNA histograms were classified according to Danque et al. [17] as diploid, tetraploid and aneuploid based on the amount of DNA relative to the normal control. The diploid position (2c) for the study population was determined after calibration of the system.

DNA histograms obtained by image analysis are classified as follows:

Diploid type, when a single peak is found in

the diploid or near diploid region, and fewer than 20% of the cells are present at the tetraploid position.

Tetraploid type, when there is a peak in the diploid region and a second peak with more than 20% of the cells in the tetraploid region. *Aneuploid type*, when at least 10% of the total events show a distinct abnormal peak outside the 2C or 4C position.

Both the diploid and the tetraploid patterns were grouped together as (non –aneuploidy), so results displayed as aneuploid and non aneuploid [8, 18].

Immunocytochemical methods

Galectin-3 expression was investigated in all tissues using streptavidin-biotin technique. Four-um thick sections were deparaffinized, hydrated and incubated in 3% hydrogen peroxide for 30 minutes to block the internal peroxidase activity. Antigen retrieval was done by microwave pretreatment for 10 minutes in 0.01M citrate buffer. The slides were incubated at 4°C overnight with mouse monoclonal anti- Galectin-3 antibody (THERMO SCIENTIFIC. Cat. No. MS- 1756-S0(0.1)). These steps were followed by a 30- minutes incubation with biotinylated horse anti-mouse antibody at room temperature, then avidin-biotin peroxidase complex for 60 minutes at room temperature and finally diaminobenzidine (DAB) for 3-5 minutes. The slides were counterstained with hematoxylin, dehydrated and mounted.

Positive control

Sections from small intestine were prepared and stained. Positive cytoplasmic staining was demonstrated in the epithelial cells [14].

Negative control

Sections of the same tissues which were used as positive control are processed in the same immunostaining procedure but the negative control serum was used instead of the primary antibody.

Scoring of the immunocytochemistry

Immunostaining were evaluated blindly without knowledge of the previously established histological diagnosis. Galectin -3 stained slides immunostains were considered positive if definitive cytoplasmic staining -with or without nuclear staining- was detected (the macrophages and stromal cells used as a positive internal control being positive).

Galectin-3 immunostaining was graded using the following semi-quantitative scale: (-) no reactivity, +/- focal reactivity (<10% of the neoplastic cells), + moderate reactivity (10-50% of the neoplastic cells)

and ++ diffuse positivity (>50% of the neoplastic cells) [14].

Statistical analysis

Data were statistically described in terms of range, mean, standard deviation (\pm SD), median, frequencies (number of cases) and relative frequencies (percentages) when appropriate.

Comparison of the study variables between benign and malignant cases in the present study was done using Mann Whitney *U* test for independent samples. Comparison of the study variables between all pathological types in the present study was done using Kruskal Wallis analysis of variance (ANOVA) test with posthoc multiple 2-group comparisons.

Accuracy was represented using the terms sensitivity, specificity, positive predictive value, negative predictive value, and overall accuracy..

A probability value (*p* value) less than 0.05 was considered statistically significant. All statistical calculations were done using computer programs Microsoft Excel version 7 (Microsoft Corporation, NY, and USA) and SPSS (Statistical Package for the Social Science; SPSS Inc., Chicago, IL, USA) statistical program.

Results

The present study included 60 FNA biopsies of different epithelial follicular lesions, divided according to the final histopathological diagnosis (post thyroidectomy) into: 16 cases of nodular goitre, 14 cases of follicular adenoma, 18 cases of papillary carcinoma, and 12 cases of follicular carcinoma.

Clinically, thyroid enlargement was the main presenting symptom for the patients. In all patients of multinodular goitre, the thyroid enlargement was asymmetrical with a lobulated nodular surface on palpation. The same clinical findings were also seen in 3 patients of follicular adenoma, while rest of the adenoma cases [11] presented as solitary thyroid nodules.

Three patients with papillary carcinoma had asymmetrical enlargement with nodular surface, and the rest [15] presented as single nodules. All included cases of follicular carcinoma presented clinically as solitary thyroid nodules. Single nodularity was significantly associated with neoplasia ($P = 0.00231$), and with malignancy ($P = 0.00341$).

By FNAC 17 cases were benign, 25 were diagnosed as Follicular neoplasm, two were suspicious of malignancy (intermediate) and 16 were malignant (Table 1).

Table 1: Cytologic diagnosis of the cases.

Diagnostic category	No. of cases	%
Benign	17	28.3%
Follicular neoplasm	25	41.7%
Suspicious	2	3.3%
Malignant	16	26.7%
Total	60	100 %

Conventional FNAC was found to predict benignity in 87.5% of MNG cases, but only in 21.4% of adenoma cases. Rest of adenoma cases and all the FTC cases were placed in the indeterminate group of “follicular neoplasm”.

Table 2: Results of FNA compared to histopathological diagnoses.

Pathology	Cytology				Total
	Benign	Follicular Neoplasm	Suspicious for malignancy	Malignant	
MNG	14	2	0	0	16
FA	3	11	0	0	14
Benign groups	17	13	0	0	30
PTC	0	0	2	16	18
FTC	0	12	0	0	12
Malignant groups	0	12	2	16	30
Total	17	25	2	16	60

Of the indeterminate cytology group “follicular neoplasm” 48% proved histologically to be follicular carcinomas.

As expected, FNAC diagnosed (or at least suspected) malignancy in all cases of papillary carcinomas, with no false positive cases (specificity 100%) (Table 2).

Conventional FNAC could diagnose malignancy with sensitivity of 60%, negative predictive value(NPV) 71.4%, specificity and positive predictive value(PPV) 100%(no false positive cases),and overall diagnostic accuracy of 80%.

DNA ploidy in studied groups

The Leica Qwin 500 image analyzer automatically expresses the DNA content of each individual cell selected and gives the percentage of each cell class out of the total number of cells examined (100-110 cells per case). DNA content of 2C is diploid while, DNA content of 4.5C or more indicates aneuploidy.

Table 3: DNA distribution in different studied groups.

Studied groups	No	DNA ploidy distribution	
		Diploid No. (%)	Aneuploid No. (%)
MNG	16	9 (56.3)*	2 (12.5)
FA	14	10 (71.4)	4 (28.6)
FTC	12	2 (16.7)	10 (84.3)
PTC	18	2 (11.1)	16 (88.9)
Total	60	23 (38.3)	32 (35.3)

*: 5 cases MNG were hypoploid.

Of the total malignant cases; aneuploidy was found in 86.7%of cases with 13.3% of malignant cases showed diploid pattern.

DNA aneuploidy was significantly associated with malignancy ($p = 0.00074$), with sensitivity 90.9% and specificity 83.33% and overall diagnostic accuracy 88.29% in identifying malignancy from thyroid aspirate.

Within the benign cases; two cases out of 16 cases of nodular goitre showed aneuploidy (12.5%), 9 cases (56.3 %) were diploid and the remaining 5 cases were hypoploid. Four adenoma cases were aneuploidy (28.6%), while rest of follicular adenoma cases were diploid (71.4%)

Significant differences were observed between follicular adenoma and follicular carcinoma ($p = 0.000337$), and between papillary carcinoma and MNG ($P = 0.0024$).

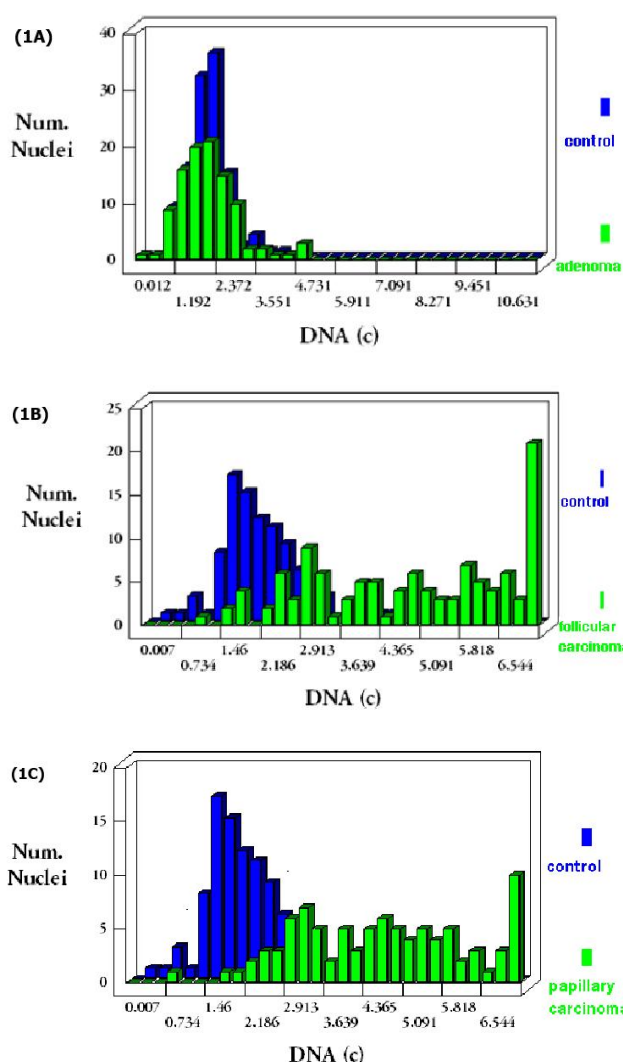


Figure 1: Histogram comparing DNA content in 1-A: follicular adenoma versus the control, cells had one peak at 2C region (diploid); 1-B: follicular carcinoma case versus the control, most of cells contained DNA content above 2C (aneuploidy); 1-C: in papillary carcinoma versus the control; most of cells contained DNA content >4.5, with peak outside the diploid and tetraploid areas (aneuploid).

Galectin-3 immunohistochemical expression

Immunocytological analysis of Galectin-3 in cases of MNG, showed absent cytoplasmic expression in 15 cases out of the included 16 cases, and only one case showed moderate reactivity (10-50% of cells).

Cases of follicular adenoma showed absent cytoplasmic expression in 11 cases, two cases showed focal positivity (< 10%), and one case was moderately positive (10-50%). The three of the aforementioned positive cases were histologically cellular microfollicular adenomas.

All the cases of papillary carcinoma showed diffuse reactivity to the Galectin-3 (> 50% of neoplastic cells), while 8 cases of follicular carcinoma were diffusely positive, two cases were moderately positive, and two cases were completely negative.

The nuclear staining in the absence of the cytoplasmic staining was considered non specific and negative. Inflammatory cells, endothelial cells and stromal cells expressed Galectin-3 in all cases (internal positive control).

Overall, Galectins-3 over-expression (moderate or diffuse positivity) was remarkably associated with malignant results; as it was found in 28/30 malignant cases, while only 2/30 benign cases (one MNG and one follicular adenoma), showed moderate Galectin-3 positivity, and the difference was statistically significant ($p = 0.0021$).

The results of Gal-3 and DNA ploidy in cases of "follicular neoplasm" group

This group constituted 25 of the studied cases (41.7%). The conventional FNA can not go further than this diagnostic terminology, Referring to the gold standard histopathologic diagnoses, it was noted that:

1. Immunocytochemical staining by Gal-3 could screen malignancy within this indeterminate group with sensitivity 83.3%, specificity 84.6%, and 84% diagnostic accuracy.
2. DNA ploidy could diagnose malignancy within this group with sensitivity 83.3%, specificity 76.9%, and 80% diagnostic accuracy.

The results of the different studied techniques versus the results of the conventional FNA

Overall, the ancillary techniques used in the study (Galectin-3 and DNA ploidy) could refine the FNA results and increase its sensitivity as a screening test from sensitivity (60%) to reach sensitivity (93.3%), thus decreasing the false negative cases (Figure 2). The assessment of the proliferative activity by PI can suggest the lesion behaviour and support the FNA and other studies results (Table 6).

Table 4: Galectin-3 scoring in the studied groups.

Studied groups	No.	Galectin-3 scoring			
		-	-/+	+	++
		Absent 0%	Focal <10%	Moderate 10-50%	Diffuse >50%
		No. (%)	No. (%)	No. (%)	No. (%)
MNG	16	15 (93.8)	0 (0)	1 (6.2)	0 (0)
FA	14	11 (71.4)	2 (14.3)	1 (14.3)	0 (0)
PTC	18	0 (0)	0 (0)	0 (0)	18 (100)
FC	12	2 (16.6)	0 (0)	2 (16.6)	8 (66.7)
Total	60	28 (43.3)	2 (5)	4 (8.3)	26 (33.3)

The total galectins-3 positivity percentage was 93.3% in malignant cases in comparison to non-malignant cases (13.3%) and the difference was highly statistically significant ($p = <0.0023$).

PTC cases showed optimum positivity percentage (100%), compared with (83.3%) positivity percentage in FTC cases.

According to these results, galectins-3 could predict malignant outcome in 28 out of 30 cases of the malignant cases included in the study, with sensitivity 93.3%, specificity 86.7%, positive predictive value 87.5%, and negative predictive value 92.9%. The overall accuracy was 90%.

Table 5: Expression of Galectin-3 in the studied groups.

Studied groups	No.	Galectin-3 expression	
		Negative No. (%)	Positive No. (%)
Benign Lesions			
MNG	16	15 (93.8)	1 (6.2)
FA	14	11 (71.4)	3 (28.6)
Total	30	26 (86.7)	4 (13.3)
Malignant Lesions			
PTC	18	0 (0)	18 (100)
FC	12	2 (16.6)	10 (83.3)
Total	30	2 (16.6)	28 (93.3)
Total	60	28 (48.3)	32 (51.7)

Table 6: Compared efficacy of different studied techniques.

Studied Technique	Sensitivity	Specificity	Diagnostic accuracy
FNAC	60%	100%	80%
Gal-3	93.3%	86.7%	90%
DNA Ploidy	90%	83.3%	88.3%

Discussion

During the last years, confidence in fine needle aspiration cytology (FNAC) has grown considerably and cytology has been widely accepted as an initial step in thyroid nodules management. By the routine use of FNAC in thyroid nodules assessment, fewer patients were subjected to surgical treatment for benign diseases and the rate of thyroid surgery was cut in half, which resulted in substantial savings in health care expenditures [19].

However, although the fact that FNA is the most accurate, cost-effective and specific test adopted for pre-surgical evaluation of thyroid nodules,

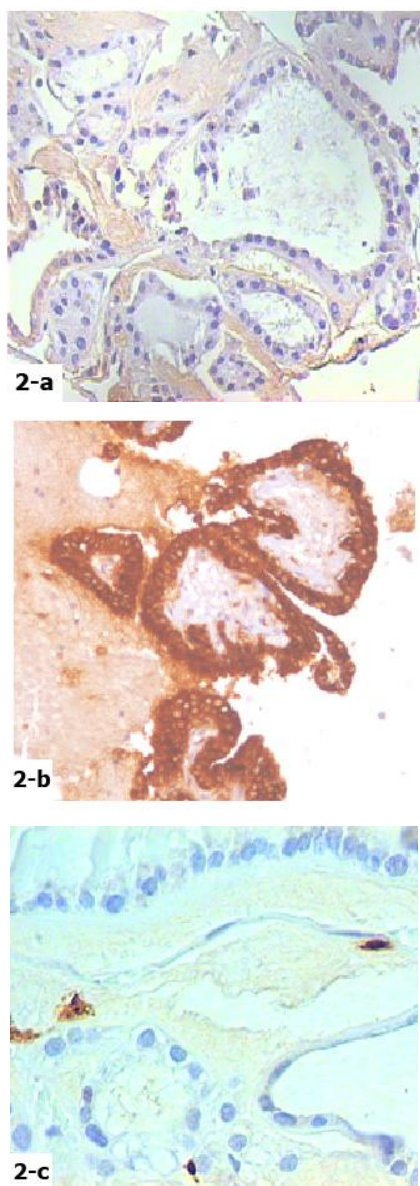


Figure 2: Cell block stained with galectins-3 of: 2-a: Follicular adenoma showing negatively stained follicular cells, some stromal cells stained positive as internal positive control (galectin-3 x 400). 2-b: Follicular carcinoma showing diffuse cytoplasmic positivity (> 50% of cells) (galectin-3 x 200). 2-c: papillary carcinoma with focal strong cytoplasmic staining, (galectin-3 x 200).

up to 30% of patients with nodular thyroid disease will receive a FNA report that reads “follicular lesions” or “follicular neoplasm” [20]. This indeterminate category is the major limitation of the technique and the most problematic in terms of risk assessment and patient counseling, with the malignancy found in about 10-20% of these nodules. Due to this high incidence of malignancy, most patients with thyroid nodules of indeterminate cytology are referred for surgical resection [21] usually in the form of diagnostic hemithyroidectomy. Moreover, those with proved carcinoma will then require a second-stage completion thyroidectomy with or without neck dissection and post operative iodine [22]. In contrast,

when the cytological report could clearly exclude malignancy, most surgeons choose to observe, unless associated with compression symptoms [23].

Thus, to overcome this well known limitation and to improve the diagnostic yield of FNAC, many modern techniques have been introduced and applied to thyroid cytology smears. These techniques include; morphometric studies, immunocytochemical studies, DNA ploidy analysis, PCR, cytogenetics, and even electron microscopic examinations [24, 25].

The aim of the current study is to evaluate whether DNA ploidy and Galactin-3 expression could help in solving the diagnostic dilemma of indeterminate cytology, either alone or in combination, thereby improving the selection criteria for cases referred for surgery and aiming at avoiding unnecessary surgical interventions.

In the present study 60 Samples were obtained prospectively from patients presenting with thyroid enlargement and referred by clinicians for FNA to the Cytology unit of Kasr Al-Aini Hospital-Pathology Department and the Cytology unit at the National Cancer Institute (NCI) as well as several private labs.

The 60 cases of thyroid epithelial lesions were categorized according to the post surgical histopathologic diagnoses as: nodular goiter (16 cases), follicular adenoma (14 cases), papillary carcinoma (18 cases), and follicular carcinoma (12 cases), with 50% of cases were benign and 50% were malignant.

A solitary thyroid nodule was the main presenting symptom in 78.6% of adenoma cases, 83.3% of papillary carcinoma cases and in all cases of follicular carcinoma. Thus, the presence of a single nodule clinically (or sonographically) was significantly associated with neoplasia and malignancy. The same findings were also mentioned by Raba et al. [26] and Giles et al. [27]. Rago et al. [28] and Lubiz et al. [29] also recorded the same finding and recommended “single nodularity” as a risk factor for thyroid malignancy.

Although Peadamallu & Peadamallu [30], and Tuille et al. [31] made the same observation, they also pointed to the percentage of malignant cases in clinically nodular enlargement, and recommended that the risk of thyroid neoplasia and malignancy in this setting not to be underestimated, and that nodular thyroid enlargement should be subjected to FNA to exclude neoplasia and malignancy especially in the presence of risk factors, family history, dominant nodules or sonographically suspicious nodules.

According to the present study results, the conventional cytological examination could perfectly diagnose (or suspect) cases of papillary carcinoma with no false positive results. Esmaili and Taghipour [32] got similar results with no false positive cases

(specificity 100%). Like wise, Siddiqui et al. [33] stated that missed diagnosis of PTC on FNA may occur only because of inadequate tumor sampling due to the heterogeneity of the nodule targeted for FNA. Flanagan et al. [34], also reported similar results and concluded that false positive reports do not constitute a major problem in thyroid FNAC for papillary cancer.

However this was not the case in other groups where conventional FNAC could predict benignity in 87.5% of MNG cases, and only in 21.4% of adenoma cases. The rest of the adenoma and MNG cases as well as all the FTC cases were placed in the indeterminate group of "follicular neoplasm", 48% of these cases proved histologically to be follicular carcinoma.

Ogilvie et al. [4], Rosaria et al. [35] and Faquin [36] agreed that the cytological diagnosis of follicular neoplasms are indeterminate and form a grey zone in thyroid FNA cytology, requiring further characterization by demonstration of capsular and/or vascular invasion upon histological examination.

According to our results and analysis, the overall diagnostic accuracy of conventional FNA was 80%. Thapa et al. [3] and Yang et al. [37] recoded an accuracy rate above 90% for conventional FNA.

Although Haugan et al. [38], Cochand-priollet et al. [39] and Hayashi & Kitaoka [40] have documented the excellent overall diagnostic accuracy of thyroid FNA; they suggested the use of additional ancillary techniques as a way to improve the indeterminate or suspicious results that pose diagnostic and management dilemma.

In the present study, DNA ploidy measurement by image analysis, and immunocytochemical staining for Galectin-3 were evaluated for their role in improving the diagnostic accuracy of thyroid FNAC.

The first ancillary test evaluated in the study was DNA ploidy assessment by image analysis system. Study of cases was done using Leica Qwin500 image analyzer. DNA content of 4.5 or more indicates aneuploidy, the case is considered aneuploid when at least 10% of the total events show distinct abnormal peak outside the 2c (diploid) or 4c (tetraploid) positions. Both the diploid and the tetraploid patterns were grouped together as (non – aneuploidy), so results displayed as aneuploid and non aneuploid [18, 19].

In the current study, aneuploidy was significantly associated with malignancy; highest mean value was noticed in papillary carcinoma. In papillary carcinoma 88.9% of cases in this study showed aneuploidy and only two cases (11.1%) were non-aneuploid. In follicular carcinoma 83.3% of cases were aneuploid and also two cases (16.7%) were non-aneuploid. In the benign cases, aneuploidy was seen in 2 cases of nodular goiter and in 4 cases of follicular adenoma. 31.3% of nodular goiter cases were hypoploid (most of cells less than 2C), rest of both

groups cases were diploid. Aneuploidy was seen in 86.7% of malignant cases but only in 20% of benign cases with sensitivity 90.9%, specificity 83.3% and accuracy 88.3% in identifying malignancy in thyroid aspirate.

Similar results were recorded by Frasoldati et al. [41] and Bakr et al. [42] and they concluded that aneuploidy was significantly more frequent in malignant cases. However, they also observed that aneuploidy was not exclusive of malignancy; aneuploid follicular adenomas exist and they may represent cases undergoing malignant transformation. Nadjari et al. [43] got a higher sensitivity in using image analysis (100%), and none of the benign cases included in that study showed aneuploidy. Sturgis et al. [19] studied aneuploidy in papillary carcinoma cases and they proved a strong association between aggressive DNA pattern (aneuploidy) and both distant metastasis and death from the disease, and linked the non aggressive (non-aneuploid) results in papillary carcinoma with a better prognosis. Orell et al. [44] also suggested that aneuploid papillary carcinoma have a higher rate of recurrence, morbidity and mortality than non-aneuploid ones.

Francis et al. [45] explained the aneuploid nodular goitre cases by the possible development of chromosomal aberrations and/or the selection of cellular clones with high growth potential. Konarska et al. [46] recorded the presence of nodular goitre cases with hypoploid DNA pattern; however they did not suggest an explanation. In our study, we suppose that these hypoploid cases may represent degenerative changes and cystifications, which are common in nodular goitre.

Onaran et al. [18], Camargo et al. [47] and Missaoui et al. [48] claimed a strict correlation between aneuploid DNA content in thyroid cells and tumor stage and behavior and they concluded that DNA measurement in FNA may be a useful adjunct method in thyroid lesion analysis, and may influence the extent of surgery as well as prognosis evaluation. On the other hand, some authors were less optimistic. Konarska et al. [46] and Lewinski [49] suggested that aneuploidy was a common feature in histopathological benign thyroid lesions, and they concluded that aneuploid was not found specific to any type of thyroid lesions and therefore could not be of clinical value in diagnosing malignancy from FNA. In 2005, Cusick et al. [50] noticed that DNA aneuploid benign and malignant thyroid lesions appeared to give parallel results, so they suggested cell cycle analysis to help in distinguishing benign from malignant thyroid lesions.

The present study results were in concordance with Frasoldati et al. [41] and Konarska et al. [46] who provided significantly higher mean PI in carcinomas than in benign lesions, and stated that PI values were independent of DNA ploidy level. Galectin-3 is a component of soluble beta-galactoside

binding lectins, which is up-regulated in thyroid carcinoma, while its expression in normal and benign thyroid tissue is absent or weak. In many studies, galectin-3 had been reported to be very sensitive and reliable marker for the preoperative identification of thyroid carcinoma with high sensitivity and specificity in cytological cell blocks and routine cytological samples [15].

According to our results, Galectins -3 over-expression was significantly associated with malignancy as it was strongly expressed (moderate or diffuse positivity) in 28/30 malignant cases, compared to 2/30 benign cases. Pennelli et al. [51] and Chiu et al. [52] agreed that Galectin-3 over-expression (moderate and diffuse scoring) was a good predictor for thyroid cancer and an unequivocal indication for surgery. Nearly similar values of sensitivity, specificity and accuracy were also reached by Saggiorato et al. [14], Bartolazzi et al. [15] and Aiad et al. [53], all suggested that the routine correct use of galectin-3 can increase the diagnostic accuracy of conventional cytology especially in the indeterminate group, hence improve the management of thyroid nodules and reduce unnecessary thyroid surgeries.

On the other hand, Aron et al. [12] and Kim et al. [13] disagreed with these results and both pointed to the poor specificity of galectins-3 because of its reactivity in some benign cases (false positive cases). Mehrotra et al. [22] and Oestreicher-Kedem et al. [54] also have found that galectin-3 is not a sensitive indicator of thyroid cancer because of the possibility of false negative cases.

In this study, all papillary carcinoma cases showed diffuse expression of Galectin-3, the finding which was also highlighted by Haugen et al. [38] and Pennelli et al. [51], and was explained by Yoshii et al. [55] as the expression of Galectin-3 appears to be necessary for the maintenance of transformed thyroid papillary cancer cell line in vitro. Papotti et al. [56] agreed also with this finding and put great emphasis on the role of Galectin-3 in differentiating between cystic papillary carcinoma and benign thyroid cysts.

In the present study, 83.4% of follicular carcinoma cases were positive for Galectin-3, while 16.6% showed a negative reaction. Pennelli et al. [51] got near results and concluded that Galectin-3 cytostest was less informative in follicular carcinoma than in papillary carcinoma. Saggiorato et al. [14] applied the Galectin-3 on the cytological samples and their post-operative specimen and noticed that the negative follicular carcinoma cases by immunocytochemistry were related to minimally invasive tumors. Bartolazzi et al. [15] have hypothesized that these false negative cases may be due to technical failure or probably because of additional molecular alterations that affect *LGALS3* gene transcription, and they suggested the possibility of further study. Herrman et al. [57] supposed that a sampling error occurred in the FNAB technique, or

that a technical error occurred in the fixation procedure. Considering that galectin-3 may show focal expression, Bartolazzi et al. [15] hypothesized that FNA sampled areas where those that did not express the molecule, and they suggested the use of large needle aspiration cytology to ensure better material sufficient for cell block preparation and fair immunostaining evaluation.

In the benign group, Galectin-3 showed moderate positivity in a case of MNG and a case of follicular adenoma, two cases of follicular adenoma showed focal positivity, while the rest of cases in both categories were negative for Galectin-3. We found that the three positive cases of follicular adenoma were histologically of microfollicular variant. Saleh et al. [58] explained the presence of some positive MNG cases were due to macrophages positively staining with Galectin - 3, and this may obscure the follicular cells mainly in the presence of cystification. Therefore, positivity of follicular cells in these cases may be false due to carry-over of the associated abundant macrophages. They studied Galectin-3 on histological sections and also observed that the MNG positivity in some case were related to cystified or inflamed areas and hypothesized that expression of non-neoplastic follicular cells in inflamed areas may result from cytokines secreted by the inflammatory cells or simple permeation of galectin-3 abundantly shed by lymphocytes in the neighboring follicular cells. Therefore, they suggested that Galectin-3 results have to be evaluated in conjunction with other features.

Martins et al. [59] applied Galectin-3 on histological sections and noticed that in false positive cases of follicular adenomas the expression of galectin-3 is restricted to follicular cells bordering the connective capsule, suggesting it might be related to malignant transformation and malignant progression. The same suggestion was made by Aiad et al. [53], when they applied Galectin-3 to both cytological preparations and their post operative histological sections. None of these studies commented on the adenoma variant in positive cases.

The presence of false positive cases was also noticed by Collet et al. [60], they suggested that these benign lesions (MNG and adenomas) present foci of clonal expansion, suggesting a stage in the multistep evolution of goiters and adenomas to carcinoma, and they concluded that, adenomas with positive expression for galectin-3 could be considered potential early cancer, and hence require therapeutic surgical intervention.. The same recommendations were also made by Saggiorato et al. [14] and Bartolazzi et al. [15] and Lubiz et al. [29] they also suggested that a new possibility of early detection of thyroid cancer can be accomplished by Galectin-3 immunostaining method, and they recommended further work to ensure the accuracy of this suggestion.

In all studied cases, the ancillary techniques

used in the study (Galectin-3 and DNA ploidy) could refine the FNA results and increase its sensitivity as a screening test from sensitivity (60%) to reach sensitivity (93.3%) and (90%) respectively, thus decreasing the false negative cases.

However, in the present work, we had 25 cases which were placed in the indeterminate grey zone of "follicular neoplasm" by the conventional cytological evaluation. Focusing on these cases, Galectin-3 could screen malignancy with sensitivity of 83.3%, specificity 84.6%, and 84% diagnostic accuracy. DNA ploidy could predict malignancy within this group with sensitivity 83.3%, specificity 76.9%, and 80% diagnostic accuracy.

The utility of Galectin-3 in indeterminate thyroid cytology was supported by Saggiorato et al. [14], and Bartolazzi et al. [15], they suggest the use of galectin-3 in the selected indeterminate cases by conventional cytology aiming to decrease the number of unnecessary surgeries. The role of DNA ploidy assessment in the risky cases of follicular neoplasms was highlighted by Wang et al. [61] and Ismail et al. [62], all considered DNA ploidy a helpful tool in solving the diagnostic dilemma of the "follicular neoplasm".

However, other studies as Aron et al. [63] and Nguyen et al. [64] denied any role for galectin-3 or DNA ploidy assessment respectively in solving these problematic cases and they suggested that all thyroid follicular neoplasia are best excised for proper histopathological examination, as the histologic determination of capsular and / or vascular invasion is the only way to differentiate benign and malignant cases within this group. To date, no method on its own appeared to be perfect, and the, DNA ploidy and immunocytochemical markers would in combination, help in solving the diagnostic dilemma of the indeterminate cytology.

References

- Rosaria MR, Campenni A, Baldari S, Trovato M. What is new on thyroid cancer biomarkers. *Biomarker Insights*. 2008;3:237-252.
- Utiger RD. The multiplicity of thyroid nodules and carcinomas. *N Eng J Med*. 2005;352: 2376-2378.
- Thapa PB, Shrestha D, Pradhananga JP. Correlation of fine needle aspiration cytology with histopathology findings in cases of thyroid lesions in Bir Hospital. *Journal of college of medical science-Nepal*. 2013; 9(1):23-29.
- Ogilvie JB, Piatigorsky EJ, Clark OH. Current status of fine needle aspiration for thyroid nodules. *Adv Surg*. 2006;40: 223-238.
- Bahar G, Braslavsky D, Sphitcer T, Avidan S. The cytological and clinical value of thyroid " follicular lesions". *Otolaryngol*. 2003; 24: 217-220.
- Nadjari B, Motherby H, Pooschke S, Gabbert HE, Simon D, Roher HD, Feldkamp J, Tharandt L, Bocking A. DNA aneuploidy as a specific marker of neoplastic cells in FNAB of the thyroid. *Anal Quant Cytol Pathol*. 1999; 21:481-488.
- Frasoldati A, Flora M, Pesenti M, Caroggio A, Valcavi R. Computer- assisted cell morphometry and ploidy analysis in the assessment of thyroid follicular neoplasms. *Thyroid*. 2001; 11: 941-946.
- Sturgis CD, Caraway NP, Johnston DA, Sherman SI, Kidd L, Katz RL. Image analysis of papillary thyroid carcinoma fine needle aspirates. *Cancer*. 1999; 87:155-160.
- Haugen BR, Woodmansee WW, McDermott MT. Towards improving the utility of fine-needle aspiration biopsy for the diagnosis of thyroid tumors. *Clin Endocrinol (Oxf)*. 2002; 56:281-290.
- Ringel M: Molecular diagnostic tests in the diagnosis and management of thyroid carcinoma. *Rev Endo Metab Dis*. 2000; 1: 173-181.
- Cohen Y, Rosenbaum E, Clark DP, Zeiger MA, Westra WH. Mutational analysis of BRAF in fine needle aspiration biopsies of the thyroid nodules. *Clin Can Res*. 2004;10:2761-2765.
- Aron M, Kaplia K, Verma K. Utility of galectins-3 expression in thyroid aspirates as a diagnostic marker in differentiating benign from malignant thyroid neoplasms. *Indian J Pathol Microbiol*. 2006;49: 376-380.
- Kim MJ, Kim HJ, Hong SJ, Shong YK, Gong G. Diagnostic utility of galectins-3 in aspirates of thyroid follicular lesions. *Acta Cytol*. 2006; 50: 28-34.
- Saggiorato E, De Pompa R, Volante M, Cappia S, Arecco F, Orlandi F, Pappi M. Characterization of thyroid "follicular neoplasm" in fine needle aspiration cytological specimens using a panel of immunohistochemical markers: a protocol for clinical application. *Endocrine Related Canc*. 2005;12: 305-317.
- Barotolazzi A, Gasbarri A, Papotti M, Bussolati G, Lucante T, Khan A, Nardi F, Tecce R, Larsson O. Application of an immunodiagnostic method for improving preoperative diagnosis of nodular thyroid lesions. *Lancet*. 2001;357:1644-1650.
- DeLellis RA, Lloyd RV, Heitz PU, Eng C (editors): *World Health Organization Classification of Tumors: pathology and Genetics of Tumors of Endocrine Organs*. Lyon, IARC Press, 2007.
- Danque POV, Chen HB, Patil J, et al. Image analysis versus flow cytometry for DNA ploidy quantitation of solid tumors: a comparison of six methods of sample preparation. *Mod Pathol*. 1993; 6:270-275.
- Onaran Y, Tezelman S, Gurel N, Teziolgu T, Oguz H, Tanakol R, Kapran Y. The value of DNA content in predicting the prognosis of thyroid carcinoma in an iodine deficiency region. *Acta chir belg*. 1999;99:30-35.
- Borget I, Vielh P, Leboulleux S, Allyn M, De Pourvoirville G. Assessment of the cost of fine needle aspiration cytology as a diagnostic tool in patients with thyroid nodules. *Am J Clin Pathol*. 2008;129:763-771.
- Ogilvie JB, Piatigorsky EJ, Clark OH. Current status of fine needle aspiration for thyroid nodules. *Adv Surg*. 2006;40: 223-238.
- Marhefka GD, McDivitt JD, Shakir KM, Drake AJ. Diagnosis of follicular neoplasm in thyroid nodules by fine needle aspiration cytology. *Acta Cytol*. 2009; 53: 517-523.
- Mehrotra P, Gonzalez M, Johnson SJ, Davis BR, Wilson JA. Mcm2 and Ki-67 have limited potential in preoperative diagnosis of thyroid malignancy. *Laryngosc*. 2006;116: 1434-1437.
- Deveci MS, Deveci G, LiVolsi VA, Baloch ZW. Fine needle aspiration of follicular lesions of the thyroid. *Diagnosis and follow up*. *Cytojournal*. 2006; 3:9-14.
- Durand S, Ferraro P, Selmi A, et al. Evaluation of gene expression profiles in thyroid nodule biopsy material to diagnose thyroid cancer. *J Clin Endocrinol Metab*. 2008;93: 1195-1202.
- Filee AC, Asa SL, Geisinger KR, et al. Utilization of ancillary studies in thyroid fine needle aspiration: a synopsis of the National Cancer Institute Thyroid Fine Needle Aspiration State of the Science Conference. *Diagn Cytopathol*. 2008;36: 438-441.

26. Raba W, Kaser K, Nieideuh H. Risk factors for malignancy of thyroid nodules initially identified as follicular neoplasia by fine needle aspiration. *Thyroid*. 2004;10: 709-712.
27. Giles Y, Boztepe H, Taziolu T, Tezelinian S. The advantage of total thyroidectomy to avoid reoperation for incidental thyroid cancer in multinodular goiter. *A Ch Surgi*. 2004;139: 179-182.
28. Rago T, Fiorc E, Santini F, Romani R, Piagyi P, Vilti P. Male sex, single nodularity are associated with the risk of thyroid cancer in patients with nodular thyroid disease. *Euro J Endocrinol*. 2010;162: 763-770.
29. Lubiz CC, Faquin WC, Yang J, Hodin R, Stephen A. Clinical and cytological features predictive of malignancy in thyroid follicular neoplasms. *Thyroid*. 2010;20: 25-31.
30. Peadamallu R, Peadamallu K. Incidence of occult carcinoma in multinodular goiter using histopathological findings. *The Internet J Surgery*. 2008;17.
31. Tuille RM, Lemar H, Burch H. The utility of fine needle aspiration for diagnosis of carcinoma associated with MNG. *Thyroid*. 2009;8: 377-383.
32. Esmaili HA, Taghipour H. Fine-Needle Aspiration in the Diagnosis of Thyroid Diseases: An Appraisal in Our Institution. *ISRN Pathology*. 2012;912728.
33. Siddiqui MA, Griffith KA, Michael CW, Pu RT. Nodule heterogeneity as shown by size differences between the targeted nodule and the tumor in thyroidectomy specimen: a cause for a false-negative diagnosis of papillary thyroid carcinoma on fine-needle aspiration. *Cancer*. 2008;25:27-33.
34. Flanagan MB, Ohori NP, Carty SE, Hunt JL. Repeat thyroid nodule fine-needle aspiration in patients with initial benign cytologic results. *Am J Clin Pathol*. 2006;125: 698-702.
35. Rosaria MR, Campenni A, Baldari S, Trovato M. What is new on thyroid cancer biomarkers? *Biomarker Insights*. 2008;3:237-252.
36. Faquin W. Diagnostic and reporting of follicular- patterned thyroid lesions by fine needle aspiration. *Head Neck Pathol*. 2009;3:82-85.
37. Yang J, Schnacling V, Logrono R. Fine needle aspiration of thyroid nodules: a study of 4703 patients with histologic correlations. *Cancer*. 2007;25: 306-315.
38. Haugan BR, Woodmansee WW, McDermott MT. Towards improving the utility of fine-needle aspiration biopsy for the diagnosis of thyroid tumors. *Clin Endocrinol (Oxf)*. 2002;56:281-290.
39. Cochand-Prisollet BK, outroumbus L, Mjalopouru T, Sivolaspenco G. Discriminating benign from malignant thyroid lesions using artificial intelligence and statistical selection. *Oncol Res*. 2006;15: 1023-1026.
40. Hayashi N, Kitaoka M. Fine needle aspiration biopsy of the thyroid nodules: uses and limitations. *Nippon Rinsho*. 2007;65: 7.
41. Frasoldati A, Flora M, Pesenti M, Caroggio A, Valcavi R. Computer- assisted cell morphometry and ploidy analysis in the assessment of thyroid follicular neoplasms. *Thyroid*. 2001;11: 941-946.
42. Bakr MH, Mourad M, Agina HA. DNA ploidy, nuclear morphometry and ki67 proliferative index in the differentiation of thyroid follicular neoplasms. *J Egy Soc Pathol*. 2000;20: 117-124.
43. Nadjari B, Motherby H, Pooschke S, Gabbert HE, Simon D, Roher HD, Feldkamp J, Tharandt L, Bocking A. DNA aneuploidy as a specific marker of neoplastic cells in FNAB of the thyroid. *Anal Quant Cytol Pathol*. 1999;21:481-488.
44. Orell SR, Sterrett GF, Whitaker D. Thyroid gland. In: 'fine needle aspiration cytology' 4th edition. Elsevier Churchill livingstone, 2005:125-158.
45. Francia G, Azzolina L, Mantovani T, Davi MV, Brazzarola P, Valerio A, Petronio R, Sussi P. Heterogeneity of nuclear DNA pattern and its relationship with cell cycle activity parameters in multinodular goiter. *Clin Endocrinol*. 1997;46: 649-654.
46. Konarska L, Skierski L, Ellert A, Steinbrich J, Wozniak A, Kalczak M. Comparative studies of nuclear DNA content in benign and malignant thyroid lesions. *Acta Biochim Poloni*. 2001;48:783-793.
47. Camargo RS, Maeda MY, Shrata NK, Fiho AL. Is a Ag NOR and DNA ploidy analysis useful for evaluating thyroid neoplasms. *Anal Quant Cytol Histol*. 2005;27: 157-161.
48. Missaoui N, Hmissa S, Mokni M, Trabelsi A, Trimech M, Lagueb I, yacoubi MI, Sriha B, Korbi S. DNA content analysis in thyroid neoplasms: diagnostic and prognostic interest. *Ann endocrinol*. 2005;66:333-339.
49. Lewinski A. 2006. <http://www.touchendocrinedisease.com/significance-fine-needle-aspiration-a895-1.html>
50. Cusick EL, Ewer SWB, Krukowski ZH, Matheson NA. DNA aneuploidy in follicular thyroid carcinoma. *Brit J Surg*. 2005;78:94-96.
51. Pennelli G, Mian C, Pelizzo MR, Naccamulli D. Galectin-3 Cytotest in Thyroid Follicular Neoplasia. *Acta Cytologica*. 2009; 53(5):7-13.
52. Chiu CG, Strugnelli SS, Griffith OL, Jones SJ, Gown AM, Walker B, Nabi IR, Wiseman SM. Diagnostic utility of galectin-3 in thyroid cancer. *Am J Pathol*. 2010;176(5):2067-81.
53. Aiad HA, Kandil MA, Asaad NY, Kased AM, El-gody S. Galectin-3 Immunostaining in Cytological and Histopathological Diagnosis of Thyroid Lesions. *Journal of the Egyptian Nat. Cancer Inst*. 2008;20: 36-46.
54. Oestreicher-Kedem Y, Halpern M, Roizman P, et al. Diagnostic value of galectin-3 as a marker for malignancy in follicular patterned thyroid lesions. *Head Neck*. 2004;26: 960-966.
55. Yoshii T, Inohara H, Takenaka Y, Honjo Y, Kubo T. Galectins-3 maintains the transformed phenotype of thyroid papillary carcinoma cells. *Inter J Oncol*. 2001;18: 787-792.
56. Papotti M, Volante M, Saggiorato E, Orlandi F. Role of galectin-3 immunodetection in cytological diagnosis of thyroid cystic papillary carcinoma. *Eur J Endocrinol*. 2005;147: 515-521.
57. Herrman MF, Livolsi VA, Pasha TL, et al. Immunohistochemical expression of galectins-3 in benign and malignant thyroid lesions. *Arch Pathol Lab Med*. 2002;126: 710-713.
58. Saleh HA, Feng J, Tabassum F, Al-Zohaili O, Husain M, Giorgadze T. Differential expression of galectin-3, CK19, HBME1, and Ret oncoprotein in the diagnosis of thyroid neoplasms by fine needle aspiration biopsy. *CytoJournal*. 2009; 6:18
59. Martins L, Matsuo S, Ebina K, Kulcar M, Friguglietti C, Kimura E. Galectin-3 Messenger Ribonucleic Acid and Protein Are Expressed in Benign Thyroid Tumors. *J Clin Endocrinol & Metabol*. 2002;87: 4806-4810.
60. Collet JF, Hurbain I, Prengel C, Utzmann O, Scetbon F, Bernaudin JF, Fajac A. Galectin-3 immunodetection in follicular thyroid neoplasms: a prospective study on fine-needle aspiration samples. *Brit J Cancer*. 2005;93: 1175-1181.
61. Wang DL, Kane SS, Darresso AK. Computerized nuclear DNA in thyroid follicular carcinoma. *World J Surg Oncol*. 2006;4:65-87.
62. Ismail RS, Mahfouz SM, Abd elfattah SL, Hussien H. Image cytometry of FNA of thyroid epithelial lesions. Thesis Cairo University, 2007.
63. Aron M, Kaplia K, Verma K. Utility of galectins-3 expression in thyroid aspirates as a diagnostic marker in differentiating benign from malignant thyroid neoplasms. *Indian J Pathol Microbiol*. 2006;49: 376-380.
64. Nguyen GK, Lee, MW, Ginsberg J, Wragg T, Bilodeau D. Fine-needle aspiration of the thyroid: an overview. *Cytojournal*. 2005; 2: 12.