

# Leptomeningeal Metastases in Solid Tumors

Marija Karakolevska-Ilova\*, Elena Simeonovska Joveva, Marija Dimitrovska Ivanova

University Goce Delchev, Faculty of Medical Sciences, Shtip, Republic of Macedonia

## Abstract

**Citation:** Karakolevska-Ilova M, Simeonovska Joveva E, Dimitrovska Ivanova M. Leptomeningeal Metastases in Solid Tumors. OA Maced J Med Sci. 2014 Dec 15; 2(4):622-625. http://dx.doi.org/10.3889/oamjms.2014.111

**Key words:** breast cancer; lung cancer; leptomeningeal metastases; metastatic disease; carcinoma.

**Correspondence:** Marija Karakolevska-Ilova. \*General Mihajlo Apostolski, No. 34/14, 2000 Shtip. Phone number: ++389 70270-284. E-mail: marija.karakolevska@ugd.edu.mk

**Received:** 04-Jul-2014; **Revised:** 27-Oct-2014; **Accepted:** 28-Oct-2014; **Online first:** 13-Nov-2014

**Copyright:** © 2014 Marija Karakolevska-Ilova, Elena Simeonovska Joveva, Marija Dimitrovska Ivanova. This is an open access article distributed under the terms of the Creative Commons Attribution License, which permits unrestricted use, distribution, and reproduction in any medium, provided the original author and source are credited.

**Competing Interests:** The authors have declared that no competing interests exist.

**BACKGROUND:** Leptomeningeal metastases are diagnosed in 1% to 8% of patients with cancer. The most common histology is leukaemia, lymphoma, breast carcinoma, lung carcinoma and melanoma. The aim of this study is to show the appearance of leptomeningeal metastases in lung and breast cancer with specific biological features.

**AIM:** The study is a review of two cases - breast and lung carcinoma with specific biological features who eventually have developed leptomeningeal metastases.

**CASE PRESENTATION:** Although CNS metastasis most commonly occurs in those with known systemic metastases, our patient had biological indolent disease (nor hormone negative or HER 2 positive and no metastatic disease) and still LM did occur. LM remains a devastating complication of cancer with classic presentation with multifocal neurologic signs and symptoms (like the case with lung cancer), but many patients also have evidence of impaired CSF flow, and hydrocephalus may be the only presenting manifestation of LM.

**CONCLUSION:** The prognostic factors associated with survival in patients with LM metastasis are not certain as well as right treatment for these patients which is still a big challenge. Due to the lack of randomized studies and especially of studies referring to one specific primary tumor, there is currently no generally accepted standard of care in the treatment of LM metastases.

## Introduction

Autopsy studies have shown that leptomeningeal metastases (LM) are diagnosed in 1% to 8% of patients with cancer [1]. Many types of tumors have been reported, but the most common histology are leukemia, lymphoma, breast carcinoma, lung carcinoma and melanoma. LM manifest as a multifocal constellation of neurologic signs and symptoms, although occasionally patients present only with evidence of hydrocephalus or elevated intracranial pressure. The location of the signs and symptoms can be divided into three anatomic compartments: the cerebral hemispheres, the posterior fossa/cranial nerves, and spinal cord/nerve roots, and any or all of compartments may be involved. Despite the improvement of the sensitivity of diagnostic techniques, the diagnosis of LM remains challenging, and neither cerebrospinal fluid (CSF) cytology nor MRI is adequately sensitive to be used in isolation. MRI has consistently been highly sensitive for the diagnosis of LM from solid tumors, with sensitivity ranging from 76 % to 100% [1], but it is less sensitive for hematopoietic tumors. MRI should generally be performed before lumbar puncture for

CSF analysis, because pachymeningeal enhancement can be seen after lumbar puncture if intracranial hypotension develops [1], so the contrast-enhanced magnetic resonance imaging has emerged as a reliable diagnostic tool in LM and in the appropriate clinical context, findings suggestive of LM on MRI are adequate to initiate treatment of LM even in the absence of positive CFS cytology [2]. Positive CSF is pathognomonic for LM, but its sensitivity is limited.

A review of the literature encompassing multiple series totaling more than 500 patients led to the calculation of 71% sensitivity for an initial cytology sample. The sensitivity increased to 86% after two samples, to 90% after three samples, and 93% after more than three samples [3]. Even in those with negative cytology, CSF pleocytosis, elevated protein, and hypoglycorrhachia are common and provide supportive evidence for the diagnosis of LM. More specialized CSF tests can also be useful in certain situations like flow cytometry in hematopoietic malignancies. Variety of other biochemical markers have also been studied in patients with LC but their use has poor sensitivity and specificity (i.e. lymphocytes in CSF can also be characterized to see whether they are T cells or B cells, specific tumor

markers – CEA etc). Chemotherapy and radiotherapy for treatment of LM metastasis have been used in different modalities. Basically, the poor results achieved with current modalities led to the controversial management of these patients and the big importance is that any treatment decision should be based on which patient is most likely to benefit from it.

The aim of this study is to show the appearance of leptomeningeal metastases in lung and breast cancer with specific biological features.

## Case Reports

The study is a review of two cases:

**First case:** This is a case about 35 years old female patient with a history of right breast carcinoma. The disease began 3 years ago (2010). She had been diagnosed with stage IIIC invasive ductal carcinoma; (ER+, PR+, HER2-), with lymphovascular invasion and positive axillary nodes as well as positive ipsilateral supraclavicular node after total mastectomy with axillary dissection. The patient was treated with neoadjuvant chemotherapy (four cycles of doxorubicin and cyclophosphamide followed by four cycles of paclitaxel). After the surgery radiation therapy was proceed (TTD = 50 Gy/25 fr) followed with hormone therapy with tamoxifen. During the treatment the patient was complained of strong headache which didn't respond to acetaminophen or ibuprofen. The conciliar neurologist was consulted and MRI was recommended. MRI demonstrated several parenchymal metastases, the largest of which was in the left cerebellar hemisphere, as well as extensive leptomeningeal enhancement most evident in the posterior fossa, around the brainstem. Lumbar puncture 3 days later revealed positive cytology demonstrating numerous malignant cells compatible with her known breast carcinoma, confirming the diagnosis of leptomeningeal metastasis. The neurologic symptoms rapidly worsened so the patient was put on anti-edematous and antiepileptic therapy.

**Second case:** This is the case about patient 60 years old man. The first symptoms of disease have occurred in 2011. He had been diagnosed with stage IIIA (T3N2M0, EGFR-) adenocarcinoma of the right lung with metastasis to the ipsilateral mediastinal lymph nodes. He was treated neoadjuvantly (cisplatin/etoposide) followed by lobectomy and selective lymph node dissection. After the operation radiotherapy was performed (TTD = 60 Gy). The patient has disease free interval of two years and then he developed focal left arm seizure. MRI was recommended and showed a right posterior frontal parenchymal brain metastasis. Systemic restaging was negative, and whole brain radiation was

recommended (TTD = 30 Gy). The chemotherapy (carboplatin/paclitaxel for 4 courses) was started. After one year he developed focal midthoracic back pain and was found to have Th8 vertebral metastasis that was radiated (TTD = 8 Gy/1fr). The patient was put on bisphosphonate therapy (amp. Zolendronic acid/4 mg). After six mounts he developed a progressive right facial droop with increasing bilateral lower extremity weakness followed by urinary incontinence. Another MRI of the brain and spine was done. There were three small superficial parenchymal brain metastases, but no lesions that would explain his symptoms. The neurologist was consulted and he recommended lumbar puncture. Lumbar puncture was performed and cytology revealed malignant cells which confirmed the diagnosis of leptomeningeal metastasis. The patient general condition was limiting for further specific therapy so he was recommended symptomatic therapy.

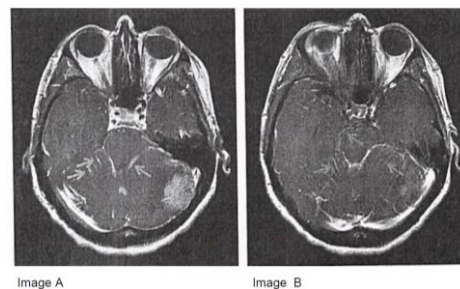


Figure 1: Axial T1 – weighted MRI indicating a parenchymal brain metastasis (image A) as well as leptomeningeal enhancement coating the brainstem (image A) and cerebellar folia (image B), consistent with leptomeningeal metastasis.

## Discussion

Carcinomatous meningitis arises from either solid tumors or haematological malignancies. During the past few decades the incidence of LC (leptomeningeal carcinomatosis) appears to be increasing as imaging studies improve and as cancer patients live longer. Overall, neoplastic meningitis occurs in 5–8% of patients with cancer, whereas almost 20% of patients with neurological symptoms and signs are found to have LC during autopsy. Among solid tumors adenocarcinoma is the most predominant histological type. LC is more frequently seen in widely disseminated and progressive disease. The interval between initial cancer diagnosis and the development of LM is longer for breast cancer than in other solid tumors. Median time from initial breast cancer diagnosis to LM is 3 ½ years [4], compared to one year or less for lung cancer [5].

Breast cancer is the most common solid tumor complicated by LC and accounts for 11–64% of all cancer patients, but only 5% of patients with breast cancer. Brain metastases in breast cancer occur most

commonly (10%) in the young adults (20-39 years-old) [6] – 35 years in our case report. CNS metastasis in breast cancer may present long after treatment of the primary cancer [7], but in some situations depending of other factors they can present during the treatment of primary disease (like our case with breast cancer). Although CNS metastasis most commonly occurs in those with known systemic metastasis, the overall risk of CNS recurrence as the initial site of metastatic spread is 1.3% and certain breast cancer subtypes have been associated with an increased risk of CNS metastasis [8]. Initial hormone receptor positivity is associated with higher incidence of bone metastasis and a longer median time to development of LM when compared to triple-negative breast cancer [9]. Triple negative breast cancer is more likely than receptor positive breast cancer to present with isolated LM and has been associated with a shorter median overall survival following the development of distant metastases. One study of a 3 year median follow-up of triple negative breast cancer patients 36% had CNS involvement in their clinical course [10]. Our patient had biological indolent disease (nor hormone negative or HER 2 positive and no metastatic disease) and still LM did occur. HER-2 status does not appear to impact overall survival from LM, but it is important to notice that the treatment with target therapy – trastuzumab was associated with a significantly longer time to the development of LM metastases (15.2 v.s 9.9 months) [11].

Lung cancer accounts for 14–29% of all cancer patients, but only 9–25% of patients with LC. The clinical features and prognostic factors of LC in NSCLC patients, however, have not been well identified [12]. LM remains a devastating complication of cancer with classic presentation with multifocal neurologic signs and symptoms (like the case with lung cancer), but many patients also have evidence of impaired CSF flow, and hydrocephalus may be the only presenting manifestation of LM. Relief of CSF outflow obstruction by CSF diversion has been shown to improve functional status, and is likely to prolong survival in these cases [13].

The prognostic factors associated with survival in patients with LM metastasis are not certain [14]. The study conducted at M. D. Anderson Cancer Center has reviewed the records from treated patients with LM metastasis between 1944 and 2002. The primary hypothesis was that more extensive burden of CNS metastasis at the time of diagnosis of LM (as evidenced by imaging of the CNS parenchyma and meninges and CSF cytology status (positive versus negative) correlates with poorer outcomes. The study has showed that the amount of CNS tumor burden at the time of diagnosis of LM did not inversely correlate with survival outcomes. Another question that is still open is the right treatment for these patients and it is still a big challenge. Due to the lack of randomized studies and especially of studies referring to one specific primary tumor, there is currently no generally

accepted standard of care in the treatment of LM metastases. Surgery (for hydrocephalus), radiation therapy (RT), and chemotherapy (systemic or intra-CSF) may be considered. Treatment decisions are influenced by the individual's functional status, ability and willingness to receive additional treatment, and extent of active systemic disease. In some cases, the diagnosis of LM compels providers and patients to pursue palliative care, especially when LM is accompanied by a dramatic clinical decline. Working with currently available therapies, aggressive ICP management and combination IT chemotherapy may afford some survival benefit over previously studied IV or IT monotherapies [15]. Intra – CSF (intralumbar or IT and IVent) chemotherapy is the mainstay of treatment for LM, although its superiority compared with systemic treatment has not been established in randomized trials and its efficacy consequently is uncertain [16]. Nevertheless, recent retrospective data suggested that intra-CSF chemotherapy may have utility in NSCLC patients [16]. Among new generation chemotherapeutic agents, several studies have suggested that in patients with NSCLC and LM metastases may benefit from EGFR target therapy [17] on the other hand aggressive chemotherapy has resulted in improved outcomes for patients with LM in breast cancer [18].

Despite advances in the treatment of cancer in general, survival for patients with LM remains dismal. Prospective studies have found a median overall survival (OS) of 9-30.3 weeks in those with breast cancer following the diagnosis of LM. Compared to lung cancer LM, studies have shown mixed results, with some favoring a longer survival for breast cancer LM and others demonstrating no difference.

## References

1. De Angelis L, Posner J. Neurological complication in cancer. 2nd ed. New York, NY: Oxford University Press, 2008.
2. Clarke JL, Perez HR, Jacks LM, Panageas KS, Deangelis LM. Leptomeningeal metastases in the MRI era. *Neurology*. 2010;74:1449–1454.
3. Le Rhun E, Tailibert S, Chamberlain M. Canceromatous meningitis: Leptomeningeal metastases in solid tumors. *Surg Neurol Int*. 2013;S265-S288.
4. Oechsle K, Lange-Brock V, Krull A, Bokemeyer C, de Wit M. Prognostic factors and treatment options in patients with leptomeningeal metastases of different primary tumors: a retrospective analysis. *J Cancer Res Clin Oncol*. 2010;136:1729
5. Park JH, Kim YJ, Lee JO, Lee KW, Kim JH, Bang SM, Chung JH, Kim JS, Lee JS. Clinical outcomes of leptomeningeal metastasis in patients with non-small cell lung cancer in the modern chemotherapy era. *Lung Cancer*. 2012;76:387–92.
6. Kim HJ, Im SA, Keam B, Kim YJ, Han SW, Kim TM, Oh DY, Kim JH, Lee SH, Chie EK, Han W, Kim DW, Kim TY, Noh DY, Heo DS, Park IA, Bang YJ, Ha SW. Clinical outcome of central nervous system metastases from breast cancer: differences in survival depending on systemic treatment. *J Neurooncol*. 2012;106:303–13.

7. Kennecke H, Yerushalmi R, Woods R, Cheang MC, Voduc D, Speers CH, Nielsen TO, Gelmon K. Metastatic behavior of breast cancer subtypes. *J Clin Oncol*. 2010;28:3271–7.
8. Slimane K, Andre F, Delaloge S, Dunant A, Perez A, Grenier J, Massard C, Spielmann M. Risk factors for brain relapse in patients with metastatic breast cancer. *Ann Oncol*. 2004;15:1640–4.
9. Lee S, Ahn HK, Park YH, Nam do H, Lee JI, Park W, Choi DH, Huh SJ, Park KT, Ahn JS, Im YH. Leptomeningeal metastases from breast cancer: intrinsic subtypes may affect unique clinical manifestations. *Breast Cancer Res Treat*. 2011;129:809–17.
10. Lin NU, Vanderplas A, Hughes ME, Theriault RL, Edge SB, Wong YN, Blayney DW, Niland JC, Winer EP, Weeks JC. Clinicopathologic Features, Patterns of Recurrence, and Survival Among Women With Triple-Negative Breast Cancer in the National Comprehensive Cancer Network. *Cancer*. 2012;118:5463–5472.
11. Lee S, Ahn HK, Park YH, Nam do H, Lee JI, Park W, Choi DH, Huh SJ, Park KT, Ahn JS, Im YH. Leptomeningeal metastases from breast cancer: intrinsic subtypes may affect unique clinical manifestations. *Breast Cancer Res Treat*. 2011;129:809–17.
12. Morris PG, Reiner AS, Szenberg OR, Clarke JL, Panageas KS, Perez HR, Kris MG, Chan TA, DeAngelis LM, Omuro AM. Leptomeningeal metastasis from non-small cell lung cancer: survival and the impact of whole brain radiotherapy. *J Thorac Oncol*. 2012;7(2):382-5.
13. Lin N, Dunn IF, Glantz M, Allison DL, Jensen R, Johnson MD, Friedlander RM, Kesari S. Benefit of ventriculoperitoneal cerebrospinal fluid shunting and intrathecal chemotherapy in neoplastic meningitis: a retrospective, case-controlled study. *J Neurosurg*. 2011;115:730–6.
14. Chamberlain MC, Kormanik PA. Prognostic significance of coexistent bulky metastatic central nervous system disease in patients with leptomeningeal metastases. *Arch Neurol*. 1997;54:1364–8.
15. Scott BJ, Brown T, Van Vught V, Kim R, Fanta PT, Bazhenova L, Kesari S. Concurrent intrathecal methotrexate and liposomal cytarabine for the treatment of leptomeningeal metastasis from solid tumors. *Journal of Clinical Oncology*. 2012:30.
16. Morris PG, Reiner AS, Szenberg OR, Clarke JL, Panageas KS, Perez HR, et al. Leptomeningeal metastasis from non-small cell lung cancer: Survival and the impact of whole brain radiotherapy. *J Thorac Oncol*. 2012;7:382-5.
17. Tetsumoto S, Osa A, Kijima T, Minami T, Hirata H, Takahashi R, et al. Two cases of leptomeningeal metastases from lung adenocarcinoma which progressed during gefitinib therapy but responded to erlotinib. *Int J Clin Oncol*. 2012;17:155-9.
18. Mehta AI, Brufsky AM, Sampson JH. Therapeutic approaches for HER2-positive brain metastases: Circumventing the blood-brain barrier. *Cancer Treat Rev*. 2013;39:261–9.