

Surgical Treatment of Anomalous Origin of Right Coronary Artery in a Patient with Mitral Stenosis

Ali Refatllari*, Ermal Likaj, Selman Dumani, Endri Hasimi, Artan Goda

Department of Cardiovascular Surgery, University Hospital Centre "Mother Theresa", Rruqa e Dibrës, N. 370, Tirana, Albania

Abstract

Citation: Refatllari A, Likaj E, Dumani S, Hasimi E, Goda A. Surgical Treatment of Anomalous Origin of Right Coronary Artery in a Patient with Mitral Stenosis. OA Maced J Med Sci. 2016 Mar 15; 4(1):131-134. <http://dx.doi.org/10.3889/oamjms.2016.002>

Key words: Coronary anomalies; right coronary artery; bypass grafting; mitral stenosis; surgical technique.

***Correspondence:** Dr. Ali Refatllari. Department of Cardiovascular Surgery, University Hospital Centre "Mother Theresa", Rruqa e Dibrës, N. 370, Tirana, Albania. E-Mail: alirefatllari@gmail.com

Received: 17-Oct-2015; **Revised:** 06-Dec-2015; **Accepted:** 07-Dec-2015; **Online first:** 24-Dec-2015

Copyright: © 2016 Ali Refatllari, Ermal Likaj, Selman Dumani, Endri Hasimi, Artan Goda. This is an open-access article distributed under the terms of the Creative Commons Attribution License, which permits unrestricted use, distribution, and reproduction in any medium, provided the original author and source are credited.

Competing Interests: The authors have declared that no competing interests exist.

BACKGROUND: An anomalous origin of the right coronary artery is rarely observed, with a reported incidence between 0.026% and 0.25%. This condition is often completely asymptomatic and is found incidentally during angiographic evaluation for other cardiac diseases. However some patients present with exertion angina or sudden death. Surgical treatment in patients with anomalous RCA is still controversial. Treatment can be conservative, angioplasty or surgery.

CASE PRESENTATION: A 59-year-old man was admitted with severe mitral stenosis. He complained exertion and rest dyspnea, NYHA III class. He had sequels of embolic stroke, results of left atrial thrombus. Echocardiography showed calcified severe mitral stenosis with mitral orifice area of 1.1 square centimeters with PSPAP 60 mmHg and normal LV function. Routine coronary angiography before surgery showed aberrant origin of RCA from the left sinus of Valsalva with 90% stenosis at his origin. Multi-slice computed tomography proved the diagnosis of anomalous RCA arising from the left sinus of Valsalva and taking an inter-arterial course between the aorta and pulmonary artery. The patient underwent mitral valve replacement with mechanical St. Jude prosthesis No 29 and saphenous vein graft to RCA. We chose by-pass grafting techniques because after aortotomy, RCA was too close to LMCA, intramural course was too short and stenosis of RCA was outside of aortic wall. The patient's perioperative course was without complications and patient was discharged on the seventh postoperative day.

CONCLUSION: Correction of anomalous of the origin of right coronary artery is mandatory in cases where patient has to be operated for other cardiac causes.

Introduction

Anomalous aortic origin of the coronary artery (AAOCA) is rarely observed, with a reported incidence between 0.026% and 0.25%. This condition is often completely asymptomatic and is found incidentally during angiographic evaluation for other cardiac diseases. However, some patients present with symptoms which may include chest pain, syncope, myocardial infarction, or sudden death [1-3]. AAOCA is the second most common cause of sudden death in young athletes, accounting for approximately 10% of such events [4, 5]. Surgical repair of AAOCA is safe and extremely successful in eliminating symptoms of myocardial ischemia [6].

We report here the first case in Albania with AAOCA associated with mitral stenosis diagnosed and treated surgically at our department.

Case presentation

A 59-year-old man was admitted with severe mitral stenosis. He complained exertion and rest dyspnea, NYHA III class. No chest pain or other ischemic symptoms were seen. He had sequels of embolic stroke, results of left atrial thrombus. ECG showed atrial fibrillation and non-specific ST changes.

Echocardiography showed calcified severe mitral stenosis with mitral orifice area of 1.1 cm² with PASP 60 mm Hg and a normal LV function. Routine coronary angiography before surgery showed aberrant origin of RCA from the left sinus of Valsalva with 90% stenosis at his origin as seen in Figure 1. Multi-slice computed tomography proved the diagnosis of anomalous RCA arising from the left sinus of Valsalva and taking an inter-arterial course between the aorta and pulmonary artery. RCA has 90% stenosis at his origin but outside of aortic wall.

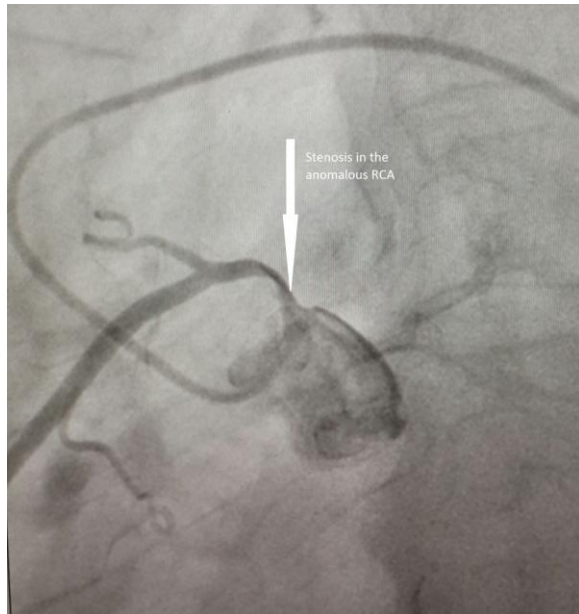


Figure 1: Coronary angiography shows anomalous origin of right coronary artery from left sinus and 75-90% stenosis at its origin

The patient underwent open heart surgery with cardiopulmonary bypass machine. After median sternotomy it was seen that right coronary artery origin was in left coronary sinus of Valsalva and the artery passed between the aorta and the pulmonary artery. After aortic clamping and mitral valve replacement with mechanical St. Jude mechanical prosthesis No 29, the aorta was divided transversally.

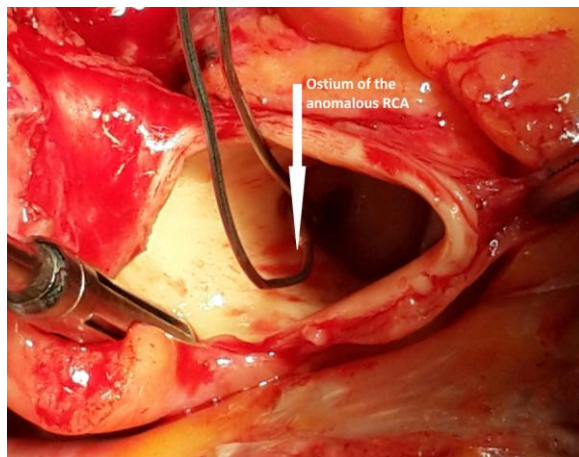


Figure 2: Intraoperative images of both ostia of the coronary arteries

It was visualized the right coronary ostium arising from left sinus of Valsalva, close to left main ostium and its inter-arterial course. We decided to perform right coronary bypass grafting with saphenous vein to RCA because the ostium of right coronary artery was small, intramural course was too short and a 90% stenosis of RCA was outside of aortic wall. We judged that it was not the case to perform unroofing techniques. The patient's perioperative course was without complications and patient was discharged on the seventh postoperative day.

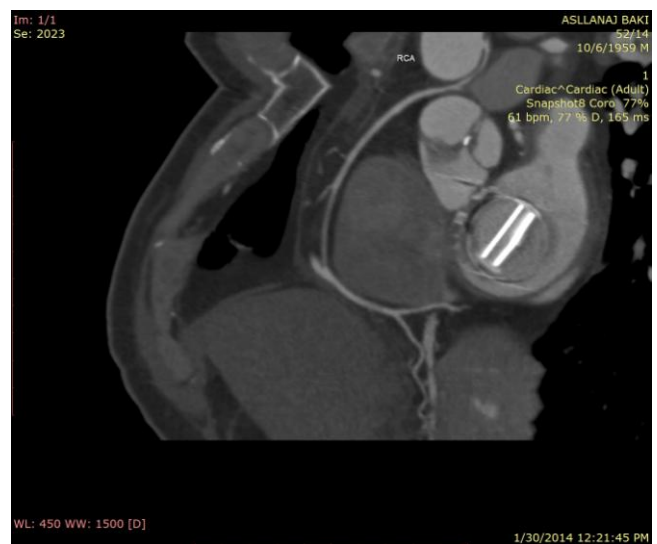
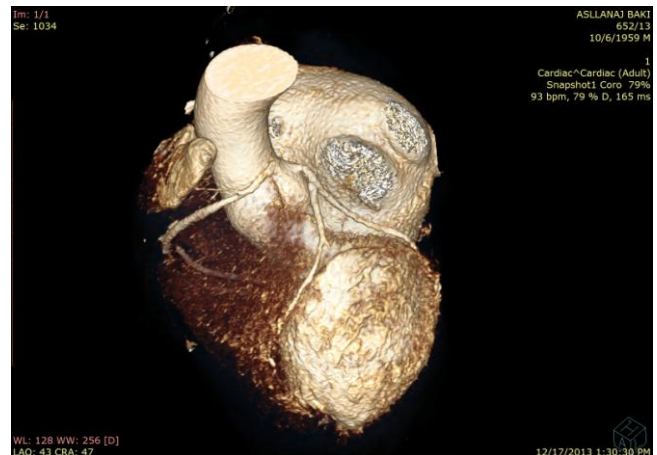


Figure 3: CT scan and 3D reconstruction of the patient before (up) and after surgery (down)

Discussion

Anomalous origin of the coronary artery from the opposite coronary sinus of Valsalva occurs with a very low incidence in the general population, but there is a high risk of sudden death due to myocardial ischemia and the resultant arrhythmias associated with them. Various mechanisms have been postulated to cause ischemia, including: origin in an acute angle

resulting in a slit-like orifice and kinking or occlusion caused by the angulation at the point of coronary artery, coronary spasm resulting from its torsion movement, mechanical compression of the coronary artery between the pulmonary and aortic trunks during physical exertion [7-9]. The majority of these complications may be exacerbated during or immediately after exercise, as exercise leads to compression of coronary arteries as well as increasing the pre-existing angulation of the proximal portion of anomalous vessel.

Patients with AAOCA are typically asymptomatic. The diagnosis is often made as an incidental finding. Symptomatic patients complain of exertional syncope, chest pain, or palpitations [10]. The physical exam, ECG and exercise stress testing are generally unremarkable. Because coronary angiography has a significant false negative rate [11], other imaging modalities are frequently employed. In particular, multi-detector computed tomography (CT) scanners and magnetic resonance angiography (MRA) now provide excellent spatial resolution allowing visualization of the coronary anatomy [10].

The choice of treatment for this coronary anomaly is controversial, medical or surgery, with most of surgeons advocating revascularization in all of cases with inter-arterial course of anomalous coronary artery [12, 13]. Most of the authors think that in symptomatic patients, without question, surgery is the best choice. For asymptomatic patients, if they have an anomalous left coronary with an intramural route, they are offered surgery. For those with an anomalous right coronary artery arising from the left sinus of Valsalva, it is a very difficult question. The level of physical activity of these patients and the dominance of their coronary artery, also play a role in decision making. A right coronary artery that has a large posterior descending artery has a large amount of myocardium at risk, and especially in young people's playing basketball even though they are asymptomatic, they are more likely to get operated on [14].

Our patient was free of ischemic symptoms, but he had to be operated for severe mitral stenosis and had a 90% stenosis of proximal RCA in the course of intramural anterior to the aorta (Fig. 1). No sign of atherosclerotic changes was seen in coronary angiography.

There are multiple surgical options for treating AAOCA. Bypass grafting was used initially but early graft failure was reported [15, 16]. Some authors explain that the early failure is due to the steal phenomenon at high levels of exertion [17] or competitive flow from patent native vessels contributing to graft thrombosis [18, 19]. For this reason bypass grafting has been used less frequently [10]. Other approaches include direct implantation of the anomalous artery [20], patch augmentation [21, 22] or pulmonary artery translocation to reduce the

risk of compression of the anomalous vessel as it transverses between the aorta and the pulmonary artery [9, 23].

More recently, unroofing the anomalous vessel along its intramural segment has become the preferred management option [9, 24, 25]. This procedure, first reported by Mustafa in 1981, creates a neo-orifice at the anatomically correct sinus [26]. The advantages of unroofing are elimination the intramural segment and avoidance of an oblique angle of take-off of the vessel.

We decided to perform CABG with saphenous graft in our patient for some reasons:

- there was a right coronary artery stenosis 90% outside of aortic wall, without signs of atherosclerosis but not spasm of coronary artery, because during the angiography procedure it was not released after nitrite injection;

- the right coronary ostium was small and too close to the ostium of left main coronary artery and intramural course was too short; and

- the right mammary artery was very small.

We conclude that correction of the anomalous origin of RCA is mandatory in cases where patient has to be operated for other cardiac causes.

References

1. Davies JE, Burkhart HM, Dearani JA, et al. Surgical management of anomalous aortic origin of a coronary artery. *Ann Thorac Surg.* 2009;88:844–848. <http://dx.doi.org/10.1016/j.athoracsur.2009.06.007> PMID:19699909
2. Tavaf-Motamen H, Bannister SP, Corcoran PC, Stewart RW, Mulligan CR, DeVries WC. Repair of anomalous origin of right coronary artery from the left sinus of Valsalva. *Ann Thorac Surg.* 2008;85:2135–2136. <http://dx.doi.org/10.1016/j.athoracsur.2007.07.006> PMID:18498845
3. Erez E, Tam VKH, Dublin NA, Stakes J. Anomalous coronary artery with aortic origin and course between the great arteries: Improved diagnosis, anatomic findings, and surgical treatment. *Ann Thorac Surg.* 2006;82:973–977. <http://dx.doi.org/10.1016/j.athoracsur.2006.04.089> PMID:16928518
4. Basso C, Maron BJ, Corrado D, Thiene G. Clinical profile of congenital coronary artery anomalies with origin from the wrong aortic sinus leading to sudden death in young competitive athletes. *J Am Coll Cardiol.* 2000;35:1493–1501. [http://dx.doi.org/10.1016/S0735-1097\(00\)00566-0](http://dx.doi.org/10.1016/S0735-1097(00)00566-0)
5. Borjesson M, Pelliccia A. Incidence and aetiology of sudden death in young athletes: an international perspective. *Br J Sports Med.* 2009;43:644–648. <http://dx.doi.org/10.1136/bjism.2008.054718> PMID:19734497
6. Mainwaring RD, Reddy VM, Reinhartz O, Petrossian E, MacDonald M, Nasirov T, Miyake CY, Hanley FL. Anomalous aortic origin of a coronary artery: medium-term results after surgical repair in 50 patients. *Ann Thorac Surg.* 2011;92(2):691-7. <http://dx.doi.org/10.1016/j.athoracsur.2011.03.127>

PMid:21718962

7. Taylor AJ, Rogan KM, Virmani. R Sudden cardiac death associated with isolated congenital coronary artery anomalies. *J Am Coll Cardiol.* 1992;20(3):640-7.

[http://dx.doi.org/10.1016/0735-1097\(92\)90019-J](http://dx.doi.org/10.1016/0735-1097(92)90019-J)

8. Kaku B, Kanaya H, Ikeda M, Uno Y, Fujita S, Kato F, Oka T. Acute inferior myocardial infarction and coronary spasm in a patient with an anomalous origin of the right coronary artery from the left sinus of valsalva. *Jpn Circ J.* 2000;64(8):641-3.

<http://dx.doi.org/10.1253/jcj.64.641>

PMid:10952167

9. Heo W, Min HK, Kang do K, Jun HJ, Hwang YH, Lee HC. Three different situations and approaches in the management for anomalous origin of the right coronary artery from the left coronary sinus: case report. *J Cardiothorac Surg.* 2014;23:9:21.

10. Pe-alver JM, Mosca RS, Weitz D, Phoon CK. Anomalous aortic origin of coronary arteries from the opposite sinus: a critical appraisal of risk. *BMC Cardiovasc Disord.* 2012;12:83.

<http://dx.doi.org/10.1186/1471-2261-12-83>

PMid:23025810 PMCID:PMC3502461

11. Jureidini SB, Singh GK, Marino CJ, Fiore AC. Aberrant origin of the left coronary artery from the right aortic sinus: surgical intervention based on echocardiographic diagnosis. *J Am Soc Echocardiogr.* 2000;13:1117-1120.

<http://dx.doi.org/10.1067/mje.2000.107072>

PMid:11119280

12. Frommelt PC, Sheridan DC, Berger S, Frommelt MA, Tweddell JS. Ten-year experience with surgical unroofing of anomalous aortic origin of a coronary artery from the opposite sinus with an interarterial course. *J Thorac Cardiovasc Surg.* 2011;142(5):1046-51.

<http://dx.doi.org/10.1016/j.jtcvs.2011.02.004>

PMid:21439578

13. John S, Strickman NE. Anomalous Origin of the Right Coronary Artery from the Left Coronary Sinus. *Tex Heart Inst J.* 2002;29(1):37-39.

14. Mumtaz MA, Lorber RE, Arruda J, Pettersson GB, Mavroudis C. Surgery for Anomalous Aortic Origin of the Coronary Artery. *Ann Thorac Surg.* 2011;91:811-815.

<http://dx.doi.org/10.1016/j.athoracsur.2010.11.002>

PMid:21353004

15. Moodie DS, Gill C, Loop FD, Sheldon WC. Anomalous left main coronary artery originating from the right sinus of Valsalva: Pathophysiology, angiographic definition, and surgical approaches. *J Thorac Cardiovasc Surg.* 1980;80:198-205.

PMid:7401670

16. Selig MB, Jafari N. Anomalous origin of the left main coronary artery from the right coronary artery ostium-interarterial subtype: angiographic definition and surgical treatment. *Cathet Cardiovasc Diagn.* 1994;31:41-47.

<http://dx.doi.org/10.1002/ccd.1810310110>

17. Tavaf-Motamen H, Bannister SP, Corcoran C, Stewart RW, Mulligan CR, DeVries WC. Repair of anomalous origin of right coronary artery from the left sinus of valsalva. *Ann Thorac Surg.* 2008;85:2135-213.

<http://dx.doi.org/10.1016/j.athoracsur.2007.07.006>

PMid:18498845

18. Reul RM, Cooley DA, Hallman GL, Reul GJ. Surgical treatment of coronary artery anomalies: report of a 37 1/2-year experience at the Texas Heart Institute. *Tex Heart Inst J.* 2002;29:299-307.

PMid:12484614 PMCID:PMC140292

19. Friedman AH, Fogel MA, Stephens P Jr, Hellinger JC, Nykanen DG, Tweddell J, Feltes TF, Rome JJ. Identification, imaging, functional assessment and management of congenital coronary arterial abnormalities in children. *Cardiol Young.* 2007;17(Suppl 2):56-67.

<http://dx.doi.org/10.1017/S1047951107001163>

PMid:18039399

20. Rogers SO, Leacche M, Mihaljevic T, Rawn JD, Byrne JG.

Surgery for anomalous origin of the right coronary artery from the left aortic sinus. *Ann Thorac Surg.* 2004;78:1829-1831.

[http://dx.doi.org/10.1016/S0003-4975\(03\)01501-7](http://dx.doi.org/10.1016/S0003-4975(03)01501-7)

21. Frommelt PC, Frommelt MA, Tweddell JS, Jaquiss RDB. Prospective echocardiographic diagnosis and surgical repair of anomalous origin of a coronary artery from the opposite sinus with an interarterial course. *J Am Coll Cardiol.* 2003;42:148-154.

[http://dx.doi.org/10.1016/S0735-1097\(03\)00503-5](http://dx.doi.org/10.1016/S0735-1097(03)00503-5)

22. Karl TR, Provenzano SC, Nunn GR. Anomalous aortic origin of a coronary artery: a universally applicable surgical strategy. *Cardiol Young.* 2010;20:44-49.

<http://dx.doi.org/10.1017/S1047951110001083>

PMid:21087559

23. Rodefeld MD, Culbertson CB, Rosenfeld HM, Hanley FL, Thompson LD. Pulmonary artery translocation: a surgical option for complex anomalous coronary artery anatomy. *Ann Thorac Surg.* 2001;72:2150-2152.

[http://dx.doi.org/10.1016/S0003-4975\(01\)03208-8](http://dx.doi.org/10.1016/S0003-4975(01)03208-8)

24. Tavaf-Motamen H, Bannister SP, Corcoran C, Stewart RW, Mulligan CR, DeVries WC. Repair of anomalous origin of right coronary artery from the left sinus of valsalva. *Ann Thorac Surg.* 2008;85:2135-2136.

<http://dx.doi.org/10.1016/j.athoracsur.2007.07.006>

PMid:18498845

25. Romp RL, Herlong JR, Landolfo CK, Sanders SP, Miller CE, Ungerleider RM, Jagers J. Outcome of unroofing procedure for repair of anomalous origin of left or right coronary artery. *Ann Thorac Surg.* 2003;76:589-596.

[http://dx.doi.org/10.1016/S0003-4975\(03\)00436-3](http://dx.doi.org/10.1016/S0003-4975(03)00436-3)

26. Mustafa I, Gula G, Radley-Smith R, Durrer S, Yacoub M. Anomalous origin of the left coronary artery from the anterior aortic sinus: a potential cause of sudden death. *J Thorac Cardiovasc Surg.* 1981;82:297-300.

PMid:7253693