

Spectrum of Childhood and Adolescent Ovarian Tumors in India: 25 Years Experience at a Single Institution

Ruchi Rathore^{1*}, Sonal Sharma², Deepshikha Arora²

¹Department of Pathology, NDMC Medical College and Hindu Rao Hospital, Guru Gobind Singh Indraprastha University, New Delhi, India; ²Department of Pathology, University College of Medical Sciences, Delhi University, New Delhi, India

Abstract

Citation: Rathore R, Sharma S, Arora D. Spectrum of Childhood and Adolescent Ovarian Tumors in India: 25 Years Experience at a Single Institution. Open Access Maced J Med Sci. 2016 Dec 15; 4(4):551-555. <https://doi.org/10.3889/oamjms.2016.090>

Keywords: paediatric population; ovary; malignancy; immature teratoma; incidence.

***Correspondence:** Ruchi Rathore, Department of Pathology, NDMC Medical College and Hindu Rao Hospital, Guru Gobind Singh Indraprastha University, New Delhi, India. E-mail: ruchirathore13@gmail.com

Received: 24-Jun-2016; **Revised:** 25-Jul-2016; **Accepted:** 01-Aug-2016; **Online first:** 30-Sep-2016

Copyright: © 2016 Ruchi Rathore, Sonal Sharma, Deepshikha Arora. This is an open-access article distributed under the terms of the Creative Commons Attribution-NonCommercial 4.0 International License (CC BY-NC 4.0).

Funding: This research did not receive any financial support.

Competing Interests: The authors have declared that no competing interests exist.

BACKGROUND: Ovarian tumour in children and adolescent girls form an uncommon but important part of gynaecological malignancies. They account for 1% of all the childhood malignancies and 8% of all abdominal tumours in children. Since the ovarian cysts are thought to arise from mature follicles, these tumours were considered to be infrequent in the paediatric population.

AIM: The rarity of this condition prompted us to conduct this study and share our experience on the incidence and clinicopathological features of different ovarian tumours in girls up to 20 years of age observed in last 25 years at a single tertiary care hospital.

MATERIAL AND METHODS: This was a retrospective study conducted in the Department of Pathology at a tertiary hospital, Delhi. All ovarian tumours up to the age of 20 years in the past 25 years (1990-2014) were included for the purpose of studying the clinicopathological aspects of ovarian tumours in this age group. Descriptive statistics for prevalence and age-wise prevalence was done. Chi-square test, to find an association between the age, laterality and size with malignancy was performed.

RESULTS: We received a total of 1102 cases of ovarian tumours over the period of 25 years (1990 to 2014), of which 112 (10%) cases were seen in girls up to 20 years of age. The mean age of the patients was 15.3 ± 4 years. The most common presenting complaint was pain abdomen (46.4 %). There was a statistically significant correlation found between size and malignancy status of tumours in our study ($p = 0.00$). Of 112 cases of ovarian tumours, 39/112 (34.8%) were malignant and 73/112 (65.2%) were benign. Mature cystic teratoma (27.6%) was the most common type of benign tumour in this age group and immature teratomas were the most common type of malignant ovarian neoplasms.

CONCLUSION: Premenarchal girls with ovarian masses may have varied presentations. Abdominal pain is the most common presenting complaint of young adolescent girls with adnexal masses. So the index of suspicion should be kept high and prompt investigations like ultrasound must be performed early to rule out such adnexal masses. Immature Teratoma was the most common malignant and mature cystic teratoma was the most common benign tumour in our study.

Introduction

Ovarian tumour in children and adolescent girls form an uncommon but important part of gynaecological malignancies. They account for 1% of all the childhood malignancies and 8% of all abdominal tumours in children. It is estimated that almost 10-30% of all the ovarian neoplasms occurring in girls up to 17 years of age are malignant [1, 2]. Tumours of the Ovary are divided into neoplastic and

non-neoplastic processes. While the non-neoplastic conditions include corpus luteal cysts, follicular cysts, and endometriotic cysts, the neoplastic processes include both benign tumours like mature cystic teratomas and highly malignant tumours like yolk sac tumours. According to the literature, paediatric ovarian tumours mostly belong to the group of germ cell tumours in contrast to the tumours occurring in the adult females, which are mostly surface epithelial in origin [3]. Since the ovarian cysts are thought to arise from mature follicles, these tumours were considered to be infrequent in the paediatric population.

The rarity of this condition prompted us to conduct this study and share our experience on the incidence and clinicopathological features of different ovarian tumours in girls up to 20 years of age observed in last 25 years in our tertiary care hospital.

Material and Methods

The study was conducted in the department of pathology at a tertiary hospital, Delhi. All ovarian tumours up to the age of 20 years received in the Dept. of Pathology in the past 25 years (1990-2014) were included for the purpose of studying the clinicopathological aspects of ovarian tumours in this age group. Clinical features like age, laterality, size and stage of the tumour were recorded in the case record form from the pathology archives. For statistical purposes, we included the non-neoplastic cases comprising of corpus luteal cyst, follicular cyst and endometriotic cyst in benign cases. The borderline surface epithelial tumours are included in the malignant category for the same reason. Descriptive statistics for prevalence and age-wise prevalence was done. Chi-square test, to find an association between the age, laterality and size with malignancy was performed.

Results

We received a total of 1102 cases of ovarian tumours over the period of 25 years (1990 to 2014), of which 112 cases were seen in girls up to 20 years of age. This constituted 112/1102 (10%) of all the ovarian tumours received so far. The mean age of the patients was 15.3 ± 4 years (range 1.5 years – 20 years). Figure 1 shows the age wise distribution of benign and malignant tumours in our study. It was seen that while the incidence of benign and malignant tumours was similar to 14 years of age, it was much higher for both, in girls more than 15 years of age. However, there was no statistically significant association between age and malignancy status of the patients (p = 0.122) (Figure 1).

The most common presenting complaint was pain abdomen (46.4 %) followed by lump abdomen (24%) and abdominal distension (10.7%) (Figure 2). While a majority of the patients presented with vague abdominal pain there were 7 patients who presented as acute pain abdomen in the emergency outpatient ward. These patients were later found to have either twisted (5) or ruptured (2) ovarian cyst. On histopathological examination, it was seen that 4/5 mature cystic teratomas (mct) and 1 dysgerminoma

presented as torsion while 1 mucinous cystadenoma and 1 mct presented with a ruptured cyst. While 4 cases of torsion occurred on the right side the remaining 3 occurred on the left side.

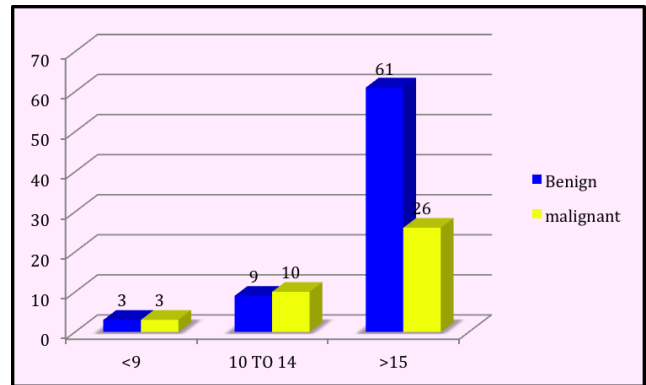


Figure 1: Frequency of benign and malignant tumours in different age group in our study

There were 4 patients who were incidentally diagnosed by the clinicians, 2 of these patients had torsion of the ovarian cyst but were clinically diagnosed as acute appendicitis with peri appendicitis by the department of surgery however later during the surgery they were found to have ovarian masses. The other 2 patients diagnosed incidentally were at gestational ages of 20 weeks and 25 weeks respectively and their ovarian masses were detected on prenatal sonography which was then later removed surgically. Seven of 39 patients with malignant neoplasm gave a history of anorexia and weight loss.

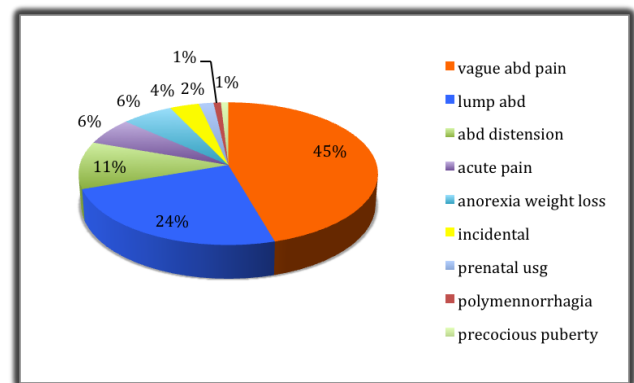


Figure 2: Frequency distribution of various presenting complaints in our study

In this study, 85/112 (75%) were Hindus, 23 Muslims and 4 others including Christians, Sikhs etc. There was no statistically significant correlation between the malignancy status and religion of the patient.

We categorised the gross findings into size laterality, and cut surface [solid/cystic (unilocular or multilocular)/solid and cystic] of the masses, as shown in Table 1. The size was further subdivided into 3 categories of less than 9 cm, 10-14 cm and >15 cms

(Table 1). It was noted that a majority of masses measuring less than 10 cm (48/112) were benign whereas those measuring 10-14 cm were predominantly malignant (23/112) cases. Surprisingly however masses measuring > 15 cm were almost equal (7) for benign and (9) malignant tumours. There was a statistically significant correlation found between size and malignancy status of tumours in our study ($p = 0.00$).

Laterality of each tumour was also recorded from the case record forms and it was seen that there was no statistically significant correlation found between laterality and malignancy status of tumours in our study ($p = 0.71$). Only one case of bilateral mature cystic teratoma was found in this study (Table 1).

Gross appearance of tumours was correlated with histopathological type in our study (Table 1). The majority of our cases were unilocular (62 cases i.e. %) which included mostly benign cystic teratoma, serous cystadenoma, mucinous cystadenoma, corpus luteal cyst, follicular cyst and endometriosis cyst. Multilocular cystic tumours were found in 7 cases of which most were benign cystic teratoma (4) followed by serous cystadenoma (2) and borderline mucinous tumours (1). Forty cases of solid or solid cystic / variegated tumours were found of which 37 cases were malignant and the remaining 3 were benign (fibroma).

Table 1: Frequency distribution of size, laterality, gross findings and treatment choices in our study

Size distribution of ovarian tumours		
Size	Benign	Malignant
<10	48	7
10 to 15	18	23
>15	7	9
Laterality distribution of ovarian tumours		
Laterality	Benign	Malignant
Right	34	17
Left	38	22
Bilateral	1	
Gross findings of ovarian tumours		
Gross	Benign	Malignant
Cystic	62	-
Unicystic	62	-
Multicystic	5	2
Solid-cystic	6	37
Treatment choices of ovarian tumours		
Type of treatment	Benign	Malignant
Cystectomy	70	2
Unilateral salpingo-oophorectomy	20	15
Bilateral cystectomy	1	
Total abdominal hysterectomy with bilateral salpingo-oophorectomy		4

Table 2 shows the age wise histopathological distribution of 112 cases of ovarian tumours, of which 39/112 (34.8 %) were malignant and 73/112 (65.2%) were benign. Whereas the incidence of benign ovarian tumours (47.8%) was marginally lower to malignant ovarian tumours (52.1) in premenarchal girls up to 14 years of age, 69.6% of the tumours were benign and the remaining 30.3% were malignant in girls >15 years of age. 52.6% of all the ovarian tumours occurring in our study population were germ cell tumours. Malignant tumours in girl's up to 20 years of age constituted 3.5% (39/1102) of all the ovarian tumours received so far in our study. 71.1% of

all the malignant tumours occurring in our study were germ cell tumours. It was seen that of the 73 benign neoplasms, mature cystic teratoma (27.6%) was the most common type of tumour in all age groups followed by serous cystadenoma and mucinous cystadenoma which were exclusively seen in girls >15 years of age in this study. It was further noted that up to 14 years of age, germ cell tumours were the most common type of ovarian tumours apart from a single case of granulosa cell tumour seen in 10-14 years of age. However, after 15 years of age, the incidence of surface epithelial tumours (34%) was only marginally higher as compared to the germ cell tumours (33%). All the cases of corpus luteal cysts, endometriotic cysts and follicular cysts were also seen in the age group of 15 to 20 years of age. 6 cases seen in the age group of 0 to nine years were all germ cell tumours.

Table 2: Age-wise distribution of ovarian tumours in our study

Histopathological type of tumour		<9	0-14	>15
Germ cell tumour				
Benign	Mature cystic teratoma	3	8	20
Malignant	Immature teratoma	1	3	5
	Yolk sac tumour	2		1
	Dysgerminoma		2	6
	Mixed germ cell tumour		3	5
Surface epithelial tumours				
Serous	Benign			21
	Borderline			2
	Malignant			-
Mucinous	Benign			11
	Borderline			2
	Malignant			1
Endometrioid adenocarcinoma				1
Sex cord stromal tumours				
	Granulosa cell tumours		1	1
	Sertoli-Leydig cell tumours			2
	Sclerosing stromal tumour			1
Non-neoplastic lesions of ovary				
	Corpus lutein cyst			2
	Simple cyst			6
	Endometriotic cyst			2

Amongst the 39 malignant cases, immature teratomas, constituting 8% of all ovarian masses, were the most common type of malignant ovarian neoplasms. Most of the malignant tumours (28/39; 71%) were seen beyond 15 years of age. While immature teratoma constituted nine cases (8%) and is observed in all age groups, dysgerminomas (8) were seen in girls more than 9 years of age. Immature teratoma was the most common GCT in our study. There were 6 malignant cases of surface epithelial origin (4 cases of borderline serous/mucinous cystadenoma, 1 mucinous cystadenocarcinoma and 1 endometrioid adenocarcinoma) and all of them were seen in age group beyond 15 years. One case of Granulosa cell tumour was also seen in the latter age group.

Operations (Table 2) performed were unilateral salpingo-oophorectomy ($n = 35$), cystectomy ($n = 72$) and unilateral salpingo-oophorectomy with contralateral biopsy ($n = 2$). Two patients had an incidental appendectomy. Total abdominal hysterectomy with bilateral salpingo-oophorectomy was done in 4 cases of stage 4 malignant cases including mixed germ cell tumour, mucinous

cystadenocarcinoma and yolk sac tumour. Patients with yolk sac tumors (n = 2), immature teratomas (n = 2) and mixed germ cell tumor had elevated alpha-fetoprotein (AFP) levels (from >350 ng/ml to 12340 ng/ml), and one patient with dysgerminoma had raised serum LDH levels (2203 IU/L).

Discussion

Ovarian tumours in young girls are uncommon, but when present they are a source of much anxiety to the patients and their families, as the management of these tumours directly affect the fertility of these girls. It is known that at puberty when menarche begins there are changes in the hormonal levels of the hypothalamus, pituitary gland, and ovaries, so these girls are predisposed to the development of various ovarian masses at puberty [4]. According to Harlan et al, menarche occurs at the age of 9.1 to 17.7 years with a mean age of 13 years [5]. In our study, patients ranged in age from 1.5 years to 20 years, with a mean age of 15.3±4 years at the time of presentation.

Adnexal masses in this age group may present in various ways like pain abdomen, lump abdomen or abdominal distention. According to the literature, abdominal pain is the most common symptom of premenarchal ovarian masses. In our study abdominal pain (45.5%) was the most common presenting symptom in concordance with the study by Ki EY et al where the incidence was an abdominal pain (47.7%), palpable abdominal masses (24.6%), incidental ultrasonographic findings (4.6%), and precocious puberty (6.2%). However, in our study one case of granulosa cell tumour presented with precocious puberty (0.89%) and in 4 patients (3.57%) it was incidental finding discovered on prenatal ultrasonography [4].

It is thought that paediatric patients are more prone to ovarian torsions due to a longer infundibulopelvic ligament [6]. Brandt ML reported that ovarian torsions are more common on the right side and are thus often misdiagnosed as acute appendicitis before surgery [7]. In our study, 6% of the patients presented with acute abdominal pain in the emergency OPD due to torsion of the ovarian cyst. Of these 2 were misdiagnosed as acute appendicitis before surgery. The appendectomy specimens sent along with were histopathologically reported as a vermiform appendix in both the cases. The adnexal torsions on the left side are still under controversy for being less common than the right side. It is unclear whether the sigmoid colon helps prevent left adnexal torsion or whether these sided torsions are more commonly missed and managed non-surgically [8, 9]. However, in our study, we had 4 cases on the right

side and 3 cases on the left side. Unlike Kandasamy Vijayalakshmi et al. [10] who reported mucinous cystadenoma to be the most common ovarian tumour undergoing torsion we found that mct was the most common tumour to undergo torsion in our study was mct.

Regarding gross features in our study cases, 111 cases were unilateral and only a single case of mature cystic teratoma was bilateral. Solid or solid-cystic ovarian masses are generally indicative of malignancy. In our study, we got 43 cases of solid/solid cystic cut surface, 37 of which were malignant. Five of the remaining 6 benign tumours were mature cystic teratoma and the other was an endometriotic cyst.

Ovarian malignancy accounts for 1% of all the childhood tumours in the previous studies but some studies like Oumachigui et al, 1991 and Sawai MM et al, 1973 found the incidence to be as high as six per cent and 11.2% respectively [2, 11, 12]. In the study conducted by Bren JL et al it was reported that 35% of all ovarian neoplasms in childhood and adolescent were malignant (Bren JL et al, 1977) [13]. In accordance with this study, we also found that 34.8% of all the ovarian tumours in our study were malignant. This was in contrast to Ehren et al. who found that 60 – 85% of all the ovarian neoplasm in Pediatric age group in their study were of germ-cell origin [2, 14]. Although Germ cell tumour was the most common malignant ovarian neoplasm in our study accounting up to 71.1% of all the malignant tumours of the ovary occurring in this age group. While immature teratoma was the most common malignant germ cell tumour in our study, dysgerminoma was most common in the studies conducted by Bhattacharyya, et al. and Mukhopadhyay et al [2,15] from India.

We found that though the incidence of surface epithelial tumours was almost equivalent to germ cell tumours in this study. In contrast to the study by Graspas D, et al, 2006 which reports the incidence of surface epithelial tumours in the prepubertal age group and adolescent age group is usually 15 - 20% we found this incidence to be 33.9% [16]. This finding could possibly be explained by the fact that our study population included girls up to 20 years of age when a lot of girls have achieved menarche and are already going through the various hormonal surges giving rise to these tumours.

Sex cord stromal tumours though uncommon can also develop in premenarcheal girls. They constitute 10%-25% of all paediatric ovarian neoplasms [4]. Granulosa cell tumours are the most common form of sex cord tumours and are frequently associated with hyperestrogenism or precocious puberty [17-19]. In our study, we had an equal incidence of granulosa cell tumour and Sertoli Leydig cell tumour (1.7%) but only 1 patient presented with precocious puberty.

Since this is a retrospective analysis, close follow-up for benign cases was not necessary where involvement was only unilateral. The only case of benign bilateral mature cystic teratoma had undergone bilateral cystectomy. But patients having malignant ovarian tumours needed follow-up regarding appropriate therapy and survival. However, since the population our hospital caters belong to far off rural destinations, follow up becomes difficult as most of these patients do not revert back for postsurgical treatment. So far, we could retrieve records for only 10 cases of malignant ovarian tumours who attended follow-ups. It was observed that six out of eight dysgerminoma cases of patients in stage I-A survived till date and other two cases lost to follow-up. One case of mixed germ cell tumour and mucinous cystadenocarcinoma who were stage 4 at presentation did not survive. Subjects having other mixed germ cell tumours were advised appropriate treatment, but unfortunately, most of them lost follow-up.

In conclusion, premenarchal girls with ovarian masses may have varied presentations. Abdominal pain is the most common presenting complaint of young adolescent girls with adnexal masses. So the index of suspicion should be kept high and prompt investigations like ultrasound must be performed to rule out such adnexal masses. Immature Teratoma was the most common malignant and mature cystic teratoma was the most common benign tumour in our study. Though germ cell tumours are the most common ovarian neoplasms in adolescent girls, the higher incidence of surface epithelial tumours in our study could not be disregarded. This was possibly because of our inclusion criteria of age up to 20 years when fair numbers of girls have already achieved menarche.

References

1. Alobaid AS. Mucinous cystadenoma of ovary in a 12-yearold girl. *Soudi Med J*. 2008;29:126-8.
2. Bhattacharyya NK, De A, Bera P, Mongal S, Chakraborty S, Bandopadhyay R. Ovarian tumors in pediatric age group- A clinicopathologic study of 10 years' cases in West Bengal, India. *Ind J Med Paed Oncol*. 2010;31(2):54-7. <http://dx.doi.org/10.4103/0971-5851.71656> PMID:21209765 PMCID:PMC2970935
3. Lack EE, Goldstein DP. Primary ovarian tumors in childhood and adolescence. *Curr Probl Obstet Gynecol*. 1984;8:1.
4. Ki EY, Byun SW, Choi YJ, Lee KH, Park JS, Lee SJ, Hur SY. Clinicopathologic review of ovarian masses in Korean premenarchal girls. *International journal of medical sciences*. 2013;10(8):1061. <http://dx.doi.org/10.7150/ijms.6216> PMID:23801894 PMCID:PMC3691806
5. Harlan WR, Harlan EA, Grillo GP. Secondary sex characteristics of girls 12 to 17 years of age: the US health examination survey. *J Pediatr*. 1980; 96(6):1074-8. [http://dx.doi.org/10.1016/S0022-3476\(80\)80647-0](http://dx.doi.org/10.1016/S0022-3476(80)80647-0)
6. Shim SI, Hur SY, et al. Clinicopathological observation on ovarian tumors in premenarcheal years. *Kor J Obstet Gynecol*. 1998; 41(8): 2072-9.
7. Brandt ML, Luks FI, Filiatrault D, Garel L, Desjardins JG, Youssef S. Surgical indications in antenatally diagnosed ovarian cysts. *J Pediatr Surg*. 1991; 26(3): 276-82. [http://dx.doi.org/10.1016/0022-3468\(91\)90502-K](http://dx.doi.org/10.1016/0022-3468(91)90502-K)
8. Cass DL, Hawkins E, Brandt ML, et al. Surgery for ovarian masses in infants, children, and adolescents: 102 consecutive patients treated in a 15-year period. *J Pediatr Surg*. 2001; 36(5): 693-9. <http://dx.doi.org/10.1053/jpsu.2001.22939> PMID:11329568
9. Quint EH, Smoth YR. Ovarian surgery in premenarchal girls. *J Pediatr Adolesc Gynecol*. 1999; 12: 27-9. [http://dx.doi.org/10.1016/S1083-3188\(00\)86617-6](http://dx.doi.org/10.1016/S1083-3188(00)86617-6)
10. Vijayalakshmi K, Reddy GM, Subbiah VN, Sathya S, Arjun B. Clinicopathological profile of adnexal torsion cases: a retrospective analysis from a tertiary care teaching hospital. *J Clin Diagn Res*. 2014 Jun 1;8(6).
11. Oumachigui, Narasimhan KL, Reddy KS. et al. A clinicopathologic study of ovarian tumors in children. *J Obstet Gynecol*. 1991;140:441-5.
12. Sawai MM, Sirsat MV. Ovarian neoplasm in children and adolescents. *Indian J Cancer*. 1973;10:302-11. PMID:4362177
13. Bren JL, Maxon WS. Ovarian tumors in children and adolescents. *Clin Obstet Gynecol*. 1977;20:607-23. <http://dx.doi.org/10.1097/00003081-197709000-00010>
14. Ehren IM, Mahour GH, Issacs H Jr. Benign and malignant ovarian tumors in children and adolescents: A review of 63 cases. *Am J Surg*. 1984;147:339-44. [http://dx.doi.org/10.1016/0002-9610\(84\)90163-6](http://dx.doi.org/10.1016/0002-9610(84)90163-6)
15. Mukhopadhyay M, Shukla RM, Mukhopadhyay B, et al. Ovarian cysts and tumors in infancy and childhood. *Journal of Indian Association of Pediatric Surgeons*. 2013;18(1):16-19. <http://dx.doi.org/10.4103/0971-9261.107010> PMID:23599577 PMCID:PMC3628238
16. Graspa D, Kairi-Vassilatou E, Hsiakos D, Kondi-Pafiti A. Ovarian Mucinous cystadenoma with extended calcification in an 11-year old girl: Case report and review of literature. *Clin Exp Obstet Gynecol*. 2006;33:181-2.
17. Moss EH, Carty H, Sprigg A. A retrospective study of large ovarian masses in paediatric practice. *Eur J Radiol*. 1993; 17(3): 159-65. [http://dx.doi.org/10.1016/0720-048X\(93\)90096-6](http://dx.doi.org/10.1016/0720-048X(93)90096-6)
18. Al Jama FE, Al Ghamdi AA, Gasim T, Al Dakheel SA, Rahman J, Rahman MS. Ovarian tumors in children and adolescents--a clinical study of 52 patients in a university hospital. *J Pediatr Adolesc Gynecol*. 2011; 24(1): 25-8. <http://dx.doi.org/10.1016/j.jpag.2010.06.005> PMID:20709583
19. Skinner MA, Schlatter MG, Heifetz SA, Grosfeld JL. Ovarian neoplasms in children. *Arch Surg*. 1993;128: 849-54. <http://dx.doi.org/10.1001/archsurg.1993.01420200023004> PMID:8343057