

Endoscopic Anatomy and Features of Anterior Cervical Foraminotomy by Destandau Technique

Keyvan Mostofi^{1*}, Reza Karimi Khouzani²

¹Department of Neurosurgery, Centre Clinical, Chirurgie de Rachis, Soyaux, France; ²Department of Neurosurgery, International Neurosciences Institute, Hannover, Germany

Abstract

Citation: Mostofi K, Khouzani RK. Endoscopic Anatomy and Features of Anterior Cervical Foraminotomy by Destandau Technique. Open Access Maced J Med Sci. <http://dx.doi.org/10.3889/oamjms.2016.106>

Keywords: Anterior cervical foraminotomy; cervical disk herniation; minimally invasive spine surgery; endoscopic surgery.

***Correspondence:** Keyvan Mostofi. Department of Neurosurgery, Centre Clinical, Chirurgie de Rachis, Soyaux, France. E-mail: keyvan.mostofi@yahoo.fr

Received: 14-Sep-2016; **Revised:** 15-Oct-2016; **Accepted:** 20-Oct-2016; **Online first:** 22-Nov-2016

Copyright: © 2016 Keyvan Mostofi, Reza Karimi Khouzani. This is an open-access article distributed under the terms of the Creative Commons Attribution-NonCommercial 4.0 International License (CC BY-NC 4.0).

Funding: This research did not receive any financial support.

Competing Interests: The authors have declared that no competing interests exist.

BACKGROUND: Minimally invasive spine surgery limits surgical trauma and avoids traditional open surgery so in the majority of cases, recovery is much quicker and patients have less pain after surgery.

AIM: The authors describe an endoscopic approach to anterior cervical foraminotomy (ACF) by Destandau's method.

MATERIAL AND METHODS: Anterior cervical foraminotomy by Destandau's method is carried out under general anaesthesia. A 3 cm transverse skin incision is used just slightly past the anterior border of the sternocleidomastoid's muscle laterally. After exposing and dissecting superficial cervical fascia, platysma muscle, and deep cervical fascia, Endospine material designed by Destandau will be inserted. As from this moment, the procedure will continue using endoscopy.

RESULTS: the Endoscopic approach to anterior cervical foraminotomy by Destandau's method offers a convenient access to the cervical foraminal stenosis with fewer complications and negligible morbidity and gives maximum exposure to discal space with the goal of minimising cutaneous incision.

CONCLUSION: Contrary to the other minimally invasive approaches, the visual field in foraminotomy by Destandau technique is broad and depending on the workability of Endospine an adequate access to cervical disc is possible.

Introduction

The development of the endoscopic approach to lumbar disc herniation by Destandau in the early 1990s first and then to degenerative cervical spine disorders transformed both the treatment and patients' recovery. Anterior cervical foraminotomy by Destandau technique (ACFD) follows two major principles of minimally invasive surgery which are minimal iatrogenic trauma and extreme efficiency. Due to these two principles, ACFD seems to consider firstly, an adequate size of incision (scar does not exceed 3cm so it is less traumatic and more cosmetic and takes a fast and safe pathway) and secondly, and ensuring adequate target accessibility. Thanks to this minimization, ACFD shortens the recovery of the patient and there is virtually no postoperative restriction. Also, return to professional and sports life is possible in almost all cases. Furthermore, since

then, more than 400 patients underwent surgery using this technique in the Endoscopy Center of Spine Surgery in Bordeaux from 2002 to 2014.

In this paper, we explain in details, endoscopic anatomy and features of anterior cervical foraminotomy by Destandau technique

Material and Methods

The surgery takes place under general anaesthesia. Supine position with the neck in gentle extension and the head held by a horseshoe-shaped pillow is required for this procedure. A preliminary x-ray image is obtained to determine the point of the skin incision and verify the correct level of disk space

once a special localisation device with two arms designed specifically for this purpose is applied. The target disc is centred on the monitor screen of the image intensifier. The localisation device is placed in position and its position modified until the two arms are projected onto the disc (Fig. 1).

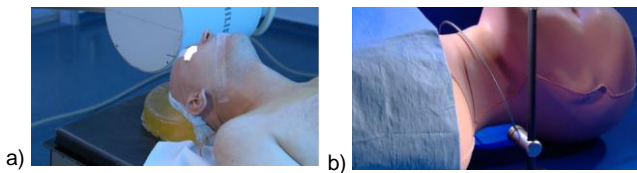


Figure 1: a) Patient position; b) identification of correct level of disc space

Shadowless lighting will be set according to the spotted path of the disc space. This trajectory will guide the surgeon to find the correct level of the disc (Fig. 2).

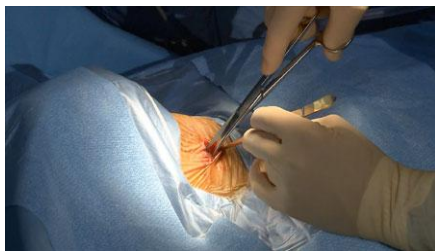

Figure 2: Shadowless lighting will be set according to the spotted path of the disc space

The skin incision is horizontal and approximately 3cm. It runs just slightly past the anterior border of the sternocleidomastoid muscle laterally extending to the midline. Subsequently, the superficial fascia is identified and sectioned. The platysma muscle is divided horizontally and the first layer of the deep cervical fascia is dissected until the omohyoid muscle and the pre-tracheal fascia is exposed. Afterward, the surgeon palpates and identifies the carotid artery by his (her) index and follows dissection superiorly and inferiorly by finger palpation to separate the neurovascular bundle on the outside from trachea and oesophagus inside. This is where anterior cervical spine can be palpated and identified. A Faraboeuf or a Richardson appendiceal retractor is placed medially to explore prevertebral layer of deep cervical fascia longus colli muscles and the anterior longitudinal ligament. An 18-gauge spinal needle is positioned in the looked-for level. A lateral intraoperative radiograph is made to confirm the level. To have access laterally to the ventral surface of the cervical spine and uncovertebral joint, we prefer to coagulate and cut the medial border of longus colli muscle instead of exerting tension on the fascia. We consider that the latter action has a higher risk for the sympathetic trunk located in this fascia, slightly more lateral at the anterior surface of the longus colli muscle, Cloward self-retaining retractors are placed in

the lateral and medial position to protect oesophagus and carotid. From this time on, Endospine will be inserted and will be placed between retractors. Endospine is the material designed by Destandau. It is composed of a speculum and an inner portion. This portion serves to support the endoscope (4 mm) and includes three other channels: one for suction, the other for surgical instruments and the last for root nerve retractor (Fig. 3). The first speculum will be placed.



Figure 3: Endospine with three channels, red arrow for surgical instruments; black arrow for suction; double arrow: for nerve root retractor

The inner portion is attached to the speculum and the rest of the procedure is carried out under endoscopic control. The first instrument used is an endoscopic drill (5 mm diameter 125 length drill). Drilling starts at the level of the disk or slightly above it, following the direction of the disk in an anteroposterior direction. This drilling is extended in order to perform a hole of approximately 8 mm. The soft tissues are resected using a 45° angled Kerrison rongeur or a disk forceps. When the posterior border of a vertebral body is reached and the posterior longitudinal ligament is uncovered bone resection will be expanded laterally using a 45°, 2 mm Kerrison rongeur. At that time, disk herniation will be identified. To get an assurance that there is no adherence between the disk herniation and dural sac, the surgeon can use a hook that can be dragged between the herniation disk and dural sac. After that the disk herniation removed by hook and disk forceps (Fig. 4).

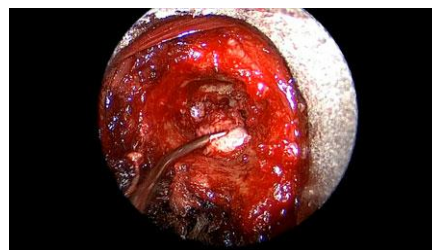

Figure 4: Using a hook, the herniation is dissected and removed by a disk forceps

If any another spinal cord compression by disk fragments is noticed, they will be removed by Kerrison rongeur. The foraminotomy is completed using 4.5 mm diameter 125 length drill and 2 mm Kerrison rongeur. Care must be taken to continue the

foraminotomy from lateral to medial to avoid inadvertent injury to the vertebral artery. The surgeon should be assured that Uncus is sufficiently open.

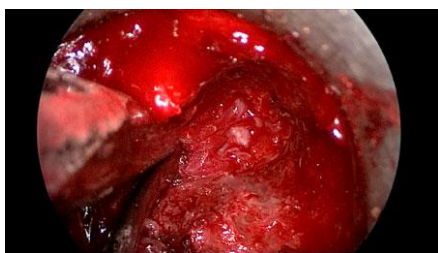

Figure 5: Nerve root is completely decompressed and exposed from the spinal canal to the vertebral artery

The procedure can be considered as being closed after complete exposure and decompression of nerve root from the spinal canal to the vertebral artery. It is not necessary to remove soft tissues adherent to the sheath of nerve because they did not exert any pressure on the nerve and their removal may lead to a dural tear.

Coagulation will be made and Endospine will be removed and the procedure comes to a closure.

Discussion

The anterior approach to the cervical spine for discectomy was described in 1955 by Robinson and Smith [1]. Cloward modified this technique with direct decompression of the spinal cord and nerve root by removal of osteophytes in addition to discectomy. Since then, anterior decompression of cervical spine becomes common place.

Alternative mini-invasive approaches have been developed for cervical discectomy and foraminotomy over the last years of the previous century [2-14]. Endoscopic approach to cervical disc herniation and foraminotomy by Destandau's method gives maximum exposure to discal space with the goal of minimising cutaneous incision. Contrary to the other minimally invasive approaches, the visual field in ACFD is broad and depending on the workability of Endospine an adequate access even to two cervical levels is possible (Fig. 6).

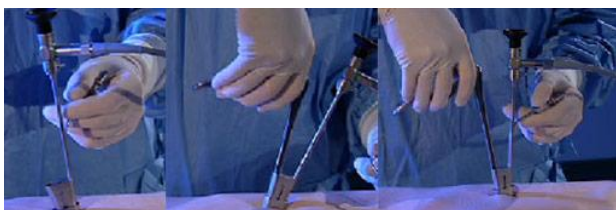

Figure 6: Endospine follows the movements of the instrument, the end of which is permanently in the field of the endoscope and gives a broad visual field

The nerve root is decompressed under direct vision and unlike conventional anterior decompression under the microscope, the surgeon does not need to stop and change the position of the surgical operating microscope. The use of x-ray will be lessened to only two times in the beginning of the intervention and one more time preoperatively to check the level.

Thanks to the particular shape of the speculum, through which the surgery is performed, the risk of anatomical structures injury is minimised. There is no necessary to maintain the retractor when the speculum is placed. In this way the risk of oesophagus and carotid artery injury during foraminotomy must be taken to not injury that. The other advantages of ACFD consist in disc sparing, avoiding fusion, and preserving motion segments. ACFD is logically indicated for foraminal and lateral disc compression, but it can be used for fulfilling adequately spinal cord decompression. ACDF is not indicated in the cases of circumferential disc herniation unless there was foraminal stenosis. Radiculopathy will be often disappeared very soon following surgery. Patients will be lifted the day of the surgery. There are no contraindications to twist the neck. The cervical collar will not be used. Patients will be discharged the day after surgery. The postoperative visit will not be necessary.

More than 400 patients underwent surgery using this technique in the Endoscopy Center of Spine Surgery in Bordeaux from 2002 to 2014. The results, Baseline characteristics will be published shortly in another paper.

References

1. Robinson R, Smith G. Anterolateral cervical disc removal and interbody fusion for cervical disc syndrome. *Bull John Hopkins Hosp.* 1955;96:223-224.
2. Aydin Y, Kaya RA, Can SM, Türkmenoğlu O, Cavusoglu H, Ziyal IM. Minimally invasive anterior contralateral approach for the treatment of cervical disc. *Surg Neurol.* 2005;63(3):210-8. <http://dx.doi.org/10.1016/j.surneu.2004.07.001> PMID:15734502
3. Chiu JC, Clifford TJ, Greenspan M, Richley RC, Lohman G, Sison RB. Percutaneous microdecompressive endoscopic cervical discectomy with laser thermodiskoplasty. *Mt Sinai J Med.* 2000; 67(4):278-82. PMID:11021777
4. Lee SH, Lee JH, Choi WC, Jung B, Mehta R. Anterior minimally invasive approaches for the cervical spine. *Orthop Clin North Am.* 2007;38(3):327-37. <http://dx.doi.org/10.1016/j.ocl.2007.02.007> PMID:17629981
5. Kotilainen E. Percutaneous nucleotomy in the treatment of cervical disc herniation: report of three cases and review. *Minim Invasive Neurosurg.* 1999;42(3):152-5. <http://dx.doi.org/10.1055/s-2008-1053389> PMID:10535300
6. Ruetten S, Komp M, Merk H, Godolias G. Full endoscopic anterior decompression versus conventional anterior decompression and fusion in cervical disc herniations. *Int Orthop.* 2009; 33(6): 1677-1682. <http://dx.doi.org/10.1007/s00264-008-0684-y> PMID:19015851 PMID:PMC2899164

7. Deng ZL, Chu L, Chen L, Yang JS. Anterior transcorporeal approach of percutaneous endoscopic cervical discectomy for disc herniation at the C4-C5 levels: a technical note. *Spine J*. 2016;16(5):659-66. <http://dx.doi.org/10.1016/j.spinee.2016.01.187> PMID:26850173
8. Kim CH, Kim KT, Chung CK, Park SB, Yang SH, Kim SM, Sung JK. Minimally invasive cervical foraminotomy and discectomy for laterally located soft disk herniation. *Eur Spine J*. 2015;24(12):3005-12. <http://dx.doi.org/10.1007/s00586-015-4198-1> PMID:26298479
9. Lee JH, Lee SH. Clinical and radiographic changes after percutaneous endoscopic cervical discectomy: a long-term follow-up. *Photomed Laser Surg*. 2014;32(12):663-8. <http://dx.doi.org/10.1089/pho.2014.3806> PMID:25393058
PMCID:PMC4267406
10. Liu KX, Massoud B. Endoscopic anterior cervical discectomy under epidurogram guidance. *Surg Technol Int*. 2010;20:373-8. PMID:21082589
11. Ding L, Sun T, Huang Y. Minimally invasive approach for cervical spondylotic radiculopathy. *Zhongguo Xiu Fu Chong Jian Wai Ke Za Zhi*. 2010;24(1):104-7. PMID:20135983
12. Kim CH, Chung CK, Kim HJ, Jahng TA, Kim DG. Early outcome of posterior cervical endoscopic discectomy: an alternative treatment choice for physically/socially active patients. *J Korean Med Sci*. 2009;24(2):302-6. <http://dx.doi.org/10.3346/jkms.2009.24.2.302> PMID:19399274
PMCID:PMC2672132
13. Pflum FA, Selby RM, Vizzone JP. Arthroscopic anterior discectomy of the cervical spine. *Arthroscopy*. 2008;24(5):612-4. <http://dx.doi.org/10.1016/j.arthro.2007.08.002> PMID:18442696
14. Tan J, Zheng Y, Gong L, Liu X, Li J, Du W. Anterior cervical discectomy and interbody fusion by endoscopic approach: a preliminary report. *J Neurosurg Spine*. 2008;8(1):17-21. <http://dx.doi.org/10.3171/SPI-08/01/017> PMID:18173342