

# Dental Implantation of Atrophic Jaws Reconstructed with Iliac Bone Graft Crest - Outcome of Seven Cases

Florian Bllaca<sup>1</sup>, Ervin Toci<sup>2\*</sup>

<sup>1</sup>Durrës Regional Hospital, Durrës, Albania; <sup>2</sup>Institute of Public Health, Health Information, Technology and Communication, Tirana, Albania

## Abstract

**Citation:** Bllaca F, Toci E. Dental Implantation of Atrophic Jaws Reconstructed with Iliac Bone Graft Crest - Outcome of Seven Cases. Open Access Maced J Med Sci. 2016 Dec 15; 4(4):709-713. <https://doi.org/10.3889/oamjms.2016.130>

**Keywords:** Albania; alveolar ridge; augmentation; edentulism; iliac bone graft.

**\*Correspondence:** Ervin Toci. Institute of Public Health, Health Information, Technology and Communication, Tirana, Albania. E-mail: [ervintoci@yahoo.com](mailto:ervintoci@yahoo.com)

**Received:** 29-Oct-2016; **Revised:** 05-Nov-2016; **Accepted:** 06-Nov-2016; **Online first:** 24-Nov-2016

**Copyright:** © 2016 Florian Bllaca, Ervin Toci. This is an open-access article distributed under the terms of the Creative Commons Attribution-NonCommercial 4.0 International License (CC BY-NC 4.0).

**Funding:** This research did not receive any financial support.

**Competing Interests:** The authors have declared that no competing interests exist.

**BACKGROUND:** Iliac bone grafts are used to augment alveolar ridges followed by subsequent dental implants in completely edentulous patients. In Albania the information about these issues is scarce.

**AIM:** To describe the procedure of iliac bone grafts augmentation of alveolar ridges and evaluate the survival rate of dental implants in completely edentulous patients in Albania.

**SUBJECTS AND METHODS:** Seven totally edentulous patients (three males, average age 45.9 years) presenting at Durrës Regional Hospital during 2008-2015 and seeking a solution to their problem through implantation procedures were included in the study. Patients were thoroughly examined, evaluated and the best augmentation procedure, using iliac crest bone grafts, and dental implantation technique was chosen. The number of dental implants placed was recorded and their survival rate was calculated.

**RESULTS:** The most common intervention site was maxillae (in 71.4% of cases). Dental implants were installed six months after augmentation, all fixed on the very stable augmented alveolar ridge. On average between 20%-30% of bone grafts, volume was resorbed. Of 37 implants settled, 36 of them or 97.3% survived.

**CONCLUSION:** Iliac bone grafts are a suitable augmentation source of bone in a patient suffering from complete edentulism in Albania. The survival rate of dental implants is very satisfactory.

## Introduction

Complete lack of teeth (edentulism) is rather frequent among human beings, varying considerably according to the age-group of the population studied and ethnicity [1]. Peltzer and colleagues found that the prevalence of edentulism varied from a minimum of 0% to a peak rate of 72% and being higher among older populations [1]. The most common factors associated with increased risk of edentulism, besides age, include disadvantageous socio-demographic and socioeconomic variables (female gender, rural residence, low education, low economic status and health security), some chronic conditions such as diabetes, asthma, high blood pressure and obesity; a

range of risky health behaviors such as smoking, low consumption of fruits and vegetables, inadequate dental care and factors associated with disadvantageous general health, mental health and social support [1].

There are different classifications of edentulous patients such as those offered by Cawood and Howell [2], McGarry and colleagues [3] etc. Cawood and Howell classify the changes in the shape of the alveolar processes of maxillae and mandible ranging from Class I (dentate) to Class VI (depressed rigid form, with some basilar loss) [2]. Class V and VI represent the most severe forms of the condition.

After tooth loss, the alveolar bone reacts through resorptive processes that finally cause loss of

tissue affecting virtually all spatial entities in this region, affecting mostly the structures of mandible than maxillary ones [4]. Bone resorption is attributed to the diminished functional loading at the edentulous ridges even though this theory is not completely proven [5]. General and local factors affect the resorption process including osteoporosis, endocrine disorders, nutritional deficiencies, local vascular changes, diseases of the soft tissue of the mouth, jaw surgeries, traumatic tooth removals, etc. [6,7]. The role of these factors may vary from individual to individual, but anyway, the determinant factor remains the tooth loss for a prolonged period of time.

Loss of teeth could lead to a series of undesirable aesthetic and functional effects, including reduction of total height of face (prognathic face), extreme lowering of labial angle, lips thinning, deepening of nasolabial sulcus, ptosis of mental muscles, collapse of mimic muscles, deepening of columella-filtrum angle, etc. [7]. Substitution or repairing of missing teeth is important as it has a positive effect on the general well-being of the patients, quality of life and reducing health care costs [8-10]. Besides classical removable denture, recent developments can offer edentulous patients fixed implant-based solutions to their problem [11]. Adaptive dental implants techniques have shown to be relatively successful with high survival rates [12, 13]. A review of fixed implant prostheses success rates reported an implant survival rate ranging from 93.4% to 100% and prosthodontic survival rates ranging from 96.3% to 100% [14]. However, the selection of these techniques does not always restore the aesthetic dimensions of the lower third of the face.

Autologous bone grafts from the iliac bone have proven successful for augmentation purposes prior to dental implants in patients with atrophic alveolar ridges [15, 16]. The total atrophic maxilla needs to be reconstructed with a bone block graft to re-establish the facial size and shape and to create the opportunity for dental implant placement. This is because the tonus of the upper lip does not depend on the teeth arch but on the volume of the alveolar process. The right evaluation of these defects caused by bone resorption is very important in order to have an optimal aesthetic result. The anterior iliac crest is a reasonably safe extra oral bone source, which can yield relatively large bone volumes ranging between 70-140 cc. In Albania the information about pre-implant augmentation of alveolar ridges using autologous bone grafts in completely edentulous patients is scarce.

In this context, the purpose of this study was to describe the reconstruction of atrophic jaws with iliac bone graft crest in a series of seven complete edentulous patients and evaluate the success of dental implants following augmentation procedure.

## Subjects and Methods

This is a cross-sectional survey including seven participants. The study subjects showed up in the Durrës Regional Hospital, the second largest hospital in Albania during 2008-2015.

Five patients presented with a severe resorption of maxillae whereas two other participants had a totally atrophic mandible. For the five patients presenting with severe resorption fixed solutions for the upper jaw were taking into consideration. All patients belonged to Class V or VI of edentulism according to the classification by Cawood and Howell [2].

During the clinical examination of the patients, it was noted that they had a considerable loss of the mandible contour, loss of volume of the lower third of the face, prognathic face, significant lowering of a labial angel, deepening of the nasolabial sulcus, ptosis of chin muscles and thinning of the upper lip. As a result, a collapse of mimic muscles had occurred. Two out of seven participants had been carrying removable prostheses for more than ten years.

After clinical examination, it was decided that simple implantation would not be able to restore normal aesthetics of the lower third of the patients' face and therefore the adequate maxillary bone volume had to be restored. The selection of the type of bone graft was done based on the aesthetic and functional evaluation of the lower third of the face. The x-ray examination enabled the specification of the implant position. Using the Cawood and Howell classification criteria [2] the necessary bone volume to achieve the desired augmentation of alveolar processes was determined.

In all cases, the source of the bone was the bio cortical part of the anterior iliac crest maintaining the prior margin in order to avoid any aesthetic defect. For obtaining the iliac bone graft we followed the same technique as described by Grillon and colleagues [17]: "raising the osteoperiosteal flap from the iliac crest and removing a medial cortico-cancellous bone block". The graft was then modelled and split in half leaving the cortical bone in the vestibular side and the cancellous bone in contact with the alveolar process. The alveolar process was decorticated prior the installation of the graft. Graft installation was done in the anterior area until reaching the level of upper first molar teeth. The iliac bone graft was fixed within the alveolar process using titanium screws. A high volume of the iliac bone graft was used and fixed to take into consideration the subsequent relatively high rates of bone resorption when using this type of bone graft. Ultimately, the wound closure was done without causing any tension and releasing flaps until deep into fornix. Dental

implants were installed six months after the augmentation procedure.

The volume of bone loss after augmentation was approximately measured using the 3D panoramic x-ray, by comparing the volume of augmented bone to the volume of bone before implantation.

**Statistical analysis**

Absolute numbers and respective percentages for categorical variables (gender and location of augmentation) as well as mean values and standard deviation for numerical variables (age) were reported.

The number of the dental implants was also reported as well as the number of dental implants that survived.

**Results**

In total seven patients participated in the survey. Three participants were males and the remaining four subjects were females. The average age of the patients was 45.9 years ± 6.5 years and ranging from 35 years old to 54 years old (Table 1)

**Table 1: Baseline characteristics of study subjects**

Study variable	Absolute number	Frequency
Age (years) - mean ± SD		45.9 ± 6.5
Gender		
Male	3	42.9
Female	4	57.1
Total	7	(100.0)

In two patients (or 28.6% of study participants) the intervention location was the mandible, whereas in the five remaining cases it was intervened in the maxilla (Table 2).

**Table 2: Number of dental implants and implant survival among study participants**

No.	Age (years)	Gender	Place of augmentation	Number of implants	Number of implants survived	Dental implants survival rate
1	54	Female	Maxillae	4	4	100%
2	52	Female	Maxillae	6	5	83.3%
3	41	Male	Maxillae	7	7	100%
4	35	Female	Maxillae	5	5	100%
5	48	Male	Mandible	3	3	100%
6	46	Male	Mandible	7	7	100%
7	45	Female	Maxillae	5	5	100%
Total				37	36	97.3%

The installation of dental implants was done six months after the augmentation procedure. In all cases, the dental implants were fixed on a very stable (augmented) alveolar ridge. After the opening of the first flap, it was noted that bone grafts had lost about 20% to 30% of their initial volume but their integrity and healing process was excellent.

In total, there were implanted 37 implants, and only one implant failed. Thus, the overall survival rate of implants was 97.3% (Table 2). In every study participants the success rate of dental implants was 100% and in only one subject (a 52 year old female) the success rate was 83.3% since one out of 6 maxillary implants installed failed (Table 2). In this patient, the procedure of dental implantation was postponed for another three months. In some patients fixed bridges were placed whereas in other patients prosthesis was placed.

Long-term monitoring and check-up of these patients showed very good stability and little bone resorption in all the studied patients. Figure 1 shows a male patient with complete edentulous maxilla followed during intervention, augmentation, implantation and recovery.

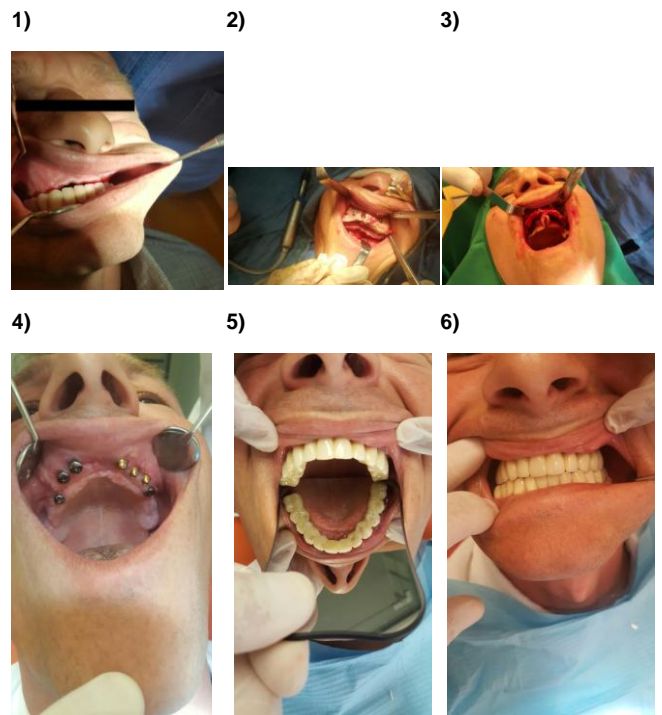


Figure 1: A male patient with complete edentulous maxilla (1); during intervention (2, 3); after implantation (4); recovered (5, 6)

**Discussion**

The present study, including 7 patients suffering from complete edentulism in Albania and showing up at the premises of Durrës Regional Hospital during 2008-2015 for specialised treatment of their condition, aimed to assess the procedures of alveolar augmentation and evaluate the success rate of dental implants. This is the first study scientifically reporting about augmentation procedures in completely edentulous patients in Albania and the

survival rates of dental implants following augmentation procedures. The results of this study suggest that the average age of completely edentulous patients in Albania is about 46 years and the most affected region is the upper jaw (maxilla). In addition, iliac crest bone grafts are suitable for the augmentation of alveolar ridges creating a stable and adequate base for the installation of dental implants. The survival rate of dental implants following augmentation with iliac bone grafts in Albania was high: 97.3%.

The average age of the patients in our study was relatively low. Age is a strong determinant of edentulism and the combination with poor socio-economic conditions [1] could increase the risk of complete tooth loss further. Albania is a developing country with considerable rates of poverty [18] and disadvantageous health care seeking indicators and therefore this could be a risk factor for tooth loss as well. There are no studies in Albania to measure the prevalence of partial or complete tooth loss. In addition, the procedures of bone augmentation and dental implantation are very expensive and unaffordable for the majority of Albanians experiencing partial or complete edentulism. Stomatology procedures are not part of health insurance scheme in Albania and all the associated costs are paid out-of-the-pocket by the patients. This could be a reason for the very few patients presenting with this condition in our hospital resulting in a relatively very small study population. In this context, it is very difficult to reach a definite conclusion and to compare our data with those reported in international literature. In general, higher percentages of males than females seek treatment for edentulism [19]. In our study, there was more female than male patients. Such discrepancy could be due to the very small study population in our survey including only seven patients.

The use of iliac crest bone for the augmentation of large defects of alveolar processes is thoroughly described in the literature [15, 16, 20, 21]. However, autologous grafts from iliac bone exhibit higher bone resorption rate compared to other types of bone grafts or grafts [22], which can be a problem usually requiring augmentation of a larger bone volume in order to take into account the resorption process. In our study, the resorption rate of the bone graft was 20% to 30% compared to the initial augmented volume. These results are similar to those reported in the literature that suggests a resorption rate ranging from 12% to 60% for iliac bone grafts [15]. Bone grafts originating from other locations, such as calvarial bone and chin bone grafts show a lower resorption rate [15]. However, in cases where the alveolar ridge defect or atrophy is severe, a high volume of bone is required and in these cases, the iliac bone offers a better solution. Nevertheless, it should be kept in mind that iliac bone grafts often require extensive surgical interventions requiring

general anaesthesia and bearing the risk of various complications, factors that must be weighed against the benefits of iliac bone grafts compared with other solutions.

The survival rate of dental implants among seven participants included in this study was relatively high, at about 97%. Only one out of 37 implants failed. This result is comparable with success rates of dental implants following augmentation procedures in the international arena. In general, the survival rate of dental implants varies from 95% to 97.5% [23-26]. A study of 24 consecutive patients was 56 implants were installed after augmentation of alveolar ridges with autogenous mandibular bone graft reported that 54 of them (or 96.4%) survived [25]. Adell et al suggested that dental implant survival rates ranged between 89%-98% in the mandible and between 81-82% in maxilla [11]. Several factors could increase the risk of failing of dental implants, including age over 60 years, smoking, diabetes mellitus, neck radiation, post-menopausal oestrogen therapy among females, etc. [27]. The higher the frequency of these factors in the studied populations the higher the likelihood of dental implant failure. However, in our study we couldn't retrieve any information regarding the existing diseases our patients might be suffering from and as a result, due also to the limited number of participants, it was not possible to reach any definite conclusion linking dental implant failure with such conditions.

The average number of implants per patient in our study was 5.3 (37 implants / 7 patients) whereas other international studies reported on average 6.6 implants per patient among totally edentulous patients [11]. The average number of implants among complete edentulous patients is clearly much higher compared with partial edentulous patients. For example, an international study among partial edentulous patients reported on average 1.2 implants per patient [19].

Our study has several limitations. Its cross-sectional nature does not allow drawing definite conclusions about the temporality of events. Furthermore, the small study population and the non-random selection of participants does not allow to generalise the present findings to larger population groups. Therefore, our study might suffer from selection bias. However, the advantage of the present survey is that for the first time it reports on augmentation procedures among completely edentulous patients in Albania and survival rates of dental implants, contributing to highlighting these under-researched topics in this Balkan country. Despite this, future research is needed to be conducted employing larger target populations in order to better understand these processes and to confirm our findings in Albanian settings.

In conclusion, iliac crest bone grafts are suitable for the augmentation of severely damaged or atrophic alveolar ridges in completely edentulous

patients in Albania. If the procedure is carried out carefully and following standard procedures it could create a solid stable bone base on which dental implant could be fixed. The survival rate of dental implants is quite high contributing to the overall satisfaction of patients and probably an improvement of their self-esteem and quality of life.

## References

- Peltzer K, Hewlett S, Yawson AE, Moynihan P, Preet R, Wu F, Guo G, Arokiasamy P, Snodgrass SJ, Chatterji S, Engelstad MW, Kowal P. Prevalence of loss of all teeth (edentulism) and associated factors in older adults in China, Ghana, India, Mexico, Russia and South Africa. *Int J Environ Res Public Health*. 2014;11:11308-24. <https://doi.org/10.3390/ijerph111111308> PMID:25361046 PMCID:PMC4245614
- Cawood JI, Howell RA. A classification of the edentulous jaws. *Int J Oral Maxillofac Surg*. 1988;17:232-6. [https://doi.org/10.1016/S0901-5027\(88\)80047-X](https://doi.org/10.1016/S0901-5027(88)80047-X)
- McGarry TJ, Nimmo A, Skiba JF, Ahlstrom RH, Smith CR, Kounjian JH. Classification system for complete edentulism. *J Prosthodont*. 1999;8(1):27-39. <https://doi.org/10.1111/j.1532-849X.1999.tb00005.x> PMID:10356552
- Peterson's principles of oral and maxillofacial surgery – 3rd ed. (eds. Miloro M, Ghali GE, Larsen PE, Waite PD). People's Medical Publishing House USA, Shelton, Connecticut, 2011:p.123.
- Sun Z, Herring SW, Tee BC, Gales J. Alveolar ridge reduction after tooth extraction in adolescents: an animal study. *Arch Oral Biol*. 2013;58(7):813-25. <https://doi.org/10.1016/j.archoralbio.2012.12.013> PMID:23380583 PMCID:PMC3665758
- Bays RA. The pathophysiology and anatomy of edentulous bone loss. In: Fonseca R, Davis W, editors. *Reconstructive preprosthetic oral and maxillofacial surgery*. Philadelphia:W.B. Saunders, 1985:19-41.
- Starshak TJ. Oral anatomy and physiology. In: Starshak TJ, Saunders B, editors. *Preprosthetic oral and maxillofacial surgery*. St.Louis: Mosby, 1980.
- Weyant RJ, Pandav RS, Plowman JL, Ganguli M. Medical and cognitive correlates of denture wearing in older community-dwelling adults. *J Am Geriatr Soc*. 2004;52:596-600. <https://doi.org/10.1111/j.1532-5415.2004.52168.x> PMID:15066077
- Yu Y-H, Lai Y-L, Cheung WS, Kuo H-K. Oral health status and self-reported functional dependence in community-dwelling older adults. *J Am Geriatr Soc*. 2011;59:519-23. <https://doi.org/10.1111/j.1532-5415.2010.03311.x> PMID:21391942
- Vogel R, Smith-Palmer J, Valentine W. Evaluating the health economic implications and cost-effectiveness of dental implants: a literature review. *Int J Oral Maxillofac Implants*. 2013;28:343-56. <https://doi.org/10.11607/jomi.2921> PMID:23527335
- Adell R, Eriksson B, Lekholm U, Brånemark PI, Jemt T. A long-term follow up study of osseointegrated implants in the treatment of totally edentulous jaws. *Int J Oral Maxillofac Implants*. 1990;5:347-59. PMID:2094653
- Monje A, Chan HL, Suarez F, Galindo-Moreno P, Wnag HL. Marginal bone loss around tilted implants in comparison to straight implants: a meta-analysis. *Int J Oral Maxillofac Implants*. 2012;27:1576-83. PMID:23189313
- Rodriguez-Chessa JG, Olate S, Netto HD, Shibli J, de Moraes M, Mazzonetto M. Treatment of atrophic maxilla with zygomatic implants in 29 consecutives patients. *Int J Clin Exp Med*. 2014;15:426-30.
- Gallucci GO, Morton D, Weber HP. Loading protocols for dental implants in edentulous patients. *Int J Oral Maxillofac Implants*. 2009;24 Suppl:132-46. PMID:19885441
- Kang YH, Kim HM, Byun JH, Kim UK, Sung IY, Cho YC, Park BW. Stability of simultaneously placed dental implants with autologous bone grafts harvested from the iliac crest or intraoral jaw bone. *BMC Oral Health*. 2015;15:172. <https://doi.org/10.1186/s12903-015-0156-x> PMID:26714451 PMCID:PMC4696287
- Faverani LP, Ramalho-Ferreira G, dos Santos PH, Rocha EP, Garcia Júnior IR, Pastori CM1, Assunção WG. Surgical techniques for maxillary bone grafting - literature review. *Rev Col Bras Cir*. 2014;41(1):61-7. <https://doi.org/10.1590/S0100-69912014000100012> PMID:24770776
- Grillon GL, Gunther SF, Connole PW. A new technique of obtaining iliac bone graft. *J Oral Maxillofac Surg*. 1984;42:172-6. [https://doi.org/10.1016/S0278-2391\(84\)80028-2](https://doi.org/10.1016/S0278-2391(84)80028-2)
- World Bank. Albania Program Snapshot, April 2015. World Bank Group Partnership. Available at: <https://www.worldbank.org/content/dam/Worldbank/document/eca/Albania-Snapshot.pdf>. Last accessed: September 2016.
- Fairbairn P, Leventis M. Protocol for Bone Augmentation with Simultaneous Early Implant Placement: A Retrospective Multicenter Clinical Study. *Int J Dent*. 2015; 2015:589135. <https://doi.org/10.1155/2015/589135> PMID:26858757 PMCID:PMC4672140
- Sjöström M, Lundgren S, Sennerby L. A histomorphometric comparison of the bone graft-titanium interface between interpositional and onlay/inlay bone grafting techniques. *Int J Oral Maxillofac Implants*. 2006;21(1):52-62. PMID:16519182
- Shimizu T, Ohno K, Matsuura M, Segawa K, Michi K. An anatomical study of vascularized iliac bone grafts for dental implantation. *J Craniomaxillofac Surg*. 2002;30(3):184-8. <https://doi.org/10.1054/jcms.2002.0299> PMID:12220998
- Chiapasco M, Zaniboni M, Boisco M. Augmentation procedures for the rehabilitation of deficient edentulous ridges with oral implants. *Clin Oral Implants Res*. 2006;17 Suppl 2:136-59. <https://doi.org/10.1111/j.1600-0501.2006.01357.x> PMID:16968389
- Schropp L, Isidor F. Timing of implant placement relative to tooth extraction. *J Oral Rehabil*. 2008;35(Suppl1):33-43. <https://doi.org/10.1111/j.1365-2842.2007.01827.x> PMID:18181932
- Rieder D, Eggert J, Krafft T, Weber HP, Wichmann MG, Heckmann SM. Impact of placement and restoration timing on single-implant esthetic outcome—a randomized clinical trial. *Clin Oral Implants Res*. 2016;27(2):e80-6. <https://doi.org/10.1111/clr.12539> PMID:25496243
- Corinaldesi G, Pieri F, Sapigni L, Marchetti C. Evaluation of survival and success rates of dental implants placed at the time of or after alveolar ridge augmentation with an autogenous mandibular bone graft and titanium mesh: a 3- to 8-year retrospective study. *Int J Oral Maxillofac Implants*. 2009;24(6):1119-28. PMID:20162118
- Nemcovsky CE, Artzi Z. Comparative study of buccal dehiscence defects in immediate, delayed, and late maxillary implant placement with collagen membranes: clinical healing between placement and second-stage surgery. *J Periodontol*. 2002;73(7):754-761. <https://doi.org/10.1902/jop.2002.73.7.754> PMID:12146535
- Moy PK, Medina D, Shetty V, Aghaloo TL. Dental implant failure rates and associated risk factors. *Int J Oral Maxillofac Implants*. 2005;20(4):569-77. PMID:16161741