

# Treatment of Pediatric Open Supracondylar Humerus Fractures: Case Report

Tabet A. Al-Sadek<sup>1\*</sup>, Desislav Niklev<sup>2</sup>, Ahmed Al-Sadek<sup>3</sup>

<sup>1</sup>Department of Orthopaedics and Traumatology, Belhoul European Hospital, Dubai, United Arab Emirates; <sup>2</sup>Orthopaedic and Trauma Clinic, University Multiprofile Hospital for Active Treatment and Emergency Medicine 'N. Pirogov', Sofia, Bulgaria; <sup>3</sup>Medical University, Sofia, Bulgaria

## Abstract

**Citation:** Al-Sadek TA, Niklev D, Al-Sadek A. Treatment of Pediatric Open Supracondylar Humerus Fractures: Case Report. Open Access Maced J Med Sci. 2016 Dec 15; 4(4):680-682.  
<https://doi.org/10.3889/oamjms.2016.133>

**Keywords:** Humerus; Open Supracondylar Fractures; Radiography.

**\*Correspondence:** Tabet A. Al-Sadek, Department of Orthopaedics and Traumatology, Belhoul European Hospital, Dubai, United Arab Emirates. E-mail: drthabet@abv.bg

**Received:** 19-Sep-2016; **Revised:** 05-Oct-2016; **Accepted:** 07-Oct-2016; **Online first:** 15-Nov-2016

**Copyright:** © 2016 Tabet A. Al-Sadek, Desislav Niklev, Ahmed Al-Sadek. This is an open-access article distributed under the terms of the Creative Commons Attribution-NonCommercial 4.0 International License (CC BY-NC 4.0).

**Funding:** This research did not receive any financial support.

**Competing Interests:** The authors have declared that no competing interests exist.

**BACKGROUND:** Open supracondylar fractures of the humerus are rare in children, and the treatment strategy for these fractures is yet to be standardised.

**AIM:** We present the case of a 7-year-old boy with open supracondylar humerus fracture that was managed with an external wrist fixator.

**CASE PRESENTATION:** A 7-year-old boy was brought to our department with pain in the right arm after a fall from a height about 3 hours before admission. On examination, the elbow was found to be markedly swollen with restriction of movement of the right arm. A 4-cm-wide wound was also observed on the flexural aspect of the elbow, indicating severe contamination of the fractured site. Neurological examination revealed restriction of hand movement and decreased sensations, which suggested the possibility of nerve injuries.

**CONCLUSION:** A good clinical outcome was achieved in this case, without the development of any complications over a 6-month follow-up period.

## Introduction

Supracondylar fractures of the humerus are common in children, accounting for 65% of elbow fractures and 3-16% of all paediatric fractures [1]. However, open supracondylar fractures of the humerus are rarely observed in the paediatric age group, and the treatment protocol for these fractures is yet to be standardised [2].

In this report, we present the case of a 7-year-old boy with an open supracondylar humerus fracture that was managed using an external wrist fixator. A good clinical outcome was achieved with this treatment method, without the occurrence of any complications.

## Case report

A 7-year-old boy was brought to our department with pain in the right arm after a fall from a height about 3 hours before admission. On examination, the elbow was found to be markedly swollen with restriction of movement of the right arm. A 4-cm-wide wound was also observed on the flexural aspect of the elbow, indicating severe contamination of the fracture site (Figure 1A). Neurological examination revealed restriction of hand movement and decreased sensations, which suggested the possibility of nerve injuries. Radiography performed at admission showed severe displacement of the right humerus fracture (Fig. 1B, 1C). The fracture was classified as Gartland type IIIb and Gustilo-Anderson type IIIa.

General anaesthesia was induced and wound cleaning and debridement were performed. Further, the fracture was reduced under C-arm X-ray guidance. Two lateral Schanz pins were inserted through the humerus and ulna. An external wrist fixator was attached to the Schanz pins. The right radial nerve was also found to be severely injured, and therefore, the nerve was anastomosed along with the fracture reduction. The patient was administered postoperative antibiotics.

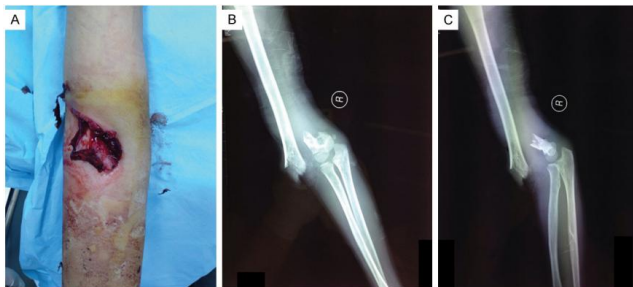


Figure 1: A) Preoperative view of the fracture. The right elbow was markedly swollen. A 4-cm wound is seen on the flexural aspect of the elbow, indicating severe contamination of the fracture site. B) and C) Preoperative radiography shows Gartland type IIIb supracondylar humerus fracture with severe displacement

Radiographic examination was performed every week after the surgery. The patient was encouraged to practice movement of the hand and arm with a static load. The elbow joint was alternatively fixed at the position of maximum flexion or extension after physical therapy every day. The external fixator lock was removed at postoperative week 3. At postoperative week 6, the external fixator was removed. At the follow-up examination, the wound showed signs of primary healing. No radiological or biochemical evidence of infection was obtained during the 6-month follow-up period (Fig. 2A, 2B). At the last follow-up examination, the patient showed radiographic evidence of good union (Fig. 2C, 2D); had a range of movement of 0°-145 at the elbow; and did not have any signs of osteomyelitis or varus or valgus deformity. Informed consent has been obtained from the patient or appropriate persons for publication, including photographs.

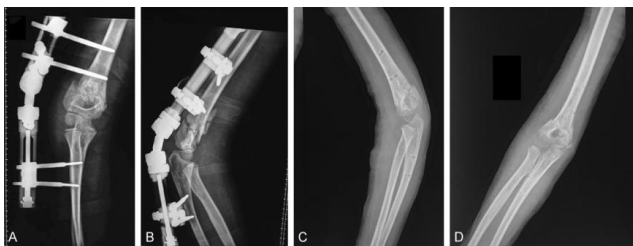

Figure 2: A) and B) Radiography at postoperative week 1 shows a good reduction of the fracture. C) and D) Radiography at postoperative week 6 shows the good union of the fractured ends without any deformities.

## Discussion

The standard treatment protocol for the type I supracondylar humerus fractures in children is conservative management with closed reduction, percutaneous pin fixation, and the application of a long arm cast [2]. However, the treatment for Gartland type III supracondylar humerus fractures in children remains debatable. The American Academy of Orthopaedic Surgeons recommends closed reduction and pin fixation for the management of type II, type III, and displaced supracondylar humerus fractures in children [2]. However, the treatment protocol for open supracondylar humerus fractures in children is yet to be standardised.

Open supracondylar fractures are usually accompanied by severe displacement and extensive vascular and nerve injuries, which cannot be optimally managed with the application of a long arm cast alone. In addition, open fractures are often severely contaminated, whereby the risk of infection remains very high even after thorough wound cleaning and debridement. Therefore, the use of internal fixation in open supracondylar humerus fractures should be avoided because they are associated with an increased risk of infection [3]. Percutaneous pin fixation may also increase the risk of infection in cases of severely contaminated open fractures [4]. The Schanz pin used in external elbow fixators is large and can cause inadvertent iatrogenic fractures in children [5].

Therefore, instead of the external elbow fixator, we used an external wrist fixator, which has smaller Schanz pins that can provide adequate fixation without increasing the risk of infection. Further, since most external elbow fixators are hinged, they prevent the rotation of the forearm. On the other hand, the external wrist fixator used in our case enables movement in multiple planes, which stabilises the fractured humerus. The external wrist fixator offers several advantages to the treatment of open supracondylar humerus fractures in children, including stable fixation for bone union and promotion of the recovery of soft tissues, such as vessels, nerves, and muscles [6]. The use of this device precludes the use of K-wires, thereby minimising the risks of decreased circulation, infection, and osteomyelitis [7].

In addition, the external wrist fixator is light and does not cause much discomfort for the patient. One of the risks associated with the use of the external wrist fixator is a pin-tract infection, which can be managed well with Betadine or povidone-iodine [8]. Another possible complication is fracture displacement because the bone is not directly fixed by the external wrist fixator. Therefore, the weekly radiological examination is recommended to monitor the patient for possible displacement.

In conclusion, we presented a case of paediatric open supracondylar humerus fracture in

which a good clinical outcome was achieved with the use of an external wrist fixator. The patient did not develop any postoperative complications such as osteomyelitis, nonunion, and varus/ valgus deformity and the elbow joint showed a good range of movement. On the basis of our experience in the case, we recommend the use of the external wrist fixator in the management of open supracondylar humerus fracture in children. Further large-scale studies need to be conducted to confirm its safety and efficacy.

## References

1. Otsuka NY, Kasser JR. Supracondylar Fractures of the Humerus in Children. *J Am Acad Orthop Surg.* 1997;5(1):19-26. <https://doi.org/10.5435/00124635-199701000-00003>
2. Mulpuri K, Wilkins K. The treatment of displaced supracondylar humerus fractures: evidence-based guideline. *J Pediatr Orthop.* 2012;32(Suppl 2):S143-52.
3. Pirone AM, Graham HK, Krajchich JI. Management of displaced extension-type supracondylar fractures of the humerus in children. *J Bone Joint Surg Am.* 1988 Jun 1;70(5):641-50. <https://doi.org/10.1097/BPO.0b013e318255b17b> PMID:22890454
4. Flynn JC, Matthews JG, Benoit RL. Blind pinning of displaced supracondylar fractures of the humerus in children. *J Bone Joint Surg Am.* 1974;56(2):263-72. <https://doi.org/10.2106/00004623-197456020-00004> PMID:4375679
5. The Schanz pin used in external elbow fixators is large and can cause inadvertent iatrogenic fractures in children.
6. Kershaw CJ. Children's Orthopaedics (Including Paediatric Orthopaedic Trauma). In *Selected References in Trauma and Orthopaedics*. Springer: London, 2014:pp. 241-272. [https://doi.org/10.1007/978-1-4471-4676-6\\_11](https://doi.org/10.1007/978-1-4471-4676-6_11)
7. Schmidmaier G, Gahukamble AD, Moriarty TF, Richards RG. Infection in fracture fixation: device design and antibiotic coatings reduce infection rates. In *Biomaterials Associated Infection 2013* (pp. 435-453). Springer New York.
8. One of the risks associated with the use of the external wrist fixator is pin-tract infection, which can be managed well with Betadine or povidone-iodine.