

Midshaft Clavicular Fractures - Osteosynthesis with Minimally Invasive Technique

Tabet A. Al-Sadek^{1*}, Desislav Niklev², Ahmed Al-Sadek³

¹Department of Orthopaedics and Traumatology, Belhoul European Hospital, Dubai, United Arab Emirates; ²Trakia University, Faculty of Medicine, Stara Zagora, Bulgaria; ³Medical University, Sofia, Bulgaria

Abstract

Citation: Al-Sadek TA, Niklev D, Al-Sadek A. Midshaft Clavicular Fractures - Osteosynthesis with Minimally Invasive Technique. Open Access Maced J Med Sci. 2016 Dec 15; 4(4):647-649. <https://doi.org/10.3889/oamjms.2016.136>

Keywords: minimally invasive plate osteosynthesis (MIPO); Midshaft Clavicle Fractures; Superior anterior Clavicle Plate.

***Correspondence:** Tabet Al-Sadek, MD, PhD. Belhoul European Hospital, Dubai, United Arab Emirates. Mobile: +971551503964. E-mail: drthabet@abv.bg

Received: 20-Sep-2016; **Revised:** 07-Oct-2016; **Accepted:** 09-Oct-2016; **Online first:** 22-Nov-2016

Copyright: © 2016 Tabet A. Al-Sadek, Desislav Niklev, Ahmed Al-Sadek. This is an open-access article distributed under the terms of the Creative Commons Attribution-NonCommercial 4.0 International License (CC BY-NC 4.0).

Funding: This research did not receive any financial support.

Competing Interests: The authors have declared that no competing interests exist.

BACKGROUND: Fractures of the clavicle are one of the most common fractures in modern orthopaedics and traumatology practice. Knowing the mechanism of trauma, and its pathophysiological elements, it's clear distinction and its individual features are essential to the development of more new and effective methods for their treatment, and the minimising of postoperative complications.

AIM: The aim of this paper was to present the results of our patients treated with minimally invasive plate osteosynthesis (MIPO).

MATERIAL AND METHODS: Between January 2011 and March 2013, 12 patients were treated with MIPO technique. The mean age was 47.5 years (range, 16-79 years). Outcomes and complications of clinical treatment were reviewed.

RESULTS: All fractures healed within a mean period of 4.9 months (range, 2-10 months). Regarding complications, there was no occurrence of implant failure or deep infection. There were no nonunions, but one 79-year-old man had a delayed union. Almost of all the cases didn't need bending of the plate. Seven plates were removed by their hopes. And there weren't any cases that required new incisions.

CONCLUSIONS: A pre-contoured plate anatomically configured to fit the clavicle was easier to apply. MIPO technique for midshaft clavicle fractures may be a good option.

Introduction

The clavicle is a membranous bone [1]. The main arterial supply to the clavicle is primarily periosteal [2]. Therefore, extensive periosteal stripping of the fracture site may cause complications, such as nonunion or infection [3]. Thus we have been performing minimally invasive plate osteosynthesis (MIPO) for displaced midshaft clavicle fractures [4].

The aim of this paper was to present the results of our patients treated with minimally invasive plate osteosynthesis (MIPO).

Materials and Methods

Under general anaesthesia, the patients were placed in a beach chair position. The C-arm was placed to take anteroposterior, oblique, and craniocaudal views of the clavicle. A superior anterior plate (DePuy Synthes, Oberdorf, Switzerland) was inserted. The function of the plate was "bridging plate". C-arm imaging in three positions was used to check fracture reduction. The craniocaudal view was the most important. That view confirmed bridging of the fracture zone in correct alignment with the plate well position to the S-shaped bone [5].

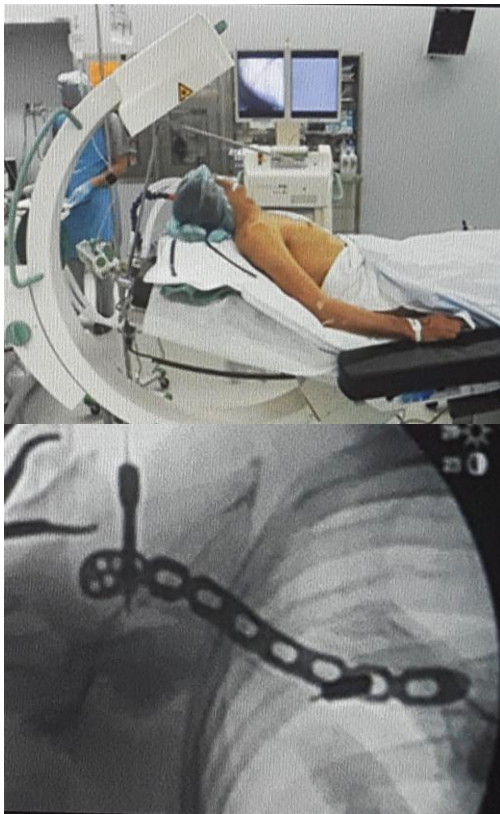


Figure 1: C-arm position of craniocaudal view

Surgical Steps

Surgical steps are shown in Fig. 2 [6]. In general, a) A small longitudinal incision was made at the distal end or proximal end of the clavicle; b) The Platysma were incised; c) Superior Anterior plate was inserted then the incision was made the other side; d) Indirect fracture reduction and temporary fixation with Kirschner wires; e) Then a fracture fixation was performed using the appropriate number of cortical screws and locking head screws; f) Layered closure was performed to repair the platysma (Fig. 2).

Between January 2011 and March 2013, 12 patients were treated with MIPO technique. The mean age was 47.5 years (range, 16-79 years). Outcomes and complications of clinical treatment were reviewed.

Results

All fractures healed within a mean period of 4.9 months (range, 2-10 months). Regarding complications, there was no occurrence of implant failure or deep infection. There were no nonunions, but one 79-year-old man had a delayed union. Almost of all the cases didn't need bending of the plate.

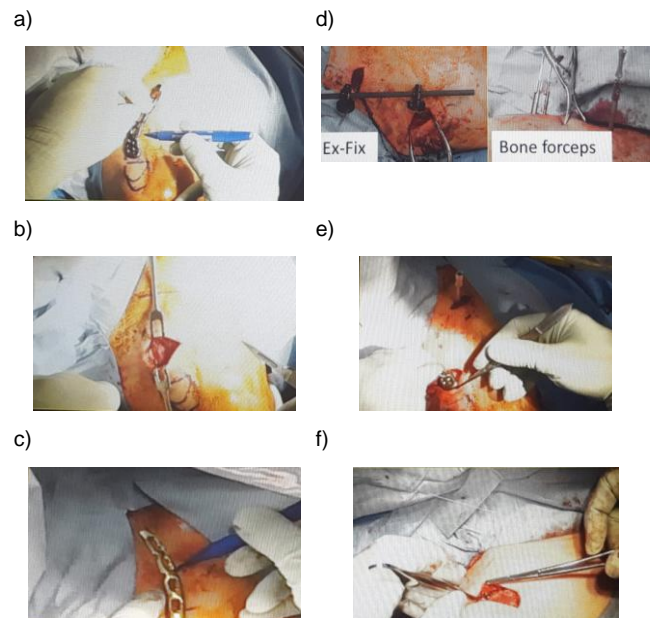


Figure 2: Surgical steps. a) A small longitudinal incision was made at the distal end or proximal end of the clavicle; b) The Platysma were incised; c) Superior Anterior plate was inserted then the incision was made the other side; d) Indirect fracture reduction and temporary fixation with Kirschner wires; e) Then a fracture fixation was performed using the appropriate number of cortical screws and locking head screws; f) Layered closure was performed to repair the platysma

Seven plates were removed by their hopes. And there weren't any cases that required new incisions.

Discussion

Traditionally, clavicle fractures have been treated nonoperatively [7]. However, recent studies have shown a high prevalence of symptomatic malunion and nonunion after nonoperative treatment of midshaft clavicular fractures [8]. Thus, operatively treated cases have increased. However, some complications have been described.

These complications may partly be caused by extensive periosteal stripping of the fracture site [9]. This study aims to assess the outcomes of midshaft clavicular fractures treated by our minimally invasive plate osteosynthesis technique (MIPO) [4].

MIPOs aims to preserve the biology at the fracture site, to maximise the healing potential of the bone, and to facilitate early and pain-free recovery [10]. To accomplish this, the fractures are reduced indirectly.

The clavicle is S-shaped. Thus, conventional plate bending may be difficult. Superior anterior plates have an anatomical design. There are two types of the

plate [11]. So they were very useful (Fig. 3).

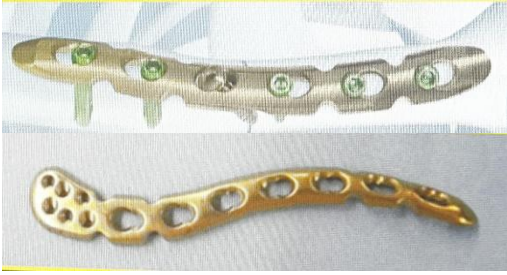

Figure 3: LCP Superior Anterior clavicle plate and LCP with lateral extension

In conclusion, a pre-contoured plate anatomically configured to fit the clavicle was easier to apply. MIPO technique for midshaft clavicle fractures may be a good option.

Reference

1. Steele DG, Bramblett CA. The anatomy and biology of the human skeleton. Texas A&M University Press, 1988.
2. Knudsen FW, Andersen M, Krag C. The arterial supply of the clavicle. *Surgical and Radiologic Anatomy*. 1989;11(3):211-4. <https://doi.org/10.1007/BF02337824> PMID:2588097
3. Zenni EJ, Krieg JK, Rosen MJ. Open reduction and internal fixation of clavicular fractures. *J Bone Joint Surg Am*. 1981;63(1):147-51. <https://doi.org/10.2106/0004623-198163010-00019> PMID:7451517
4. Sohn HS, Shin SJ, Kim BY. Minimally invasive plate osteosynthesis using anterior-inferior plating of clavicular midshaft fractures. *Archives of orthopaedic and trauma surgery*. 2012;132(2):239-44. <https://doi.org/10.1007/s00402-011-1410-6> PMID:22006573
5. Jubel A. Minimally Invasive Operative Treatment of Displaced Midclavicular Fractures with a Titanium Elastic Nail. *Minimally Invasive Orthopaedic Trauma*. 2013:65.
6. Sohn HS, Kim BY, Shin SJ. A surgical technique for minimally invasive plate osteosynthesis of clavicular midshaft fractures. *Journal of orthopaedic trauma*. 2013;27(4):e92-6. <https://doi.org/10.1097/BOT.0b013e31826579c7> PMID:22773015
7. McKee MD, Pedersen EM, Jones C, Stephen DJ, Kreder HJ, Schemitsch EH, Wild LM, Potter J. Deficits following nonoperative treatment of displaced midshaft clavicular fractures. *J Bone Joint Surg Am*. 2006;88(1):35-40. <https://doi.org/10.2106/0004623-200601000-00005>
8. Robinson CM, McQueen MM, Wakefield AE. Estimating the risk of nonunion following nonoperative treatment of a clavicular fracture. *J Bone Joint Surg Am*. 2004;86(7):1359-65. <https://doi.org/10.2106/0004623-200407000-00002> PMID:15252081
9. Neviasser RJ, Neviasser JS, Neviasser TJ, Neviasser JS. A Simple Technique for Internal of the Clavicle: A Long Term Evaluation. *Clinical orthopaedics and related research*. 1975;109:103-7. <https://doi.org/10.1097/00003086-197506000-00013>
10. Shin SJ, Sohn HS, Do NH. Minimally invasive plate osteosynthesis of humeral shaft fractures: a technique to aid fracture reduction and minimize complications. *Journal of orthopaedic trauma*. 2012;26(10):585-9. <https://doi.org/10.1097/BOT.0b013e318254895f> PMID:22534690
11. Schliemann B, Roßlenbroich SB, Schneider KN, Petersen W, Raschke MJ, Weimann A. Surgical treatment of vertically unstable lateral clavicle fractures (Neer 2b) with locked plate fixation and coracoclavicular ligament reconstruction. *Archives of orthopaedic and trauma surgery*. 2013;133(7):935-9. <https://doi.org/10.1007/s00402-013-1737-2> PMID:23589063