

Bone Height Changes of the Mandibular Edentulous Ridge in Screw Retained Versus Telescopic Restorations for Completely Edentulous Patients

Eman Helal^{1*}, Mohamed El-Zawahry¹, Ayman Gouda², Amr Hosny Elkhadem³, Samira Ibrahim Ibrahim³

¹National Research Center, Fixed and Removable Prosthodontics, Cairo, Egypt; ²Faculty of Oral and Dental Medicine, Oral and Maxillofacial Surgery, Cairo University, Cairo, Egypt; ³Egypt Faculty of Oral and Dental Medicine, Prosthodontics, Cairo University, Cairo, Egypt

Abstract

Citation: Helal E, El-Zawahry M, Gouda A, Elkhadem AH, Ibrahim SI. Bone Height Changes of the Mandibular Edentulous Ridge in Screw Retained Versus Telescopic Restorations for Completely Edentulous Patients. Open Access Maced J Med Sci. 2017;10.3889/oamjms.2017.004

Keywords: Dental implants; screw retained; telescopic overdenture; bone height; index area; mandible.

***Correspondence:** Eman Helal. National Research Center, Fixed and Removable Prosthodontics, Cairo, Egypt. E-mail: emangamalrashed@gmail.com

Received: 20-Nov-2016; **Revised:** 18-Dec-2016; **Accepted:** 20-Dec-2016; **Online first:** 18-Jan-2017

Copyright: © 2017 Eman Helal, Mohamed El-Zawahry, Ayman Gouda, Amr Hosny Elkhadem, Samira Ibrahim Ibrahim. This is an open-access article distributed under the terms of the Creative Commons Attribution-NonCommercial 4.0 International License (CC BY-NC 4.0).

Funding: This research did not receive any financial support.

Competing Interests: The authors have declared that no competing interests exist.

AIM: This study was established to evaluate the amount of bone height changes in the posterior mandibular area of edentulous patients receiving screw-retained prostheses versus removable telescopic implant overdentures.

MATERIAL AND METHODS: Every patient received four inter-foraminal implants regarding the mandibular arch and four anterior implants for the maxillary arch, computer guided surgical guides were planned for the insertion of the implants accurately with a flapless technique. Panoramic radiographs were made immediately, six months and twelve months after the prostheses' use proportional area and vertical measurements were applied to determine changes in the bone height of the posterior mandibular edentulous area.

RESULTS: After twelve months, a statistically non-significant amount of bone resorption was reported for both groups.

CONCLUSION: Up to the limitations of this study both treatment options the screw retained and telescopic overdenture can be used for rehabilitation of completely edentulous patients. These cases must be followed for a longer period to have a definite answer regarding their efficiency in the long run.

Introduction

It is well recognised that an edentulous condition has a negative impact on patient's life. Common complaints with conventional dentures are the pain and minimal masticatory efficiency. In combination, these complaints impair function, as well as, lower self-esteem. Recently, Osseointegrated implant-retained prostheses have allowed many patients to improve their quality of life when compared to complete dentures [1-4].

Endosteal implants are the most commonly used. They are manufactured in a variety of widths, lengths, designs and materials [5]. Because of the advantages of the root form implant it is considered the first and most realistic choice on a selection of

implant as it offers wide stress distribution with good retention and easy surgical procedure with fairly good healing [6, 7].

Telescopic crowns are also known as a double crown, crown and sleeve coping. These crowns consist of an inner or primary telescopic coping, permanently cemented or screwed to an abutment, and a congruent detachable outer or secondary telescopic crown, rigidly connected to a detachable prosthesis [8, 9].

The screw-retained implant prosthesis consists of artificial teeth connected to a metal frame work with acrylic resin base. By Usually four to five implants are placed in the anterior region to support a cantilevered prosthesis. The length of the cantilever was supposed to be 1.5 times the anterior-posterior

span, but shorter in poor quality bone. With moderate to advanced jaw resorption, screw retained prosthesis can replace lost bone and soft tissue [10, 11]. Also, this prosthesis offers retention security [8]. Up till now, several trials are going on to find a solution for the problem of edentulous alveolar ridge resorption [12]. The trials are devoted to finding a solution by which ridge resorption can be minimised [13-15].

Alveolar ridge resorption is annoying to both the patient and the prosthodontist; Conventional complete denture wearers are in most of the time unsatisfied by their appliances [14, 16]. The advent of dental implants helped to improve the value of the prostheses that may be removable overdenture, fixed prosthesis or fixed detachable appliances [15, 17].

This study was established to evaluate the amount of bone height changes in the posterior mandibular area of edentulous patients receiving screw-retained prostheses versus removable telescopic implant overdentures.

Material and Methods

This study was a clinical trial (RCT), using cone-beam computed tomography (CBCT) imaging and flapless surgical technique to place four implants in the maxillary and mandibular arches utilising tissue supported computer aid ed surgical guides using MIMICS software.

The study was a part of a group study that was performed on fourteen completely edentulous male patients from the outpatient Clinic of Faculty of Oral and Dental Medicine, Cairo University, Department of Removable Prosthodontics. Each patient received eight implants (four in each arch) and was restored with either a telescopic or a screw-retained prosthesis; however, this study was mainly concerned with the mandibular arch as the maxillary arch was the concern of another colleague of the team.

Ethical approval the study protocol was reviewed and approved by staff members of Prosthodontics Department, Ethics Committee, Evidence-based Dentistry committee in Faculty of Oral and Dental Medicine, Cairo University and staff members of Prosthodontics Department, Ethics Committee in National Research Center Egypt.

The patients were selected from the outpatient clinic of the Faculty of the Oral Dental Medicine, Prosthodontics Department, Cairo University according to the following inclusion and exclusion criteria:

Inclusion criteria

Completely edentulous for at least one year, ages range between 50-70 years; adequate bone thickness examined initially by digital palpation, Covered by the adequate zone of keratinized mucosa, Angle's class I maxillo-mandibular relationship.

Exclusion criteria

The presence of any flabby tissue or pathological lesions that may interfere with the surgical procedures or interfere with the proper seating of the prosthesis Patients with systemic disease that may affect dental implants placement andr osseointegration and alveolar bone resorption e.g. Uncontrolled diabetes, hypertension and osteoporosis, neuromuscular disorders [14, 18-22].

Planning was done using specialised software (Mimics 10.01), The obtained DICOM files were imported into it (Fig. 1).

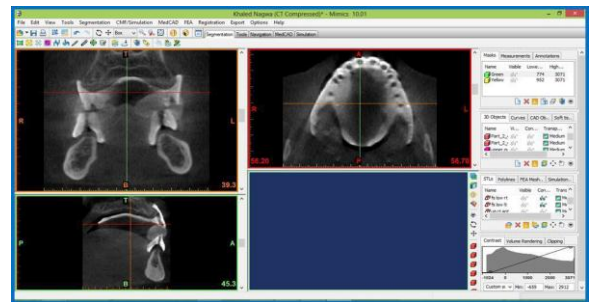


Figure 1: Mimics10.01 interface

The proposed implant sites were the canine and the second premolar (bilaterally) (Fig. 2). These proposed sites were identified by the radiolucent channels, previously prepared in the radiographic templates and were evaluated for sufficient bone height and buccolingual width.

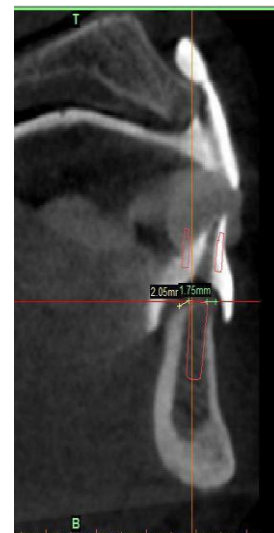


Figure 2: Cross-sectional view showing the distances' measurements around the virtual implants

The proposed implant diameter was 3.75 mm and the proposed length was 10 mm and 12 mm in the posterior and anterior areas respectively. Four virtual implants were placed in each arch, and parallelism between them was checked. Once the positions of implants were accepted in the virtual guide, four holes corresponding to prefabricated metallic sleeves was designed on the MIMICS software.

The virtual implant guide was sent in an STL format to be exported to selective laser sintering (SLS) rapid prototyping machine for guide construction. The sent STL file of the virtual guide was exported into the rapid prototyping machine at the—Central Metallurgic Research And Developing Institutell (CMRDI). The technology used in this study was selective laser sintering [fabricated in a slice-by-slice manner using poly-ether ether-ketone (PEEK)] material. The surgical guide had four holes through which metallic sleeves, with specific dimensions, were fitted through and seated in position, using adhesive [23-26] (Fig. 3).



Figure 3: The fabricated surgical guides

A prophylactic dose of 2 gm of amoxicillin and Ibuprofen 600 mg were prescribed for the patient one hour before the surgery [27]. Root formed, tapered threaded dental implants were prepared before surgery. Four implants were prepared with dimensions 3.75 mm diameter and 10 mm and 12 mm length for the canine and premolar area respectively.

After healing period of four months, the surgical stent was used to relocate the position of the implants using tissue punch. Then permanent transmucosal titanium abutments were fastened into the implant fixtures and torqued up to 35 Ncm using torque ratchet.

Acrylic custom trays were constructed on the study casts with a window cut over each implant. Then impression transfer copings were screwed to the abutment using long fixation screws; then open impression technique was used for the final impression making.

Then the patients were grouped into two groups according to a computerized random allocation program. Allocation concealment was ensured as the randomization table was kept with the

study coordinator. The 1st^t Group Screw retained fixed restoration and the 2nd Group Telescopic removable implant overdentures.

Group, I Screw retained fixed restoration

Acrylic resin verification jig was fabricated for passivity check using the single screw test. The prosthesis was screwed intra-orally with a torque wrench. Finally, the access holes were partially plugged with rubber pieces and completely blocked with light-cured composite resin.

Group II Telescopic removable implant overdentures

The obtained cast was sawed to obtain separate removable dies for the analogue with its anti-rotational plastic cap*attached to it; the die was indicated by ditching and the wax pattern of the primary coping was built up in milling wax.

The obtained cast was modified and duplicated into a refractory cast on which the wax pattern of the metallic framework with the secondary copings was built up as a mesh work covering the residual ridge and slightly shorter than the acrylic resin denture base. The wax pattern of the framework attached to the patterns of the secondary.

Panoramic radiographs were done immediately after prostheses insertion, six months and twelve months after prostheses use. Panoramic radiography was performed with the Scanora, multimodal radiography system and the screen/ film combination Lanex medium/T-mat G (Eastman Kodak Co., Rochester, N.Y., USA). During the radiographic exposure the patients of the screw-retained prosthesis had their prosthesis fixed in the mouth, however, those of the telescopic crowns wear their conventional acrylic complete dentures after their modification to fit the four implants. the exposure was done while the patients were closing in the centric occlusion.

For calculating the amount of ridge resorption two methods were followed:

1-Mandibular bone height measurement: The radiographs were digitised by scanning, and the following lines were drawn (Fig. 4). (MM') Horizontal line tangent to the upper border of the mental foramina, (XA) Vertical line tangent to the distal side of the posterior implant of each side to meet the horizontal line at point A. Five and ten millimetres apart of point A two vertical lines were drawn parallel to (XA) till the top of the alveolar bone border. These three vertical lines were measured, and the mean of them was considered during the statistical analysis of this study. The right and left sides mean values were compared and the degree of bone height resorption

was calculated by subtraction: The mean bone height at twelve months the mean bone height at base line and the mean bone height at six months the mean bone height at base line.

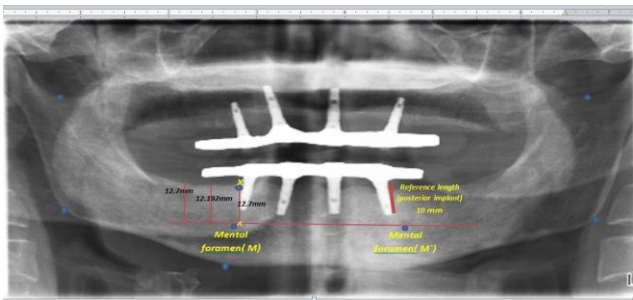


Figure 4: Mandibular bone height measurement

II-Proportional area measurement: This method is similar to that used by Wright et al. 2002 [12] using proportions that minimise errors related to magnification and distortion. The radiographs were digitised by scanning and tracing was done using AutoCAD computer program.

The anatomical landmarks: (Fig. 5) M (lower border of mental foramen), S (sigmoid notch) and G (gonion). These three landmarks were used to construct the triangles on the right side (M-S-G) and left side (M'-S'-G') of the mandible. N (centre of the triangle) (Fig. 6). Center of the triangle If a line was drawn from each corner (or vertex) of a triangle to the midpoint of the opposite sides, then those three lines meet at a centre, or centroid, of the triangle.

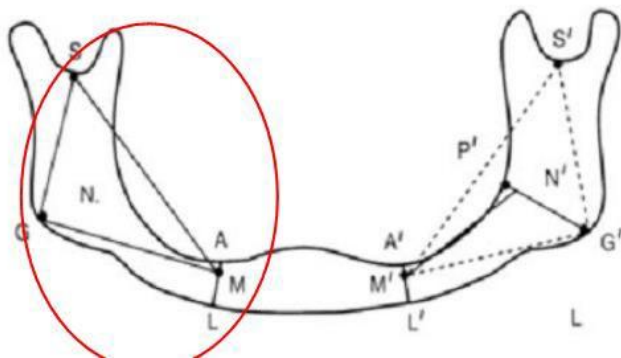


Figure 5: The tracing anatomical landmarks

Boundaries were constructed by the following lines: The boundary line M G, The boundary line A-L; a line from the crest of residual ridge (point A) to the lower border of the mandible (point L) through M perpendicular to M-G, the boundary line M-N and the boundary line G-P; the line G-N extended to the crest of the residual ridge through point P.

The experimental bone area was eventually outlined by the area PAMG and the reference area of the triangle MGN (Fig. 6). The Posterior Ridge Ratio was calculated by dividing the anatomic bone area

(PAMG) by the reference area (MNG), the ratios for the right and left side in each patient were averaged. The change in the posterior mandibular ridge ratio was calculated by subtracting (the ratio at twelve months the ratio at the base line) and subtracting (the ratio at six months the ratio at the base line).

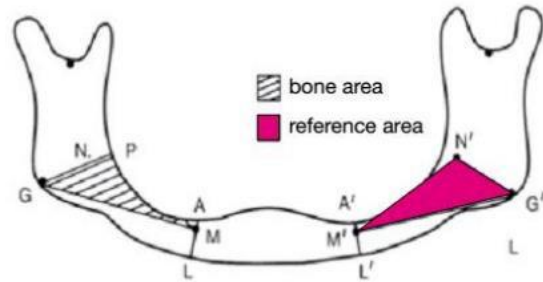


Figure 6: The boundaries of the bone area and reference area

Results

This study started with fourteen patients; however, twelve patients attended the six and twelve months follow-up recall visits after prostheses use. There was a drop out of two patients at both groups one patient has died group II (telescopic overdenture group), and another one was in a group I (screw retained) didn't attend the follow-up appointment. During the different follow-up periods alveolar bone ridge reduction was recorded in both groups but in different degrees. When comparing the mean values of alveolar bone height loss in the right and left sides for each patient in the two groups no statistically significant difference was observed during the different follow-up periods. Therefore the mean values of the decrease of bone height of the right and left sides of the posterior mandibular edentulous ridge were added to represent the mean bone height decrease in each group during the different follow-up periods: Base line (immediately on prostheses' delivery), 1st follow-up (6 months), and 2nd follow-up (12 months).

For the description of the data, the mean values and standard deviations were calculated for proportional areas of the posterior mandibular ridge height at the different three timings and then the changes in posterior ridge height at the different three timings.

For all tests: Data presented as mean and standard deviation (SD) values. Data checked for normality using student t-test, Statistical analysis was performed with IBM® SPSS® (SPSS Inc., IBM Corporation, NY, USA) Statistics Version 23 for Windows.

The mean values and standard deviation of the measurements of the posterior mandibular ridge height were 12.87 ± 2.3 mm, 12.37 ± 2.1 mm and 12.31 ± 2.4 mm at baseline, 1st follow-up, and 2nd follow-up respectively. For Group II (Telescopic overdenture): The mean values and standard deviation of the measurements of the posterior mandibular ridge height were 11.78 ± 2.7 mm, 11.71 ± 2.2 mm and 11.68 ± 1.95 mm at baseline, 1st follow-up and 2nd follow up respectively that showed slight higher bone loss in (group I) than (group II) but it remains non-significant (p value > 0.05) (Fig. 7).

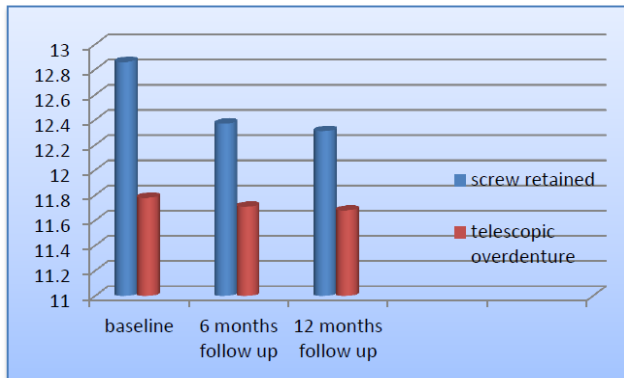


Figure 7: Chart representing the difference between of the measurements of the posterior mandibular ridge height for both groups at the different follow-up periods

The bone height measurements were recorded at baseline, six months and 12 months. The mean bone height loss for Group I Screw retained from base line to the 1st follow-up was 0.33 ± 0.11 mm², from 1st follow-up to 2nd follow-up was 0.12 ± 0.09 mm² and from baseline to the second follow-up was 0.45 ± 0.12 mm². On the other hand, the mean bone height loss for Group II telescopic overdenture was 0.21 ± 0.05 mm² from base line to the 1st follow-up, 0.15 ± 0.29 mm² from 1st follow-up to 2nd follow-up and 0.36 ± 0.16 mm² from baseline to the second follow-up i.e. the bone loss was higher also in group I than in group II but statistically non-significant with (p -value > 0.05) (Fig. 8).

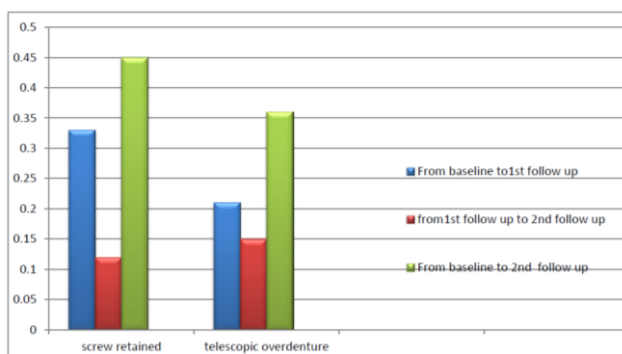


Figure 8: Chart representing comparison between Mean bone height changes for both groups at different follow-up periods

Discussion

In this study, all factors that could affect implant osseointegration, bone height changes and the health of the residual ridge were carefully considered during patient selection and later on after restoration. These factors could be biological or mechanical and most probably both together. The biological factors could be related to the patient's selection, to the design of the implants and the steps of implant installation.

On the other hand, the mechanical factors are mainly related to the amount of stress transmitted to the supporting structure whether implants or ridges. Also, the level of oral hygiene is of great importance to the serviceability of the implants and its indirect effect on the residual alveolar ridge changes. The age of the selected patients was nearly the same and ranged between 50 and 60 years to avoid the effect of old age on the degree of bone changes, as the catabolic process is relatively higher than the anabolic process. Also hormonal imbalance is another factor. Maintenance of proper oral hygiene may be deficient in old people and hence its effect on alveolar bone changes which is the target of this study. Patients were free from systemic diseases that could affect the metabolic, and a catabolic process was selected to avoid the adverse effect of systemic disorders on the healing process, a condition of the bone and soft tissues that might affect the results of this study. Regarding the process of brushing in the telescopic group, no difficulty was experienced by the patients as the dentures can be removed and cleaned easily. All patients have been totally edentulous for at least one year before placement of implants to avoid the effect of bone remodelling which follows tooth extraction. Only patients having Angle's class I ridge relationship were selected to avoid subjecting the implants to abnormal forces. The flapless surgical technique was followed in this study due to short surgical procedure causing less damage resulting in less post-operative pain, swelling and discomfort to the patient. The adequate thickness of buccal and lingual bone around the implant was a demand to ensure higher implant stability. Also, safety bone margin of two millimetres from the vital anatomical structures was considered. Cone-beam computed tomography (CBCT) was the imaging technique in this study. Data acquisition was done using Cone-beam computed tomography (CBCT) to visualise bone availability, bone quality and vital anatomical structures. Cone-beam computed tomography (CBCT) allowed visualisation of the bone in a buccolingual direction for optimising the virtual implant placement during the planning phase. Also, cone-beam computed tomography (CBCT) delivers reduced radiation dose and produces a radiographic image of adequate quality to assist in the preoperative surgical planning [28]. The technology used in this study was

selective laser sintering (SLS) rapid prototyping and the material used was polyetheretherketone (PEEK). PEEK provided several advantages like being of high strength; autoclavable possess a high degree of accuracy [26]. Anchoring fixation screws were used to stabilise the template and avoid the rotation during operation [28]. In the screw retained group the parallelism between the implants and passive fit of superstructure is a request in order to avoid the determinant lateral forces that may be applied to the implants, the same principle of passive fit of the appliance was considered in the telescopic group, to assure this in that group primary copings screwed to the implants and secondary copings fixed in the metal framework embedded in the acrylic resin base were precisely done to be passively fit. Also, the metal framework carrying the secondary copings could help this request as it is accurate enough to overcome the discrepancy that could occur if the secondary copings were embedded directly in the acrylic resin.

To assure passive seating of the metallic framework of the screw-retained prosthesis an acrylic resin verification jig was constructed over the implants in the inter foraminal region that must seat passively without movement, rock or interference. In case the jig didn't satisfy this request as happened in one case, the jig was split and screwed to the implant abutment and joined with dura lay inside the patient's mouth and a new impression was taken. Changes regarding the upper arch are not the concern of this study as it was covered by another member of the team. However, it was opposed with implant prostheses in both groups to simulate to some extent the forces and the stresses transmitted and opposing natural teeth as it was not easy to select all the cases under investigation with single upper dentulous and lower edentulous. Panoramic radiographs have been reported to be sufficiently reliable to evaluate the available bone height in the area of posterior mandible [29]. In this study tracing the panoramic radiograph was done following the proportional method followed by (Wright et al. 2002) [12] during the different follow-up periods. The author considered the changes of the proportional area measurement could represent the changes of the alveolar ridge height. This method helped in studying the changes in a wide area which is not possible with the other means. It is worthy to mention that the examined area is subjected to bone loss due the flexing of the mandible under masticatory load. This can be considered as indirect way of measurement for that reason vertical measurement were done on the radiographs considering the line tangent to the upper border of the two mental foramina as the horizontal base line and the tangent line to last implant on each side as a reference point for vertical measurement, three lines were measured on each side and the mean of them was conceded during the statistical analysis.

Generally speaking, the edentulous alveolar ridge resorption is a continuous process that occurs throughout life, so reduction of the alveolar ridge occurred in the two studied groups is expected. This reduction is most probably due to that the forces transmitted to the ridge exceed the physiological level of tolerance of the alveolar bone. Also wearing of the denture in general changes the ecology of the oral environment which may be responsible for the changes in the supporting soft tissues influencing the state of ridge reduction.

However, this alveolar ridge reduction was not the same in the two studied groups. The reduction was slightly higher in the screw retained group than the telescopic group. Although statistically non-significant this slight difference is most probably attributed to the relatively excessive masticatory forces exerted in the screw retained group as the patients used their prostheses with great confidence as their natural teeth. Another possible factor is the difficulty in maintaining proper denture and oral hygiene as the prosthesis is fixed by screws and patients complained of the difficulty of using brushes. Another point is that isolation of the supporting ridge depriving it of the natural stimulation of food and tongue subjected that tissues to inflammation hence its adverse effect on the degree of alveolar ridge resorption.

On the other hand, regarding the telescopic overdenture group the patient had the chance to maintain good oral and denture hygiene. It also gives ea chance for the tissues to rebound and recoil as the denture was kept out of the mouth during sleeping hours. Also, this group of patients knew that the denture is removable, so they were cautious about using it avoiding eating hard food that needs exertion of that much forces hence the relatively less bone resorption in this group.

Honestly, the results of this study do not recommend one of the two options over the other as the difference in the degree of bone resorption in the two studied groups is very small (statistically not – significant), however, if this study was extended for a longer period the difference might be more evident.

In conclusion, up to the limitations of this study both treatment options the screw retained and telescopic overdenture can be used for rehabilitation of completely edentulous patients. These cases must be followed for a longer period to have a definite answer regarding their efficiency in the long run.

References

1. Serino G, Ström C. Peri-implantitis in partially edentulous patients: Association with inadequate plaque control. *Clin Oral Implants Res.* 2009;20(2):169-174. <https://doi.org/10.1111/j.1600-0501.2008.01627.x> PMID:19077152

2. Kern JS, Kern T, Wolfart S, Heussen N. A systematic review and meta-analysis of removable and fixed implant-supported prostheses in edentulous jaws: post-loading implant loss. *Clin Oral Implants Res.* 2016;27(2):174-95. <https://doi.org/10.1111/clr.12531> PMID:25664612 PMCID:PMC5024059
3. Christopher B, Ho CK, Hons BDS, et al. Implant rehabilitation in the edentulous jaw: the "All-on-4" immediate function concept. *Australasian Dental Practice.* 2012;(March/April):138-148.
4. Rangert B, Nobre M. Concept with Brånemark System® Implants for Completely Edentulous Mandibles : A Retrospective Clinical Study. *Implant Dent.* 2003;5:2-9. <https://doi.org/10.1111/j.1708-8208.2003.tb00010.x>
5. El-Anwar MI, El-Zawahry MM. A three dimensional finite element study on dental implant design. *J Genet Eng Biotechnol.* 2011;9(1):77-82. <https://doi.org/10.1016/j.jgeb.2011.05.007>
6. Binon PP. Implants and components: entering the new millennium. *Int J Oral Maxillofac Implants.* 2000;15(1):76-94. PMID:10697942
7. Zitzmann NU, Berglundh T. Definition and prevalence of peri-implant diseases. *J Clin Periodontol.* 2008;35(SUPPL. 8):286-291. <https://doi.org/10.1111/j.1600-051X.2008.01274.x> PMID:18724856
8. Resnik RR, Kircos LT, Misch CE. Diagnostic imaging and techniques. Misch CE, *Contemporary Implant Dentistry.* 3rd ed. St. Louis, MO: Mosby. 2008:38-67.
9. Hoffmann O, Beaumont C, Tatakis DN, Zafiroopoulos G. Telescopic crowns as attachments for implant supported restorations: A case series. *J Oral Implantol.* 2006:291-300. <https://doi.org/10.1563/0-815.1> PMID:17193931
10. El-anwar MI, El-zawahry MM, El-mofty M. Load Transfer on Dental Implants and Surrounding Bones 1. *Aust J Basic Appl Sci.* 2012;6(3):551-560.
11. Mohamed M EL- Zawahry, Mohamed I EL- Anwar, Mohamed S EL-Mofty,Ahmed F EL-Ragi, Biological and Chemical Sciences. *Res J Pharm Biol Chem Sci.* 5(388):388-396.
12. Wright PS, Glantz P-O, Randow K, Watson RM. The effects of fixed and removable implant- stabilised prostheses on posterior mandibular residual ridge resorption. *Clin Oral Implants Res.* 2002;13(2):169-174. <https://doi.org/10.1034/j.1600-0501.2002.130207.x> PMID:11952737
13. Wittneben J-G, Millen C, Brägger U. Clinical performance of screw- versus cement-retained fixed implant-supported reconstructions--a systematic review. *Int J Oral Maxillofac Implants.* 2014;29(Suppl):84-98. <https://doi.org/10.11607/jomi.2014suppl.q2.1> PMID:24660192
14. Torrado E, Ercoli C, Mardini M Al, Graser GN, Tallents RH, Cordaro L. A comparison of the porcelain fracture resistance of screw-retained and cement-retained implant-supported metal-ceramic crowns. *J Prosthet Dent.* 2004;91(6):532-537. <https://doi.org/10.1016/j.prosdent.2004.03.014> PMID:15211294
15. Sailer I, Mühlemann S, Zwahlen M, Hämmerle CHF, Schneider D. Cemented and screw-retained implant reconstructions: a systematic review of the survival and complication rates. *Clin Oral Implants Res.* 2012;23:163-201. <https://doi.org/10.1111/j.1600-0501.2012.02538.x> PMID:23062142
16. Winkler S. *Essentials of Complete Denture Prosthodontics.* 1996:341-351.
17. Babbush C a, Kutsko GT, Brokloff J. The All-on-Four Immediate Function Treatment Concept With NobelActive Implants: A Retrospective Study. *J Oral Implantol.* 2011;37(4):431-445. <https://doi.org/10.1563/AAID-JOI-D-10-00133> PMID:21186961
18. Ural C, Bereket C, Sener ., Aktan A, Akpınar Y. Bone height measurement of maxillary and mandibular bones in panoramic radiographs of edentulous patients. *J Clin Exp Dent.* 2011;3(1):e5-e9. <https://doi.org/10.4317/jced.3.e5>
19. Elkholy S, Zaki M. Evaluation of the posterior edentulous area with implant supported removable partial denture versus implant supported fixed partial denture as treatment option for free end cases: a six months follow up study. *Dental Journal.* 2012;58(2995):3004.
20. Chen S, Buser D. Esthetic Outcomes Following Immediate and Early Implant Placement in the Anterior Maxilla — A systematic Review. *Int J Oral Maxillofac Implants.* 2014;29(Supplement):186-215. <https://doi.org/10.11607/jomi.2014suppl.q3.3> PMID:24660198
21. Atieh M, Payne AGT, Duncan WJ, de Silva RK, Cullinan MP. Immediate placement or immediate restoration/loading of single implants for molar tooth replacement: a systematic review and meta-analysis. *Int J Oral Maxillofac Implants.* 2009;25(2):401-415.
22. Malo P, Nobre MDA, Moss SM, Molina GJ, Lopes A. Updated information and services including high-resolution figures, can be found in the online version of this article at: *Jada.* 2011;142:310-320. <https://doi.org/10.14219/jada.archive.2011.0170> PMID:21357865
23. Schneider D, Marquardt P, Zwahlen M, Jung RE. A systematic review on the accuracy and the clinical outcome of computer-guided template-based implant dentistry. *Clin Oral Implants Res.* 2009;20(SUPPL. 4):73-86. <https://doi.org/10.1111/j.1600-0501.2009.01788.x> PMID:19663953
24. Tal H, Moses O. A comparison of panoramic radiography with computed tomography in the planning of implant surgery. *Dentomaxillofac Radiol.* 1991;20(1):40-42. <https://doi.org/10.1259/dmfr.20.1.1884852> PMID:1884852
25. Neugebauer J, Stachulla G, Ritter L, et al. Computer-aided manufacturing technologies for guided implant placement. *Expert Rev Med Devices.* 2010;7(1):113-129. <https://doi.org/10.1586/erd.09.61> PMID:20021243
26. Hultin M, Svensson KG, Trulsson M. Clinical advantages of computer-guided implant placement: A systematic review. *Clin Oral Implants Res.* 2012;23(SUPPL.6):124-135. <https://doi.org/10.1111/j.1600-0501.2012.02545.x> PMID:23062137
27. Esposito M, Grusovin MG, Worthington H V. Interventions for replacing missing teeth: antibiotics at dental implant placement to prevent complications. *Cochrane Database Syst Rev.* 2013;7(7):CD004152. <https://doi.org/10.1002/14651858.cd004152.pub4>
28. Verhamme LM, Meijer GJ, Boumans T, Schutyser F, Bergé SJ, Maal TJJ. A clinically relevant validation method for implant placement after virtual planning. *Clin Oral Implants Res.* 2013;24(11):1265-1272. PMID:22905668
29. Vazquez L, Nizamaldin Y, Combesure C, et al. Accuracy of vertical height measurements on direct digital panoramic radiographs using posterior mandibular implants and metal balls as reference objects. *Dentomaxillofac Radiol.* 2013;42(2):20110429. <https://doi.org/10.1259/dmfr.20110429> PMID:23360688 PMCID:PMC3699017